

Case Report

Spontaneous Twin Pregnancy in Uterus Bicornis Unicollis

Arzu Doruk,¹ Ilay Gozukara,² Güneş Burkaş,¹ Esin Bilik,¹ and Talat Umut Kutlu Dilek¹

¹ Department of Obstetrics and Gynecology, Mersin University, School of Medicine, 33200 Mersin, Turkey

² Department of Obstetrics and Gynecology, Kütahta Dumlupınar University, School of Medicine, 43050 Kütahta, Turkey

Correspondence should be addressed to Ilay Gozukara; ilayozt@gmail.com

Received 4 September 2013; Accepted 7 October 2013

Academic Editors: G. Capobianco, M. A. Osmanagaoglu, S. Salhan, and P. Schuetze

Copyright © 2013 Arzu Doruk et al. This is an open access article distributed under the Creative Commons Attribution License, which permits unrestricted use, distribution, and reproduction in any medium, provided the original work is properly cited.

Abnormal fusion of the Müllerian ducts or failure of resorption of the septum causes varying degrees of congenital uterine malformation. They are often associated with reproductive problems such as miscarriage, premature labour, premature rupture of the membranes, or malpresentation. Twin gestation in a case of bicornuate uterus is extremely rare. A 37-year-old multiparous woman conceived a twin dichorionic diamniotic pregnancy spontaneously. Three-dimensional ultrasound revealed bicornuate uterus with one embryo in each cavity. Perinatal course was uneventful. At 35 weeks of pregnancy, spontaneous labour started and twin babies were delivered by bilateral low transvers caesarean section. Because of the rare occurrence of twin gestation in bicornuate uterus, there is no uniform guideline to manage these cases appropriately. Delivery by planned caesarean section could avoid the possible obstetric complications by dystocia.

1. Introduction

Congenital abnormalities of female genital tract may involve fallopian tubes, uterus, cervix, and vagina. Uterine anomalies are the most commonly seen form Müllerian fusion anomalies. Uterine anomalies are associated with both normal or adverse reproductive outcomes [1]. Various occurrence rates were reported by reproductive performance. In the fertile group, incidence was reported as 3-4%, 5-10% in women with recurrent early pregnancy loss, and up to 25% in women with late first or second trimester pregnancy loss or preterm delivery [2, 3]. Also these congenital anomalies are associated with late pregnancy adverse outcomes including preterm delivery and malpresentations [4]. Optimal way of pregnancy follow up is controversial in patients with Müllerian fusion anomalies. Spontaneous twin pregnancies in case of uterus bicornis unicollis were reported rarely. We reported an extremely rare occurrence of spontaneous twin pregnancy in a women uterus bicornis unicollis.

2. Case

A 37-year-old woman applied to hospital with twin pregnancy at 8th week of pregnancy. She was referred by suspicion of twin pregnancy that located in separate uterine cavities.

During the gynecological exam, single cervix was detected. In the first ultrasound exam, a viable twin dichorionic pregnancy was seen. Both gestational sacs were located in separate uterine cavities. Crown-Rump Length (CRL) of embryos was 8,9 mm and 8,8 mm, respectively. Subsequent 3D ultrasound exam by Philips HD 11 SE which equipped 3D8-4 convex probe (Philips, Milwaukee, USA) revealed one twin in each uterine cavity (Figures 1 and 2) and that the uterus was bicornuate (Figures 1 and 2). Pregnancy outcome was uneventful. Down syndrome screening was performed by only nuchal translucency (NT) measurement and presence or absence of nasal bone. Down syndrome risk was calculated by NT for each twin separately. Anatomical survey by ultrasound was normal for each fetus. The patient was examined regularly in 2-3-week interval. Growth of both fetus was appropriate. At 35 weeks of pregnancy, she admitted by regular and painful uterine contractions. Cervical dilation was 2 cm and effacement was 50%. Both twins were in cephalic presentation. Presented part of fetus was over the pelvic inlet. She underwent caesarean-section due to previous C-section history. Both twins were delivered successfully by two separate lower segment transverse incisions. Birth weights were 2140 and 2270 g, respectively. Apgar scores were 7/9 and 8/9 at 1 and 5 minutes, respectively. Each incision was repaired simultaneously by two different operators with

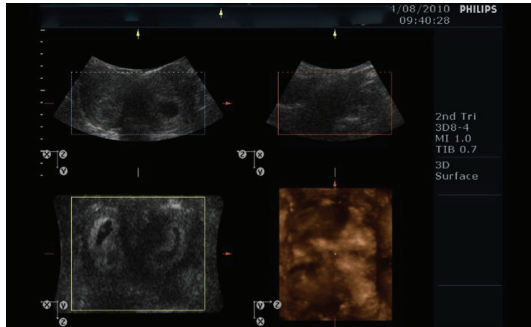


FIGURE 1: Two embryos were located in separate cavities of the bicornuate uterus.

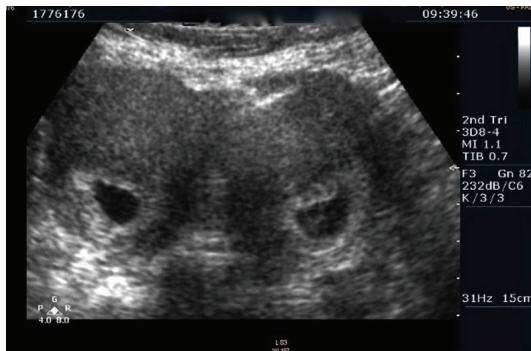


FIGURE 2: Two gestational sacs in coronal and sagittal view of 3D ultrasound.

two rows of polyglactin sutures (Figure 3). There were no complications in the early and late postoperative periods. Total blood loss did not exceed 1000 mL (collected by surgical suction system and blood stained compress). She was discharged from the hospital 2 days after delivery with two healthy babies.

3. Discussion

Bicornuate uterus results from incomplete fusion of 2 uterine horns (Müllerian tubes) leading to varying degrees of separation between the cavities. Complete bicornuate uterus has two separate uterine cavities without any communication. Uterine anomalies have been associated with an increased incidence of spontaneous abortion, malpresentation, placental abruption, preterm delivery, intrauterine growth restriction, and the need for operative delivery [3, 5, 6]. The theories which were used to explain adverse pregnancy outcomes are diminished muscle mass, abnormal uterine blood flow, and cervical insufficiency [4].

We did not perform cervical cerclage to prevent second trimester pregnancy loss due to cervical insufficiency. She had two successful term deliveries.

There are no guidelines about the followup of the pregnancy or selecting the mode of delivery, because the incidence is very low [7]. To date, there are only 12 reported cases of twin pregnancy in bicornuate uterus [7–11]. Mode of delivery could be abdominal or vaginal. However, dystocia,



FIGURE 3: Two incisions were repaired separately.

malpresentation, and possible risk of uterine rupture are major handicaps to avoid in the vaginal delivery [8].

We delivered twins by abdominal delivery. We performed first incision to deliver the first baby, and immediately a second incision was done to deliver the second one. Following the delivery of the fetuses and placentas, each incision was sutured simultaneously by two operators.

Pregnancies of women with Müllerian anomalies have some potential obstetric complications. However, pregnancies within the bicornuate uteri have better obstetric outcome than other Müllerian fusion defects [3, 4]. The management of twin pregnancy in uterus bicornis should be individualized because of the possible risk and the rare occurrence of these cases.

Conflict of Interests

The authors confirm that there is no known conflict of interests associated with this paper and that there has been no significant financial support for this work that could have influenced its outcome.

References

- [1] A. L. Stein and C. M. March, "Pregnancy outcome in women with müllerian duct anomalies," *The Journal of Reproductive Medicine*, vol. 35, pp. 411–415, 1990.
- [2] G. F. Grimbizis, M. Camus, B. C. Tarlatzis, J. N. Bontis, and P. Devroey, "Clinical implications of uterine malformations and hysteroscopic treatment results," *Human Reproduction Update*, vol. 7, no. 2, pp. 161–174, 2001.
- [3] F. Raga, C. Bauset, J. Remohi, F. Bonilla-Musoles, C. Simón, and A. Pellicer, "Reproductive impact of congenital Müllerian anomalies," *Human Reproduction*, vol. 12, no. 10, pp. 2277–2281, 1997.
- [4] D. E. Reichman and M. R. Laufer, "Congenital uterine anomalies affecting reproduction," *Best Practice and Research: Clinical Obstetrics and Gynaecology*, vol. 24, no. 2, pp. 193–208, 2010.
- [5] A. W. Cohen and G. Chhibber, "Obstetric complications of congenital anomalies of the paramesonephric ducts," *Seminars in Reproductive Endocrinology*, vol. 4, no. 1, pp. 59–65, 1986.

- [6] L. K. Green and R. E. Harris, "Uterine anomalies. Frequency of diagnosis and associated obstetric complications," *Obstetrics and Gynecology*, vol. 47, no. 4, pp. 427–429, 1976.
- [7] M. Arora, N. Gupta, N. Neelam, and S. Jindal, "Unique case of successful twin pregnancy after spontaneous conception in a patient with uterus bicornis unicollis," *Archives of Gynecology and Obstetrics*, vol. 276, no. 2, pp. 193–195, 2007.
- [8] M. Cruceyra, C. Iglesias, M. la Calle, M. Sncha, S. L. Magallon, and S. González, "Successful delivery of a twin pregnancy in a bicornuate uterus (uterus bicornis unicollis) by bilateral Caesarean section," *Journal of Obstetrics and Gynaecology Canada*, vol. 33, no. 2, pp. 142–144, 2011.
- [9] F. K. Ahmad, S. J. Sherman, and K. H. Hagglund, "Twin gestation in a woman with a uterus didelphys: a case report," *The Journal of Reproductive Medicine*, vol. 45, no. 4, pp. 357–359, 2000.
- [10] M. M. Jones and M. C. Flanagan, "Twin pregnancy in a uterus didelphys delivered by bilateral repeat cesarean sections," *Journal of the National Medical Association*, vol. 65, no. 1, pp. 53–54, 1973.
- [11] R. Kekkonen, M. Nuutila, and T. Laatikainen, "Twin pregnancy with a fetus in each half of a uterus didelphys," *Acta Obstetrica et Gynecologica Scandinavica*, vol. 70, no. 4-5, pp. 373–374, 1991.