



Case report

Wandering Ozurdex in eyes with scleral fixated intraocular lens and its management: A report of two cases

Ashok Kumar, Vikas Ambiya*, Gaurav Kapoor, Amit Arora

Army College of Medical Sciences and Base Hospital, New Delhi, India

Received 21 September 2018; revised 15 October 2018; accepted 19 October 2018

Available online 9 November 2018

Abstract

Purpose: To report a complication little reported until now: to and fro migration of the dexamethasone implant between the anterior and posterior segment (wandering Ozurdex) of sclera fixated intraocular lens (IOL) eyes and its effective management.

Methods: Two cases of to and fro migration of Ozurdex (wandering Ozurdex) in two pseudophakic patients with scleral fixated posterior chamber IOL: first, a case of Vogt Koyanagi Harada (VKH) disease and second, a case of pseudophakic cystoids macular edema (CME) were successfully managed.

Results: Both patients were initially managed with repositioning of implants by supine posturing and use of drugs, but implants again migrated into anterior chamber and underwent surgical removal with preservation of corneal transparency.

Conclusions: Patients with scleral fixated posterior chamber IOL present a high risk of anterior chamber migration of the Ozurdex implant. Prompt removal of Ozurdex implant in these patients can reduce risk of endothelial decompensation. In such cases, returning the implant with positioning is not a good option.

Copyright © 2018, Iranian Society of Ophthalmology. Production and hosting by Elsevier B.V. This is an open access article under the CC BY-NC-ND license (<http://creativecommons.org/licenses/by-nc-nd/4.0/>).

Keywords: Ozurdex; Dexamethasone implant; Wandering Ozurdex; Migrating Ozurdex

Introduction

Ozurdex is a dexamethasone (700 µg) rod-shaped, biodegradable implant, 6 mm in length and 0.46 mm in diameter, which is injected into the vitreous cavity. The Ozurdex intravitreal implant has been approved for the management of several ocular diseases including macular edema due to retinal vein occlusion (RVO),^{1,2} non-infectious uveitis affecting the posterior segment,^{3,4} and diabetic macular edema (DME).⁵ The efficacy and safety of the Ozurdex

implant has also been reported in cases of pseudophakic cystoid macular edema (CME).⁶

Despite the clinical evidence of its efficacy, certain rare complications associated with the Ozurdex implant have been described. These include not only long-term adverse events such as cataract and secondary glaucoma,⁷ but also complications due to the implant itself, such as desegmentation (fracture) of the implant,⁸ accidental injection of the implant into the crystalline lens,⁹ and migration of the implant into the anterior chamber.¹⁰

The migration of an Ozurdex implant into the anterior chamber represents an uncommon complication of this procedure. To and fro motion of wandering implant between the anterior and posterior segments can not only reduce its efficacy, but can also result in corneal endothelial damage, leading to serious visual impairment. The condition can be managed by either extracting the implant through a sclerocorneal incision or repositioning it into the vitreous cavity.¹¹

Conflicts of interest: The authors declare that they have no conflict of interest.

* Corresponding author. Army College of Medical Sciences and Base Hospital, Delhi Cantonment, New Delhi, 110010, India.

E-mail address: vikasambiya@gmail.com (V. Ambiya).

Peer review under responsibility of the Iranian Society of Ophthalmology.

<https://doi.org/10.1016/j.joco.2018.10.007>

2452-2325/Copyright © 2018, Iranian Society of Ophthalmology. Production and hosting by Elsevier B.V. This is an open access article under the CC BY-NC-ND license (<http://creativecommons.org/licenses/by-nc-nd/4.0/>).

We describe two cases of wandering Ozurdex implant in two eyes with scleral fixated intraocular lenses (IOLs), which were initially managed with repositioning of implant by pharmacological mydriasis and supine positioning of patients' head, but subsequently needed extraction of the implant through the limbal route.

Case report

Case 1

A 65-year-old male patient, a known case of Vogt Koyanagi Harada (VKH) syndrome for the past 15 years, had multiple recurrences with both anterior and posterior segment manifestations of the disease, each episode having been managed with systemic steroids, with good visual recovery. He had undergone uneventful cataract surgery in both eyes with posterior chamber IOL implantation 10 years earlier. He presented eight months ago with spontaneous dislocation of IOL in his right eye for which he underwent IOL explantation with glued scleral fixated IOL implantation in the same eye.

The patient again presented to our institute two months ago with complaints of diminution of vision, ocular pain, and photophobia in both eyes. On examination, he had in both eyes, a best corrected visual acuity (BCVA) of 6/60, cells 2+ and flare 2+ in the anterior chamber, vitritis, with massive CME (right more than left eye) on optical coherence tomography (OCT). In view of bilaterality of the condition, he was started on systemic steroids, to which he developed systemic adverse effects. He was therefore considered for Ozurdex implant in both eyes, along with systemic immunosuppression. He underwent intravitreal Ozurdex implantation in the left eye followed by the right eye at an interval of one week, after ruling out baseline features of glaucoma. He responded well to Ozurdex with significant reduction in macular edema after the injection.

He reported to our clinic 3 weeks after the procedure with complaints of pain, redness, and diminution of vision in the right eye. Examination revealed BCVA of 3/60 in the right eye and 6/24 in the left eye. The Ozurdex implant in the right eye was found to have migrated into the anterior chamber, with associated corneal stromal edema and Descemet's membrane folds. The left eye was relatively quiet with minimal macular edema. The patient was reluctant to undergo immediate explantation of the implant and opted for conservative management. The implant was maneuvered back into the vitreous cavity by positioning the patient's head supine after inducing pharmacological mydriasis, followed by pharmacological miosis. However, the patient presented again after two days with recurrence of symptoms due to re-migration of the implant into the anterior chamber of the right eye [Fig. 1A]. He was managed with immediate extraction of Ozurdex implant from the right eye through a limbal incision and was simultaneously given a posterior subtenon injection of triamcinolone acetonide (40 mg in 1 ml) in the same eye. He responded well to treatment with complete resolution of

corneal edema [Fig. 1B] and CME two weeks after extraction of the implant. His BCVA improved to 6/18 in the right eye after one month, and posterior segment examination revealed a quiet sunset glow fundus in both eyes [Fig. 1C,D].

Case 2

A 54-year-old healthy male patient had undergone an eventful cataract surgery in his right eye eight months earlier with intra-operative posterior capsular tear and was left aphakic. He underwent pars plana vitrectomy with scleral fixated IOL implantation in his right eye 6 months ago with a postoperative BCVA of 6/18 in the operated eye. He subsequently developed diminution of vision in the same eye four months after the surgery, when examination revealed BCVA of 3/60, despite a well-centered IOL. OCT of the right eye revealed CME [Fig. 2A], while fundus fluorescein angiography showed petalloid pattern of perifoveal leakage and a leakage from the optic disc confirming the diagnosis of pseudophakic CME.

Patient was managed with intravitreal Ozurdex implant in the right eye after ruling out preexisting glaucoma. He responded well to treatment with improvement of BCVA to 6/24 and complete resolution of CME in four weeks following injection. But he again presented with acute diminution of vision in the right eye with examination revealing BCVA of 6/60, mild corneal edema, and migrated Ozurdex implant lying in pupillary area in front of the IOL in the same eye [Fig. 2B]. Since the patient had a good response to Ozurdex implant, the implant was displaced to the back of the vitreous cavity by pharmacologically dilating the pupil, keeping the patient's head supine and finally constricting the pupil with pilocarpine. The patient returned after four days with similar symptoms and was found to have migrated implant again lying in the anterior chamber in front of the IOL. He was managed with immediate explantation of the implant through a clear corneal incision and simultaneous posterior subtenon injection of triamcinolone acetonide (40 mg in 1 ml) in the same eye. He responded well to treatment with resolution of corneal edema [Fig. 2C] and the CME three weeks after the explantation, with a final BCVA of 6/18 and a normal foveal contour on OCT of the right eye.

Discussion

Ozurdex intravitreal implant has been used in the treatment of macular edema secondary to central and branch RVOs, DME, and for the treatment of non-infectious posterior uveitis. It has also been shown to be effective in refractory pseudophakic CME.^{12,13} Although the absence of the lens capsule and prior vitrectomy are the known risk factors for migration of the implant into the anterior chamber, this complication has also been reported in eyes with an intact posterior capsule.^{10,14} The major complications of anterior chamber migration are corneal decompensation and elevation of intraocular pressure (IOP). Corneal endothelial toxicity is possibly due to

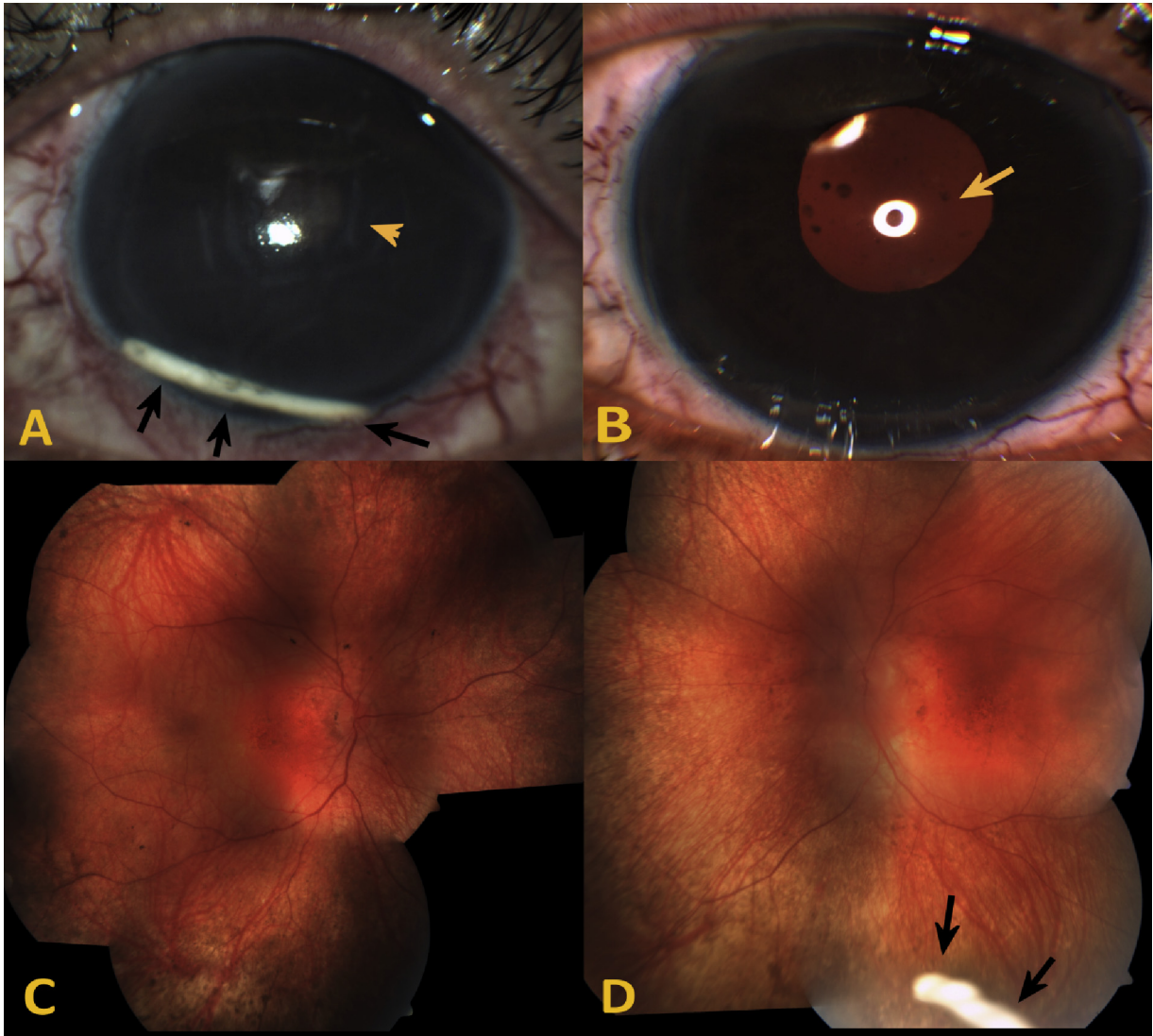


Fig. 1. A 65-year-old male patient with a recurrent episode of Vogt Koyanagi Harada (VKH) syndrome was injected intravitreal Ozurdex (dexamethasone implant) in both eyes. He had a scleral fixated intraocular lens (IOL) in the right eye. **A.** Color photograph of the anterior segment of right eye showing Ozurdex implant (black arrows) migrated into the anterior chamber three weeks after implantation. The eye had corneal endothelial damage with Descemet membrane folds (yellow arrowhead) and stromal edema. The implant was repositioned into the vitreous cavity by posturing the head, but the implant migrated back into the anterior chamber. The best corrected visual acuity (BCVA) in the right eye was 3/60. The implant was immediately explanted through a clear corneal incision. **B.** Color photograph of the same eye showing a clear cornea after explantation of Ozurdex implant from the anterior chamber and a well-centered scleral fixated IOL in situ (yellow arrow). The BCVA in the right eye improved to 6/18. **C.** Color fundus photograph of the right eye after explantation of Ozurdex, showing a sunset glow fundus. **D.** Color fundus photograph of the left eye showing Ozurdex implant (black arrows) in inferior vitreous with sunset glow fundus in the background.

mechanical trauma from the rigid implant as well as chemical toxicity. Unresolved or chronic corneal edema may be severe enough to warrant keratoplasty, thereby justifying an early surgical removal of the implant if it cannot be repositioned back to the vitreous cavity by posturing the patients appropriately.

The non-invasive repositioning of the implant by posturing and pharmacotherapy have been reported and described.¹⁵ We followed the conservative method of management initially, but the implant re-migrated into the anterior chamber in two and four days, respectively, in both cases. In order to avoid vision-

threatening complications of retained implant in the anterior chamber, the wandering Ozurdex was removed from anterior route through a small limbal incision with viscoexpression and using vitreous forceps.

It is imperative to be cautious while using a dexamethasone implant in eyes with aphakia, scleral fixated IOLs, posterior capsular compromise, or dehiscence. Alternative routes of steroid administration like sub-tenon depot injection, or oral or topical routes should be preferred in these cases. With a frequent follow-up, early detection of migrated implant is possible. The complication can be managed non-invasively as

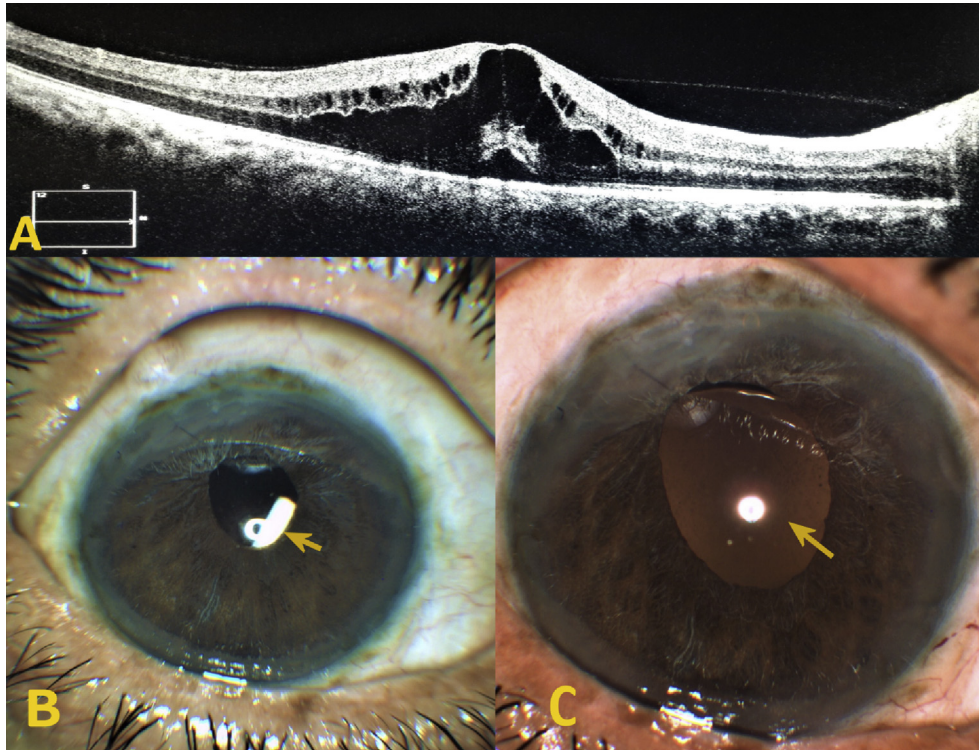


Fig. 2. A 54-year-old male patient with a scleral fixated intraocular lens (IOL) was implanted with Ozurdex implant for treating pseudophakic cystoid macular edema (CME). **A.** Optical coherence tomogram of the right eye showing pseudophakic CME. **B.** Color photograph of the anterior segment of the right eye showing the Ozurdex implant (yellow arrow) migrated into the anterior chamber, lying in the pupil, anterior to the IOL. The best corrected visual acuity (BCVA) in right eye was 3/60. **C.** Color photograph of the same eye after explantation of Ozurdex implant from the anterior chamber and a well-centered scleral fixated IOL (yellow arrow). The BCVA of the same eye improved to 6/18.

described, but a wandering implant repetitively migrating into anterior segment requires surgical extraction, in order to prevent complications such as corneal decompensation and raised IOP. Thus, it is a first attempt at management of wandering Ozurdex in scleral fixated IOL eyes with dual approach of conservative as well as surgical extraction. Returning the implant with positioning is not a good option in such cases.

References

- Haller JA, Bandello F, Belfort Jr R, et al. Randomized, sham-controlled trial of dexamethasone intravitreal implant in patients with macular edema due to retinal vein occlusion. *Ophthalmology*. 2010;117(6):1134–1146.
- Pacella E, Vestri AR, Muscella R, et al. Preliminary results of an intravitreal dexamethasone implant (Ozurdex®) in patients with persistent diabetic macular edema. *Clin Ophthalmol*. 2013;7:1423–1428.
- Lowder C, Belfort Jr R, Lightman S, et al. Dexamethasone intravitreal implant for noninfectious intermediate or posterior uveitis. *Arch Ophthalmol*. 2011;129(5):545–553.
- Pacella F, Ferraresi AF, Turchetti P, et al. Intravitreal injection of Ozurdex® implant in patients with persistent diabetic macular edema, with six-month follow-up. *Ophthalmol Eye Dis*. 2016;8:11–16.
- Pacella E, La Torre G, Turchetti P, et al. Evaluation of efficacy dexamethasone intravitreal implant compared to treatment with anti-VEGF in the treatment of diabetic macular edema. *Senses Sci*. 2014;1(4):164–168.
- Belloq D, Korobelnik JF, Burillon C, et al. Effectiveness and safety of dexamethasone implants for post-surgical macular oedema including Irvine-Gass syndrome: the EPISODIC study. *Br J Ophthalmol*. 2015;99(7):979–983.
- Meyer LM, Schönfeld CL. Secondary glaucoma after intravitreal dexamethasone 0.7 mg implant in patients with retinal vein occlusion: a one-year follow-up. *J Ocul Pharmacol Ther*. 2013;29(6):560–565.
- Agrawal R, Fernandez-Sanz G, Bala S, Addison PK. Desegmentation of Ozurdex implant in vitreous cavity: report of two cases. *Br J Ophthalmol*. 2014;98(7):961–963.
- Coca-Robinot J, Casco-Silva B, Armada-Maresca F, García-Martínez J. Accidental injections of dexamethasone intravitreal implant (Ozurdex) into the crystalline lens. *Eur J Ophthalmol*. 2014;24(4):633–636.
- Khurana RN, Appa SN, McCannel CA, Elman MJ, Wittenberg SE, Parks DJ. Dexamethasone implant anterior chamber migration: risk factors, complications, and management strategies. *Ophthalmology*. 2014;121(1):67–71.
- Kishore SA, Schaal S. Management of anterior chamber dislocation of dexamethasone implant. *Ocul Immunol Inflamm*. 2013;21(1):90–91.
- London NJ, Chiang A, Haller JA. The dexamethasone drug delivery system: indications and evidence. *Adv Ther*. 2011;28(5):351–366.
- Kapoor KG, Wagner MG, Wagner AL. The sustained-release dexamethasone implant: expanding indications in vitreoretinal disease. *Semin Ophthalmol*. 2015;30(5–6):475–481.
- Kocak N, Ozturk T, Karahan E, Kaynak S. Anterior migration of dexamethasone implant in a pseudophakic patient with intact posterior capsule. *Indian J Ophthalmol*. 2014;62(11):1086–1088.
- Srinivasan P, Jayadev C, Shetty R. The nomadic Ozurdex®: anterior migration of the dexamethasone implant and back!. *Oman J Ophthalmol*. 2017;10(2):109–111.