

CASE REPORT

INTERMEDIATE

CLINICAL CASE

# Iatrogenic Radial Recurrent Artery Perforation in Coronary Intervention



Sathish Parasuraman, MBBS,<sup>a</sup> Holly Morgan, MBBS,<sup>b</sup> Rito Mitra, MBBS, MD<sup>b</sup>

## ABSTRACT

An 80-year-old man underwent percutaneous coronary intervention of the left anterior descending coronary artery for intractable angina. During catheter advancement, he experienced an iatrogenic perforation of the radial recurrent artery that was successfully managed by covered stent placement in the radial artery, effectively occluding the radial recurrent branch. (**Level of Difficulty: Intermediate.**) (J Am Coll Cardiol Case Rep 2019;1:737-41) © 2019 The Authors. Published by Elsevier on behalf of the American College of Cardiology Foundation. This is an open access article under the CC BY-NC-ND license (<http://creativecommons.org/licenses/by-nc-nd/4.0/>).

## HISTORY OF PRESENTATION

An 80-year-old Caucasian man was referred for elective percutaneous coronary intervention (PCI) for intractable angina. Previous diagnostic coronary angiography had shown severe mid left anterior descending coronary artery (LAD) stenosis. His right radial artery was occluded after his diagnostic procedure, so left radial access was planned.

Left radial access was obtained using a 6-F Glide-sheath Slender (Terumo, Tokyo, Japan). A 6-F extra backup guide was selected for the intervention and advanced over a 0.035-inch J-tipped guidewire. The

guidewire would not advance beyond the (left) radioumeral joint. However, the guide catheter was accidentally advanced beyond the wire tip. This was recognized early; the guidewire was removed, and a contrast injection was performed (Video 1). This showed diffuse contrast staining. The guide was pulled back, and repeat angiography was performed with 3 ml of contrast (Figure 1). This showed a perforation of the proximal radial recurrent artery, with the proximal radial artery in secondary spasm.

## MEDICAL HISTORY

The patient was known to have hypertension and hypercholesterolemia, with normal renal function and hemoglobin level. Percutaneous intervention was decided as the best method of revascularization, per American and European guidelines.

## DIFFERENTIAL DIAGNOSIS

With extensive contrast staining, the differential diagnoses were radial artery perforation, brachial artery perforation, radial artery dissection, or a branch (of the radial) artery perforation.

## LEARNING OBJECTIVES

- Operators should be aware of perforation as a complication of radial access and the importance of early recognition and definitive management to reduce the risk for subsequent compartment syndrome.
- Operators should understand the management options for radial perforation, including the use of covered stents should conservative management steps fail.

From <sup>a</sup>Musgrove Park Hospital, Taunton, United Kingdom; and the <sup>b</sup>University Hospital of Wales, Cardiff, United Kingdom. The authors have reported that they have no relationships relevant to the contents of this paper to disclose.

Informed consent was obtained for this case.

Manuscript received August 28, 2019; revised manuscript received October 18, 2019, accepted October 22, 2019.

**ABBREVIATIONS  
AND ACRONYMS**

**LAD** = left anterior descending coronary artery

**PCI** = percutaneous coronary intervention

**INVESTIGATIONS**

Because dissection of the artery was a possibility, strong antegrade injection was not performed. Gentle injections with 3 ml of contrast showed a perforation at the proximal part of the radial recurrent artery. The radial artery cranial to the radial recurrent branch was in vasospasm secondary to catheter-induced injury (Video 2).

**MANAGEMENT**

A floppy tip 0.014-inch angioplasty wire (Versaturn, Abbott Laboratories, Lake Bluff, Illinois) was carefully advanced across the origin of the radial recurrent branch into the proximal radial artery and then into the aortic root. The extra backup guide catheter could not be advanced easily over the wire, so balloon tracking using a 2.5 × 15 mm semicompliant balloon (inflated to 4 atm) was performed to allow guide advancement. PCI to the LAD was then performed without complication (Figures 2A and 2B).

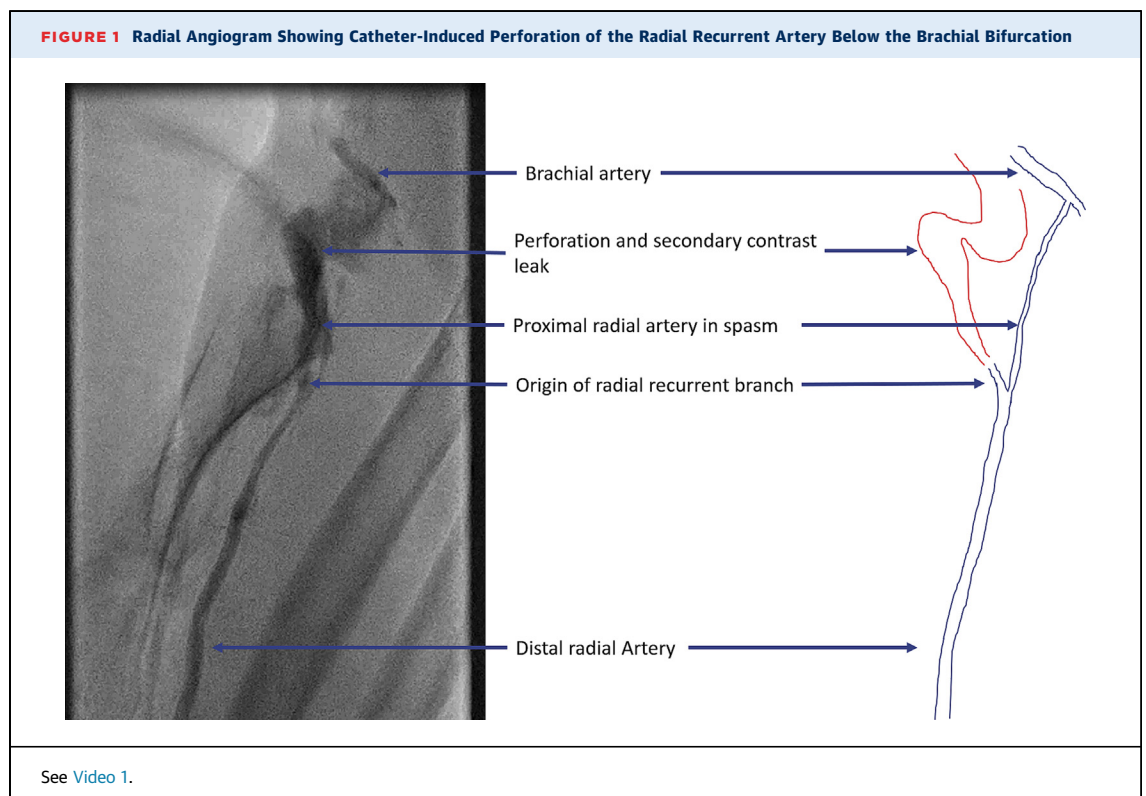
The procedure was completed in 40 min. Intra-arterial heparin was used as sole anticoagulant agent, with activated coagulation time guidance (target 250 to 300 s maintained throughout). After completion of the coronary intervention, the guide was withdrawn back into the brachial artery, leaving a

Versaturn wire in the left subclavian artery. Brachial angiography was performed with 5 ml of contrast, during which time the catheter was pulled back into the radial artery. This again demonstrated contrast extravasation from the radial recurrent branch (Figure 3).

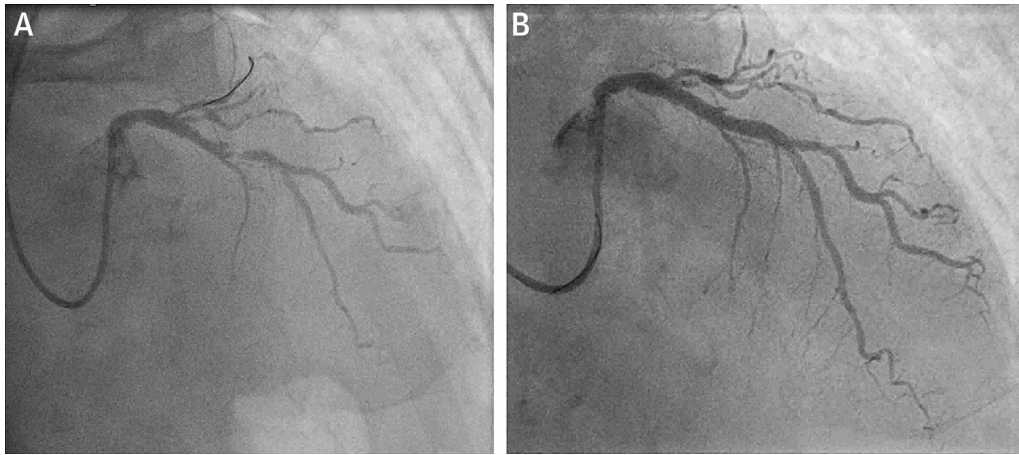
Initial attempts to occlude the radial recurrent branch perforation with a 2.5 × 15 mm semicompliant balloon were made, with 2 episodes of 10-min inflations. However, this did not successfully occlude the artery and control the perforation (Figure 4A). A 2.5 × 18 mm pericardium covered stent (Aneugraft, ITGI Medical, Or Akiva, Israel) was then implanted across the radial recurrent branch. There was still flow into the radial recurrent branch after stent implantation (Video 3), which was managed with post-dilatation of the stent, first with a 3-mm and then with a 4-mm noncompliant balloon (Figures 4A and 4B). This successfully occluded the radial recurrent branch and ended contrast extravasation (Figure 4C, Video 4).

**DISCUSSION**

Radial artery access is recommended over femoral artery access for coronary interventions by the European Society of Cardiology (1). Compared with femoral access, radial access is shown to reduce major bleeding, vascular complications, and major acute



**FIGURE 2** Stenosis of the Mid LAD

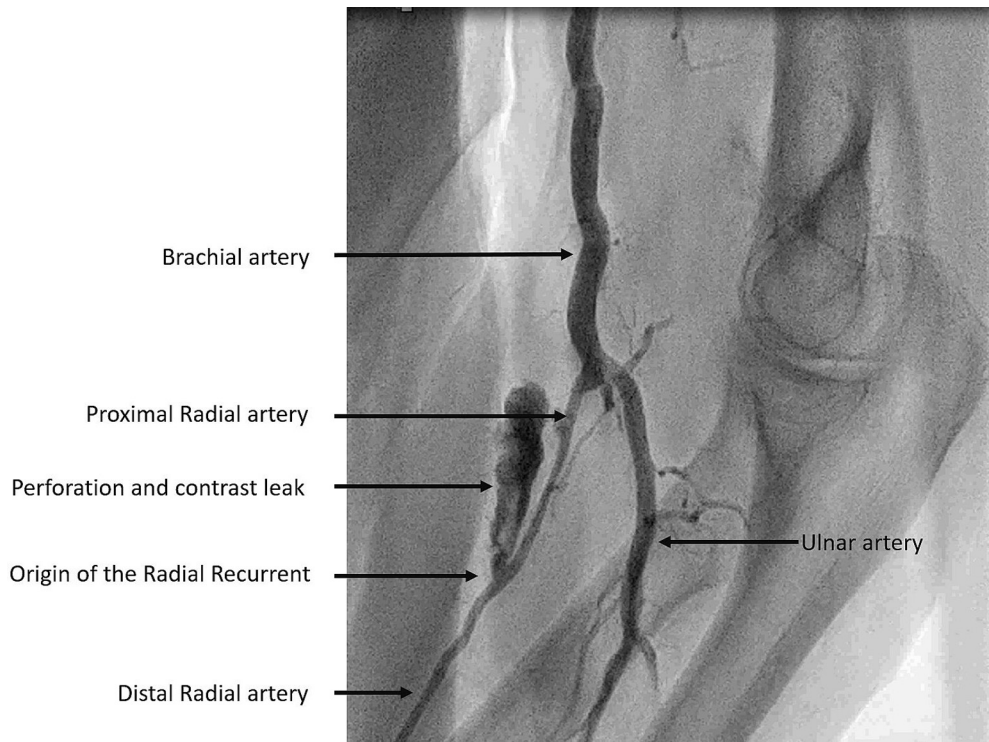


(A) Severe stenosis of the mid left anterior descending coronary artery (LAD). (B) Treated mid LAD stenosis.

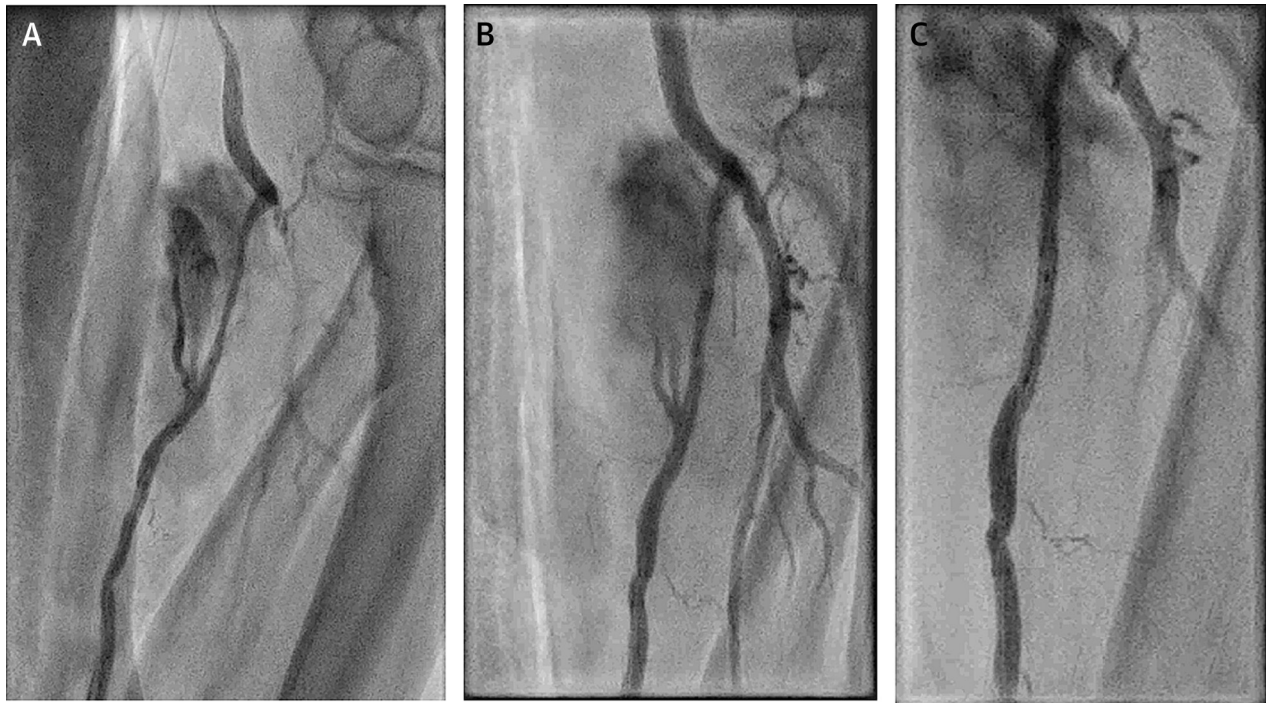
cardiovascular events (2). Analysis of a large American registry of more than 290,000 patients with ST-segment elevation myocardial infarction showed that transradial access resulted in lower risk for

bleeding and lower in-hospital mortality (3). The large randomized MATRIX trial, which compared transradial and femoral access in acute coronary syndromes, showed that radial access reduced

**FIGURE 3** Post-PCI Brachioradial Angiogram Showed Persistent Leak Into the Radial Recurrent Branch and Contrast Extravasation



See [Video 2](#). PCI = percutaneous coronary intervention.

**FIGURE 4** Sealing of the Radial Recurrent Branch

**(A)** Balloon tamponade failed to occlude the radial recurrent branch. **(B)** Covered stent reduced the flow but did not stop it completely. See [Video 3](#). **(C)** After post-dilatation of covered stent with a 4-mm noncompliant balloon, the radial recurrent branch was sealed completely. See [Video 4](#).

bleeding risk and 30-day mortality compared with femoral access.

Access-site complications are extremely rare in radial access, occurring in <1% of cases (4). Vessel spasm, hematoma, dissection, perforation, and compartment syndrome can complicate radial access procedures, with spasm being the most common and usually occurring with no sequelae (4). Increased tortuosity in the radial artery can increase the risk for complications, as was seen in this patient ([Figures 1 and 4](#)). Perforation is a rare complication in trans-radial access. In a large series of 10,324 patients undergoing radial access coronary procedures, radial perforation occurred in 8 patients (0.08%) (5). Once recognized, radial perforations can be overcome using a balloon-assisted tracking technique to advance a guide, or by using a sheathless guide (6). The guide allows coronary intervention to be completed while tamponading the radial artery perforation. Guide tamponade is a sufficient treatment in most cases, resulting in closure of the perforation by the end of the procedure (6). Insertion of extra long sheaths (up to 23 cm) extending into the brachial artery has also been

described, thereby sheath-tamponading the perforation (7). This is considered a useful option if multiple catheter exchanges are expected but comes at the recognized increased risk of placing a large sheath in the brachial artery. Simultaneous external compression with a manual blood pressure cuff can also aid in achieving hemostasis. If there is persistent radial contrast extravasation, prolonged balloon tamponade across the perforation is the logical next step (8). If this fails to stop the contrast leak, then a covered stent can be deployed across the perforation.

Advanced age, female sex, shorter stature, and hypertension are risk factors for radial artery perforation (7). Radial artery spasm, a small-caliber vessel, anatomic variations including radial loop, and aggressive catheter manipulation can also contribute to the occurrence of perforation (8). In this case, perforation occurred because of the advancement of a guiding catheter beyond the guidewire into the radial artery.

To our knowledge this is the first reported case of radial recurrent artery perforation during coronary intervention, treated by the deployment of a covered

stent across the radial recurrent branch. Because the left arm was positioned across the patient's body to allow the operator to reach from the right side, the patient's left elbow was maintained in a flexed position during the procedure. On reflection, this could have led to selective wire and subsequently catheter advancement into the radial recurrent branch during wire advancement. Strategies that may have reduced the perforation risk in this case and should be considered by all operators when using left radial access, include advancement of the wire across a straightened left elbow as well as careful catheter manipulation.

If forearm swelling is noted post-procedure, external compression with a manual blood pressure cuff inflated to 10 to 15 mm Hg below systolic pressure for 2 periods of 15 min is recommended (9). Unrecognized radial perforations can lead to continuous bleeding into the forearm and can cause compartment syndrome (10). The normal pressure in the forearm compartments is <10 mm Hg, and a pressure >30 mm Hg suggests the development of compartment syndrome (10). Surgical fasciotomy is the definitive treatment for compartment syndrome,

which if untreated can lead to tissue ischemia and significant long term-sequelae (10).

#### FOLLOW-UP

The patient was subsequently reviewed in the outpatient clinic 6 weeks after the procedure and had made a full recovery with no ongoing vascular complications.

#### CONCLUSIONS

Perforation is a rare complication in radial access coronary interventions. Dissection and perforation of the radial artery or its branches is possible as described. Operators should remain calm and use a stepwise approach to manage the situation. Balloon tracking techniques can be used to allow the radial procedures to be completed despite significant endothelial trauma.

**ADDRESS FOR CORRESPONDENCE:** Dr. Holly Morgan, Cardiology Department, University Hospital of Wales, Cardiff CF14 4XW, United Kingdom. E-mail: [morganhp7@gmail.com](mailto:morganhp7@gmail.com). Twitter: [@hollymorgs](https://twitter.com/hollymorgs).

#### REFERENCES

1. Neumann F-J, Sousa-Uva M, Ahlsson A, et al. 2018 ESC/EACTS guidelines on myocardial revascularization. *Eur Heart J* 2018;40:87-165.
2. Valgimigli M, Frigoli E, Leonardi S, et al. Radial versus femoral access and bivalirudin versus unfractionated heparin in invasively managed patients with acute coronary syndrome (MATRIX): final 1-year results of a multicentre, randomised controlled trial. *Lancet* 2018;392:835-48.
3. Baklanov DV, Kaltenbach LA, Marso SP, et al. The prevalence and outcomes of transradial percutaneous coronary intervention for ST-segment elevation myocardial infarction: analysis from the National Cardiovascular Data Registry (2007 to 2011). *J Am Coll Cardiol* 2013;61:420-6.
4. Agostoni P, Biondi-Zoccai GGL, De Benedictis ML, et al. Radial versus femoral approach for percutaneous coronary diagnostic and interventional procedures: systematic overview and meta-analysis of randomized trials. *J Am Coll Cardiol* 2004;44:349-56.
5. Tatli E, Buturak A, Cakar A, et al. Unusual vascular complications associated with transradial coronary procedures among 10,324 patients: case based experience and treatment options. *J Interv Cardiol* 2015;28:305-12.
6. Liang M, Burgess S, Aitken A, et al. TCTAP A-122 the use of sheathless Eaucath to overcome radial artery spasm and perforation. *J Am Coll Cardiol* 2014;63 12 Suppl 2:S35.
7. Calviño-Santos RA, Vázquez-Rodríguez JM, Salgado-Fernández J, et al. Management of iatrogenic radial artery perforation. *Catheter Cardiovasc Interv* 2004;61:74-8.
8. Sallam MM, Ali M, Al-Sekaiti R. Management of radial artery perforation complicating coronary intervention: a stepwise approach. *J Interv Cardiol* 2011;24:401-6.
9. Tizon-Marcos H, Barbeau GR. Incidence of compartment syndrome of the arm in a large series of transradial approach for coronary procedures. *J Interv Cardiol* 2008;21:380-4.
10. Shroff A, Siddiqui S, Burg A, Singla I. Identification and management of complications of transradial procedures. *Curr Cardiol Rep* 2013;15:350.

**KEY WORDS** branch perforation, covered stent, radial complications, radial dissection, radial PCI, radial perforation, radial recurrent perforation

**APPENDIX** For supplemental videos, please see the online version of this paper.