

Diagnostic Accuracy of Lymphoscintigraphy for Lymphedema and Analysis of False-Negative Tests

Aladdin H. Hassanein, MD, MMSc*
 Reid A. Maclellan, MD, MMSc*
 Frederick D. Grant, MD†
 Arin K. Greene, MD, MMSc*

Background: Lymphedema is the chronic enlargement of tissue due to inadequate lymphatic function. Diagnosis is made by history and physical examination and confirmed with lymphoscintigraphy. The purpose of this study was to assess the accuracy of lymphoscintigraphy for the diagnosis of lymphedema and to determine characteristics of patients with false-negative tests.

Methods: Individuals referred to our lymphedema program with “lymphedema” between 2009 and 2016 were analyzed. Subjects were assessed by history, physical examination, and lymphoscintigraphy. Patient age at presentation, duration of lymphedema, location of disease, gender, previous infections, and lymphedema type were analyzed.

Results: The study included 227 patients (454 limbs); lymphedema was diagnosed clinically in 169 subjects and confirmed by lymphoscintigraphy in 162 (117 primary, 45 secondary; 96% sensitivity). Fifty-eight patients were thought to have a condition other than lymphedema, and all had negative lymphoscintigrams (100% specificity). A subgroup analysis of the 7 individuals with lymphedema clinically, but normal lymphoscintigrams, showed that all had primary lymphedema; duration of disease and infection history were not different between true-positive and false-negative lymphoscintigram results ($P = 0.5$). Two patients with a false-negative test underwent repeat lymphoscintigraphy, which then showed lymphatic dysfunction consistent with lymphedema.

Conclusion: Lymphoscintigraphy is very sensitive and specific for lymphedema. All patients with false-negative studies had primary lymphedema. A patient with a high clinical suspicion of lymphedema and a normal lymphoscintigram should be treated conservatively for the disease and undergo repeat lymphoscintigraphy. (*Plast Reconstr Surg Glob Open* 2017;5:e1396; doi: 10.1097/GOX.0000000000001396; Published online 12 July 2017.)

INTRODUCTION

Lymphedema is the chronic, progressive swelling of tissue due to inadequate lymphatic function. The disease is caused by abnormal development of the lymphatic system (primary) or injury to lymph vessels and nodes (secondary). Many conditions can produce enlargement of an extremity; 25% of patients referred to a lymphedema pro-

gram with “lymphedema” have another disease.^{1,2} Distinguishing lymphedema from other diseases that cause limb overgrowth is necessary because the natural history and treatment of lymphedema is distinct from other disorders.

Lymphedema is managed by compression regimens and/or operative interventions.^{3–10} Although lymphedema usually can be identified by history and physical examination, diagnostic confusion is common and the most definitive test for the condition is lymphoscintigraphy. This radionuclide imaging test involves the injection of a tracer protein into the distal extremity, which is preferentially taken up by the lymphatic vasculature because of its high molecular weight. A gamma camera then detects the signal emitted by the protein as it migrates proximally to the inguinal or axillary lymph nodes.^{1,3,9} The purpose of this study was to (1) assess the accuracy of lymphoscintigraphy for the diagnosis of lymphedema and (2) determine characteristics of patients with false-negative tests.

*From the *Lymphedema Program, Department of Plastic and Oral Surgery, Boston Children's Hospital, Harvard Medical School, Boston, Mass.; and †Division of Nuclear Medicine and Molecular Imaging, Department of Radiology, Boston Children's Hospital, Harvard Medical School, Boston, Mass.*

Received for publication December 9, 2016; accepted May 9, 2017.

Copyright © 2017 The Authors. Published by Wolters Kluwer Health, Inc. on behalf of The American Society of Plastic Surgeons. This is an open-access article distributed under the terms of the Creative Commons Attribution-Non Commercial-No Derivatives License 4.0 (CCBY-NC-ND), where it is permissible to download and share the work provided it is properly cited. The work cannot be changed in any way or used commercially without permission from the journal.

DOI: 10.1097/GOX.0000000000001396

Disclosure: The authors have no financial interest to declare in relation to the content of this article. The Article Processing Charge was paid for by the authors.

METHODS

Following approval from the Committee on Clinical Investigation at Boston Children's Hospital, patients referred to our Lymphedema Program between 2009 and 2016 were analyzed. Individuals were evaluated clinically and a lymphoscintigram was obtained to verify lymphedema or confirm normal lymphatic function. Evaluation was performed by the senior author (A.K.G.), and patients were categorized with either (1) lymphedema or (2) another condition causing an enlarged extremity based on history and physical examination findings.

Lymphoscintigraphy was performed using Tc99m-labeled filtered sulfur colloid. The radiopharmaceutical (100 millicurie) was injected intradermally approximately 1–2 cm proximal to the second and fourth tarsometatarsal joint (lower extremity) or metacarpophalangeal joint (upper extremity) bilaterally. Imaging with a gamma camera then was performed 45 minutes, 2 hours, and 4 hours later using an ultra-high resolution collimator (matrix 256×256, 5 minutes). Each study was interpreted by an attending radiologist in the Division of Nuclear Medicine and Molecular Imaging. Lymphatic dysfunction was diagnosed if lymphoscintigraphy exhibited delayed transit time of the radiolabeled colloid to the regional lymph nodes (> 45 minutes), dermal backflow, asymmetric node uptake, and/or formation of collateral lymphatic channels.^{3,4}

Patient age at presentation, duration of lymphedema, location of disease, gender, previous infections, and lymphedema type (primary or secondary) were analyzed. Exclusion criteria were (1) individuals with a body mass index > 50 kg/m² (the diagnosis of obesity-induced lymphedema requires lymphoscintigraphy and cannot be made by history and physical examination),^{7–10} (2) patients who did not follow-up for lymphoscintigraphy, and (3) subjects with a history and physical examination that was indeterminate for lymphedema.

RESULTS

The study included 227 patients (454 limbs); 72% were female and 28% male. Mean age was 36.7±23 years.

Lymphedema was diagnosed clinically in 169 subjects and confirmed by lymphoscintigraphy in 162 (72% primary, 28% secondary; Fig. 1). Fifty-eight individuals were thought to have a condition other than lymphedema and all had negative lymphoscintigrams (specificity 100%; Fig. 2). Seven patients were diagnosed with lymphedema clinically but had negative lymphoscintigrams (sensitivity 96%; Fig. 3).

A subgroup analysis of the 7 patients with lymphedema clinically but a normal lymphoscintigram was performed. Each individual had primary lymphedema, 4 were male, 5 had bilateral disease, 6 involved the lower extremity, and 2 had previous infections. Lymphedema type, duration of disease, and infection history were not different between patients with true-positive and false-negative lymphoscintigrams ($P = 0.5$). Mean duration of disease before lymphoscintigram was 9 years (range, 1 month to 32 years). Two patients with a false-negative result underwent repeat lymphoscintigraphy 2–3 years later and exhibited a positive study consistent with lymphedema.

DISCUSSION

The term “lymphedema” often is used generically to describe patients with an enlarged extremity, regardless of the etiology of their condition.^{1,2} Lymphedema is managed with counseling regarding activities of daily living (e.g., infection prevention), compression regimens, and operative interventions.^{3–10} Lymphedema usually can be diagnosed by history and physical examination. Characteristic findings include a family history of the disease, axillary/inguinal radiation, lymphadenectomy, travel to areas endemic for filariasis, or extreme obesity (body mass index > 50). Primary lymphedema affects 1/100,000 individuals¹¹; men usually have bilateral lower extremity swelling during infancy, and women typically present with unilateral limb enlargement in adolescence.⁵ Secondary lymphedema accounts for > 99% of lymphedema cases; swelling typically begins 12 months after the injury to lymph vessels.¹² Pitting edema almost always affects the distal limb and later

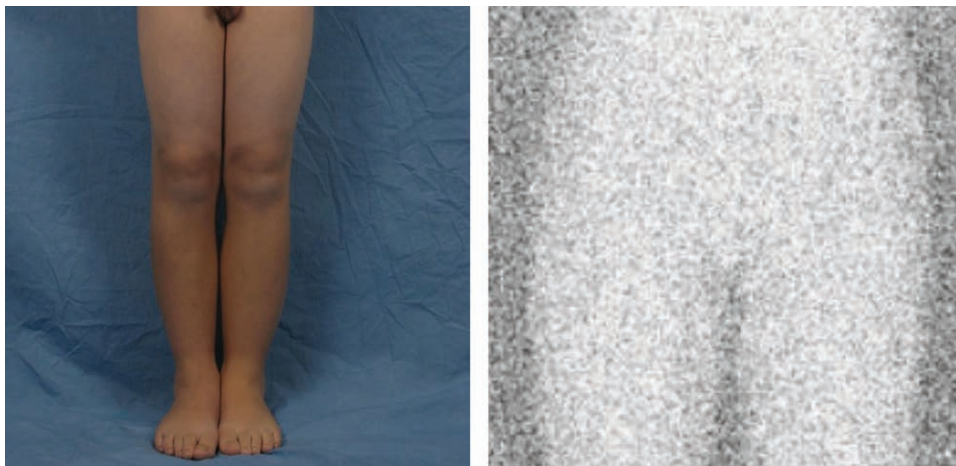

Fig. 1. True-positive lymphoscintigram result. An 11-year-old boy with a history and physical examination consistent with primary lymphedema. Lymphoscintigraphy confirmed the diagnosis and showed absence of tracer in the inguinal nodes 4 hours after injection (normal transit time is less than 1 hour).

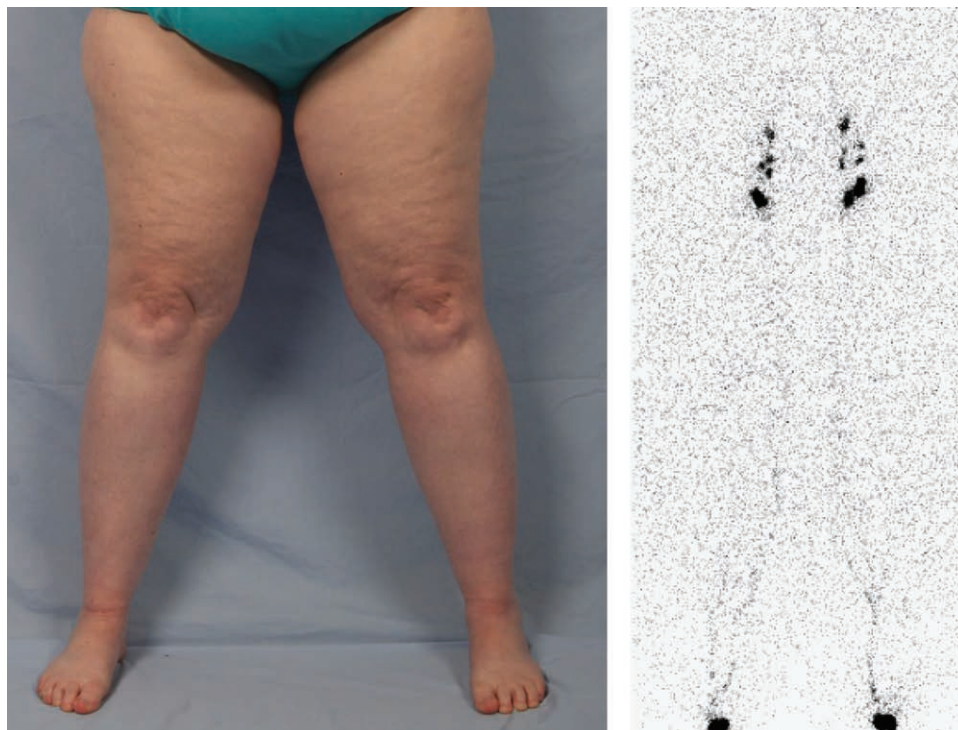


Fig. 2. True-negative lymphoscintigram result. A 45-year-old woman was referred with a diagnosis of bilateral lower extremity “lymphedema.” Her history and physical examination, however, was consistent with lipedema and not lymphedema. Lymphoscintigraphy confirms normal lymphatic function (tracer in the inguinal nodes 45 minutes after injection and no dermal backflow).

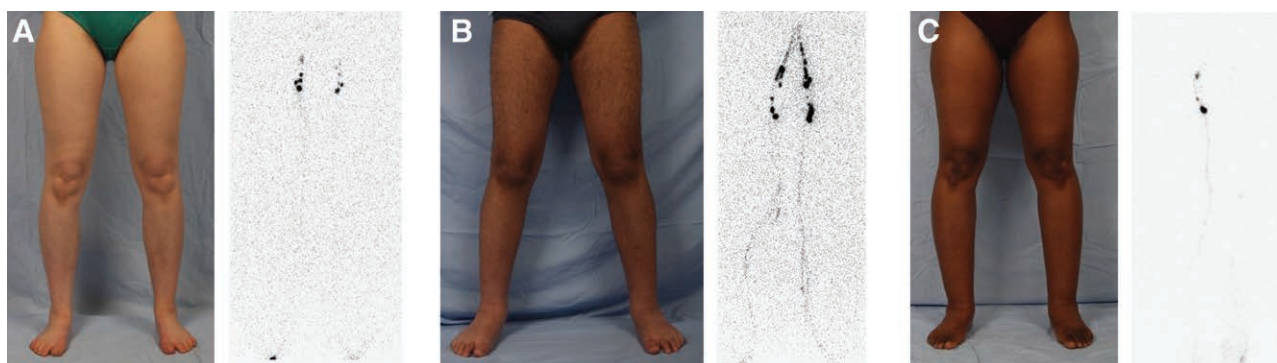


Fig. 3. False-negative lymphoscintigram studies in patients with a history and physical examination highly consistent with primary lymphedema. A) 25-Year-old woman with a 7-year history of right lower extremity swelling. Lymphoscintigram shows normal lymphatic function in both lower extremities (tracer uptake at 45 minutes and no dermal backflow). B) 16-Year-old boy with a 4-month history of bilateral lower extremity swelling. Lymphoscintigraphy illustrates normal lymphatic function on the 45-minute image. C) 48-Year-old woman with a 32-year history of symmetrical bilateral lower extremity edema. Lymphoscintigraphy shows lymphatic dysfunction in the left lower extremity (no transit to the inguinal nodes at 45 minutes and dermal backflow), but normal lymphatic function in the right lower extremity.

becomes nonpitting because of the development of subcutaneous adipose and fibrosis.¹³ A positive Stemmer sign (inability to pinch the base of the second finger or toe) typically is present.¹⁴

We perform lymphoscintigraphy on almost all patients referred to our center because the test (1) confirms lymphedema in patients with an equivocal clinical diagnosis, (2) verifies normal lymphatic function in those suspected to have another condition, or (3) documents the severity of

lymphatic dysfunction in patients thought to have lymphedema.⁶ Abnormal findings include delayed transit time of the radiolabeled colloid to the regional lymph nodes, dermal backflow, asymmetric node uptake, and/or formation of collateral lymphatic channels.^{3,4}

We found that the sensitivity (96%) of lymphoscintigraphy was superior to 2 smaller series in the literature published in 1989 (92%)³ and 1993 (73%)¹⁵; the specificity was similar (100%). Sensitivity of the test depends on

the clinician's ability to differentiate patients with lymphedema from those with other conditions. For example, if a subject with a disease other than lymphedema [e.g., lipedema, lymphatic malformation, arteriovenous malformation, venous malformation, infantile hemangioma, lipofibromatosis, Klippel-Trenaunay syndrome, CLOVES syndrome, Parkes-Weber syndrome, obesity, venous stasis, systemic disease (rheumatologic, cardiac, renal, hepatic), orthopedic condition (e.g., tenosynovitis, occult fracture, ligament sprain)] is thought to have lymphedema, then a normal lymphoscintigram will be a false-negative result and lower the sensitivity of the study. Our knowledge of conditions that cause extremity overgrowth has increased significantly over the past 25 years, and thus older studies may have included patients, who would not be considered to have lymphedema clinically by us. Because the clinical diagnosis of lymphedema relies on the physician's aptitude to assess the condition, a limitation of this study is that the false-negative rate of lymphoscintigraphy may be higher at a center with less experience managing the disease.

Although newer imaging modalities can give supplemental information about the lymphedematous extremity that may be useful for surgical planning,¹⁶ these tests are not as accurate for diagnosing lymphedema. Magnetic resonance lymphangiography outlines lymphatic vasculature of the limb but has a sensitivity of 68% for lymphedema.¹⁷ Indocyanine green lymphangiography details subdermal lymphatics, but the specificity for lymphedema is 55%.¹⁸

Our subgroup analysis of patients who had a false-negative lymphoscintigram result indicated that all the patients were diagnosed clinically with primary lymphedema; none of the subjects thought to have secondary lymphedema had a false-negative study. No predictive variables were associated with a false-negative result. Possible reasons that the test did not show abnormalities in some patients with the disease clinically include (1) the clinical impression was incorrect and the study was a true-negative, (2) patients had early disease below the sensitivity of the test, (3) primary lymphedema with hypoplastic/aplastic lymphatics has delayed findings compared with secondary lymphedema, and (4) there is an inherent false-negative rate with the study (e.g., technical variation with the location/volume of tracer injection or gamma camera function).

Two patients with primary lymphedema clinically and normal lymphoscintigrams underwent repeat lymphoscintigraphy, which was abnormal and confirmed lymphedema. As a result of this observation, we recommend that an individual with a high clinical suspicion of lymphedema should be treated conservatively for the disease with compression regimens even if lymphoscintigraphy does not confirm the diagnosis. The test should be repeated at least 1 year later. If the test continues to show normal lymphatic function, we consider discontinuing compression treatment depending on the patient's symptoms.

CONCLUSIONS

Lymphoscintigraphy is very sensitive (96%) and specific (100%) for diagnosing lymphedema when performed at a high volume center. Individuals with false-negative

tests in the study had primary lymphedema, but no predictive factors were identified. Patients with a high clinical suspicion of lymphedema and a normal lymphoscintigram should be treated conservatively for the disease and undergo repeat lymphoscintigraphy.

Arin K. Greene, MD, MMSc

Department of Plastic and Oral Surgery
Boston Children's Hospital
300 Longwood Ave.
Boston, MA 02115

E-mail: arin.greene@childrens.harvard.edu

REFERENCES

- Schook CC, Mulliken JB, Fishman SJ, et al. Differential diagnosis of lower extremity enlargement in pediatric patients referred with a diagnosis of lymphedema. *Plast Reconstr Surg*. 2011;127:1571–1581.
- Maclellan RA, Couto RA, Sullivan JE, et al. Management of primary and secondary lymphedema: analysis of 225 referrals to a center. *Ann Plast Surg*. 2015;75:197–200.
- Gloviczki P, Calcagno D, Schirger A, et al. Noninvasive evaluation of the swollen extremity: experiences with 190 lymphoscintigraphic examinations. *J Vasc Surg*. 1989;9:683–9; discussion 690.
- Szuba A, Shin WS, Strauss HW, et al. The third circulation: radio-nuclide lymphoscintigraphy in the evaluation of lymphedema. *J Nucl Med*. 2003;44:43–57.
- Schook CC, Mulliken JB, Fishman SJ, et al. Primary lymphedema: clinical features and management in 138 pediatric patients. *Plast Reconstr Surg*. 2011;127:2419–2431.
- Maclellan RA, Greene AK. Lymphedema. *Semin Pediatr Surg*. 2014;23:191–197.
- Greene AK, Grant FD, Slavin SA. Lower-extremity lymphedema and elevated body-mass index. *N Engl J Med*. 2012;366:2136–2137.
- Greene AK, Maclellan RA. Obesity-induced upper extremity lymphedema. *Plast Reconstr Surg Glob Open*. 2013;1:e59.
- Greene AK, Grant FD, Slavin SA, et al. Obesity-induced lymphedema: clinical and lymphoscintigraphic features. *Plast Reconstr Surg*. 2015;135:1715–1719.
- Greene AK. Diagnosis and management of obesity-induced lymphedema. *Plast Reconstr Surg*. 2016;138:111e–118e.
- Smeltzer DM, Stickler GB, Schirger A. Primary lymphedema in children and adolescents: a follow-up study and review. *Pediatrics*. 1985;76:206–218.
- Petrek JA, Senie RT, Peters M, et al. Lymphedema in a cohort of breast carcinoma survivors 20 years after diagnosis. *Cancer*. 2001;92:1368–1377.
- Brorson H, Svensson H. Liposuction combined with controlled compression therapy reduces arm lymphedema more effectively than controlled compression therapy alone. *Plast Reconstr Surg*. 1998;102:1058–67; discussion 1068.
- Stemmer R. [A clinical symptom for the early and differential diagnosis of lymphedema]. *Vasa*. 1976;5:261–262.
- Ter SE, Alavi A, Kim CK, et al. Lymphoscintigraphy. A reliable test for the diagnosis of lymphedema. *Clin Nucl Med*. 1993;18:646–654.
- Chang DW, Masia J, Garza R, 3rd, et al. Lymphedema: surgical and medical therapy. *Plast Reconstr Surg*. 2016;138:209S–218S.
- Weiss M, Burgard C, Baumeister R, et al. Magnetic resonance imaging versus lymphoscintigraphy for the assessment of focal lymphatic transport disorders of the lower limb: first experiences. *Nuklearmedizin*. 2014;53:190–196.
- Akita S, Mitsukawa N, Kazama T, et al. Comparison of lymphoscintigraphy and indocyanine green lymphography for the diagnosis of extremity lymphoedema. *J Plast Reconstr Aesthet Surg*. 2013;66:792–798.