

# Hybrid imaging in dementia: A semi-quantitative (<sup>18</sup>F)-fluorodeoxyglucose positron emission tomography/magnetic resonance imaging approach in clinical practice

## ABSTRACT

Neurodegenerative disorders may demonstrate typical lobar and regional patterns of volume loss with corresponding decreased glucose metabolism. In this retrospective study, we correlated semi-quantitative volumetric changes utilizing NeuroQuant morphometric analysis with decreased fluorodeoxyglucose (FDG) uptake age-matched calculated z-scores utilizing <sup>18</sup>F-FDG positron emission tomography/magnetic resonance imaging (PET/MRI). Eighty-nine patients (mean age 71.4) with clinical findings suggestive of various subtypes of dementia underwent PET/MR brain imaging. Cases were categorized as follows: Alzheimer's dementia (AD), frontotemporal lobar degeneration (FTLD), dementia with Lewy bodies (DLB), and corticobasal degeneration (CBD). NeuroQuant software provided semi-quantitative assessment of lobar-specific patterns of volume loss compared to age-matched controls. MIMneuro software provided semi-quantitative FDG uptake data, with metabolic z-scores generated in comparison to age-matched controls. Volumetric and metabolic data were then correlated for statistical significance. In 29 AD cases, Pearson correlation coefficient between z-score and lobar volume was 0.3 ( $P=0.120$ ) and 0.38 ( $P<0.05$ ), for parietal and temporal lobes, respectively. In 34 FTLD cases, it was 0.35 ( $P=0.051$ ) and 0.02 ( $P=0.916$ ), for frontal and temporal lobes, respectively. In 14 DLB cases, it was 0.42 ( $P=0.130$ ), 0.5 ( $P=0.067$ ), and 0.22 ( $P=0.447$ ) for the occipital lobes, middle occipital gyrus, and parietal lobes, respectively. In 12 CBD cases, it was 0.58 ( $P<0.05$ ) for the superior parietal lobule. Semi-quantitative (F18)-FDG PET/MRI analysis demonstrated a positive relationship between volumetric loss and hypometabolism within certain lobar-specific regions, depending on neurodegenerative disorder subtype. Our findings may add diagnostic confidence in the accurate imaging diagnosis of neurodegenerative disease.

**Keywords:** Brain hypometabolism, dementia, neurodegeneration, positron emission tomography/magnetic resonance imaging, semi-quantitative analysis

## INTRODUCTION

Hybrid positron emission tomography/magnetic resonance imaging (PET/MRI) provides an effective modality in the clinical evaluation of cognitively impaired patients. Dedicated high-resolution brain MR sequences provide quantifiable information that can be used to aid in diagnosis. Decreased radiation exposure with PET/MRI and improved motion correction functionality result in improved PET image quality and more accurate anatomic localization compared to PET/CT. In addition, simultaneous PET/MRI scanners allow for images to be obtained in a single, convenient session, minimizing patient discomfort. These advances in technology

**ANA MARIJA FRANCESCHI, KIYON NASER-TAVAKOLIAN<sup>1</sup>, MICHAEL CLIFTON<sup>1</sup>, OSAMA AHMED<sup>1</sup>, KATARINA STOFFERS<sup>1</sup>, LEV BANGIYEV<sup>1</sup>, GIUSEPPE CRUCIATA<sup>1</sup>, SEAN CLOUSTON<sup>2</sup>, DINKO FRANCESCHI<sup>1</sup>**

Department of Radiology, Donald and Barbara Zucker School of Medicine at Hofstra/Northwell Health, Manhasset, <sup>1</sup>Department of Radiology, Stony Brook University Hospital, Stony Brook, <sup>2</sup>Department of Family, Population and Preventative Medicine, SUNY Stony Brook, NY, USA

**Address for correspondence:** Dr. Ana Marija Franceschi, Department of Radiology, Northwell Health, Manhasset NY 11030 USA. E-mail: franceschi.amf@gmail.com

**Submission:** 21-Mar-2020, **Revised:** 23-May-2020, **Accepted:** 01-Jun-2020, **Published:** 02-Oct-2020

This is an open access journal, and articles are distributed under the terms of the Creative Commons Attribution-NonCommercial-ShareAlike 4.0 License, which allows others to remix, tweak, and build upon the work non-commercially, as long as appropriate credit is given and the new creations are licensed under the identical terms.

**For reprints contact:** WKHLRPMedknow\_reprints@wolterskluwer.com

**How to cite this article:** Franceschi AM, Naser-Tavakolian K, Clifton M, Ahmed O, Stoffers K, Bangiyev L, *et al.* Hybrid imaging in dementia: A semi-quantitative (<sup>18</sup>F)-fluorodeoxyglucose positron emission tomography/magnetic resonance imaging approach in clinical practice. World J Nucl Med 2021;20:23-31.

### Access this article online

#### Website:

www.wjnm.org

#### DOI:

10.4103/wjnm.WJNM\_27\_20

#### Quick Response Code



provide newer and more effective ways to evaluate patients with cognitive impairment and suspected underlying neurodegenerative disease.<sup>[1-3]</sup>

Neurodegenerative disorders typically manifest with a myriad of clinical symptoms, including memory loss, impaired higher-order cognitive functioning, and some degree of corresponding brain volume loss – all of which progress following diagnosis.<sup>[4]</sup> The most common form of dementia is Alzheimer's disease (AD) followed by frontotemporal lobar degeneration (FTLD), dementia with Lewy bodies (LBD), and other rare neurodegenerative disorders such as corticobasal degeneration (CBD), which are far less common.<sup>[5,6]</sup> Early diagnosis is essential in patients with suspected dementia as early intervention can slow progression and improve quality of life. As per the National Institute for Neurologic and Communicative Disorders and Related Disorders Association, when tissue sampling is not feasible, imaging and CSF biomarkers should be used for the diagnosis of neurodegenerative disorders.<sup>[7]</sup> Utilizing <sup>18</sup>F-fluorodeoxyglucose <sup>18</sup>F-FDG PET brain imaging aids in diagnosis as lobar-specific, characteristic patterns of hypometabolism may be evident in these patients.<sup>[8]</sup> FDG-PET brain imaging, and subsequently, metabolic analysis, is influenced by the volume of brain matter present within each area of interest, for example, partial volume averaging. Therefore, regions of atrophy may underestimate the degree of FDG uptake in select regions, depending on neurodegenerative disease subtype. Correcting for this is difficult and limited by the current technology. However, advanced hybrid imaging such as simultaneous PET/MRI may decrease this underestimation, thereby increasing accuracy of metabolic data interpretation.

Utilizing novel hybrid and molecular imaging techniques provides an avenue for improved early and accurate diagnosis of underlying neurodegenerative disorder. Multiple previous publications have extensively studied characteristic lobar and sublobar regional patterns of hypometabolism in the various dementia subtypes. Specifically, AD characteristically involves the precuneus, posterior cingulate gyrus, medial temporal, and posterior parietal lobes with corresponding hypometabolism in these regions.<sup>[8-11]</sup> Frontotemporal lobar dementia encompasses multiple disorders, with the behavioral variant being the most common. Other subtypes include primary progressive aphasia variants, including semantic dementia (svPPA), logopenic variant (lvPPA), agrammatic variant or progressive nonfluent aphasia (PNFA); and also, the progressive supranuclear palsy (PSP) variant of FTLD. Each of these disorders has slightly different patterns of hypometabolism, but the typical underlying lobar distribution

primarily involves the frontal and temporal lobes.<sup>[8,12-14]</sup> Finally, dementia with Lewy bodies classically demonstrates hypometabolism in the occipital lobes, including the mesial occipital lobes and primary visual cortex in a symmetric pattern, especially if presenting with visual hallucinations, a feature distinguishing it from Alzheimer's disease. There is also involvement of the parietal, mesial temporal regions, and posterior cingulate gyrus in DLB.<sup>[8,15-17]</sup>

CBD is a rare neurodegenerative disorder that classically presents with movement abnormalities, including myoclonus and alien limb phenomenon. This disorder is not as well understood as the other dementias, and previous studies have reported asymmetric, unilateral hypometabolism in the posterior frontal and parietal lobes typically involving the primary sensorimotor cortex and also in the ipsilateral basal ganglia and thalamus.<sup>[18]</sup>

Currently, there is limited data assessing the relationship between semi-quantitative changes in lobar-specific gray matter volumes and corresponding regions of brain hypometabolism in the various subtypes of dementia and neurodegenerative disease. In this retrospective study, we aim to identify the presence and strength of the relationship between cortical gray matter volume loss utilizing NeuroQuant morphometric analysis and decreased FDG uptake as per calculated hypometabolism z-scores using MIMneuro software in patients undergoing <sup>18</sup>F-FDG PET/MR brain imaging as part of their routine clinical dementia workup.

## MATERIALS AND METHODS

### Patients

This was an institutional review board and HIPAA-compliant retrospective study. We identified 175 patients who were referred from January 2015 to February 2019 for brain FDG PET/MRI examination as part of their routine clinical care. We excluded: patients younger than 18 years old, clinical indication other than dementia, pregnant women, and patients with a fasting blood glucose level >150 mg/dL; we also excluded all patients with PET/MRI scans without dedicated brain sequences, PET/MRI scans with technical issues such as missing sequences, or non-FDG PET/MRI studies. Of the 175 patients identified, 89 patients meeting inclusion criteria (average age 71.4 years, range 53–85 years) received a combined clinical and radiological diagnosis of a specific subtype of dementia (AD, FTLD, DLB, CBD) and were included in this study. Common presenting symptoms (must have been reported in >50% of patients) by dementia subtype were collected based on the referring clinician's

documentation. Neurocognitive testing varied based on the referring neurologist, and as such multiple different testing tools were used by private referrers as well as our staff academic neurologists. Due to this lack of consistency in the type of test and charting, standardized information was limited. The symptoms listed in Table 1 were obtained directly from the history of present illness in the patient’s medical charts. Additional available clinical information is summarized in Table 1.

The final imaging diagnosis was made by combining the pattern of FDG distribution and corresponding volume loss, as determined by our staff neuroradiologists and nuclear medicine physician, in communication with the referring clinician to correlate with the patient’s symptoms and cognitive testing results. For all dementia patients, semi-quantitative calculated z-scores < -1.65 (the threshold for statistically significant hypometabolism using MIMneuro software) in the selected regions of interest (ROIs) were considered abnormal and supportive of a specific diagnosis. For MRI volumetric analysis, the lobar and sublobar cortical volume loss was considered abnormal if gray matter volumes were less than the 5<sup>th</sup> percentile for age (>1.65 standard deviations [SDs] below the mean), as provided by NeuroQuant software.

**Image acquisition**

Before imaging, an injection of approximately 5 mCi of FDG was given. Allowing for 40 min of uptake, patients were positioned for brain imaging in a Siemens mMR 3T PET/MRI (Siemens Healthcare, Erlangen, Germany) scanner with a standard 12-channel head coil. The PET and MRI data were obtained simultaneously. A dual-echo T1-weighted gradient-recalled echo sequence was completed to acquire an MRI attenuation-correction map based on Dixon segmentation (air, fat, soft tissue, and lungs). MRI data

included images from the skull vertex to the foramen magnum. Standard high-resolution 3D sagittal MPRAGE and 3D fluid-attenuated inversion recovery (FLAIR) sequences were used for brain anatomy. Afterward, routine diagnostic MRI sequences including T2 Turbo Spin Echo in the axial and coronal planes, axial susceptibility-weighted imaging, diffusion tensor imaging, proton density axial imaging, and diffusion-weighted imaging were performed while PET data were simultaneously obtained for a total of 45 min.

Along with qualitative assessment, 3D MPRAGE image data were additionally evaluated by NeuroQuant (2019 CorTechs Labs, Inc., San Diego, California) for semi-quantitative volumetric analysis. The automated analysis provided by NeuroQuant compares lobar and sublobar cortical volumes to their standardized atlas. NeuroQuant is the Food and Drug Administration-cleared software for the utilization of parenchymal volumetric data, providing volumetric measurements of brain structures and comparing these volumes to a normative database adjusted for age, sex, and intracranial volume. Per the manufacturer, NeuroQuant’s normative database is founded on a population-based set which collected data from several thousand subjects from 3 to 100 years of age with an equivalence of gender.<sup>[19]</sup> Regions of parenchymal volume loss > 1.65 SDs from normal controls in the standardized atlas were flagged as abnormal. Quantitative percentiles were assigned to lobar and sublobar areas to quantify the extent of decreased parenchymal volume loss.

Further postprocessing of PET images was performed utilizing MIMneuro version 6.9.5 (MIM Software, Inc., Cleveland, Ohio). MIMneuro software runs a region-based analysis that calculates z-scores (number of SDs from the mean) and asymmetry measurements for individual brain regions defined by the Single Brain Atlas and MIM Probabilistic anatomical atlas to provide semi-quantitative analysis of brain hypometabolism. Per the manufacturer, the Single Brain Atlas and MIM Probabilistic anatomical atlas are composed of 43 individuals (19 females and 24 males), ages 41–80 years. The breakdown into age ranges are as follows: six subjects ages 40–49, eight subjects ages 50–59, 14 subjects ages 60–69, 14 subjects ages 70–79, and one subject with age between 80 and 89. The mean age and SD of these 43 individuals are 63.8 ± 9.98 years. The automated z-scores are calculated by comparing the patient to the selected age-matched set of normal controls. Both NeuroQuant and MIMneuro software age-match the standard atlas within 5 years of the patient’s age. Please note, both software only provide semi-quantitative data regarding the aforementioned variables and do not offer a dementia diagnosis.

**Table 1: Common clinical symptoms reported by dementia subtype**

Dementia subtype	Most common clinical symptoms (>50% of patients)
Alzheimer’s dementia	Progressive memory loss >1 year in duration Word finding difficulties Difficulties with activities of daily living
Frontotemporal lobar degeneration	Word finding difficulties Behavioral changes Memory loss
Dementia with Lewy bodies	Gait disturbance Tremor Visual hallucinations Memory loss
Corticobasal degeneration	Tremor Unilateral weakness Gait disturbance Apraxia

### Image interpretation

Two fellowship-trained neuroradiologists, one with dedicated PET/MRI training and 6 years research experience in the field, assessed scans first qualitatively and then in conjunction with NeuroQuant and MIMneuro z-score data. Each neuroradiologist reader interpreted the images independently, followed by adjudication with a board-certified nuclear medicine physician with 25 years of experience in brain PET imaging. The imaging diagnosis was then discussed with the referring clinician to correlate with the patient's symptoms and neuropsychological testing.

### Statistical analysis

NeuroQuant quantitative volumetric percentiles and MIMneuro software brain hypometabolism z-scores were correlated using Pearson's correlation coefficient ( $r$ ) in a lobar specific pattern for each subtype of dementia (Alzheimer's dementia, frontotemporal lobar dementia, dementia with Lewy bodies and CBD). All statistical tests were conducted with a two-tailed  $t$ -test with a  $P < 0.05$  significance level. In addition, ratio of z-score to volume percentile (M/V index) was calculated as a way to further compare regions by providing assessment of metabolic activity within respective corresponding regions of volume loss.

## RESULTS

The distribution of the dementia subtypes within the 89 individuals was as follows: 29 with Alzheimer's dementia, 34 with frontotemporal lobar degeneration, 14 with dementia with Lewy bodies, and 12 with CBD. Of the 34 patients with FTL, subtypes were as follows: 16 patients with behavioral variant (bvFTL), 10 with semantic dementia, 4 with logopenic variant primary progressive aphasia, 2 with the agrammatic variant primary progressive aphasia, and 2 with the PSP.

The average patient age was 71.3 (SD = 7.7), and the majority (54.1%) were female. Mean z-scores were generally negative across all corresponding ROIs in this study [results detailed in Table 2]. Associations between z-scores and volumetric percentiles were moderate in strength across all patients, specifically in the parietal lobe, temporal pole, and occipital lobe and weak in the frontal and temporal lobes. These findings were significant in the frontal lobe, parietal lobe, temporal pole, occipital lobe, and temporal lobe ( $P < 0.05$ ). The ratio of the mean z-score to mean volumetric percentile (M/V index) was determined and provided in Tables 3 and 4 for the various neurodegenerative disorders, respectively.

### Alzheimer's dementia

Twenty-nine patients (10 males, 19 females, average age 70.6 years) with suspected AD had an average parietal lobe

z-score of  $-1.76$  with a corresponding mean lobar volume in the 21<sup>st</sup> percentile. The mean z-score for the temporal lobe was  $-1.67$ , with a corresponding mean lobar volume in the 7<sup>th</sup> percentile. There was a weak positive relationship that approached statistical significance between the Z-scores and degree of volume loss for patients with suspected Alzheimer's disease in the parietal lobe,  $r = 0.3$  ( $P = 0.120$ ). A similar yet statistically significant, weakly positive relationship was noted for the temporal lobe,  $r = 0.38$  ( $P < 0.05$ ). These results are presented in Table 3 accordingly.

### Frontotemporal lobar degeneration

Thirty-four patients (19 males, 15 females, average age 72.8 years) with suspected frontotemporal lobar degeneration demonstrated a mean frontal lobe z-score of  $-1.10$  and corresponding lobar volume in the 22.8<sup>th</sup> percentile. The mean temporal lobe z-score was  $-0.59$ , with a corresponding volume in the 13.8<sup>th</sup> percentile. There was a weakly positive relationship that approached statistical significance between the z-scores and degree of volume loss for patients with suspected FTL in the frontal lobe,  $r = 0.35$  ( $P = 0.051$ ). No relationship between volume and metabolic z-score was suggested by the data for the temporal lobe,  $r = 0.02$  ( $P = 0.916$ ). These results are outlined in Table 3 accordingly.

Figure 1a-d demonstrates the cortical surface maps, NeuroQuant output, and MIMneuro z-score output images of a patient with PET/MRI findings suggestive of bvFTL. Cortical surface maps [Figure 1a] demonstrated significantly decreased uptake in the frontal lobes, most evident in the right frontal lobe. These findings were confirmed on the z-score data overlay on cortical surface maps [Figure 1b]. NeuroQuant morphometric results [Figure 1c] demonstrate a corresponding decrease in the volume of the frontal lobes, which was in the 1<sup>st</sup> percentile when compared to age-matched controls. MIMneuro software z-score tabular output [Figure 1d] for this patient with FTL further confirmed decreased metabolism with diffusely decreased z-scores in the frontal lobes (total frontal lobe z-score =  $-4.98$ ).

Figure 2a-d is an example of a patient with PET/MRI findings consistent with semantic dementia (semantic variant, primary progressive aphasia) subtype of FTL. Fusion FDG-PET and FLAIR axial images [Figure 2a] provide insight into the anatomy and distribution of hypometabolism with striking decreased tracer uptake and corresponding volume loss in the left temporal lobe. Corresponding z-score overlay data [Figure 2b] confirm these findings and shows markedly decreased metabolism, particularly in the left temporal pole. NeuroQuant morphometric analysis [Figure 2c] and MIMneuro



**Table 2: Descriptive characteristics for shared MIMneuro and NeuroQuant regions of interest across all patients included in this study**

Region	Mean ± SD					Association	
	Overall sample (Z-score)	FTLD	AD	DLB	CBD	ρ	P
Amygdala	-0.51 ± 1.26	-0.67 ± 1.27	-0.66 ± 1.57	-0.28 ± 1.06	0.00 ± 0.00	0.11	0.417
Frontal lobe	-0.77 ± 1.58	-1.10 ± 1.67	-0.38 ± 1.06	-0.84 ± 2.43	-0.60 ± 0.84	0.26	<0.05
Occipital lobe	-0.75 ± 1.38	-0.06 ± 0.34	-0.59 ± 1.40	-2.89 ± 1.26	0.85 ± -2.3	0.30	<0.05
Parietal lobe	-1.24 ± 1.71	-0.14 ± 0.50	-1.83 ± 2.10	-2.16 ± 1.60	1.60 ± -5.9	0.47	<0.05
Temporal lobe	-0.80 ± 1.36	-0.60 ± 1.26	-1.15 ± 1.72	-0.88 ± 1.07	0.99 ± -3.0	0.24	<0.05
Temporal pole	-0.76 ± 1.64	-1.33 ± 1.89	-0.43 ± 1.16	-0.64 ± 2.07	0.00 ± 0.00	0.33	<0.05

FTLD: Frontotemporal lobar degeneration; AD: Alzheimer’s dementia; DLB: Dementia with Lewy bodies; CBD: Corticobasal degeneration; SD: Standard deviation

**Table 3: Alzheimer’s dementia and frontotemporal lobar degeneration: Average z-scores, lobar volumetric percentiles, and degree of correlation**

	Mean z-score	Mean volume (percentile)	Pearson correlation coefficient (r)	P	Metabolism to volume loss index (mean Z-score/volumetric percentile)
AD			n=29, 10 male and 19 female (average age 70.6)		
Parietal lobe	-1.76	21	0.30	0.12	-8.4
Temporal lobe	-1.67	7	0.38	<0.05	-23.8
FTLD			n=34, 19 male and 15 female (average age 72.8)		
Frontal lobe	-1.10	22.8	0.35	0.05	-4.82
Temporal lobe	-0.6	13.8	-0.09	0.92	-4.34

AD: Alzheimer’s dementia; FTLD: Frontotemporal lobar degeneration

**Table 4: Dementia with Lewy bodies and corticobasal degeneration: Average z-scores, lobar volumetric percentiles, and degree of correlation**

	Z-score	Mean volume (percentile)	Pearson correlation coefficient (r)	P	Metabolism to volume loss index (mean Z-score/volumetric percentile)
DLB			n=14, 7 male and 7 female, average age 66.7		
Occipital lobe	-2.88	16	0.42	0.13	-18
Middle occipital gyrus	-4.23	44	0.50	0.07	-9.6
Parietal lobe	-2.15	17	0.22	0.45	-12.6
CBD			n=12, 3 male and 9 female, average age 74.3		
Superior parietal lobule	-1.65	16	0.58	<0.05	-10.3

DLB: Dementia with Lewy bodies; CBD: Corticobasal degeneration

z-score tabular data [Figure 2d] demonstrated concordance of decreased grey matter volume (1<sup>st</sup> percentile) and hypometabolism (z-score = -3.13) in the left temporal pole.

**Dementia with Lewy bodies**

Fourteen patients (7 males, 7 females, average age 66.7 years) with suspected DLB demonstrated an average occipital lobe z-score of -2.88 and corresponding mean lobar volume in the 16<sup>th</sup> percentile. Mean middle occipital gyrus z-score was -4.23, which corresponded to a sublobar volume in the 44<sup>th</sup> percentile. Mean z-scores of the parietal lobes were -2.15 with corresponding mean lobar volumes in the 17<sup>th</sup> percentile. A moderate positive trend that approached statistical significance was seen in the occipital lobe and middle occipital gyrus *r* = 0.42 (*P* = 0.130) and 0.5 (*P* = 0.067), respectively. The parietal lobe demonstrated a weakly positive, however not statistically significant, relationship between the metabolic z-score and lobar volume with *r* = 0.22 (*P* = 0.447). These results are outlined in Table 4.

**Corticobasal degeneration**

Twelve patients (3 males, 9 females, average age 74.3 years) with clinical history and FDG uptake pattern suggestive of underlying CBD including unilateral hemispheric hypometabolism with decreased FDG uptake including in the primary sensorimotor cortex and ipsilateral basal ganglia and thalami, demonstrated an average superior parietal lobule z-score of -1.65 and corresponding mean volume in the 16<sup>th</sup> percentile. A moderately positive relationship between these findings was seen in the superior parietal lobule *r* = 0.58. This relationship was found to be statistically significant (*P* < 0.05). These results are outlined in Table 4.

**DISCUSSION**

Neurodegenerative disorders encompass a broad range of diseases initially presenting with mild cognitive impairment, which, oftentimes, then directs the neurologist to pursue further neuroimaging workup following cognitive screening

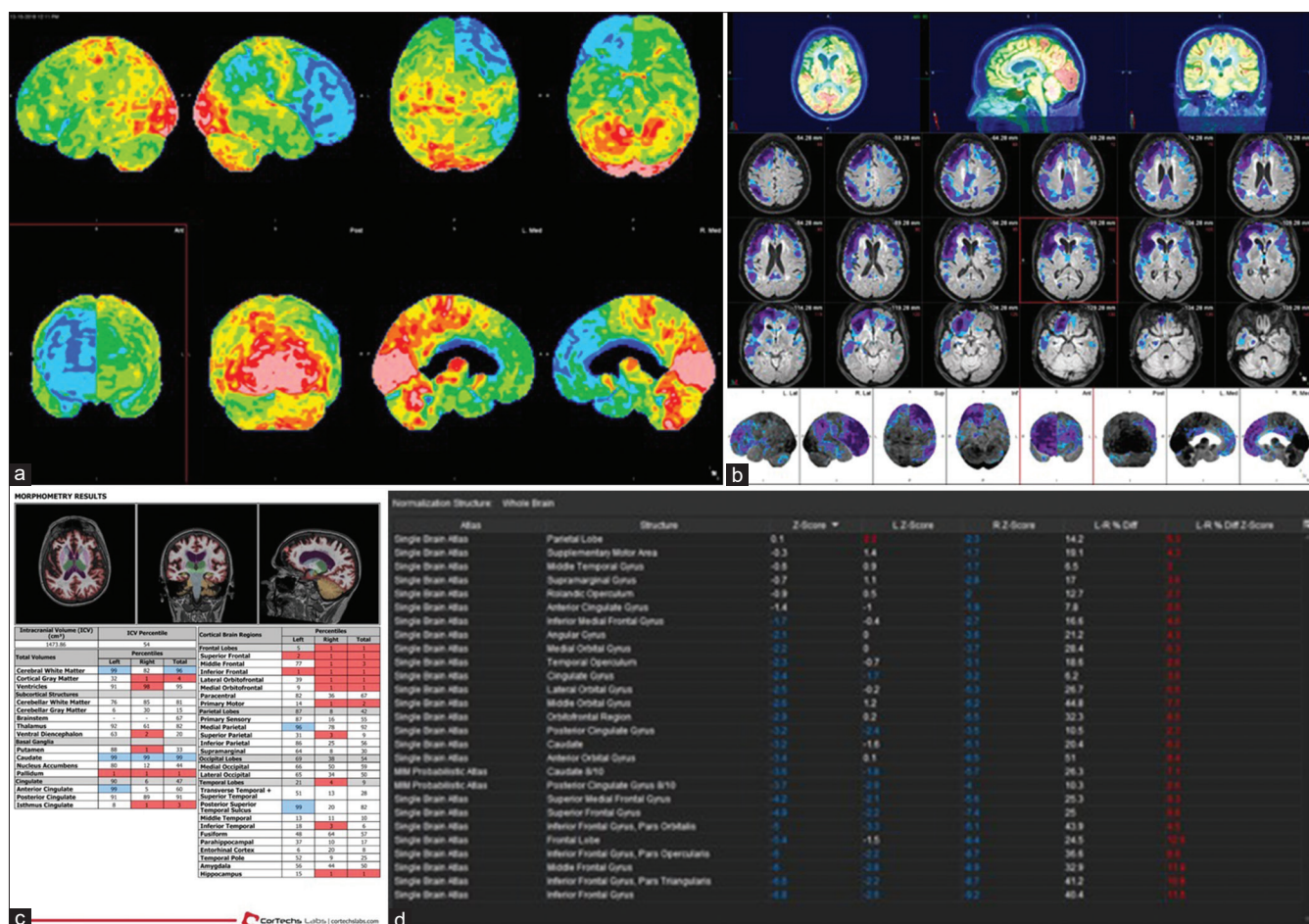


Figure 1: (a) 71-year-old female with behavioral variant frontotemporal lobar degeneration: cortical surface maps. (b) 71-year-old female with behavioral variant frontotemporal lobar degeneration: z-score overlay on cortical surface maps. (c) 71-year-old female with behavioral variant frontotemporal lobar degeneration: NeuroQuant morphometric results. (d) 71-year-old female with behavioral variant frontotemporal lobar degeneration: MIMneuro z-score output

tests such as the Montreal Cognitive Assessment or the Mini-Mental State Exam.

Neuroradiologists are then charged with the responsibility of determining the presence, and subtype, of the underlying neurodegenerative condition. Since there is relatively little guidance about the utility of semi-quantitation reported by different software programs commonly utilized in clinical practice such as NeuroQuant and MIMneuro software, we assessed the feasibility of an approach relying on these semi-quantitative tools with a focus on the strength of expected positive correlation between lobar-specific patterns of hypometabolism on metabolic imaging and volumetric patterns of cortical volume loss on structural MRI brain scans. When compared among all dementia subtypes, we found a statistically significant, positive relationship between grey matter volume loss and corresponding regional hypometabolism, as summarized in Table 2. Within the various subtypes of dementia, however, there was some variability in the strength of this relationship.

For our subset of patients with clinical and imaging findings consistent with underlying AD, the parietal and temporal lobe semi-quantitative data demonstrated a positive correlation between the degree of hypometabolism and volume loss in the parietal lobes, including the precuneus and posterior cingulate gyrus. These findings were statistically significant for the temporal lobe and approached statistical significance in the parietal lobe. In addition, the average z-score data and cortical volume percentiles, when assessed independently of each other, were consistent with prototypical findings seen in AD patients. The calculated M/V index for the temporal and parietal lobe in this subset of AD patients demonstrated a larger, more negative value in the temporal lobe compared to the parietal lobe indicating that the remaining neurons in the temporal lobe exhibited higher amounts of volume loss per degree of hypometabolism. This is as opposed to the parietal lobe, which, albeit, still demonstrated some correlation, although not approaching statistical significance.



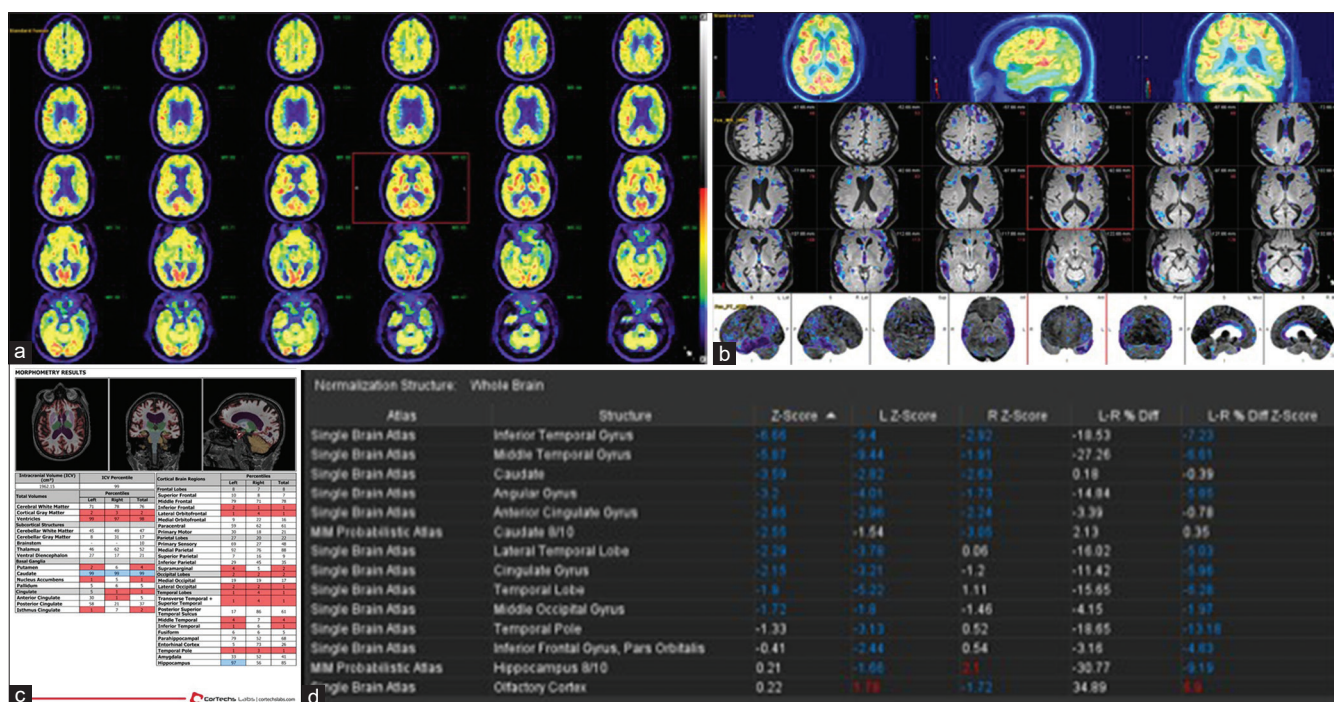


Figure 2: (a) 82-year-old male with semantic PPA: fusion fluorodeoxyglucose positron emission tomography and fluid-attenuated inversion recovery magnetic resonance imaging axials. (b) 82-year-old male with semantic PPA: z-score overlay on cortical surface maps. (c) 82-year-old male with semantic PPA: NeuroQuant morphometric analysis. (d) 82-year-old male with semantic PPA: MIMneuro software z-score output

Furthermore, positive relationship between semi-quantitative data for cortical volume loss and corresponding hypometabolism was elucidated in the frontal lobes in our patients with suspected FTLT, which nearly reached statistical significance. This finding is important as it suggests this correlation may be used to strengthen a radiologist’s confidence in the diagnosis of FTLT in patients displaying frontal lobe hypometabolism and volume loss. Interestingly, no relationship between the two variables was seen in the temporal lobe of patients with FTLT, which may be explained by a predominance of bvFTLT cases in our dataset as compared to the primary progressive aphasia subtypes including semantic dementia and logopenic PPA of which there were 10 and 4 cases, respectively. Of note, the M/V index for both the frontal and temporal lobe demonstrated nearly identical values of  $-4.82$  versus  $-4.34$ , respectively, which likely represent similar degrees of hypometabolism per unit of volume loss in the frontal and temporal lobes of FTLT patients in our dataset.

In our DLB cohort, we noted moderately positive relationship for semi-quantitative data assessing hypometabolism and volume loss, specifically in the occipital lobes including the middle occipital gyrus which is characteristic for DLB as previously shown by Higuchi *et al.*<sup>[16]</sup> In this instance the middle occipital gyrus, which is part of the occipital lobe had a higher volume percentile compared to the occipital lobe (44 vs. 16). This is due to the nature of the NeuroQuant software’s semi-quantitative analysis providing an average

percentile for the entire occipital lobe. This includes the middle occipital gyrus but also other regions which were likely more disproportionately affected with volume loss thus decreasing the overall average of the occipital lobe to the 16<sup>th</sup> percentile in our study. In addition, a weakly positive relationship was seen for the parietal lobes including in the precuneus and posterior cingulate (although to a lesser degree than with AD cases), regions also typically affected in DLB. However, the latter relationships did not reach statistical significance, likely due to the size of our study sample and variable disease severity. The M/V index for DLB demonstrated increased values in the occipital and parietal lobes compared to the middle occipital gyrus, which again may represent higher rates of hypometabolism per region of volume loss in these regions.

In our CBD cohort, in addition to the characteristic FDG uptake pattern with markedly hypometabolic single hemisphere including the ipsilateral thalami and basal ganglia and importantly involving the primary sensorimotor cortex, a statistically significant, moderately positive, relationship on semi-quantitative analysis was observed in the ipsilateral superior parietal lobule which is a region thought to be typically involved in CBD according to a study by Grijalvo-Perez and Litvan.<sup>[18]</sup> This again resonates with our earlier statements that radiologists may have increased clinical confidence in their diagnosis of underlying CBD when evaluating a patient with suggestive hypometabolism

and volume loss patterns upon semi-quantitative review of images, particularly focusing on the superior parietal lobule, along with history and symptoms supportive of underlying CBD. In addition, the M/V index for the superior parietal lobule was more negative than regions seen in the other disorders (e.g., frontal/temporal lobe in FTLD). This also likely corresponds to increasing degrees of hypometabolism per unit of volume loss, similar to lobar-specific regions typical for previously mentioned disorders.

Of note, there are several limitations inherent to our study. First, the retrospective nature of the research and selection of cases, which were dependent on our referring clinicians, may skew the cohort composition. The sample size and heterogeneity of the patient groups are a limiting factor, as described above, within each disorder and may have contributed to the lack of statistically significant metabolic and volumetric correlation in some lobar-specific regions including in the parietal lobe in AD, temporal lobe in FTLD and parietal lobe in DLB; regions shown to be affected in prior studies.<sup>[4,5,13,17,18]</sup>

Furthermore, the volumetric analysis and the calculated hypometabolism *z*-scores, as provided by NeuroQuant and MIMneuro software, respectively, are both semi-quantitative tools and as such are meant to be representative of hypometabolism and brain volume loss patterns and are not quantitative data. Therefore, although the *z*-score can potentially be strikingly low, cortical volume loss cannot decrease below the 1<sup>st</sup> percentile. This limited our ability to draw relationships for patients with the most severe disease as they would appear to have the same degree of volume loss as subjects with less severe hypometabolism. As part of our data analyses, we also noted regions with hypometabolism without significant brain volume loss, which may reflect decreases in neuronal activity or other effects such as diaschisis. Alternatively, in cases where there was volume loss with maintained levels of metabolism, findings may reflect a compensatory increased activity of residual neurons due to the surrounding neurodegenerative process. These observations warrant further delineation by carefully planned longitudinal clinical studies.

## CONCLUSION

Semi-quantitative <sup>18</sup>F-FDG PET/MRI analysis demonstrated a positive relationship between structural volume loss and hypometabolism within certain lobar-specific regions, depending on neurodegenerative disorder subtype. We believe our findings add new information to the limited existing literature specifically regarding the clinical utility of

hybrid brain PET/MRI in patients presenting with cognitive impairment due to suspected neurodegeneration. With the use of computer assisted semi-quantitative tools such as NeuroQuant morphometric analysis and MIMneuro software hypometabolism *z*-scores; neuroradiologists, nuclear medicine physicians, and clinicians interpreting these images can gain increased confidence in their diagnoses and provide more accurate and precise information in the assessment of patients with cognitive impairment due to underlying dementia and related neurodegenerative disorders.

## Declaration of patient consent

The authors certify that they have obtained all appropriate patient consent forms. In the form the patient(s) has/have given his/her/their consent for his/her/their images and other clinical information to be reported in the journal. The patients understand that their names and initials will not be published and due efforts will be made to conceal their identity, but anonymity cannot be guaranteed.

## Financial support and sponsorship

Nil.

## Conflicts of interest

There are no conflicts of interest.

## REFERENCES

1. Franceschi AM, Abballe V, Raad RA, Nelson A, Jackson K, Babb J, *et al.* Visual detection of regional brain hypometabolism in cognitively impaired patients is independent of positron emission tomography-magnetic resonance attenuation correction method. *World J Nucl Med* 2018;17:188-94.
2. Franceschi AM, Matthews R, Bangiyev L, Relan N, Chaudhry A, Franceschi D. Added value of including entire brain on body imaging with FDG PET/MRI. *Am J Roentgenol* 2018;211:176-84.
3. Ehman EC, Johnson GB, Villanueva-Meyer JE, Cha S, Leynes AP, Larson PE, *et al.* PET/MRI: Where might it replace PET/CT? *J Magn Reson Imaging* 2017;46:1247-62.
4. Gallucci M, Limbucci N, Catalucci A, Caulo M. Neurodegenerative diseases. *Radiol Clin North Am* 2008;46:799-817, vii.
5. Herholz K, Carter SF, Jones M. Positron emission tomography imaging in dementia. *Br J Radiol* 2007;80:S160-7.
6. Togasaki DM, Tanner CM. Epidemiologic aspects. *Adv Neurol* 2000;82:53-9.
7. Arlt S, Brassens S, Jahn H, Wilke F, Eichenlaub M, Apostolova I, *et al.* Association between FDG uptake, CSF biomarkers and cognitive performance in patients with probable Alzheimer's disease. *Eur J Nucl Med Mol Imaging* 2009;36:1090-100.
8. Brown RK, Bohnen NI, Wong KK, Minoshima S, Frey KA. Brain PET in suspected dementia: Patterns of altered FDG metabolism. *Radiographics* 2014;34:684-701.
9. Choo IH, Lee DY, Youn JC, Jhoo JH, Kim KW, Lee DS, *et al.* Topographic patterns of brain functional impairment progression according to clinical severity staging in 116 Alzheimer disease patients: FDG-PET study. *Alzheimer Dis Assoc Disord* 2007;21:77-84.
10. Del Sole A, Clerici F, Chiti A, Lecchi M, Mariani C, Maggiore L, *et al.* Individual cerebral metabolic deficits in Alzheimer's disease and



- amnesic mild cognitive impairment: An FDG PET study. *Eur J Nucl Med Mol Imaging* 2008;35:1357.
11. Jagust W, Reed B, Mungas D, Ellis W, Decarli C. What does fluorodeoxyglucose PET imaging add to a clinical diagnosis of dementia? *Neurology* 2007;69:871-7.
  12. Diehl-Schmid J, Grimmer T, Drzezga A, Bornschein S, Riemenschneider M, Förstl H, *et al.* Decline of cerebral glucose metabolism in frontotemporal dementia: A longitudinal 18F-FDG-PET-study. *Neurobiol Aging* 2007;28:42-50.
  13. Jeong Y, Cho SS, Park JM, Kang SJ, Lee JS, Kang E, *et al.* 18F-FDG PET findings in frontotemporal dementia: An SPM analysis of 29 patients. *J Nucl Med* 2005;46:233-9.
  14. Kanda T, Ishii K, Uemura T, Miyamoto N, Yoshikawa T, Kono AK, *et al.* Comparison of grey matter and metabolic reductions in frontotemporal dementia using FDG-PET and voxel-based morphometric MR studies. *Eur J Nucl Med Mol Imaging* 2008;35:2227-34.
  15. Colloby S, John O. Functional imaging in Parkinson's disease and dementia with Lewy bodies. *J Geriatr Psychiatry Neurol* 2004;17:158-63.
  16. Higuchi M, Tashiro M, Arai H, Okamura N, Hara S, Higuchi S, *et al.* Glucose hypometabolism and neuropathological correlates in brains of dementia with Lewy bodies. *Exp Neurol* 2000;162:247-56.
  17. Imamura T, Ishii K, Hirono N, Hashimoto M, Tanimukai S, Kazui H, *et al.* Occipital glucose metabolism in dementia with Lewy bodies with and without Parkinsonism: A study using positron emission tomography. *Dement Geriatr Cogn Disord* 2001;12:194-7.
  18. Grijalvo-Perez AM, Litvan I. Corticobasal degeneration. *Semin Neurol* 2014;34:160-73.
  19. Luo W, Airriess C, Albright J. The neuroquant normative database: Comparing individual brain structures. *CorTechs Labs* 2015.