

# Acute Obstructive Suppurative Pancreatic Ductitis

Theodore Tollivoro, MD<sup>1</sup>, Sandeep Palakodeti, MD, MPH<sup>2</sup>, and Craig Munroe, MD<sup>1</sup>

<sup>1</sup>Kaiser Permanente Medical Center, San Francisco, CA

<sup>2</sup>Mayo Clinic, Rochester, MN

## ABSTRACT

Acute obstructive suppurative pancreatic ductitis (AOSPD) is a rare clinical entity defined as suppuration from the pancreatic duct without concomitant pancreatic cyst, abscess, or necrosis. We describe a case of AOSPD in a woman with a past medical history of type 2 diabetes and chronic pancreatitis who presented with abdominal sepsis, which resolved only after therapeutic endoscopic retrograde cholangiopancreatography. Our case highlights the importance of considering AOSPD as a cause of abdominal sepsis particularly in patients with chronic pancreatitis or any recent pancreatic duct instrumentation and demonstrates that treatment requires prompt drainage and decompression of the pancreatic duct.

## INTRODUCTION

While acute cholangitis secondary to obstruction of the biliary tree is a well-known condition, suppuration of the pancreatic duct without evidence of necrotic pancreatic tissue, abscess, or pseudocyst is rare.<sup>1-3</sup> Typically, patients present with abdominal sepsis and elevated inflammatory markers; however, asymptomatic cases have been reported.<sup>1,4</sup> Acute obstructive suppurative pancreatic ductitis (AOSPD) is a rare condition defined as suppuration of the pancreatic duct without concomitant pancreatic cyst, abscess, or necrosis.<sup>1</sup>

## CASE REPORT

A 56-year-old woman presented to the emergency department with abdominal pain, nausea, and vomiting. Her medical history was significant for type 2 diabetes and chronic pancreatitis of unclear etiology, possibly hereditary given a history of pancreatic cancer on her maternal side. She did not have a history significant for alcoholism and never smoked. The patient had undergone endoscopic retrograde cholangiopancreatography (ERCP) with placement and subsequent removal of a stent for strictures within her main pancreatic duct 3.5 years prior to presentation. Upon presentation, she was febrile and tachycardic with labs significant for a white blood cell count of 10.9 k/ $\mu$ L with 90% neutrophils and liver function tests notable for a mildly elevated alkaline phosphatase of 141 U/L. Her total bilirubin was 0.4 mg/dL, and her lipase was <3 U/L. Abdominal computed tomography demonstrated severe dilation of the pancreatic duct with intraductal calcifications measuring up to 1 cm and multiple calcifications of the pancreatic parenchyma (Figure 1). Pancreatic fat stranding suggested acute on chronic pancreatitis. The common bile duct was normal. She was started on intravenous piperacillin-tazobactam.

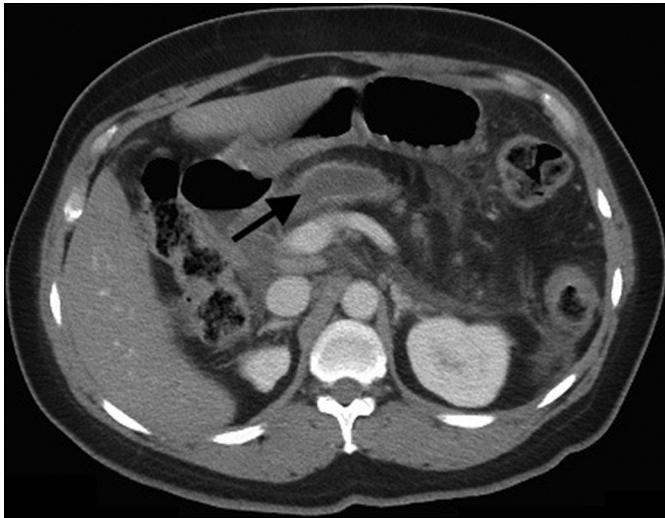Due to the severe pancreatic duct dilatation, the patient underwent ERCP, which demonstrated a fistula that was draining pus and extended from the main pancreatic duct to an opening above the ampulla of Vater (Figure 2). A pancreatogram revealed stones in the pancreatic duct and a stricture to 2 mm in the distal head of the pancreas with dilatation to 9 mm upstream of the stricture. The pancreatic duct was deeply cannulated, and prompt drainage of pus was noted upon placement of a 5 Fr x 7 cm plastic straight stent (Figure 3). The finding of pus emanating from the main pancreatic duct was consistent with AOSPD. No culture data were obtained from the pancreatic juices, and the patient's blood cultures remained sterile at 5 days.

ACG Case Rep J 2016;3(4):e136. doi:10.14309/crj.2016.109. Published online: September 28, 2016.

Correspondence: Theodore Tollivoro, MD, 2425 Geary Blvd, M160, San Francisco, CA 94115 (Theodore.A.Tollivoro@kp.org).



Copyright: © 2016 Tollivoro et al. This work is licensed under a Creative Commons Attribution-NonCommercial-NoDerivatives 4.0 International License. To view a copy of this license, visit <http://creativecommons.org/licenses/by-nc-nd/4.0>.

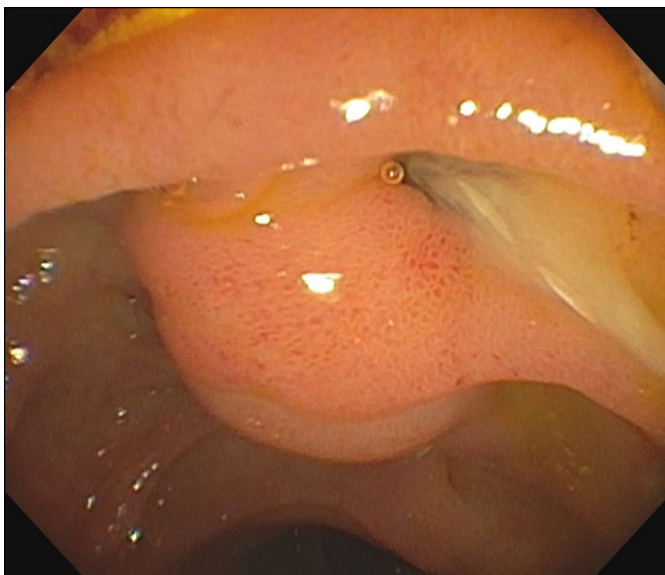


**Figure 1.** Computed tomography demonstrating severe dilation of the pancreatic duct.

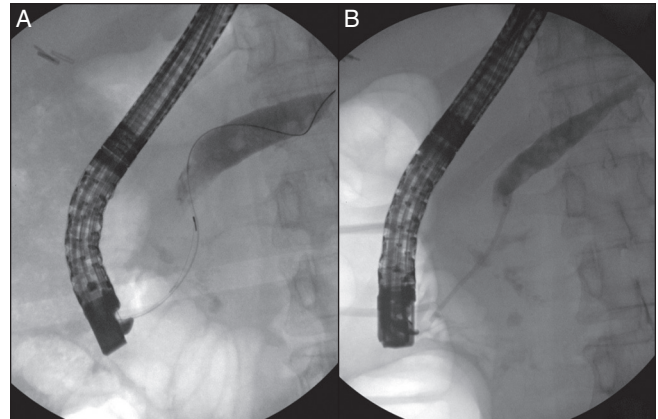
The patient's sepsis resolved, and she was discharged with 10 days of oral antibiotics. In total, she received 22 days of antibiotics. She underwent a repeat ERCP 30 days later, during which the indwelling stent was removed and 2 straight plastic stents (7 Fr x 8 cm and 5 Fr x 8 cm) were placed adjacent to one another.

## DISCUSSION

Acute obstructive suppurative pancreatic ductitis is associated with chronic pancreatitis, diabetes, and prior pancreatic procedures.<sup>1,5,6</sup> It is hypothesized that chronic pancreatitis predisposes to AOSPD because chronic inflammation impairs



**Figure 2.** Pus emanating from an opening superior to the ampulla of Vater.



**Figure 3.** (A) Deep cannulation of the pancreatic duct, several stones are visible within the duct. (B) Placement of stent into the main pancreatic duct.

the secretion of antibacterial substances that are normally secreted from a healthy pancreas.<sup>3</sup> Furthermore, the immunosuppressed state of a diabetic is thought to place patients at risk for bacterial infections, and prior pancreatic procedures are thought to introduce duodenal contents into the pancreatic duct.<sup>1,3,6</sup>

A recent case series from Japan of 20 patients with AOSPD sought to delineate the clinical features of AOSPD. Similar to our case, 17 of 20 patients presenting with AOSPD had a history significant for chronic pancreatitis. Of the 20 patients, 10 had a prior pancreatic procedure within 1 month of presentation. In the Japanese study, 19 of 20 patients underwent ERCP with successful drainage and stenting of their pancreatic ducts, resulting in resolution of the AOSPD. This underscores that drainage of the pancreatic duct is the cornerstone of therapy for AOSPD. Of note, the Japanese case series study population was predominantly male (e.g., 19 of 20 patients), whereas our case presented in a female.<sup>6</sup>

AOSPD is a rare condition that only resolves after drainage and decompression of the pancreatic duct via ERCP. AOSPD must be considered in the differential diagnosis for abdominal sepsis, particularly in patients with a history of chronic pancreatitis or any recent pancreatic duct instrumentation.

## DISCLOSURES

Author contributions: T. Tollivoro and S. Palakodeti wrote the manuscript. C. Munroe critically revised the manuscript for important intellectual contact. T. Tollivoro is the article guarantor.

Financial disclosures: None to report.

Informed consent was obtained for this case report.

Received December 19, 2015; Accepted April 15, 2016

## REFERENCES

1. Wali E, Koo P, Packer CD. Acute obstructive suppurative pancreatic ductitis in an asymptomatic patient. *Case Rep Med*. 2015;2015:919452.
2. Fujimori N, Igarashi H, Ito T. Acute obstructive suppurative pancreatic ductitis. *Clin Gastroenterol Hepatol*. 2011;9(8):A28.
3. Deeb LS, Bajaj J, Bhargava S, et al. Acute suppuration of the pancreatic duct in a patient with tropical pancreatitis. *Case Rep Gastroenterol*. 2008;2(1):27-32.
4. Fujinaga T, Nishida T, Miyazaki M, et al. Acute suppurative pancreatic ductitis associated with pancreatic duct obstruction. *Endoscopy*. 2013;45(S 02):E135.
5. Weinman DS. Acute suppuration of the pancreatic duct. *Gastrointest Endosc*. 1995;41(3):268-70.
6. Kondo H, Naitoh I, Okumura F, et al. Clinical features of acute obstructive suppurative pancreatic ductitis: A retrospective review of 20 cases. *J Gastroenterol Hepatol*. 2016;31(7):1366-73.