



Complementary role of EUS, EndoFLIP, and manometry for management of type III achalasia with peroral endoscopic myotomy in a patient with compensated cirrhosis and no varices

M. Phillip Fejleh, MD, Rena Yadlapati, MD, Michel H. Mendler, MD, Rohit Loomba, MD, Wilson T. Kwong, MD, Syed M. Abbas Fehmi, MD

A 52-year-old woman with alcoholic cirrhosis was evaluated for dysphagia and found to have type III achalasia. Her cirrhosis was complicated by portal hypertension in the form of ascites and hepatic encephalopathy. Because of her decompensated cirrhosis, she was initially treated with balloon dilations, with minimal to no durable improvement in dysphagia. However, several months after cessation of alcohol use, her ascites and encephalopathy resolved, and she no longer required paracenteses and lactulose. She desired definitive treatment of her achalasia.

Cirrhosis with portal hypertension is considered a contraindication to peroral endoscopic myotomy (POEM).¹ However, after discussing the case in a multidisciplinary motility conference, the options of POEM or a robotic Heller myotomy with combined thoracic and abdominal

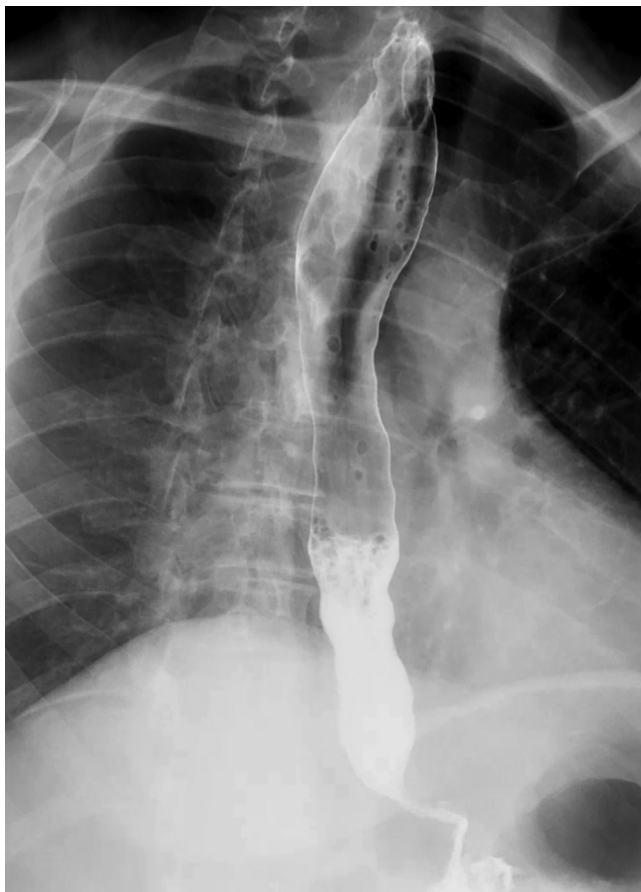

Figure 1. Barium esophagram before peroral endoscopic myotomy, with mild esophageal dilation, tertiary contractions, and poor transit of contrast through the esophagogastric junction, which had a bird beak appearance.

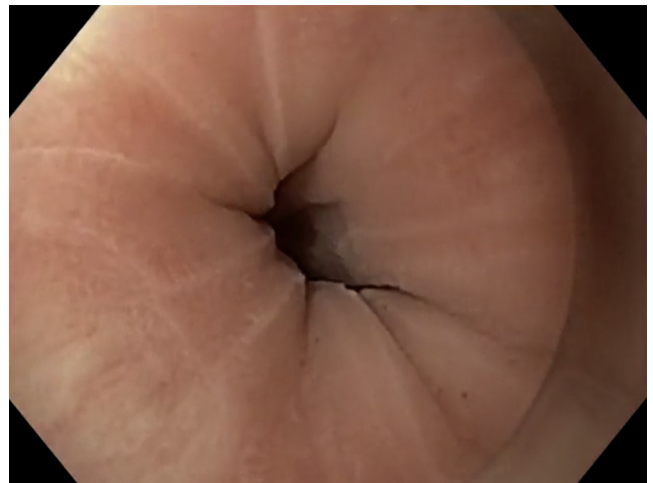

Figure 2. Image of the tight lower esophageal sphincter before peroral endoscopic myotomy.

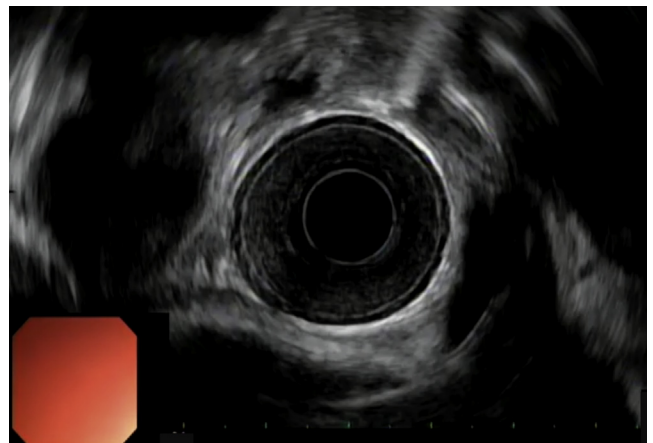


Figure 3. EUS of the esophageal wall layers, demonstrating thickening of the circular muscle.

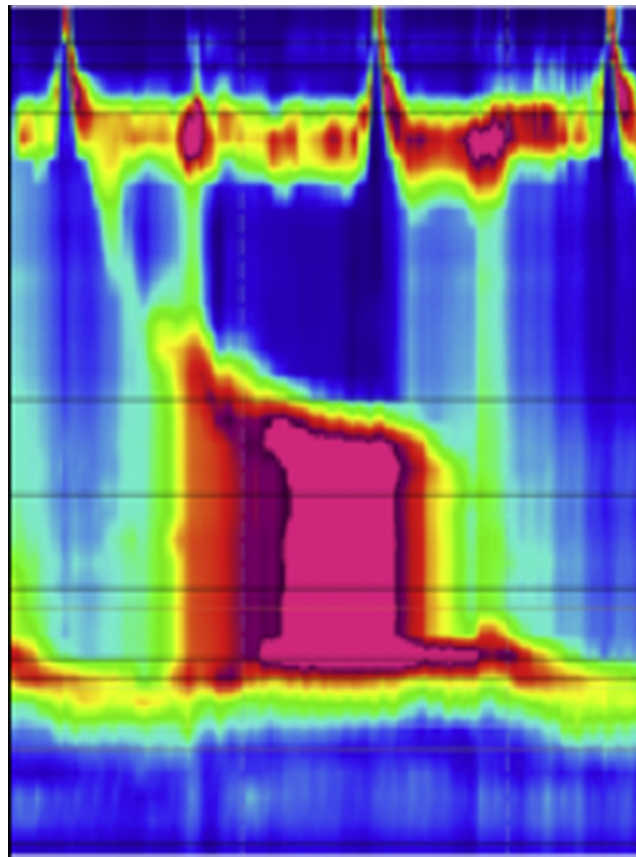


Figure 4. Esophageal manometry showed type III achalasia. The median lower esophageal sphincter integrated relaxation pressure was elevated at 45.7 mm Hg, and 100% of peristalsis failed with embedded spasm in 100% of swallows.

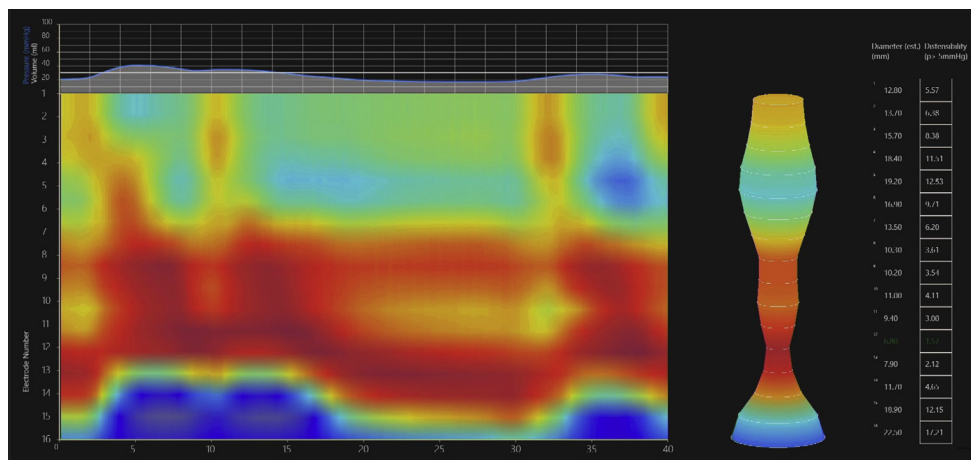


Figure 5. Endoluminal functional lumen imaging probe showed a reduced distensibility index of 0.9 mm²/mm Hg at the esophagogastric junction, a maximal esophagogastric junction diameter of 6.7 mm, spastic occlusive contractile response to distension suggestive of an outflow obstructive physiology across the esophagogastric junction, and a spastic response in the esophageal body.

approach were offered to the patient. She elected to undergo POEM because it is a less invasive procedure offering the opportunity for a long myotomy (Video 1, available online at www.giejournal.org).

Laboratory evaluation showed a platelet count of 100,000 per microliter and an international normalized

ratio of 1.1. A CT scan was notable for paraesophageal varices and perigastric collaterals in the abdomen. A barium esophagram revealed mild esophageal dilation, tertiary contractions, and poor transit of contrast through the esophagogastric junction (EGJ), which had a bird beak appearance (Fig. 1).

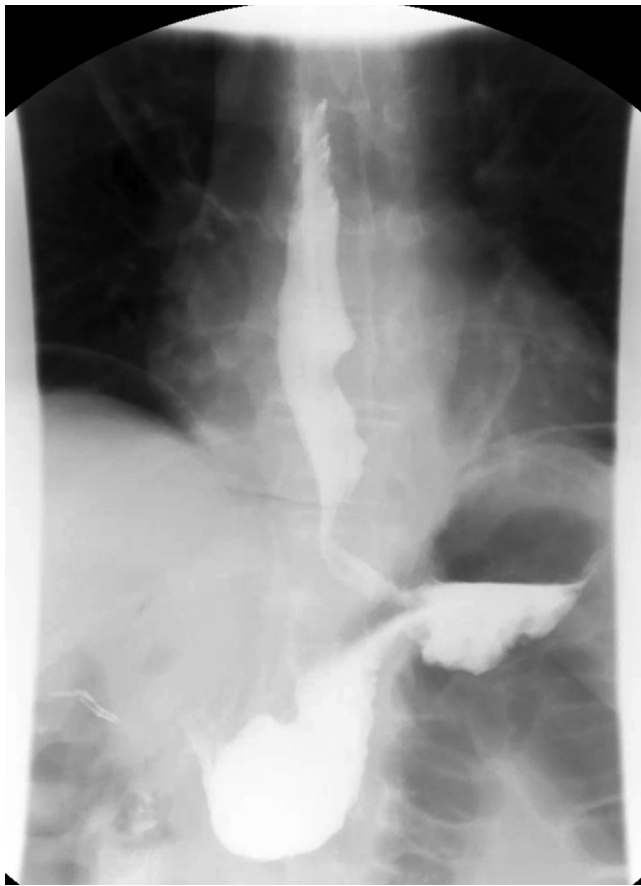

Figure 6. Barium esophagram after peroral endoscopic myotomy, with normal passage of contrast through the esophagus and into the stomach and expected mild pneumoperitoneum.

An upper endoscopy showed retained saliva in the esophagus, esophageal spasm, and a tight lower esophageal sphincter (LES; Fig. 2). There were no esophageal or gastric varices. EUS demonstrated a thickened circular layer of the esophageal wall from 25 cm to the level of the LES (Fig. 3). Circular muscle thickness was consistently more than 1.8 mm and suddenly decreased to 1 mm at 24 cm.

Esophageal manometry was consistent with type III achalasia per the Chicago Classification version 3.0; the median LES integrated residual pressure was elevated at 45.7 mm Hg, and 100% of peristalsis failed with embedded spasm in 100% of swallows (Fig. 4). The spastic segment on manometry extended 14 cm proximal to the LES, and a long myotomy was planned. Endoluminal functional lumen imaging probe (EndoFLIP) showed a reduced distensibility index (DI) at the EGJ of 0.9 mm²/mm Hg, a maximal EGJ diameter of 6.7 mm, spastic occlusive contractile response to distension suggestive of an outflow obstructive physiology across the EGJ, and a spastic response in the esophageal body, which can be seen in spastic achalasia (Fig. 5).

A submucosal injection of saline solution with indigo carmine was performed anteriorly at 23 cm from the

incisors, followed by mucosal incision with a triangle tip knife to allow entry into the submucosal tunnel. Submucosal dissection was carried out to 2 to 3 cm below the EGJ using the triangle tip knife from the point of tunnel entry to 2 to 3 cm below the EGJ. Prophylactic treatment of visualized vessels was performed as needed.

Because of a narrow working space from significant spastic esophageal contractions and the lengthy planned myotomy, a scissor type knife was then used to minimize the chance of mucosotomy and for a potentially faster and safer myotomy. The myotomy was carried out from 25 cm to beyond the EGJ at 42 cm and was directed more toward the lesser curve at the level of the EGJ and distally. This may minimize damage to sling fibers of the stomach, which are continuous with the distal esophageal circular muscle,² and may potentially decrease the risk of reflux after POEM. Before tunnel closure, EndoFLIP was performed and the DI was 5.1, indicating an adequate myotomy.

The patient was admitted for observation, and a barium esophagram revealed normal passage of contrast through the esophagus and into the stomach (Fig. 6). The patient reported resolution of her dysphagia and a weight gain of 15 pounds after the procedure. Repeat EndoFLIP demonstrated a DI of 6 at 3-month follow-up.

DISCLOSURE

Dr Yadlapati is a consultant for Medtronic, Ironwood Pharmaceuticals, and Diversatek Health; is on the advisory board for Phathom Pharmaceuticals; and has research grants from Ironwood Pharmaceuticals. Dr Febmi is a consultant for Boston Scientific and Cook. All other authors disclosed no financial relationships.

Abbreviations: DI, distensibility index; EGJ, esophagogastric junction; EndoFLIP, endoluminal functional lumen imaging probe; LES, lower esophageal sphincter; POEM, peroral endoscopic myotomy.

REFERENCES

1. Stavropoulos SN, Modayil RJ, Friedel D, et al. The International Per Oral Endoscopic Myotomy Survey (IPOEMS): a snapshot of the global POEM experience. *Surg Endosc* 2013;27:3322-38.
2. Zifan A, Kumar D, Cheng LK, et al. Three-dimensional myoarchitecture of the lower esophageal sphincter and esophageal hiatus using optical sectioning microscopy. *Sci Rep* 2017;7:13188.

University of California, San Diego, La Jolla, California.

Copyright © 2021 American Society for Gastrointestinal Endoscopy. Published by Elsevier Inc. This is an open access article under the CC BY-NC-ND license (<http://creativecommons.org/licenses/by-nc-nd/4.0/>).

<https://doi.org/10.1016/j.vgje.2020.12.010>