



## Late presentation of acromial base fracture after reverse shoulder arthroplasty: a case report

Ansab Khwaja, MD <sup>a,\*</sup>, Nathan Sherman, MD, MBA <sup>a</sup>, Andrew Knox, PA <sup>b</sup>, Andrew Mahoney, MD <sup>b</sup>

<sup>a</sup> Department of Orthopedic Surgery, University of Arizona, Tucson, AZ, USA

<sup>b</sup> Tucson Orthopaedic Institute, Tucson, AZ, USA

### ARTICLE INFO

#### Keywords:

Reverse shoulder arthroplasty  
acromion fracture  
scapula fracture

Level of evidence: Case Report

For many patients with rotator cuff arthropathy, a reverse shoulder arthroplasty is a surgical option with good results in terms of pain and function.<sup>5,6,17</sup> Acromion fractures are a recognized postoperative complication, and increased tension on the deltoid is hypothesized as a possible contributing factor.<sup>14,22</sup> Fracture classification is as outlined: Type 1 are tip of the acromion fractures; type 2 are lateral acromion fractures; and type 3 are base of acromion fractures.<sup>11</sup> The prevalence of acromial fractures after reverse shoulder arthroplasty ranges between 0.8% and 10.2%,<sup>11</sup> but base of acromion fractures are relatively rare with incidence of approximately 1% in one review of 400 patients.<sup>3</sup> Most fractures of the acromial base occur within one year of surgery secondary to minor trauma.<sup>3</sup> Although type 1 and 2 fractures may be managed nonoperatively or with a tension band technique,<sup>4,7,18</sup> the force of the deltoid on the acromion makes it challenging to manage an acromial base fracture nonoperatively.<sup>9,19</sup> Fracture location, however, may not affect long-term outcomes.<sup>20</sup> Our patient sustained her type 3 acromial base fracture in a low-energy twisting mechanism five years after index surgery, with underlying osteoporosis treated with bisphosphonate therapy considered to be a potentially contributing factor.

### Case report

The patient is a 72-year-old right-hand-dominant woman who in 2014 underwent a right reverse shoulder arthroplasty (Exactech) for

No institutional review board approval was required for this case report. Verbal and written consent were obtained from the patient in order to publish information pertaining to this case.

\* Corresponding author: Ansab Khwaja, MD, Department of Orthopedic Surgery, University of Arizona, 1501 N Campbell Ave, Tucson, AZ 85724, USA.

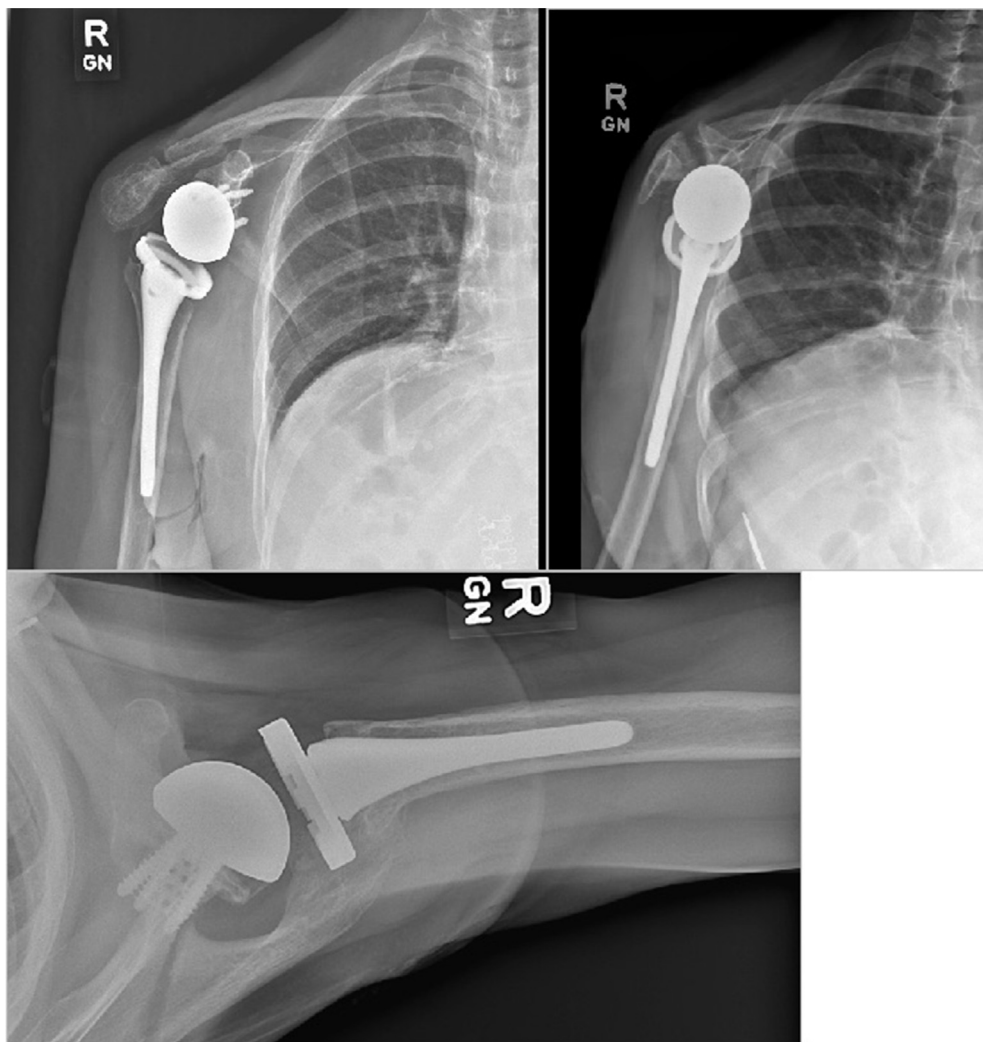
E-mail address: [akhwaja@ortho.arizona.edu](mailto:akhwaja@ortho.arizona.edu) (A. Khwaja).

<https://doi.org/10.1016/j.jseint.2020.10.024>

2666-6383/© 2021 The Authors. Published by Elsevier Inc. on behalf of American Shoulder and Elbow Surgeons. This is an open access article under the CC BY-NC-ND license (<http://creativecommons.org/licenses/by-nc-nd/4.0/>).

rotator cuff arthropathy with severe osteoarthritis and a Walch grade B2 glenoid. Past medical history was notable for coronary artery disease and osteoporosis. The patient took aspirin 81 mg daily, vitamin D, calcium, and had been on alendronate for three years at the time of her fracture. She had a bone density (DEXA) scan demonstrating a t-score of –1.1 at her femoral neck approximately three to four years after her index operation. She had been doing very well with good range of motion, strength, and pain relief. At her last recorded visit, she had flexion of 160 degrees, external rotation of 30 degrees, and full internal rotation to L2. In July 2019, she was pulling a suitcase on vacation with her right arm extended, when the suitcase hit an uneven terrain in the sidewalk causing her right arm to suddenly externally rotate. She had the immediate onset of severe pain in her posterior shoulder and an inability to raise her arm, without numbness or tingling. She presented within one week of the injury to be evaluated. AP, lateral, and axillary radiographs demonstrated a type III displaced base of acromion fracture (Fig. 1). After discussing the options, she elected to proceed with open reduction internal fixation of the displaced fragment.

The patient was placed in a lateral decubitus position. A posterior incision was made over the spine of the scapula and the fracture site identified under C-arm. Dissection was carried down and the fracture line identified. The fracture was reduced with abduction of the arm and held in position with provisional K-wires. The scapular specific plating system (Acumed) did not have an ideal plate to address the fracture, therefore a clavicle plate was selected. This was fashioned onto the spine of the scapula and held in place with a proximal 3.5 mm bicortical screw. This was followed by placement of an additional screw distally for temporary fixation of the fracture. This was verified to be in good position under C-arm, and then multiple proximal and distal nonlocking screws were



**Figure 1** Radiographs of the patient's right shoulder at the time of injury.

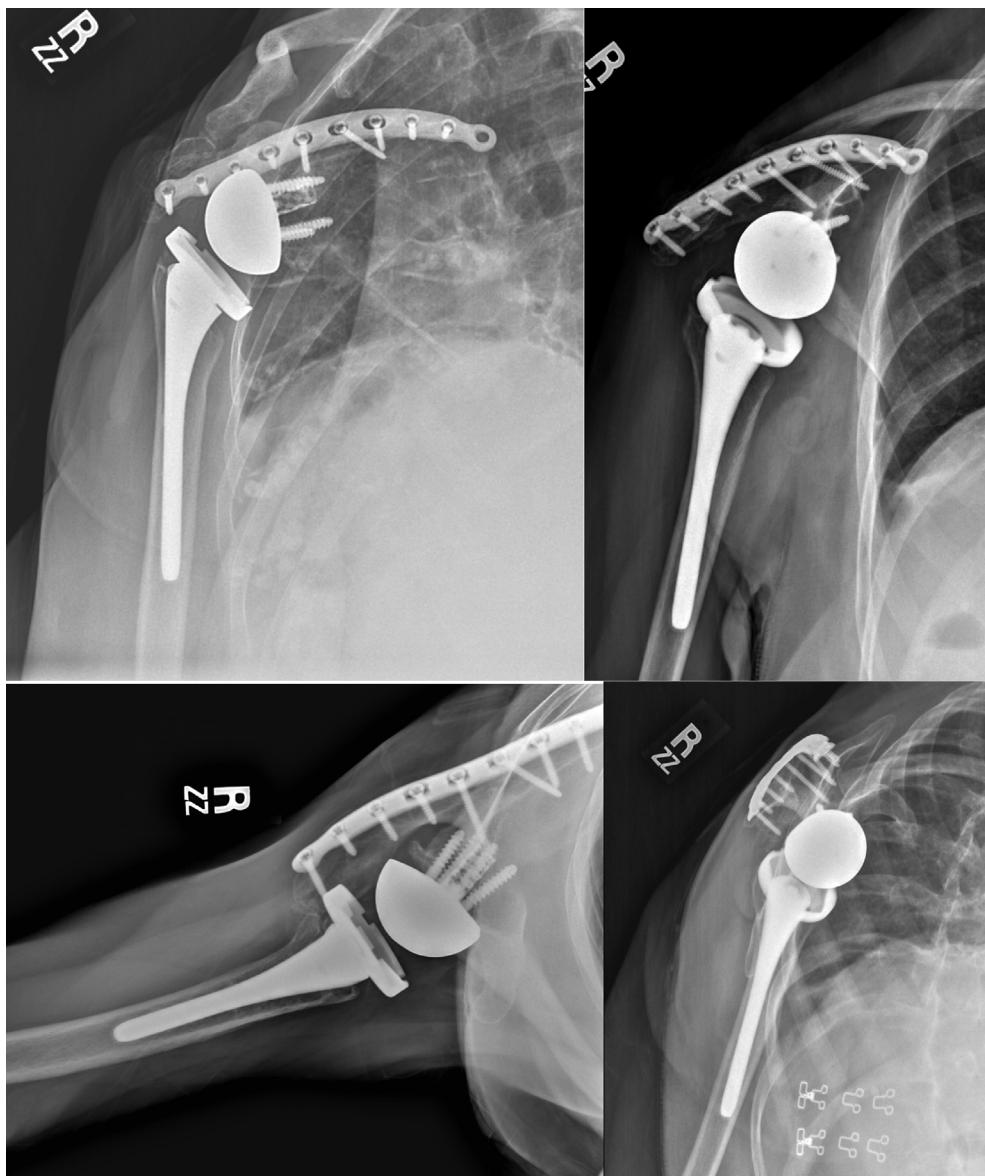
placed in addition to two distal locking screws. The wound was irrigated and closed in a layered manner, and the right arm was placed in an abduction sling.

At the two-week follow-up, the patient was doing very well without pain, and she was compliant with postoperative instructions. Wounds were well healed. Radiographs obtained at this time demonstrated anatomic reduction of fracture with no hardware loosening or failure. She was started on elbow, wrist, and hand range of motion. At her six-week visit, she continued to show improvement. On physical examination, she had returned to the baseline function of her right shoulder with flexion 160 degrees, external rotation 30 degrees, internal rotation L2. No pain, and patient instructed to discontinue sling at this time and maintain weightbearing less than 20 pounds until 12 weeks. At that visit she again had no complaints, radiographs demonstrated healed fracture in anatomic alignment, and was released to full activity. She worked with her primary care physician for osteoporosis management and was transitioned off of alendronate. At the one-year postoperative appointment, she had not suffered any setbacks and continued to have range of motion and function equivalent to her baseline. Radiographs demonstrated no new fractures or hardware failure (Fig. 2).

## Discussion

Fractures at the base of the acromion pose a challenge in the face of reverse total shoulder arthroplasty, as the deltoid muscle is functionally compromised for shoulder range of motion.<sup>12,22</sup> Because the rotator cuff is not functional, the load is transferred to the deltoid. There is a deforming force at the fracture site, and improper tension leads to compromised deltoid function.<sup>22</sup> Although Neyton et al identified three scapular spine fractures in asymptomatic patients at final follow-up approximately 112, 136, and 167 months, respectively, after reverse total shoulder arthroplasty, the dates and mechanisms of these injuries were unknown.<sup>15</sup> To our knowledge, this case report is the furthest from surgery that a base of acromion fracture with known mechanism and date of injury has been documented.

Our patient sustained a low-energy fracture after a sudden external rotation force on an extended right arm while rolling a suitcase behind her approximately five years after her index surgery. A clavicle plate was applied for fixation as it contoured to the patient's bone and provided adequate screw purchase on both sides of the fracture. Although several case reports have discussed the utility of 90/90 plating and mesh plating for these fractures,<sup>2,18</sup> to



**Figure 2** Radiographs of the patient's right shoulder approximately 1 year postoperatively.

the authors' knowledge, there has not been any specific discussion of clavicle plate fixation for type III fractures. However, nonoperative treatment of type III fractures leads to higher rates of nonunion and malunion.<sup>18</sup> There is no consensus on the methodology to fix this injury. While dual plating may offer a biomechanically advantageous construct, it requires additional soft tissue dissection, and there is no evidence demonstrating superior outcomes of dual fixation over single. Regardless of the construct, rigid fixation in type III acromion fractures may lead to satisfactory outcomes, but functional results may be limited even with surgical fixation.<sup>1,23</sup> Crosby et al note in their review that the superior metaglene screw can be a potential stress riser for a base of the acromion fracture, which may have been a contributing factor in this case.<sup>3</sup> Superior metaglene screws are more likely to be associated with type III scapular fractures than screws placed inferior to the central cage.<sup>10</sup> Our report suggests that a single plate can provide robust fixation with an excellent clinical outcome.

An additional consideration in this case is the use of the bisphosphonate, alendronate, which our patient had taken for

three years for management of her osteoporosis before her fracture. While one case report has linked bisphosphonate use to atraumatic scapular fracture,<sup>8</sup> there is no definitive evidence that bisphosphonate use is a risk factor to acromial base fractures after reverse total shoulder arthroplasty. One recent retrospective study suggested that previous bisphosphonate use is associated with a higher likelihood of fracture intraoperatively and after shoulder arthroplasty.<sup>13</sup> Some authors recommend a bisphosphonate holiday 3-5 years after treatment.<sup>21</sup> Osteoporosis, however, is a risk factor for scapular fracture after reverse total shoulder arthroplasty,<sup>16</sup> and the paradoxical effect of bisphosphonate-associated fractures in the scapula has not definitively been demonstrated.

There is an opportunity for orthopedists to ask about bone health and bisphosphonate use in routine follow-up after reverse shoulder arthroplasty, given the possible increased fracture risk at the base of the acromion. By ensuring appropriate referrals, patients can be regularly evaluated by a provider knowledgeable on bone health and able to manage and adjust medications as needed.

It may be prudent to counsel patients regarding bone health preoperatively and postoperatively.

## Conclusion

There should be suspicion of type III base of acromion fractures even in low-energy trauma after reverse shoulder arthroplasty. Surgeons considering reverse shoulder arthroplasty should review bisphosphonate medications with patients and encourage primary care or endocrinologist management. Avoidance of a superior metaglene screw should be considered if stable fixation can otherwise be obtained. Open reduction internal fixation of an acromial base fracture allowed a return to baseline function in our patient approximately five years after her reverse shoulder arthroplasty.

## Disclaimer

The authors, their immediate families, and any research foundations with which they are affiliated have not received any financial payments or other benefits from any commercial entity related to the subject of this article.

No funding was disclosed by the authors.

## References

1. Ascione F, Kilian CM, Laughlin MS, Bugelli G, Domos P, Neyton L, et al. Increased scapular spine fractures after reverse shoulder arthroplasty with a humeral onlay short stem: an analysis of 485 consecutive cases. *J Shoulder Elbow Surg* 2018;27:2183-90. <https://doi.org/10.1016/j.jse.2018.06.007>.
2. Camarda L, Phadnis J, Clitherow HD, Bain GI. Mesh plates for scapula fixation. *Tech Shoulder Elbow Surg* 2015;16:79-84. <https://doi.org/10.1097/BTE.0000000000000054>.
3. Crosby LA, Hamilton A, Twiss T. Scapula fractures after reverse total shoulder arthroplasty: classification and treatment. *Clin Orthop Relat Res* 2011;469:2544-9. <https://doi.org/10.1007/s11999-011-1881-3>.
4. Familiari F, Huri G, Gonzalez-Zapata A, McFarland EG. Scapula fracture and os acromiale after reverse total shoulder arthroplasty. *Orthopedics* 2014;37:434, 492-5. <https://doi.org/10.3928/01477447-20140626-01>.
5. Favard L, Katz D, Colmar M, Benkalfate T, Thomazeau H, Emily S. Total shoulder arthroplasty — arthroplasty for glenohumeral arthropathies: results and complications after a minimum follow-up of 8years according to the type of arthroplasty and etiology. *Orthop Traumatol Surg Res* 2012;98:S41-7. <https://doi.org/10.1016/j.otsr.2012.04.003>.
6. Frankle M, Siegal S, Pupello D, Saleem A, Mighell M, Vasey M. The reverse shoulder prosthesis for glenohumeral arthritis associated with severe rotator cuff deficiency. A minimum two-year follow-up study of sixty patients. *J Bone Joint Surg Am* 2005;87:1697-705. <https://doi.org/10.2106/JBJS.D.02813>.
7. Hamid N, Connor PM, Fleischli JF, D'Alessandro DF. Acromial fracture after reverse shoulder arthroplasty. *Am J Orthop* 2011;40:E125-9.
8. Haque S, Pandey R. Case report of bisphosphonate-associated atypical scapular fracture and brief literature review. *Int J Shoulder Surg* 2016;10:92-3. <https://doi.org/10.4103/0973-6042.180723>.
9. Hatstrup SJ. The influence of postoperative acromial and scapular spine fractures on the results of reverse shoulder arthroplasty. *Orthopedics* 2010;33. <https://doi.org/10.3928/01477447-20100329-04>.
10. Kennon JC, Lu C, McGee-Lawrence ME, Crosby LA. Scapula fracture incidence in reverse total shoulder arthroplasty using screws above or below metaglene central cage: clinical and biomechanical outcomes. *J Shoulder Elbow Surg* 2017;26:1023-30. <https://doi.org/10.1016/j.jse.2016.10.018>.
11. Levy JC, Anderson C, Samson A. Classification of postoperative acromial fractures following reverse shoulder arthroplasty. *J Bone Joint Surg Am* 2013;95:e104. <https://doi.org/10.2106/JBJS.K.01516>.
12. Levy JC, Blum S. Postoperative acromion base fracture resulting in subsequent instability of reverse shoulder replacement. *J Shoulder Elbow Surg* 2012;21:e14-8. <https://doi.org/10.1016/j.jse.2011.09.018>.
13. Mai DH, Oh C, Doany ME, Rokito AS, Kwon YW, Zuckerman JD, et al. Preoperative bisphosphonate treatment may adversely affect the outcome after shoulder arthroplasty. *Bone Joint J* 2019;101-B:147-53. <https://doi.org/10.1302/0301-620X.101B2.BJJ-2018-0906.R1>.
14. Mayne IP, Bell SN, Wright W, Coghlan JA. Acromial and scapular spine fractures after reverse total shoulder arthroplasty. *Shoulder Elbow* 2016;8(2):90-100. <https://doi.org/10.1177/1758573216628783>.
15. Neyton L, Erickson J, Ascione F, Bugelli G, Lunini E, Walch G. Grammont award 2018: scapular fractures in reverse shoulder arthroplasty (Grammont style): prevalence, functional, and radiographic results with minimum 5-year follow-up. *J Shoulder Elbow Surg* 2019;28:260-7. <https://doi.org/10.1016/j.jse.2018.07.004>.
16. Otto RJ, Virani NA, Levy JC, Nigro PT, Cuff DJ, Frankle MA. Scapular fractures after reverse shoulder arthroplasty: evaluation of risk factors and the reliability of a proposed classification. *J Shoulder Elbow Surg* 2013;22:1514-21. <https://doi.org/10.1016/j.jse.2013.02.007>.
17. Rittmeister M, Kerschbaumer F. Grammont reverse total shoulder arthroplasty in patients with rheumatoid arthritis and nonreconstructible rotator cuff lesions. *J Shoulder Elbow Surg* 2001;10:17-22.
18. Rouleau DM, Gaudelli C. Successful treatment of fractures of the base of the acromion after reverse shoulder arthroplasty: case report and review of the literature. *Int J Shoulder Surg* 2013;7:149-52. <https://doi.org/10.4103/0973-6042.123531>.
19. Stevens CG, Murphy MR, Stevens TD, Bryant TL, Wright TW. Bilateral scapular fractures after reverse shoulder arthroplasties. *J Shoulder Elbow Surg* 2015;24(2):e50-5. <https://doi.org/10.1016/j.jse.2014.09.045>.
20. Teusink MJ, Otto RJ, Cottrell BJ, Frankle MA. What is the effect of postoperative scapular fracture on outcomes of reverse shoulder arthroplasty? *J Shoulder Elbow Surg* 2014;23:782-90. <https://doi.org/10.1016/j.jse.2013.09.010>.
21. Villa JC, Gianakos A, Lane JM. Bisphosphonate treatment in osteoporosis: optimal duration of therapy and the incorporation of a drug holiday. *HSS J* 2016;12:66-73. <https://doi.org/10.1007/s11420-015-9469-1>.
22. Wahlquist TC, Hunt AF, Braman JP. Acromial base fractures after reverse total shoulder arthroplasty: report of five cases. *J Shoulder Elbow Surg* 2011;20:1178-83. <https://doi.org/10.1016/j.jse.2011.01.029>.
23. Walch G, Mottier F, Wall B, Boileau P, Molé D, Favard L. Acromial insufficiency in reverse shoulder arthroplasties. *J Shoulder Elbow Surg* 2009;18:495-502. <https://doi.org/10.1016/j.jse.2008.12.002>.