

# Radiographic analysis of the angle in the lateromedial projection of the metacarpophalangeal joint and the distal interphalangeal joint in metacarpophalangeal flexural deformities in calves

Ayano Sato,<sup>1</sup> Osamu Ishii,<sup>2</sup> Motoshi Tajima<sup>1</sup>

**To cite:** Sato A, Ishii O, Tajima M. Radiographic analysis of the angle in the lateromedial projection of the metacarpophalangeal joint and the distal interphalangeal joint in metacarpophalangeal flexural deformities in calves. *Veterinary Record Open* 2018;**5**:e000271. doi:10.1136/vetreco-2017-000271

Received 21 December 2017  
Revised 7 February 2018  
Accepted 8 March 2018

## ABSTRACT

The bone alignment of the metacarpophalangeal joint (MPJ) of the distal interphalangeal joint (DIPJ) in metacarpophalangeal flexural deformity (MPFD) in calves was evaluated by radiography. This study was designed by retrospective study of radiographs. Lateral to medial radiographs of distal forelimbs were taken from 19 MPFD affected calves (35 forelimbs) and 21 normal calves (42 forelimbs). Based on the radiographs, the lateral angles of MPJ were measured from the metacarpal bone axis and proximal phalanx axis, and lateral angles of DIPJ were measured from the middle phalanx axis and distal phalanx axis. Mean lateral angle of MPJ in the normal limbs was 175.9 (95% CI 174.5 to 177.4). Mean lateral angles of MPJ in MPFD were as follows: mild: 167.1 (158.9–175.2), moderate: 165.1 (158.5–171.7) and severe: 150.6 (146–155.1). MPJ angle in MPFD limbs was narrower than that in the normal limbs (mild, moderate and severe:  $P=0.017$ ,  $P=0.003$  and  $P<0.001$ , respectively). Mean lateral angle of DIPJ in the normal limbs was 211.9 (210.7–213.2). Mean lateral angles of DIPJ in moderate: 200.6 (195.2–206.1) and severe: 204.9 (203.3–206.5) MPFD were narrower than that in the normal limbs (both  $P<0.001$ ). There was no significant difference between the normal limbs and mild: 210.3 (206.9–213.7) MPFD limbs ( $P=0.7$ ). The clinical severity of MPFD corresponded well with the lateral angle of MPJ. The flexion of DIPJ in moderate and severe MPFD was similar to the flexion of MPJ in MPFD. This suggested that the lateral to medial radiographs accurately reflected the MPJ flexion and the DIPJ in MPFD in calves, providing useful information for the treatment of MPFD.

such as splints or foot extensions.<sup>4–6</sup> However, some severe cases do not recover and require surgery, in which MPFD is treated by sequentially transecting the superficial digital flexor tendon (SDFT), deep digital flexor tendons (DDFT) and suspensory ligament until remission of the deformity.<sup>1,5</sup> The surgeon decides intraoperatively which tendons or ligament to transect, and thus an estimation of the deformity is helpful for treatment.

In horses, distal limb flexural deformities present as carpus flexural deformities, MPFD or distal interphalangeal flexural deformities (clubfeet, DIPFD).<sup>7–11</sup> The DDFT, SDFT and suspensory ligament may all contribute to the occurrence of MPFD in horses.<sup>10,12,13</sup> In contrast, DIPFD involves only the DDFT.<sup>9,12,13</sup> For identification of the pathogenic origin in such cases, radiography is useful for assessing joint disorders and their prognoses.<sup>7,8,11,14–16</sup> Lateral to medial and 45°–60° dorsopalmar views of the foot are used for the diagnosis of DIPFD and MPFD in foals.

In the bovine cases, criteria for the choice of treatment have not been described. The objective of this study was to evaluate the changes of bone alignment on the metacarpophalangeal joint (MPJ) and the distal interphalangeal joint (DIPJ) in MPFD in calves.

## INTRODUCTION

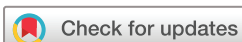Congenital metacarpophalangeal flexural deformities (MPFD) in calves present most commonly in the forelimbs.<sup>1</sup> A diagnosis can be made based on the anatomical construction of limbs examined by inspection and palpation.<sup>2,3</sup> Most cases are mild and recover naturally, whereas moderate and severe cases can be treated with non-surgical treatments

## MATERIALS AND METHODS

### Animals

This study was conducted according to the guidelines of the Experimental Animal Research Committee of Rakuno Gakuen University.

Nineteen calves (14±10 days old), 17 Holstein and two Brown Swiss, with MPFD were hospitalised at the Animal Medical



<sup>1</sup>Large Animal Clinical Sciences, Rakuno Gakuen University, Ebetsu, Japan

<sup>2</sup>Minami-NOSAI, Southern Hokkaido Agricultural Mutual Relief Association, Yakumo, Japan

### Correspondence to

Professor Motoshi Tajima; motoshi@rakuno.ac.jp

Center of Rakuno Gakuen University. Thirty-five MPFD forelimbs (left=18, right=17) were examined in this study including 16 calves' bilateral forelimbs and three calves' unilateral forelimbs. Twenty-one Holstein calves ( $10 \pm 7$  days), which were hospitalised for treatment of diarrhoea, pneumonia, omphalitis or other conditions with normal walking, were examined as normal control forelimbs (42 forelimbs: left=21, right=21).

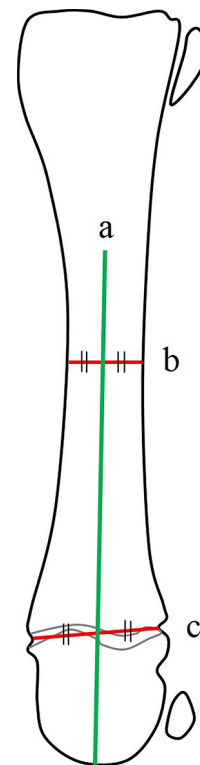
All MPFD were classified based on the inspection and palpation of affected calves according to a previous report.<sup>4</sup> In mild cases, calves are able to walk on their feet but the heels do not contact the ground. In moderate cases, the dorsal aspect of the hoof breaks over a vertical plane perpendicular to the ground. In severe cases, the calves walked on the dorsal aspect of the pastern, fetlock or carpus. The MPFD cases observed in the present study were classified into 7 mild, 7 moderate and 21 severe limbs.

### Radiographic technique

The calf was placed on a mattress in the lateral recumbent position with the affected limb uppermost. The affected limb was positioned perpendicular to the trunk and the carpal joint was extended. The limbs were adjusted so that the outside claw overlapped the inside claw. The adjustment was performed by the rotation of elbow joint which was out of the primary radio beam. Lateral to medial radiographs from proximal of the metacarpal bone to the toe were made with the limb parallel to the radiographic film cassette. The x-ray was focused on the centre of MPJ under conditions of 70 kV and 0.4 mAs.

### Radiographic evaluation

Radiographs were digitised and analysed using software (ImageJ, V.1.48, NIH, USA). The lateral angles of MPJ and DIPJ were measured using axis lines of the metacarpal bone and each phalanx. The metacarpal bone axis line was drawn between the midpoint of the minimum diameter of the diaphysis and the midpoint of the distal growth plate (Fig 1). The proximal phalanx axis (P1 axis) line was drawn between the midpoint of the metacarpophalangeal and proximal interphalangeal articular surface (Fig 2). The middle phalanx axis (P2 axis) line was drawn between the midpoint of the proximal interphalangeal articular surface and the midpoint of the minimum diameter portion of the middle phalanx. The distal phalanx axis (P3 axis) line was drawn between the midpoint of the distal interphalangeal articular surface and the tip of the distal phalanx. The metacarpal bone axis and the P1 axis were translated and extended to intersect with each other, and the lateral angle of MPJ was measured as the angle formed on the palmar side (Fig 3). Similarly, the P2 axis and the P3 axis were translated and extended to intersect with each other, and the lateral angle of DIPJ was measured between the palmar sides. All axis lines and angle measurements were made by the first author.

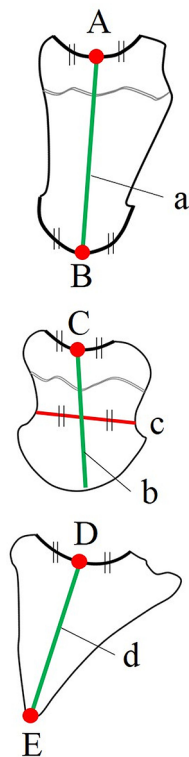


**FIGURE 1:** Landmarks for metacarpal bone axis in the lateral to medial direction. The metacarpal bone axis (line a) was defined as a line connecting the midpoint of the minimum diameter portion of the diaphysis of the metacarpal bone (line b) and the midpoint of the distal growth plate (line c).

The lateromedial direction angles of MPJ and DIPJ were measured at the outside claw and the inside claw, and the average values were calculated. The radiographic features of both sides of the claw at MPJ did not completely overlap. To evaluate the angle variation by positional rotation of the limb in radiological examinations, we calculated a *per cent deviation* of the outside claw and the inside claw in the lateral angles of MPJ and DIPJ, respectively. The *per cent deviation* was calculated as the difference of the angles in the area of the DIPJ of both digits divided by the average angle in this area of all calves involved, multiplied by 100 (Fig 4). *Per cent deviation* of the lateral angle of DIPJ including all normal and MPFD cases varied in range compared with *per cent deviation* of the lateral angle of MPJ including all cases. Any *per cent deviation* of 5 per cent or more in the lateral angle of DIPJ was excluded as an outlier, and 42 normal limbs and 35 MPFD limbs were used for this estimation in the present study.

### Statistical analysis

All statistical analyses were performed using a software program (SPSS Statistics V.24, IBM). Data from each group were combined, and means $\pm$ sd with 95% CIs were determined. A *t* test was performed to determine differences between left forelimbs and right forelimbs for normal and MPFD, respectively. After analysis of variance



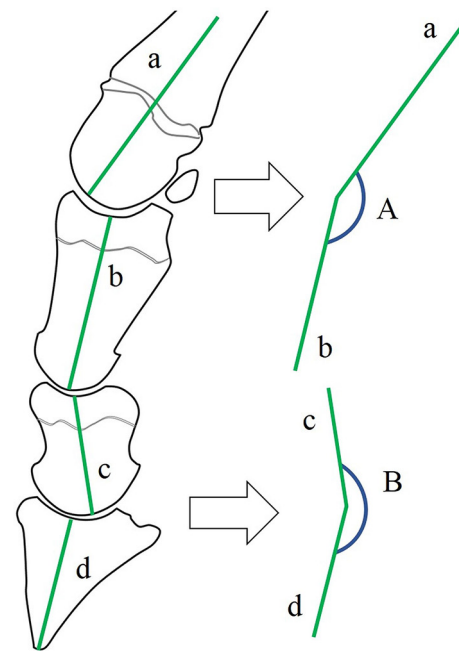
**FIGURE 2:** Landmarks for each phalangeal axis in the lateral to medial direction. The proximal phalanx axis (P1 axis, line a) was defined as a line connecting the midpoint of the metacarpophalangeal articular surface (A) and the midpoint of the proximal interphalangeal articular surface (B). The middle phalanx axis (P2 axis, line b) was defined as a line connecting the midpoint of the proximal interphalangeal articular surface (C) and the midpoint of the minimum diameter portion of middle phalanx (line c). The distal phalanx axis (P3 axis, line d) was defined as a line connecting the midpoint of the distal interphalangeal articular surface (D) and the tip of the distal phalanx (E).

as post hoc analysis, Dunnett's test was performed to determine the differences between controls and each severity of MPFD (mild, moderate and severe) in lateral angle of MPJ and DIPJ. Significance was set at  $P < 0.05$ .

## RESULTS

The *per cent deviation* of the lateral angle of MPJ in 77 forelimbs ranged from 0 to 2.5 per cent (minimum to maximum). The *per cent deviation* of DIPJ in 77 forelimbs ranged from 0 to 4.5 per cent. Three forelimbs from three MPFD calves were excluded from the study with *per cent deviation* over 5 per cent. All normal forelimbs were used for the study.

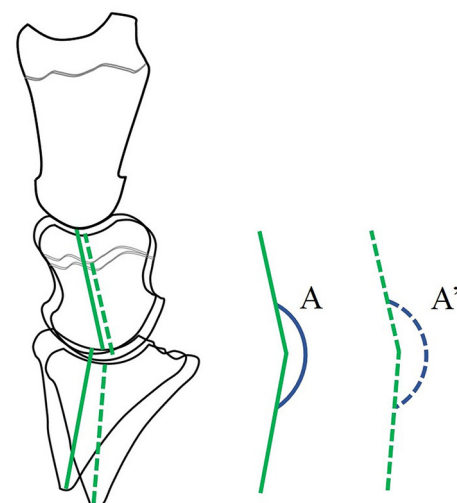
The lateral angles of MPJ and DIPJ in 21 normal left limbs were  $176.9 \pm 4.9^\circ$  (mean  $\pm$  sd) and  $211.5 \pm 4.5^\circ$ , and in 21 normal right limbs were  $174.9 \pm 4.3^\circ$  and  $212.4 \pm 4.1^\circ$ , respectively. There was no significant difference between left and right limbs (MPJ:  $P = 0.2$  and DIPJ:  $P = 0.5$ , respectively). The lateral angles of MPJ and DIPJ in 18 MPFD left limbs were  $158.7 \pm 11.6^\circ$  and  $204.1 \pm 6.3^\circ$ , and in 17 MPFD right limbs were  $154.7 \pm 13.6^\circ$  and  $206.3 \pm 4.7^\circ$ .



**FIGURE 3:** The lateral angle of the metacarpophalangeal joint (MPJ) (angle A) was determined by crossing the metacarpal bone axis (line a) and the P1 axis (line b) and measuring the angle formed on the palmar aspect. The lateral angle of the distal interphalangeal joint (DIPJ) (angle B) was made by crossing the P2 axis (line c) and P3 axis (line d) and measuring the angle formed on the palmar aspect.

Also, in MPFD-affected calves, there was no significant difference between left and right limbs ( $P = 0.4$  and  $P = 0.3$ , respectively).

The lateral angles of MPJ in normal limbs and MPFD limbs are summarised in Table 1. The lateral angle of MPJ in MPFD was significantly narrower (mild:  $P = 0.017$ , moderate:  $P = 0.003$  and severe:  $P < 0.001$ , respectively).



**FIGURE 4:** The *per cent deviation* was the average deviation of A and A' values divided by the average of A and A' and multiplied by 100. *Per cent deviation* =  $|A - \{(A+A')/2\} / \{(A+A')/2\} \times 100\%$ . A, angle of one lateral distal interphalangeal joint; A', angle of the other lateral distal interphalangeal joint.

**TABLE 1:** Lateral angles of MPJ in 42 normal limbs and 35 MPFD limbs

	Normal limbs (n=42)	Mild MPFD limbs (n=7)	Moderate MPFD limbs (n=7)	Severe MPFD limbs (n=21)
Mean lateral angle of MPJ±sd (°)	175.9±4.6	167.1±10.9*	165.1±8.9†	150.6±10.4†
95% CI for mean lateral angle of MPJ	174.5 to 177.4	158.9 to 175.2	158.5 to 171.7	146.1 to 155.1

Significant difference (\*p<0.05, \*\*p<0.01) compared with normal limbs (Dunnett's test). MPFD, metacarpophalangeal flexural deformity; MPJ, metacarpophalangeal joint.

than that in the normal limbs. Severe MPFD showed the smallest angle among the affected limbs.

The lateral angles of DIPJ in normal limbs and MPFD limbs are summarised in Table 2. The lateral angle of DIPJ in moderate and severe MPFD was significantly narrower (both P<0.001) than that in the normal limbs. There was no significant difference between the normal limbs and mild MPFD limbs (P=0.7). The DIPJ angle corresponded well with the severity of MPFD.

There were no fractures or morphological abnormalities of bones in all calves. Both joint angles were narrower according to the severity of clinical features. This indicated that the joint disorders reflected surrounding soft tissue abnormalities.

## DISCUSSION

In the present study, the lateral angle of MPJ in MPFD limbs was narrower, according to severity, and the lateral angles of DIPJ in moderate and severe MPFD were significantly narrower on the palmar side compared with normal limbs.

In MPFD and DIPFD of horses, the characteristic morphology of affected limbs in severe cases has been used for diagnosis.<sup>9-11</sup> Treatment guidelines for MPFD in horses are based on the angle of the fetlock, and treatment guidelines for DIPFD in foals are based on the angle of the dorsal hoof wall relative to the ground. The surgical options including desmotomy and/or tenotomy are determined based on the angle of the deformity.<sup>8,9,12</sup> Lateral to medial view radiographs of the foot in DIPFD are useful to estimate the disorders of DIPJ alignment and angle of the dorsal hoof wall.<sup>9,11,14,16</sup> The present study is the first radiographic analysis of MPFD in calves. Accordingly, the metacarpal bone and phalanx axes were established by reference to radiographs of flexural deformities in foals.<sup>9,11,14,16</sup>

For accurate radiographs of DIPFD in horses, lateral to medial and dorsopalmar views with weightbearing by the affected limbs in a standing position are necessary.<sup>8,9,11,14,16</sup> The anatomical change involves the degree of flexion and the soft tissues related to the distortion of the hoof capsule.<sup>14,16</sup> The weightbearing properties of the foot reveal the position of the distal phalanx within the hoof capsule, solar depth and length of the heels, and the osseous integrity of the perimeter of the distal phalanx.<sup>8,14,16</sup> It is difficult to exactly overlap both digits of the same foot in standing position. Thus, in the present study, radiography was performed in a lateral recumbent position. The affected limb was positioned perpendicular to the trunk and the carpal joint was extended as far as naturally possible without traction. Because radiographs were obtained without weightbearing, the present study was designed under restricted conditions. A comparison with radiographs taken while weightbearing in a standing position is needed. However, based on the comparison with normal limbs, the lateral angle of MPJ in MPFD limbs narrowed depending on the severity. As shown in the Results section, the morphological changes corresponded well with the severity of the joint disorder. The soft tissue damage to tendons and ligaments could be estimated from the analysis of the bone alignment of MPJ.

The lateral angles of MPJ and DIPJ were measured from radiographic features of both sides of the claw. Radiographs of obviously rotated limbs were excluded, and the deviation between both digits of the same foot for all lateral angles of MPJ was very small (*per cent deviation*: 0–2.5 per cent, minimum-maximum). In contrast, a large deviation between both sides of the claw for all lateral angles of DIPJ was recognised (*per cent deviation*: 0–4.5 per cent). Although radiographs were taken many times in some cases, the digits of the same foot did not always exactly overlap. This was thought to be due to the

**TABLE 2:** Lateral angles of DIPJ in 42 normal limbs and 35 MPFD limbs

	Normal limbs (n=42)	Mild MPFD limbs (n=7)	Moderate MPFD limbs (n=7)	Severe MPFD limbs (n=21)
Mean lateral angle of DIPJ±sd (°)	211.9±4.3	210.3±4.6	200.6±7.4*	204.9±3.8*
95% CI for mean lateral angle of DIPJ	210.7 to 213.2	206.9 to 213.7	195.2 to 206.1	203.3 to 206.5

\*Significant difference (P<0.01) compared with normal limbs (Dunnett's test). DIPJ, distal interphalangeal joint; MPFD, metacarpophalangeal flexural deformity.

focus of the radiographs and to the route of the common digital extensor tendons.<sup>17</sup> The variance between lateral angles of DIPJ from both sides of the claws was considered to result from the harmonisation of extensor and flexor musculotendinous tissues. The mean lateral angle of DIPJ in moderate MPFD, which was smaller than the mean lateral angle of DIPJ in severe MPFD, might be influenced by variance between the digits of the same foot. However, the lateral angle of DIPJ in moderate and severe MPFD limbs was significantly narrower than that in normal limbs. The appearance of DIPJ in moderate and severe MPFD by inspection and radiographs was similar to DIPFD caused by contracted DDFT in horses. We suspected that moderate and severe MPFD in calves is influenced by a contracted DDFT.

Successful treatment of MPFD depends on the severity and on an appropriate choice of therapy.<sup>6</sup> Mild to moderate MPFD usually responds to physical therapy and treatments using a toe shoe, splint or cast.<sup>1</sup> Most MPFD calves recover by non-surgical management. However, the results in severe MPFD limbs, especially chronic cases, are often disappointing and these animals are usually euthanased because of their restricted movement even after complete tenotomy of the flexor tendons.<sup>1 4 6</sup> Severe MPFD is an intractable disease, and it is important that an appropriate diagnosis is made and surgery is performed early. This study suggested that a criterion for appropriate surgical treatment of severe MPFD may be obtained based on radiographs of the lateral angle of DIPJ.

In conclusion, the present study showed that radiographs provide more detailed information about the MPFD in calves, supplementing inspection and palpation. The lateral angles of MPJ in MPFD were more flexed to the palmar side according to the severity of MPFD compared with normal limbs, and the lateral angles of DIPJ in moderate and severe MPFD were more flexed to the palmar side compared with normal limbs. We suggest that the DIPJ flexion is related to MPJ flexion, and that lateral to medial radiographs are diagnostically useful for estimating the prognosis of MPFD in calves with DIPJ flexion, particularly when planning surgery.

**Acknowledgements** We thank all the staff members of the Animal Medical Center of Rakuno Gakuen University for their support.

**Contributors** AS and OI took radiographs. AS performed image analysis and wrote this paper. MT is the corresponding author.

**Funding** The authors have not declared a specific grant for this research from any funding agency in the public, commercial or not-for-profit sectors.

**Competing interests** I do not disclose my identity.

**Provenance and peer review** Not commissioned; externally peer reviewed.

**Data sharing statement** There are no additional unpublished data.

**Open Access** This is an Open Access article distributed in accordance with the Creative Commons Attribution Non Commercial (CC BY-NC 4.0) license, which permits others to distribute, remix, adapt, build upon this work non-commercially, and license their derivative works on different terms, provided the original work is properly cited and the use is non-commercial. See: <http://creativecommons.org/licenses/by-nc/4.0/>

© British Veterinary Association (unless otherwise stated in the text of the article) 2018. All rights reserved. No commercial use is permitted unless otherwise expressly granted.

## REFERENCES

1. Ducharme NG, Desrochers A, Freeman D. Surgery of flexural and hyperextension deformities. In: *Farm animal surgery*. 2nd edn. St. Louis: Elsevier, 2017:519–23.
2. Leipold HW, Hiraga T, Dennis SM. Congenital defects of the bovine musculoskeletal system and joints. *Vet Clin North Am Food Anim Pract* 1993;9:93–104.
3. Weaver AD, St Jean G, Steiner A, et al. *Bovine surgery and lameness*. 2nd edn. Oxford: Blackwell, 2005:240–2.
4. Anderson DE, Desrochers A, St Jean G. Management of tendon disorders in cattle. *Vet Clin North Am Food Anim Pract* 2008;24:551–66.
5. Pentecost R, Niehaus AJ, Anderson DE. Surgical management of fractures and tendons. *Vet Clin North Am Food Anim Pract* 2016;32:797–811.
6. Steiner A, Anderson DE, Desrochers A. Diseases of the tendons and tendon sheaths. *Vet Clin North Am Food Anim Pract* 2014;30:157–75.
7. Auer JA. Diagnosis and treatment of flexural deformities in foals. *Clinical Techniques in Equine Practice* 2006;5:282–95.
8. Baxter GM, deformity F. *Adams and Stashak's lameness in horses*. 6th edn. Chichester: Wiley-Blackwell, 2011:1145–54.
9. Caldwell FJ. Flexural deformity of the distal interphalangeal joint. *Vet Clin North Am Equine Pract* 2017;33:315–30.
10. Gaughan EM. Flexural limb deformities of the carpus and fetlock in foals. *Vet Clin North Am Equine Pract* 2017;33:331–42.
11. Kidd JA, Barr ARS. Flexural deformities in foals. *Equine Vet Educ* 2002;14:311–21.
12. Adams SB, Santschi EM. Management of congenital and acquired flexural limb deformities. *Proceedings Am Assoc Eq Pract* 2000;46:117–25.
13. Wagner PC, Reed SM, Hergeberg GA, et al. Contracted tendons (flexural deformities) in the young horse. *Comp Cont Educ Pract Vet* 1982;4:S101–8.
14. Arnbjerg J. Changes in the distal phalanx in foals with deep digital flexor tendon contraction. *Veterinary Radiology* 1988;29:65–9.
15. Lloyd-Bauer PM, Fretz PB. Correction of acquired flexural deformity by deep digital flexor tenotomy in a miniature horse. *Can Vet J* 1989;30:585–9.
16. O'Grady SE. Flexural deformities of the distal interphalangeal joint (clubfeet). *Equine Vet Educ* 2012;24:260–8.
17. Dyce K, Sack W, Wensing CJG. The forelimb of the ruminant. In: *Textbook of veterinary anatomy*. 4th edn. St. Louis: Elsevier, 2009:728–41.