

Pre-operative angle of trunk rotation in prone position estimates postoperative correction results

Masashi Uehara, MD, PhD^{a,*}, Shota Ikegami, MD, PhD^a, Shugo Kuraishi, MD, PhD^a, Hiroki Oba, MD, PhD^a, Takashi Takizawa, MD, PhD^a, Ryo Munakata, MD^a, Terue Hatakenaka, MD^a, Michihiko Koseki, PhD^b, Jun Takahashi, MD, PhD^a

Abstract

This study investigated whether postoperative rotational deformity in adolescent idiopathic scoliosis patients could be predicted by prone-position pre-operative angle of trunk rotation (ATR).

Surgical rib hump correction is performed with the patient in a prone position. However, the association between pre-operative ATR in the prone position and postoperative ATR results is unknown.

Thirty-four consecutive patients who underwent skip pedicle screw fixation for Lenke type 1 or 2 adolescent idiopathic scoliosis were retrospectively reviewed. All subjects were followed for a minimum of 1 year. ATR measurements were taken for the standing-flexion position with a scoliometer before surgery and at 1 year afterward. Pre-operative measurements were also taken for the prone position. Correlations between pre- and postoperative ATR were calculated by means of Pearson correlation coefficient. Associations between the correction angle from the standing-flexion position to prone position and postoperative standing-flexion correction angle were determined by linear regression analysis.

Pre- and postoperative ATR for the standing-flexion position showed a moderate association ($r=0.64$, $P<.01$). A similar correlation was seen for pre-operative prone-position ATR and postoperative standing-flexion ATR ($r=0.56$, $P<.01$). In linear regression analysis, there was significant proportional error between the correction angle from the standing-flexion position to prone position and postoperative standing-flexion correction angle ($\beta=0.40$, $P<.01$).

In conclusion, pre-operative ATR in either standing-flexion or prone position and postoperative standing-flexion ATR displayed moderate associations. Linear regression analysis revealed that ATR correction angle could be estimated by calculating the correction gains of 0.4° per 1° of correction angle in the prone position.

Abbreviations: AIS = adolescent idiopathic scoliosis, ATR = angle of trunk rotation, EV = end vertebra, MT = main thoracic.

Keywords: adolescent idiopathic scoliosis, angle of trunk rotation, posterior spinal fusion, prone position, selective thoracic fusion

1. Introduction

The main goals of corrective surgery for adolescent idiopathic scoliosis (AIS) are coronal deformity correction, improved

sagittal alignment, and axial rotation while minimizing the number of motion segments fused. Therefore, it is important to know pre-operatively how much correction is possible. Evaluating curve flexibility also is important to achieve good correction in the surgical treatment of AIS. Regarding coronal curve correction, several reports have addressed flexibility evaluation in AIS, such as the fulcrum bending, supine traction, and prone-push positions^[1-3] (Table 1). However, few studies have assessed the correlation between pre-operative parameters and axial rotation correction.

One of the characteristic findings in thoracic AIS (Lenke type 1 or 2) is a rib hump. The angle of trunk rotation (ATR) as measured by a scoliometer is widely used for rib hump evaluation. Normally, the patient assumes a standing position with the trunk bending forward (i.e., the standing-flexion position) and the scoliometer is placed on the most inclined part of the rib protuberance to evaluate the rotation of the trunk.^[4] However, surgical rib hump correction is performed with the patient in a prone position. We have recently devised a method to evaluate ATR in the prone position and hypothesize that it may correlate with postoperative standing-flexion ATR. There are few studies on the prediction of axial rotation correction in the surgical treatment of scoliosis despite such correction also being important. The purpose of this study was to investigate whether postoperative rotation deformity could be predicted by pre-operative ATR in the prone position.

Editor: David Cory Adamson.

The authors have no conflicts of interest to disclose.

The datasets generated during and/or analyzed during the current study are available from the corresponding author on reasonable request.

^a Department of Orthopaedic Surgery, Shinshu University School of Medicine, 3-1-1 Asahi, Matsumoto, Nagano, Japan, ^b Faculty of Textile Science and Technology, Shinshu University, 3-15-1 Tokida, Ueda, Nagano, Japan.

* Correspondence: Masashi Uehara, Department of Orthopaedic Surgery, Shinshu University School of Medicine, 3-1-1 Asahi, Matsumoto, Nagano 390-8621, Japan (e-mail: masashi_u560613@yahoo.co.jp).

Copyright © 2021 the Author(s). Published by Wolters Kluwer Health, Inc. This is an open access article distributed under the terms of the Creative Commons Attribution-Non Commercial License 4.0 (CCBY-NC), where it is permissible to download, share, remix, transform, and build upon the work provided it is properly cited. The work cannot be used commercially without permission from the journal.

How to cite this article: Uehara M, Ikegami S, Kuraishi S, Oba H, Takizawa T, Munakata R, Hatakenaka T, Koseki M, Takahashi J. Pre-operative angle of trunk rotation in prone position estimates postoperative correction results. *Medicine* 2021;100:51(e28445).

Received: 3 February 2020 / Received in final form: 6 December 2021 /

Accepted: 8 December 2021

<http://dx.doi.org/10.1097/MD.00000000000028445>

Table 1**Previous reports on pre-operative assessment of scoliosis correction.**

Year of publication	Author [reference]	Title of article	Assessment of scoliosis correction
1998	Luk et al ^[1]	Assessment of scoliosis correction in relation to flexibility using the fulcrum bending correction index	Fulcrum bending correction radiograph
2005	Hamzaoglu et al ^[2]	Assessment of curve flexibility in adolescent idiopathic scoliosis	Traction radiograph under general anesthesia
2011	Chen et al ^[3]	Using precisely controlled bidirectional orthopedic forces to assess flexibility in adolescent idiopathic scoliosis: comparisons between push-traction film, supine side bending, suspension, and fulcrum bending film	Push and traction correction radiograph
	Present study		Pre-operative angle of trunk rotation scoliometry

2. Materials and methods

Thirty-four consecutive patients (4 male and 30 females; mean \pm standard deviation age: 14.9 ± 2.3 years [range: 11–20 years]) who underwent skip pedicle screw fixation as previously described^[5–7] for Lenke type 1 or 2 AIS between November 2015 and September 2018 were retrospectively reviewed. Lenke classification was type 1A in 15 patients, type 1B in 4, type 1C in 8, type 2A in 6, and type 2B in 1. All subjects were followed for a minimum of 1 year. Inferior facetectomy was carried out for all subjects, followed by manual pushing on the hump for correction. For curves in which the surgeon felt that such correction was not feasible during pushing on the hump, a Ponte osteotomy was performed on 3–5 inter-vertebrae to set an apex region of the main thoracic (MT) curve.

2.1. Selection of upper instrumented vertebra and lower instrumented vertebra

The upper instrumented vertebra was T2 for Lenke 2 curves and was generally decided as the upper end vertebra (EV) for Lenke type 1 AIS with an elevated right shoulder, EV+1 in patients with horizontal shoulders, and EV+2 or T2 in patients with an elevated left shoulder. The lower instrumented vertebra was the vertebra that last touched the center sacral vertical line for Lenke 1A and 2A. For Lenke 1B and 1C, the lower instrumented vertebra was determined as the stable vertebra or 1 level below the stable vertebra according to the report by Takahashi et al.^[8]

2.2. Measurement of ATR

Clinically, the transverse plane deformity was assessed by posterior trunk asymmetry (rib hump) with the Bunnell technique^[9] as measured with a scoliometer placed at the apex of the deformity. Measurements were performed using the forward-bending Adam test with a scoliometer before surgery and at 1 year afterward^[4] (Fig. 1A). We also performed pre-operative measurements in the prone position (Fig. 1B).

2.3. Radiological assessment

This study evaluated radiological curve flexibility before surgery and radiological curve correction at 1 year postoperatively. We defined flexibility as follows: (Cobb angle in standing position – Cobb angle in side bending)/Cobb angle in standing position \times 100%.

2.4. Statistical analysis

Correlations between pre- and postoperative ATR values were calculated by means of Pearson correlation coefficient. Associations between the correction angle from the standing-flexion position to prone position and postoperative correction angle were calculated by linear regression analysis. Statistical analyses between pre- and postoperative Cobb angle and ATR were calculated by paired *t* testing. All statistical analyses were performed using EZR (Saitama Medical Center, Jichi Medical University, Saitama, Japan), a graphical user interface for R (The

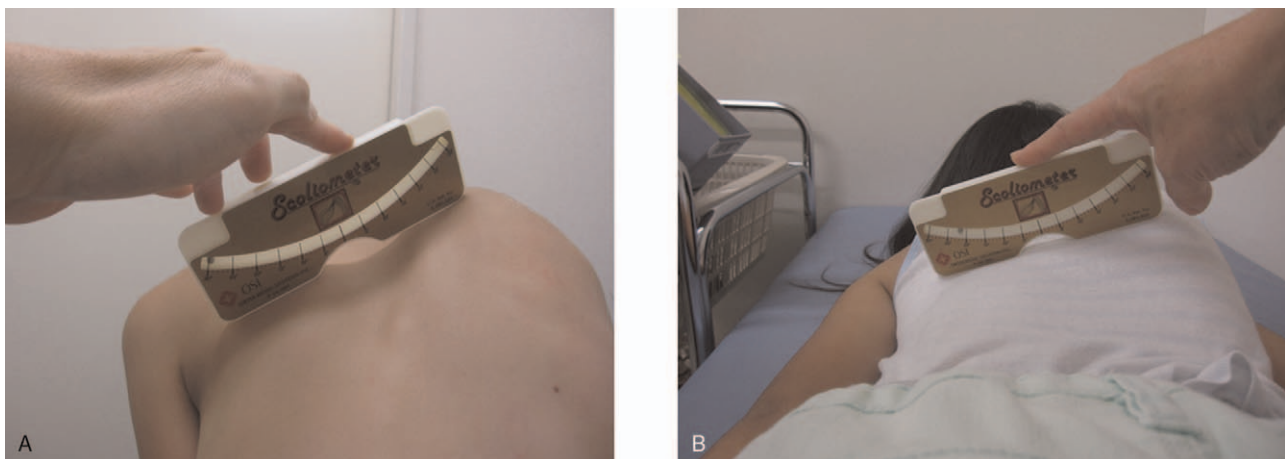


Figure 1. Measurement of angle of trunk rotation (ATR). ATR measurements were performed in the standing-flexion (A) and prone (B) positions with a scoliometer.

Table 2
Pre-operative radiological and clinical features.

	Mean ± standard deviation (range)
Age, yrs	14.9 ± 2.3 (11–20)
Sex, male:female	4:30
Cobb angle of MT curve, °	52 ± 8 (37–72)
MT curve flexibility, %	44.9 ± 18.6 (20.0–100)
ATR in standing-flexion position, °	16 ± 5 (9.5–26.5)
ATR in prone position, °	12 ± 3 (7–18)

ATR=angle of trunk rotation, MT=main thoracic.

Foundation for Statistical Computing, Vienna, Austria). More precisely, EZR is a modified version of R commander designed to add statistical functions frequently used in biostatistics.^[10] The level of significance was set at $P < .05$. Prior approval of the study was obtained from the investigational review board of Shinshu University hospital (No. 3500). Written informed consent for publication was obtained from all patients prior to this study.

3. Results

The cohort’s pre-operative radiological and clinical features are summarized in Table 2. The mean ± standard deviation number of fused vertebrae was $7.8 ± 1.5$ (range: 6–9). Ponte osteotomy was performed in 16 cases and involved a mean of $4.3 ± 1.3$ inter-vertebrae (range: 3–11 inter-vertebrae). Pre-operative mean MT curve Cobb angle was significantly improved from $52° ± 8°$ to $24° ± 7°$ (mean correction rate: $53 ± 13%$) at 1 year after surgery ($P < .01$). The 1-year postoperative mean standing-flexion ATR angle was significantly ameliorated from $16° ± 5°$ to $9° ± 3°$, with a mean correction rate of $46% ± 18%$ ($P < .01$). Standing-flexion pre- and postoperative ATR showed a moderate association ($r = 0.64$, $P < 0.01$) (Table 3, Fig. 2A). A moderate correlation was also observed between pre-operative ATR in the prone position and postoperative standing-flexion ATR ($r = 0.56$, $P < .01$) (Table 3, Fig. 2B). There was no remarkable relationship between MT curve flexibility and ATR correction rate ($r = -0.02$, $P = .89$).

Table 3
Correlation between pre-operative ATR and 1-year postoperative standing-flexion ATR.

Pre-operative ATR	R	P value
Standing-flexion position	0.64	< .01*
Prone position	0.56	< .01*

ATR=angle of trunk rotation.
* < 0.05.

We further analyzed the association between the correction angle from the standing-flexion position to prone position and postoperative correction angle by linear regression analysis to reveal a significant proportional error ($\beta = 0.40$, 95% confidence interval [0.18, 0.61], $P < .01$).

Lastly, ATR correction was compared between patients with and without Ponte osteotomy. Correction was similar at $7.7° ± 3.2°$ and $7.8° ± 4.5°$, respectively ($P = .94$). The differences between pre-operative prone-position ATR and postoperative standing-flexion ATR were $2.9° ± 2.5°$ with Ponte osteotomy and $3.0° ± 4.1°$ without, which were also comparable ($P = .93$) (Fig. 3).

4. Discussion

This study investigated the correlation between pre-operative ATR in the standing-flexion or prone position and postoperative standing-flexion ATR at 1 year after surgery in AIS patients with Lenke type 1 or 2 curves. Pre-operative ATR in both positions exhibited moderate correlations with postoperative ATR, indicating that either might be used to predict surgical results.

The main purpose of AIS surgery is adequate coronal and sagittal correction, including rotational deformity correction such as ATR. The pre-operative estimation of coronal curve following posterior correction surgery has been described in several studies.^[1–3] However, reports on the correlation between pre-operative parameters and axial rotational deformity correction remain scarce, with precise associations unclear.

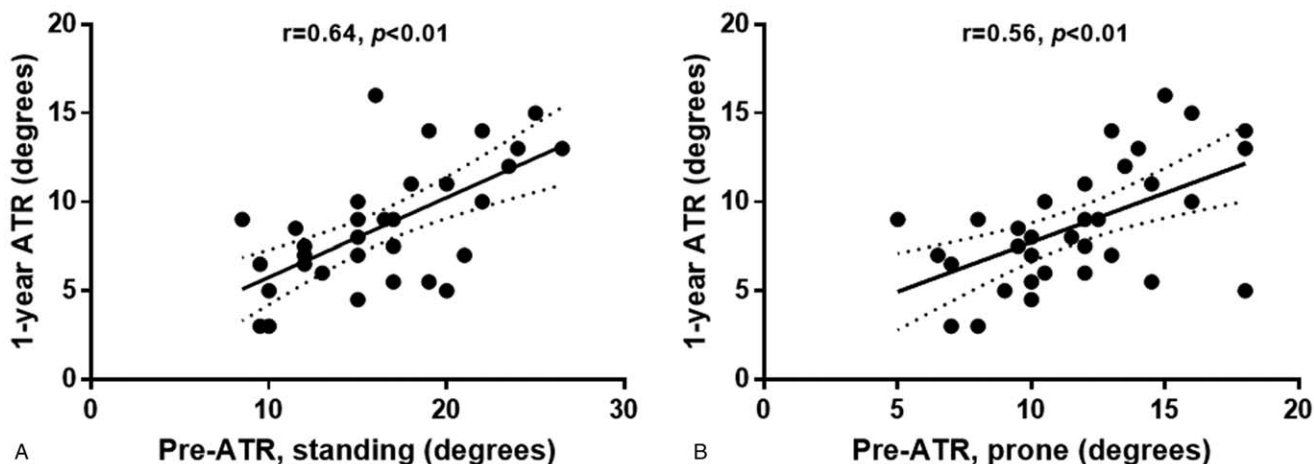


Figure 2. Correlations between pre- and postoperative angle of trunk rotation (ATR). (A) A moderate correlation was seen between pre- and postoperative standing-flexion ATR ($r = 0.64$, $P < .01$). (B) Pre-operative ATR in the prone position and postoperative standing-flexion ATR also showed a moderate association ($r = 0.56$, $P < .01$).

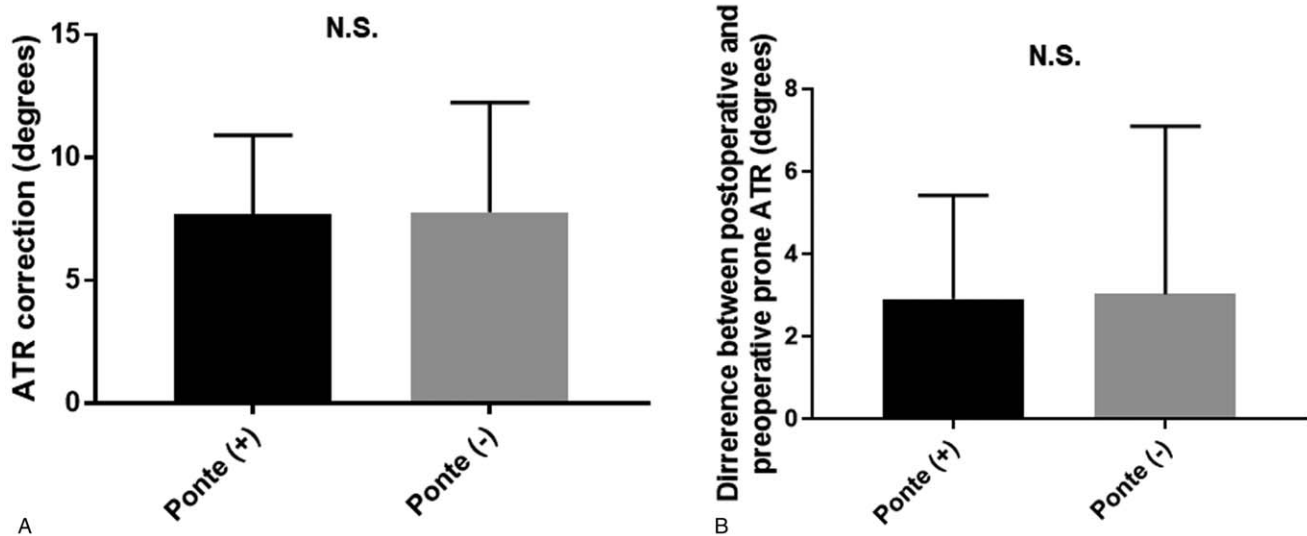


Figure 3. Influence of Ponte osteotomy on angle of trunk rotation (ATR). (A) ATR correction in patients with and without Ponte osteotomy was similar at 7.7° and 7.8°, respectively ($P=.94$). (B) The difference between pre-operative prone-position ATR and postoperative standing-flexion ATR was 2.9° with Ponte osteotomy and 3.0° without, which was comparable ($P=.93$).

Concerning MT curve correction, Luk et al^[1] used fulcrum bending radiographs for determination of MT curve flexibility, while Chen et al^[3] evaluated flexibility by push-traction films. Hamzaoglu et al^[2] reported that traction radiographs with the patient under general anesthesia might better show flexibility, especially for curves greater than 65° and rigid curves.

One of the characteristic findings in thoracic AIS is a rib protuberance, which is commonly evaluated by ATR. In a previous study, rib hump correction was occurred with the patient in a prone position.^[11] However, the predictive ability of prone-position ATR on postoperative hump correction results is unknown. Our results indicated moderate correlations between pre-operative ATR in the standing-flexion or prone position and postoperative standing-flexion ATR, with none for MT curve flexibility with ATR correction rate. Furthermore, linear regression analysis showed significant proportional error between the correction angle from the standing-flexion position to prone position and postoperative correction angle ($\beta=0.40$, 95% confidence interval [0.18, 0.61], $P<.01$). In other words, ATR correction angle could be estimated by calculating a correction gain of 0.4° per 1° of correction angle in the prone position.

It has been reported that Ponte osteotomy can also help coronal and sagittal plane deformities during thoracic vertebrae correction.^[12,13] However, in our study, there were no significant ATR gain differences between patients with and without Ponte osteotomy. We therefore considered the influence of Ponte osteotomy to be relatively small on the results of this investigation.

In recent years, translational research, which is the application of basic research results in clinical practice, has been garnering attention.^[14] We hope to extend the results of this study to such clinical applications as the development of instruments that can calculate the predicted correction angle of axial rotation in scoliosis surgery by measuring pre-operative ATR. Further

research on measurement methods and instrument development related to ATR is needed.

4.1. Limitations

The main limitations of the current study include a small sample size and retrospective design. Accordingly, we could not precisely assess the effects of osteotomy in this limited cohort.

Notwithstanding, our analysis of outcomes showed that pre-operative ATR in the prone position could predict ATR correction after posterior surgical correction for AIS with Lenke type 1 or 2 curves.

5. Conclusion

This study evaluated the association between pre- and postoperative ATR in AIS patients. Pre-operative ATR in the standing-flexion or prone position had moderate associations with postoperative ATR. Linear regression analysis showed that ATR correction angle could be estimated by calculating a correction gain of 0.4° per 1° of correction angle in the prone position. Additional research on the development of measurement methods and devices is needed for clinical application.

Author contributions

Conceptualization: Masashi Uehara.

Data curation: Masashi Uehara, Shota Ikegami, Shugo Kuraishi, Hiroki Oba, Takashi Takizawa, Ryo Munakata, Terue Hatakenaka, Michihiko Koseki, Jun Takahashi.

Formal analysis: Masashi Uehara.

Investigation: Masashi Uehara, Shota Ikegami, Shugo Kuraishi, Hiroki Oba, Takashi Takizawa, Ryo Munakata, Terue Hatakenaka, Michihiko Koseki, Jun Takahashi.

Methodology: Masashi Uehara, Shota Ikegami, Shugo Kuraishi, Jun Takahashi.

Project administration: Jun Takahashi.

Supervision: Jun Takahashi.

Writing – original draft: Masashi Uehara.

Writing – review & editing: Shota Ikegami, Shugo Kuraishi, Hiroki Oba, Takashi Takizawa, Ryo Munakata, Terue Hatakenaka, Michihiko Koseki, Jun Takahashi.

References

- [1] Luk KD, Cheung KM, Lu DS, Leong JC. Assessment of scoliosis correction in relation to flexibility using the fulcrum bending correction index. *Spine* 1998;23:2303–7.
- [2] Hamzaoglu A, Talu U, Tezer M, Mirzanli C, Domanic U, Goksan SB. Assessment of curve flexibility in adolescent idiopathic scoliosis. *Spine* 2005;30:1637–42.
- [3] Chen ZQ, Wang CF, Bai YS, et al. Using precisely controlled bidirectional orthopedic forces to assess flexibility in adolescent idiopathic scoliosis: comparisons between push-traction film, supine side bending, suspension, and fulcrum bending film. *Spine* 2011;36:1679–84.
- [4] Hiresko MT. Clinical practice. Idiopathic scoliosis in adolescents. *N Engl J Med* 2013;368:834–41.
- [5] Takahashi J, Ikegami S, Kuraishi S, Shimizu M, Futatsugi T, Kato H. Skip pedicle screw fixation combined with Ponte osteotomy for adolescent idiopathic scoliosis. *Eur Spine J* 2014;23:2689–95.
- [6] Uehara M, Takahashi J, Kuraishi S, et al. Computer-assisted skip pedicle screw fixation for adolescent idiopathic scoliosis. *J Orthop Sci* 2017;22:218–23.
- [7] Uehara M, Takahashi J, Ikegami S, et al. Mid-term results of computer-assisted skip pedicle screw fixation for patients with Lenke type 1 and 2 adolescent idiopathic scoliosis: a minimum five-year follow-up study. *J Orthop Sci* 2018;23:248–52.
- [8] Takahashi J, Newton PO, Ugrinow VL, Bastrom TP. Selective thoracic fusion in adolescent idiopathic scoliosis: factors influencing the selection of the optimal lowest instrumented vertebra. *Spine* 2011;36:1131–41.
- [9] Bunnell WP. An objective criterion for scoliosis screening. *J Bone Joint Surg Am* 1984;66:1381–7.
- [10] Kanda Y. Investigation of the freely available easy-to-use software 'EZR' for medical statistics. *Bone Marrow Transplant* 2013;48:452–8.
- [11] Pizones J, Sánchez-Mariscal F, Zúñiga L, Izquierdo E. The effect of sublaminar wires on the rib hump deformity during scoliosis correction manoeuvres. *Eur J Ortho Surg Traumatol* 2016;26:771–7.
- [12] Shah SA, Dhawale AA, Odda JE, et al. Ponte osteotomies with pedicle screw instrumentation in the treatment of adolescent idiopathic scoliosis. *Spine Deform* 2013;1:196–204.
- [13] Pizones J, Sánchez-Mariscal F, Zúñiga L, Izquierdo E. Ponte osteotomies to treat major thoracic adolescent idiopathic scoliosis curves allow more effective corrective maneuvers. *Eur Spine J* 2015;24:1540–6.
- [14] Mediouni M, R. Schlatterer D, Madry H, Cucchiarini M, Rai B. A review of translational medicine. The future paradigm: how can we connect the orthopedic dots better? *Curr Med Res Opin* 2018;34:1217–29.