

Tumefactive inflammatory lesions in juvenile metachromatic leukodystrophy

Kolja Meier, MD, Jutta Gärtner, MD, and Peter Huppke, MD

Neurol Neuroimmunol Neuroinflamm 2021;8:e922. doi:10.1212/NXI.0000000000000922

Correspondence

Dr. Huppke
phuppke@med.uni-goettingen.de

Juvenile metachromatic leukodystrophy (MLD) is caused by autosomal recessive defects in the *ARSA* gene coding for arylsulfatase A. Clinically, it is characterized by slowly progressive ataxia, spasticity, cognitive decline, and behavioral disturbances starting at age 4–10 years. White matter abnormalities are often first seen in the corpus callosum subsequently extending into the periventricular regions with a diffuse symmetrical pattern.

Results

We report on a previously healthy girl who first presented with a focal seizure affecting the left arm and the left side of the face at age 5 years. On admission, mild left-sided ataxia and clumsiness were noted. Cranial MRI showed a large contrast-enhancing lesion in the right somatosensory cortex, suggestive of acute disseminated encephalomyelitis (ADEM) (figure, A and B). Retrospectively, subtle white matter abnormalities of the corpus callosum and the bilateral periventricular white matter were present at the time (figure, G). CSF analysis demonstrated no pleocytosis but elevated protein (415 mg/L). Oligoclonal bands, myelin oligodendrocyte glycoprotein, and aquaporin-4 antibodies were negative. Steroid treatment led to clinical improvement, and cranial MRI after 14 days showed regression of the lesion. The following 6 months, she suffered 2 further attacks, both responsive to steroids, 1 with right-sided facial paresis and a left precentral lesion (figure, C and D) and 1 with headaches and clumsiness with a mesencephalic lesion (figure, E and F). Only after the third attack, the girl developed the typical symptoms of juvenile MLD with a progressive cognitive decline and behavioral problems. Within 6 months, she was not able to attend school anymore. Clinical examination at age 7 demonstrated ataxia, pyramidal signs, and an IQ of 70 (Wechsler Intelligence scale). MRI showed progressive bilateral periventricular T2-hyperintensities with a tigroid pattern typical of MLD (figure, H). Analysis of arylsulfatase A activity (30.4 nmol/h × mg; Ref 31–151) and genetic testing of the *ARSA* gene (compound heterozygosity for variants c.1283C>T and c.684+1G>A) confirmed the diagnosis. No further episodes with inflammatory lesions have occurred since, but her MLD symptoms have continued to progress.

Discussion

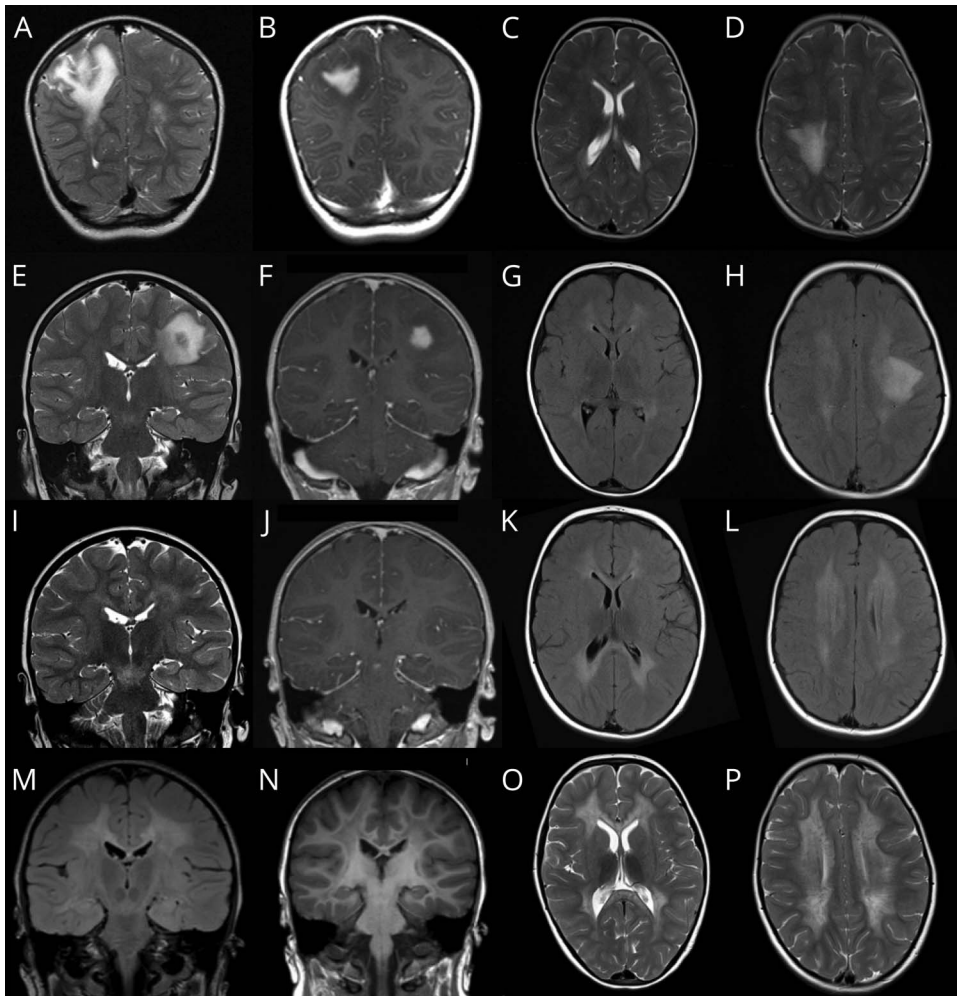
We describe a juvenile MLD patient, who initially presented with 3 attacks of an acute inflammatory demyelinating disorder. Review of the literature revealed that 3 very similar cases have been reported. The first patient, a girl aged 6 years, was diagnosed with MLD after she developed a gait disturbance. Her condition remained stable for 1 year before she experienced 4 further episodes with focal seizures, vertigo, diplopia, headaches, and loss of consciousness.¹ MRI demonstrated tumefactive contrast-enhancing lesions in the cerebrum and mesencephalon very similar to the lesions seen in our patient. The second patient presented at age 5 years with acute left-sided hemiparesis to our clinic.¹ MRI showed a tumefactive lesion in the right centrum semiovale. Two years later, he developed symptoms typical of juvenile MLD. The

From the Department of Pediatrics and Adolescent Medicine, Pediatric Neurology, University Medical Center Göttingen, Georg August University, Germany.

Go to [Neurology.org/NN](https://www.neurology.org/NN) for full disclosures. Funding information is provided at the end of the article.

The Article Processing Charge was funded by the University Medical Center Göttingen.

This is an open access article distributed under the terms of the Creative Commons Attribution-NonCommercial-NoDerivatives License 4.0 (CC BY-NC-ND), which permits downloading and sharing the work provided it is properly cited. The work cannot be changed in any way or used commercially without permission from the journal.



(A–D) MRI images at the first attack at age 5 years showing a right-sided tumefactive lesion with contrast enhancement and subtle white matter abnormalities in the corpus callosum and periventricular regions; (E–H) MRI images demonstrating a left-sided tumefactive lesion with contrast enhancement 4 months later; (I–L) MRI images at the third attack 2 months later showing a demyelinating mesencephalic lesion with contrast enhancement and progressive leukodystrophy; (M–P) MRI images at age 7 years showing the typical tigroid pattern of MLD. (A, C, D, E, I, O, P) T2-weighted images; (B, F, J) T1-weighted images after gadolinium administration, and (N) without gadolinium; (G, H, K, L) flair-weighted images. MRD = metachromatic leukodystrophy.

third case, a girl, developed an acute flaccid left-sided hemiparesis and a focal seizure at age 4 years.² Cranial MRI demonstrated a tumefactive contrast-enhancing right occipital lesion, and brain biopsy was compatible with a demyelinating disorder. During the following 10 months, 3 further severe demyelinating attacks occurred. MRI in the symptom-free interval between the third and fourth attack already demonstrated periventricular white matter hyperintensity. Symptoms typical of juvenile MLD occurred 2 years after the first demyelinating attack.

Demyelinating attacks with single tumefactive lesions are very rare in childhood. In fact, brain tumors, which were initially suspected in 3 of the patients including the one presented here, are more common in this age group. A recent review yielded only 79 published cases with tumefactive demyelinating lesions.³ The most frequent childhood demyelinating disorders, MS, neuromyelitis optica spectrum disorders, and ADEM, typically present with multifocal lesions. Because both MLD (1 per 100,000 live births in Europe) and tumefactive lesions are extremely rare, it seems

unlikely that the co-occurrence is a coincidence. One may speculate that the developing MLD exposes epitopes that trigger an immune reaction. Interestingly, the cerebral form of adrenoleukodystrophy, also characterized by large contrast enhancing lesions, and ADEM, the most common demyelinating disorder in childhood, also most commonly manifest at age 3–8 years, possibly reflecting a vulnerable phase in development of either the brain or the immune system.

Recently, it has been reported that allogeneic hematopoietic stem cell transplantation and hemopoietic stem-cell gene therapy can lead to stabilization of MLD.^{4,5} However, only patients who are treated presymptomatically or in the very early stages of the disease profit from these interventions. In 3 of the patients, the demyelinating events preceded the onset of MLD symptoms by 1–2 years, and in the fourth patient, only a gait disturbance was present. Knowledge of the rare occurrence of tumefactive lesions in early MLD might allow a timely diagnosis and therapy in some patients.

Study funding

No targeted funding reported.

Disclosure

The authors report no disclosures relevant to the manuscript. Go to [Neurology.org/NN](https://www.neurology.org/NN) for full disclosures.

Publication history

Received by *Neurology: Neuroimmunology & Neuroinflammation* August 18, 2020. Accepted in final form October 12, 2020.

References

1. Anlar B, Wayne JS, Eng B, Oguz KK. Atypical clinical course in juvenile metachromatic leukodystrophy involving novel arylsulfatase A gene mutations. *Dev Med Child Neurol* 2006;48:383–387.
2. Kaufman M. Juvenile metachromatic leukodystrophy mimicking relapsing-remitting multiple sclerosis. *Int J MS Care* 2006;8:141–143.
3. Perez CA, Patnaik A, Oommen S, Redko A, Mathis SB. Tumefactive demyelinating lesions in children: a rare case of conus medullaris involvement and systematic review of the literature. *J Child Neurol* 2020;35:690–699.
4. Groeschel S, Kuhl JS, Bley AE, et al. Long-term outcome of allogeneic hematopoietic stem cell transplantation in patients with juvenile metachromatic leukodystrophy compared with nontransplanted control patients. *JAMA Neurol* 2016;73:1133–1140.
5. Sessa M, Lorioli L, Fumagalli F, et al. Lentiviral haemopoietic stem-cell gene therapy in early-onset metachromatic leukodystrophy: an ad-hoc analysis of a non-randomised, open-label, phase 1/2 trial. *Lancet* 2016;388:476–487.

Appendix Authors

Name	Location	Contribution
Kolja Meier, MD	University Medical Center Göttingen, Germany	Analyzed the data and drafted the manuscript for intellectual content
Jutta Gärtner, MD	University Medical Center Göttingen, Germany	Interpreted the data and revised the manuscript for intellectual content
Peter Huppke, MD	University Medical Center Göttingen, Germany	Analyzed the data and drafted the manuscript for intellectual content