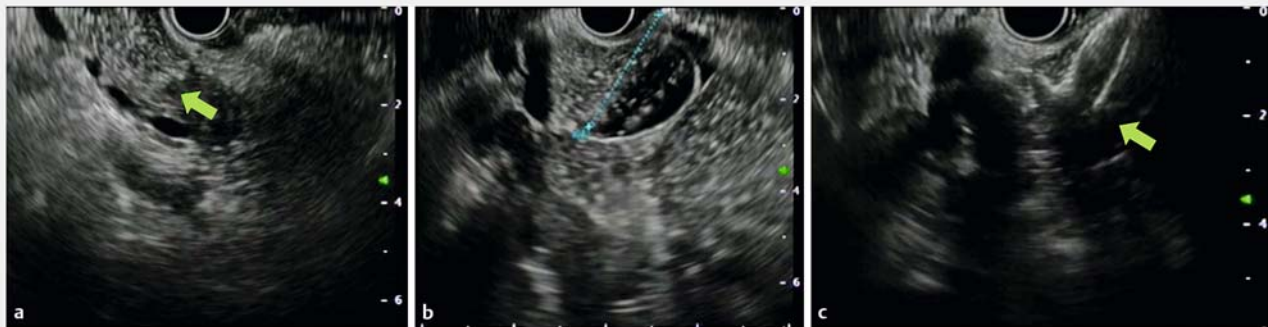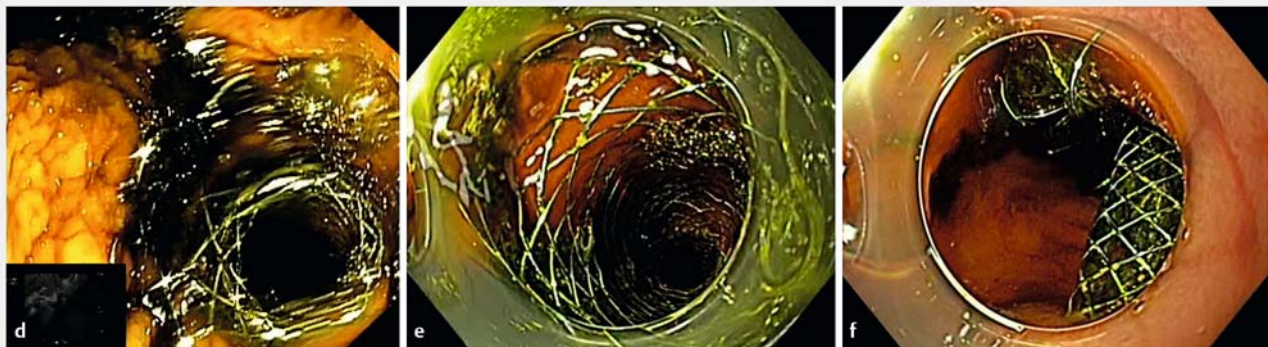


Endoscopic ultrasound-guided choledochoduodenostomy with pyloric occlusion by proximal flange of electrocautery-enhanced lumen-apposing metal stent: solving a rare adverse event

OPEN
ACCESS



► **Fig. 1** Ultrasonographic view of the lesion. **a** Hypoechoic lesion infiltrating the biliary tract. **b** Dilated bile duct. **c** Endoscopic ultrasound-guided choledochoduodenostomy.



► **Fig. 2** Endoscopic view of the lumen-apposing metal stent (LAMS). **d** Transpyloric release of the metal stent into the stomach. **e** Proximal flange pushed through the pylorus. **f** The LAMS pushed into the duodenal bulb.

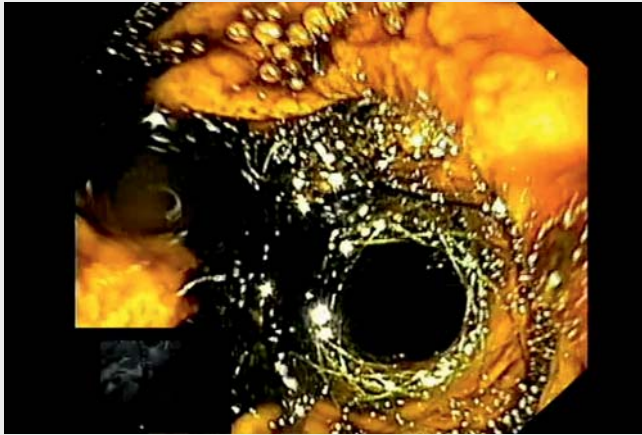
An 80-year-old woman presented to our emergency room with jaundice, nausea, and vomiting. An abdominal tomography revealed intrahepatic biliary ducts and common bile duct (CBD) dilation because of an inhomogeneous hypoechoic mass of 2×1.5 cm in its distal part and an absence of distant metastases. After a multidisciplinary case discussion it was decided to perform an endoscopic ultrasound-guided fine needle biopsy (EUS-FNB) of the mass and drainage of the CBD.

With a linear echoendoscope (GF-UCT 180; Olympus, Tokyo, Japan), we ob-

served an 18×20-mm hypoechoic lesion infiltrating the biliary tract responsible for an upstream dilation of the CBD up to 22 mm. A 22-gauge fine-needle-biopsy needle (Acquire Endoscopic Biopsy Device, Boston Scientific, Marlborough, Massachusetts, USA) was used to perform a biopsy with macroscopic on-site evaluation of the specimen [1]. Histology revealed a cholangiocarcinoma.

An endoscopic retrograde cholangiopancreatography (ERCP) was unsuccessful. We decided to perform an EUS-guided choledochoduodenostomy using an electrocautery-enhanced lumen-appos-

ing metal stent (LAMS) (8×20-mm Hot SPAXUS; Taewoong Medical, Gyeonggi-do, South Korea) from the duodenal bulb with the intrachannel release of the proximal flange (► **Fig. 1**) [2]. An efficient bile flow was immediately observed through the stent. However, the proximal flange was released transpylorically into the stomach, covering the pylorus completely. With a gastroscope with a preloaded smooth cap, we gently pushed the proximal flange through the pylorus into the duodenal bulb, replacing the proximal flange inside the duodenum (► **Fig. 2**, ► **Video 1**).



Video 1 Endoscopic ultrasound-guided choledochoduodenostomy with pyloric occlusion by the proximal flange of an electrocautery-enhanced lumen-apposing metal stent: how to solve a rare adverse event.

This is a possible complication that can be encountered during EUS-guided drainage, especially if the proximal flange release is performed inside the operative channel of the scope. A soft electrocautery-enhanced LAMS, such as the Hot SPAXUS [3], allows easy management of this rare adverse event [4–5].

Endoscopy_UCTN_Code_TTT_1AS_2AG

Competing interests

The authors declare that they have no conflict of interest.

The authors

Danilo Paduano¹, **Francesco Auriemma**¹, **Federica Spatola**¹, **Laura Lamonaca**¹, **Alessandro Repici**^{2,3}, **Benedetto Mangiavillano**^{1,3}

- 1 Gastrointestinal Endoscopy Unit, Humanitas Mater Domini, Castellanza, VA, Italy
- 2 Endoscopy Unit, Humanitas Clinical and Research Center IRCCS, Rozzano, Milan, Italy
- 3 Department of Biomedical Sciences, Humanitas University, Rozzano, Milan, Italy

Corresponding author

Danilo Paduano, MD

Gastrointestinal Endoscopy Unit, Humanitas Mater Domini, Via Gerenzano, 2, 21053 Castellanza VA, Italy
danilo.paduano@libero.it

References

- [1] Mangiavillano B, Frazzoni L, Togliani T et al. Macroscopic on-site evaluation (MOSE) of specimens from solid lesions acquired during EUS-FNB: multicenter study and comparison between needle gauges. *Endosc Int Open* 2021; 9: E901–E906
- [2] Yoo HW, Moon JH, Jo SJ et al. A novel electrocautery-enhanced delivery system for one-step endoscopic ultrasound-guided drainage of the gallbladder and bile duct using a lumen-apposing metal stent: a feasibility study. *Endoscopy* 2021; 53: 922–926
- [3] Mangiavillano B, Moon JH, Crinò SF et al. Safety and efficacy of a novel electrocautery-enhanced lumen-apposing metal stent in interventional EUS procedures (with video). *Gastrointest Endosc* 2022; 95: 115–122
- [4] Amato A, Sinagra E, Celsa C et al. Efficacy of lumen-apposing metal stents or self-expandable metal stents for endoscopic ultrasound-guided choledochoduodenostomy: a systematic review and meta-analysis. *Endoscopy* 2021; 53: 1037–1047

- [5] Teoh AYB, Kongkam P, Bapaye A et al. Use of a novel lumen apposing metallic stent for drainage of the bile duct and gallbladder: long term outcomes of a prospective international trial. *Dig Endosc* 2021; 33: 1139–1145

Bibliography

Endoscopy 2022; 54: E918–E919

DOI 10.1055/a-1866-3459

ISSN 0013-726X

published online 5.7.2022

© 2022. The Author(s).

This is an open access article published by Thieme under the terms of the Creative Commons Attribution-NonDerivative-NonCommercial License, permitting copying and reproduction so long as the original work is given appropriate credit. Contents may not be used for commercial purposes, or adapted, remixed, transformed or built upon. (<https://creativecommons.org/licenses/by-nc-nd/4.0/>)

Georg Thieme Verlag KG, Rüdigerstraße 14, 70469 Stuttgart, Germany



ENDOSCOPY E-VIDEOS

<https://eref.thieme.de/e-videos>



Endoscopy E-Videos is an open access online section, reporting on interesting cases and new techniques in gastroenterological endoscopy. All papers include a high quality video and all contributions are freely accessible online. Processing charges apply (currently EUR 375), discounts and waivers acc. to HINARI are available.

This section has its own submission website at <https://mc.manuscriptcentral.com/e-videos>