Hitesh Mistry, PhD
Eliana Vasquez Osorio, PhD
Division of Cancer Science
University of Manchester
Manchester, United Kingdom

Alan McWilliam, PhD
Ananya Choudhury, PhD
Division of Cancer Science
University of Manchester
Manchester, United Kingdom
Christie Medical Physics & Engineering
The Christie NHS Foundation Trust
Manchester, United Kingdom

Marianne Aznar, PhD
Marcel van Herk, PhD
Andrew Green, PhD
Division of Cancer Science
University of Manchester
Manchester, United Kingdom

https://doi.org/10.1016/j.ijrobp.2021.10.154

References

1. Shortall J, Palma G, Mistry H, et al. Flogging a dead salmon? Reduced dose posterior to prostate correlates with increased PSA progression in voxel-based analysis of 3 randomized phase 3 trials. *Int J Radiat Oncol Biol Phys* 2021;110:696–699.
2. Marcello M, Denham JW, Kennedy A, et al. Reduced dose posterior to prostate correlates with increased PSA progression in voxel-based analysis of 3 randomised phase 3 trials. *Int J Radiat Oncol Biol Phys* 2020;108:1304–1318.
3. Ebert MA, Marcello M, Haworth A, et al. In regard to Shortall et al. *Int J Radiat Oncol Biol Phys* 2022;112:831–833.
4. Bennett C, Miller M, Wolford G. Neural correlates of interspecies perspective taking in the post-mortem Atlantic Salmon: An argument for multiple comparisons correction. *Neuroimage* 2009;47:S125.
5. Witte MG, Heemsbergen WD, Bohoslavsky N, et al. Relating dose outside the prostate withfreedome from failure in the Dutch trial 68 Gy vs. 78 Gy. *Radiat Oncol Biol* 2010;77:131–138.
6. Chen C, Witte M, Heemsbergen W, van Herk M. Multiple comparisons permutation test for image based data mining in radiotherapy. *Radiat Oncol* 2013;8:293.
7. Green A, Vasquez Osorio E, Aznar MC, McWilliam A, van Herk M. Image-based data mining using per-voxel Cox regression. *Front Oncol* 2020;10:1178.
8. Cella L, Monti S, Xu T, et al. Probing thoracic dose patterns associated to pericardial effusion and mortality in patients treated with photons and protons for locally advanced non-small-cell lung cancer. *Radiother Oncol* 2021;160:148–158.
9. McWilliam A, Kennedy J, Hodgson C, Osorio EV, Faivre-Finn C, van Herk M. Radiation dose to heart base linked with poorer survival in lung cancer patients. *Eur J Cancer* 2017;85:106–113.
10. van Herk M. Errors and margins in radiotherapy. *Semin Radiat Oncol* 2004;14:52–64.
11. Palma G, Monti S, Cella L. Voxel-based analysis in radiation oncology: A methodological cookbook. *Phys Med* 2020;69:192–204.

Radiation Recall After COVID-19 Vaccine Booster

In Regard to Soyfer et al.

Three cases of radiation recall phenomenon (RRP) after COVID-19 vaccination have been reported in the *International Journal of Radiation Oncology, Biology, Physics.* All reported cases to date have followed the first or second dose in the vaccination series and have had a 5- to 7-day onset after vaccination. Within our practice, we observed a case of a delayed radiation recall reaction 28 days after the third dose of the Pfizer BioNTech vaccine.

Soyfer et al[1] described 2 patients developing RRP dermatitis after their second dose of Pfizer-BioNTech; 1 patient experienced RRP 5 days after their second vaccination and 66 days after their most recent radiation therapy (RT), and the other experienced RRP 6 days after vaccination and 22 days after RT. Stewart and McDowell[2] described RRP dermatitis after the AstraZeneca vector vaccine, with rapid onset 3 hours after the first dose and occurring 6 months after RT. Additional cases have been reported: Afacan et al[3] reported a case of RRP dermatitis 5 days after initial inoculation with Sinovac and 27 months after RT, and Steber et al[4] noted RRP pneumonitis 3 days after initial vaccination with the Moderna mRNA vaccine, approximately 8 months after RT. The SARS-CoV-2 virus itself may induce similar effects: Kurosaki et al, for instance, have reported an RRP pneumonitis coinciding with COVID-19 infection, 3.5 years after initial RT.[5]

Our patient is a 46-year-old female who received 60 Gy (RBE) in 30 fractions of adjuvant proton irradiation (Fig. 1) with concurrent cisplatin for American Joint Committee on Cancer 8 pT1N1 p16 tonsillar squamous cell carcinoma, completing treatment June 14, 2021 (Fig. 2). She previously received Pfizer-BioNTech vaccination on March 5, 2021, and March 26, 2021, and received her booster vaccine on September 9, 2021. On 3-month follow-up in late September, she exhibited minimal toxicity, with only xerostomia and mild thrush noted. She experienced a dermatitis flare on her neck on October 7 (28 days after dose 3) after 1 day of low-grade fever, nausea, vomiting, and joint pain. Skin cultures were negative, and she was diagnosed with radiation dermatitis (Fig. 1b-f). She was begun on a 2-week oral steroid regimen.

Case reports with RRP remain limited, although both dermatitis and pneumonitis have been seen after a range of SARS-CoV-2 vaccinations, timing, and tumor histologies. This case appears to be the first involving RRP after booster vaccination for SARS-CoV-2 and the first report involving proton irradiation, with delayed development of RRP after vaccination.

Disclosures: none.

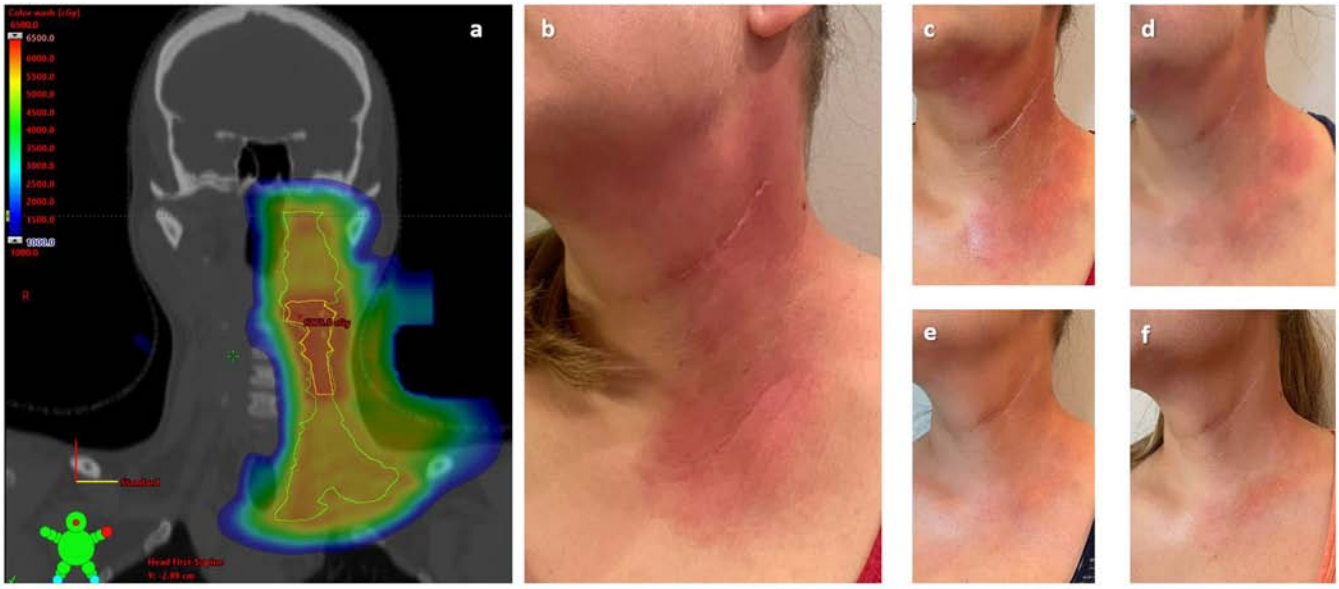

Fig. 1. (a) Radiation treatment plan, 60 Gy (RBE-1.1) in 30 fractions proton radiation, with (b-f) resultant radiation recall phenomenon skin changes noted.

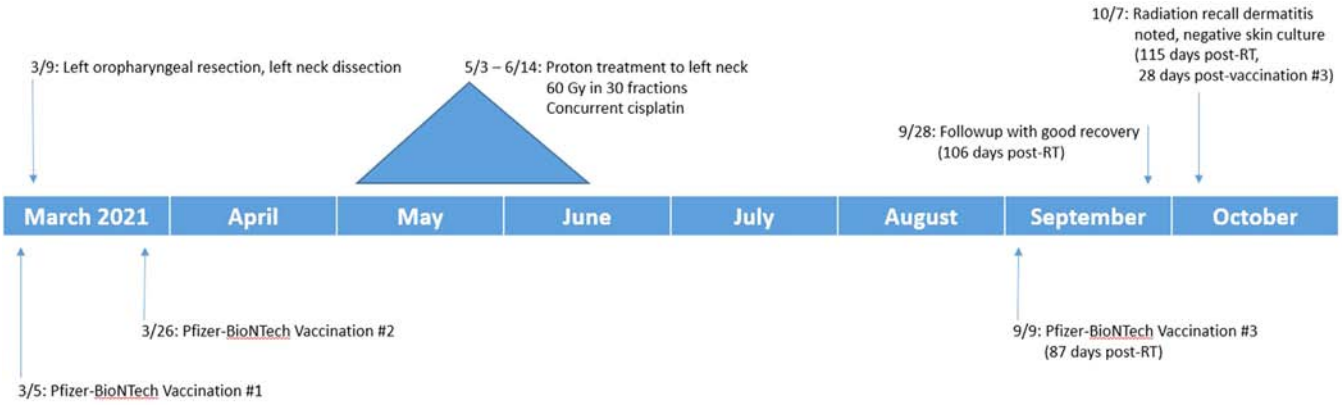

Fig. 2. Patient treatment time course.

Daniel K. Ebner, MD, MPH
Connie S. Geno, APRN, CNP
Daniel J. Ma, MD
Department of Radiation Oncology
Mayo Clinic
Rochester, Minnesota

https://doi.org/10.1016/j.ijrobp.2021.11.005

References

1. Soyfer V, Gutfeld O, Shamai S, Schlocker A, Merimsky O. COVID-19 vaccine-induced radiation recall phenomenon. *Int J Radiat Oncol Biol Phys* 2021;110:957–961.
2. Stewart R, McDowell L. Radiation Recall Phenomenon Following COVID-19 Vaccination. *Int J Radiat Oncol Biol Phys* 2021;111:835–836.
3. Afacan E, Öğüt B, Üstün P, Şentürk E, Yazıcı O, Adışen E. Radiation recall dermatitis triggered by inactivated COVID-19 vaccine. *Clin Exp Dermatol* 2021;46:1582–1584.
4. Steber CR, Ponnatapura J, Hughes RT, Farris MK. Rapid development of clinically symptomatic radiation recall pneumonitis immediately following COVID-19 vaccination. *Cureus* 2021;13:e14303.
5. Kurosaki H, Utsumi N, Miura K. A case of suspected radiation recall pneumonitis after a COVID-19 infection. *Cureus* 2021;13:e13688.

Hyperbaric Oxygen for Prevention of Osteoradionecrosis

In Regard to Shaw et al.

To the Editor: Randomized controlled trials (RCTs) are a reliable form of scientific evidence and strongly influence

Disclosure: G.L. is the director of a hyperbaric facility that treats patients with late radiation tissue injury.