



CASE SERIES

# Subject Satisfaction with Trifarotene 50 µg/g Cream in the Treatment of Facial and Truncal Acne Vulgaris: A Case Series

Sandra M. Johnson · Rajeev Chavda · Janet C. DuBois

Received: June 1, 2020 / Published online: July 4, 2020  
© The Author(s) 2020

## ABSTRACT

There is a paucity of literature covering patient-reported outcomes of treatments for truncal acne. Trifarotene 50 µg/g cream is a novel retinoid molecule approved for once-daily topical treatment of facial and truncal acne vulgaris. As physicians are starting to gain real-world experience with this retinoid treatment, their access to reporting from the patient's perspective provides a valuable adjunct to the pivotal studies. We report a case series of three subjects with moderate facial and truncal acne treated with trifarotene 50 µg/g cream on the face, shoulders, upper back and upper anterior chest for 12 weeks and evaluated by satisfaction questionnaires. This case series illustrating the treatment of facial and truncal acne with trifarotene 50 µg/g cream, in the form of real-world data, describes high overall satisfaction and excellent tolerability to support the use of

this new retinoid molecule in the treatment of acne vulgaris on both the face and trunk.

**Keywords:** Acne; Case series; Facial; Retinoid; Trifarotene; Truncal

### Key Summary Points

#### Why carry out this study?

There is a paucity of literature covering patient-reported outcomes of treatments for truncal acne.

Topical trifarotene 50 µg/g cream is a new retinoid molecule specifically developed and approved for both facial and truncal acne vulgaris.

This case series describes three subjects treated with trifarotene 50 µg/g cream on their face, chest and back for 12 weeks.

#### What was learned from the study?

The results with trifarotene 50 µg/g cream demonstrate high overall subject satisfaction and excellent tolerability to support the use of this newly approved treatment for both facial and truncal acne vulgaris.

**Digital Features** To view digital features for this article go to <https://doi.org/10.6084/m9.figshare.12535697>.

S. M. Johnson (✉)  
Johnson Dermatology, Fort Smith, AR, USA  
e-mail: drsandy@johnsondermatology.com

R. Chavda  
Galderma SA, La Tour-de-Peilz, Switzerland

J. C. DuBois  
DermResearch, Inc., Austin, TX, USA

## INTRODUCTION

Acne vulgaris, predominantly found on the face and upper trunk region, is one of the most common skin diseases and has a considerable impact on quality of life (QoL; see Claudel et al. 2019 for a recent review [1]). In a referral cohort of 965 patients with acne, Tan et al. reported that the prevalence of acne on the face, chest and back was 92, 45 and 61%, respectively [2]. However, patients appear to be less likely to report truncal acne on initial appointments for evaluation of acne. In a US study in acne patients, Del Rosso et al. found that around a quarter of patients who presented with both facial and truncal acne did not voluntarily mention the presence of truncal acne, which was detected only after clinical examination [3]. Regardless of whether or not they mentioned it as part of their chief complaint, more than 75% of them desired treatment for their truncal acne [3]. Tan et al. also noted that patient reporting was consistent with the clinical evaluation in 92% of cases for facial acne, but only in around 70% of cases for truncal acne [2]. There is a paucity of literature covering patient-reported outcomes of treatments for truncal acne [4].

Retinoids are widely used in the management of acne [5–7]. Topical trifarotene (AKLIEF® Cream 0.005%; Galderma) is the first new retinoid molecule approved in the USA in over 20 years for the once-daily topical treatment of acne vulgaris [8–10]. Trifarotene 50 µg/g cream first received approval in the USA in October 2019, followed by Canada in November 2019 and Europe in December 2019. Trifarotene is a potent and selective retinoic acid receptor (RAR)- $\gamma$  agonist [9]. An improved safety profile is predicted with trifarotene since, *in vitro*, it is active and stable in cultured keratinocytes but rapidly metabolized by human hepatic microsomes [8]; in addition, clinical pharmacology data demonstrate low systemic absorption of trifarotene 50 µg/g cream when applied daily under maximal use conditions [11]. Previously developed retinoids were evaluated only in facial acne and not truncal acne, possibly due to safety concerns about treating a large area or a lack of consideration for truncal acne and its

prevalence. Trifarotene 50 µg/g cream was evaluated in both moderate facial and truncal acne in two large-scale, randomized, double-blind, vehicle-controlled studies and one long-term safety study [10, 12]. As physicians have had little real-world experience with its qualities, reporting from the patient's perspective provides a valuable adjunct to the results of these pivotal studies.

Here we report a case series of three subjects drawn from a larger ongoing study evaluating subject satisfaction with 12 weeks of treatment with trifarotene 50 µg/g cream on both the face and trunk.

## METHODS

In this case series drawn from an interim 12-week analysis that is part of a larger ongoing 24-week study, the three subjects had moderate acne vulgaris with facial and truncal acne vulgaris at baseline with  $\geq 20$  inflammatory lesions and  $\geq 25$  non-inflammatory lesions on the face, in addition to  $\geq 20$ –100 inflammatory lesions and  $\geq 20$  non-inflammatory lesions on the trunk (shoulders, upper back and upper anterior chest). The subjects were instructed to apply trifarotene 50 µg/g cream once daily in the evening after washing. Each subject was given both oral and written instructions on the proper dosing and how to apply a thin layer of trifarotene 50 µg/g cream on the facial region (one pump actuation) and the trunk (two actuations), corresponding to the amounts in the Summary of Product Characteristics [13]. To reduce any irritation and enhance compliance, the subjects were encouraged to use a cleanser and moisturizer (Cetaphil®; Galderma), as well as a non-comedogenic sunscreen; additionally, the physician could institute an alternate day regimen application for a maximum of 2 weeks during the first 4 weeks. Any previous acne vulgaris treatments within the previous 6 months were recorded, and a wash-out period of at least 2 weeks was applied before the start of the study in the case of topical treatments (4 weeks if retinoids) on the face and trunk.

Subjects were asked to complete subject satisfaction questionnaires after 12 weeks of

treatment. Also, the Dermatology Life Quality Index (DLQI) for those aged  $\geq 17$  years and the children's Dermatology Life Quality Index (c-DLQI) for those aged  $\leq 16$  years were completed before and after 12 weeks of treatment.

All adverse events were recorded, and local tolerability (erythema, scaling, dryness, stinging/burning) was assessed using a 4-point scale from none (0) to severe (3).

To standardize acne assessment on the trunk, the trunk anatomic area was delimited using a size-fitted T-shirt. Before and after 12 weeks of treatment, facial photographs were taken under visible light conditions using a stereotactic device (VISIA®-CR imaging system; Canfield Scientific, Parsippany, NJ, USA), and truncal photographs were taken using IntelliStudio® digital imaging system (Canfield Scientific).

All subjects, or their parent or guardian, provided written informed consent before participating in the study; ethics committee and/or institutional review board approval were obtained (IntegReview meeting held on 18 February 2019); and the study was performed in accordance with the Helsinki Declaration of 1964, and its later amendments. All data were deidentified. All subjects, or their parent or guardian, have provided written informed consent for publication of their clinical details and photographs.

## RESULTS

### Case Study 1

This 16-year-old male with moderate acne and Fitzpatrick skin type II had a history of acne vulgaris for 2.8 years. The cDLQI questionnaire was not completed before he started treatment with trifarotene 50  $\mu\text{g/g}$  cream.

On his satisfaction questionnaire completed after 12 weeks of treatment, he reported being overall satisfied with the treatment for the face and very satisfied with that for the trunk. Concerning the time the treatment took to work, he was satisfied for his face and very satisfied for his trunk. In general, he was very satisfied with how easy it was to use the study treatment.

This subject experienced no treatment-emergent adverse events. When asked whether he was bothered by side effects, he responded: (1) not bothered at all for face and (2) somewhat for trunk (on a 4-point scale). He indicated that he used the provided moisturizing lotion. The subject had no treatment-emergent adverse events and no treatment-associated scaling, dryness or stinging/burning, and erythema was mild (week 1, face only; week 4, face and trunk).

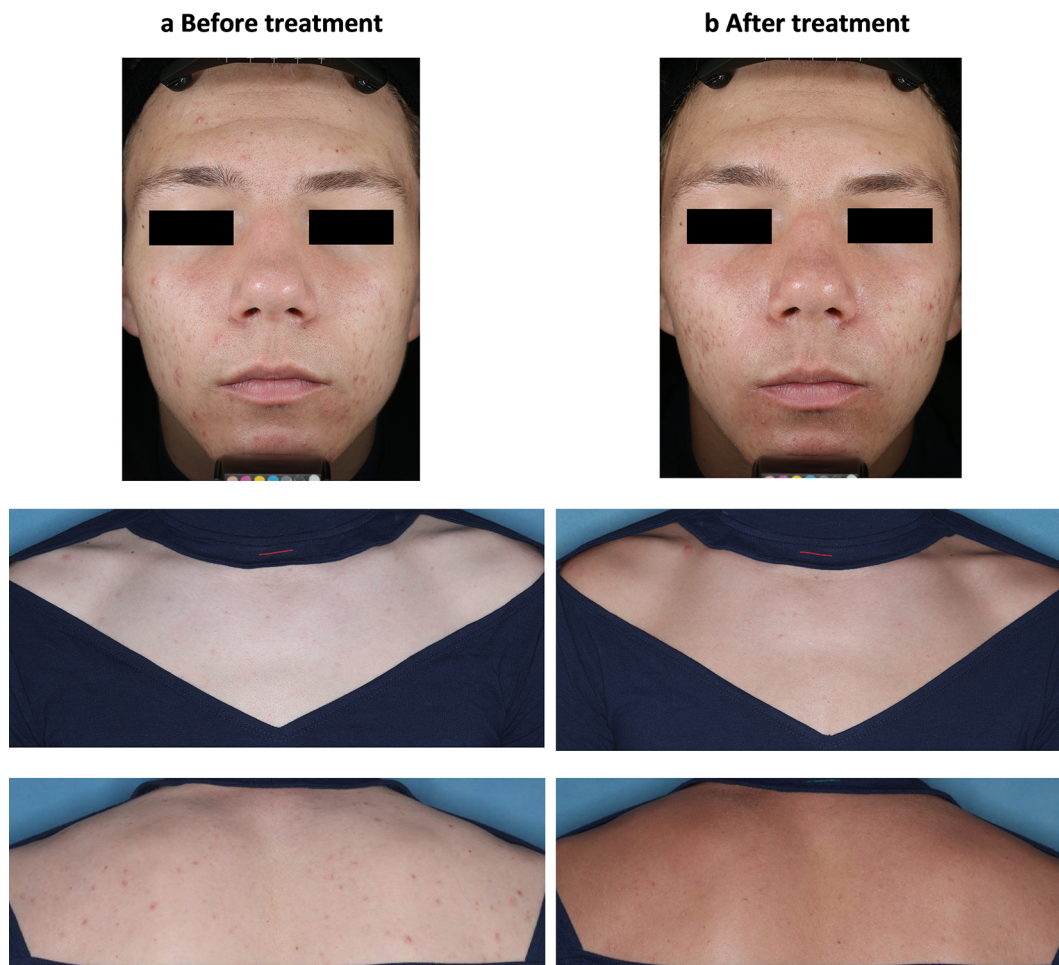
After 12 weeks of treatment with trifarotene 50  $\mu\text{g/g}$  cream, the percentage reductions in total number of lesions on his face and trunk was 90% for inflammatory lesions and 47% for noninflammatory lesions; photographs of this case before and after treatment are shown in Fig. 1.

### Case Study 2

This 17-year-old male with Fitzpatrick skin type II had acne vulgaris for 3.4 years. He had used benzoyl peroxide 8.5% for 3 months within the previous 6 months, but this was stopped 28 days before he started the study. He had a DLQI total score of 3 (small effect of acne on QoL) before treatment and a score of 0 (no effect of acne on QoL) after 12 weeks of treatment.

Questionnaire responses (after 12 weeks of treatment) included being overall satisfied with the treatment on the trunk, very satisfied with the treatment on the face and very satisfied with the time the treatment took to work for both face and trunk. In response to the question "How do you feel about yourself since starting your treatment?", he indicated that he felt a lot better about himself since starting treatment for his face and trunk. In general, he was very satisfied with how easy it was to use the study treatment.

Although he experienced some mild erythema, scaling and dryness on his face and trunk during the first 4 weeks of treatment, the only tolerability parameter that was moderate was erythema on the face and trunk at week 4 and on the face at week 12. However, the results of the satisfaction questionnaire indicate that he was not bothered at all by treatment side effects on his face (response 1) and bothered



**Fig. 1** Case 1: photographs of a 16-year old male subject before (a) and after (b) 12 weeks of treatment with trifarotene 50 µg/g cream on the face and trunk

only somewhat for treatment side effects on his trunk (response 2 on a 4-point scale). He used the provided moisturizer on his face and trunk, which he indicated helped to reduce irritation. The subject had mild dryness at week 1 (face and trunk) and mild scaling at week 1 (trunk) and week 4 (face). He experienced two mild adverse events, both of which were considered to be unrelated to the trifarotene 50 µg/g treatment (transient burning on the upper chest/back for 1 day; sunburn on his shoulders for 8 days).

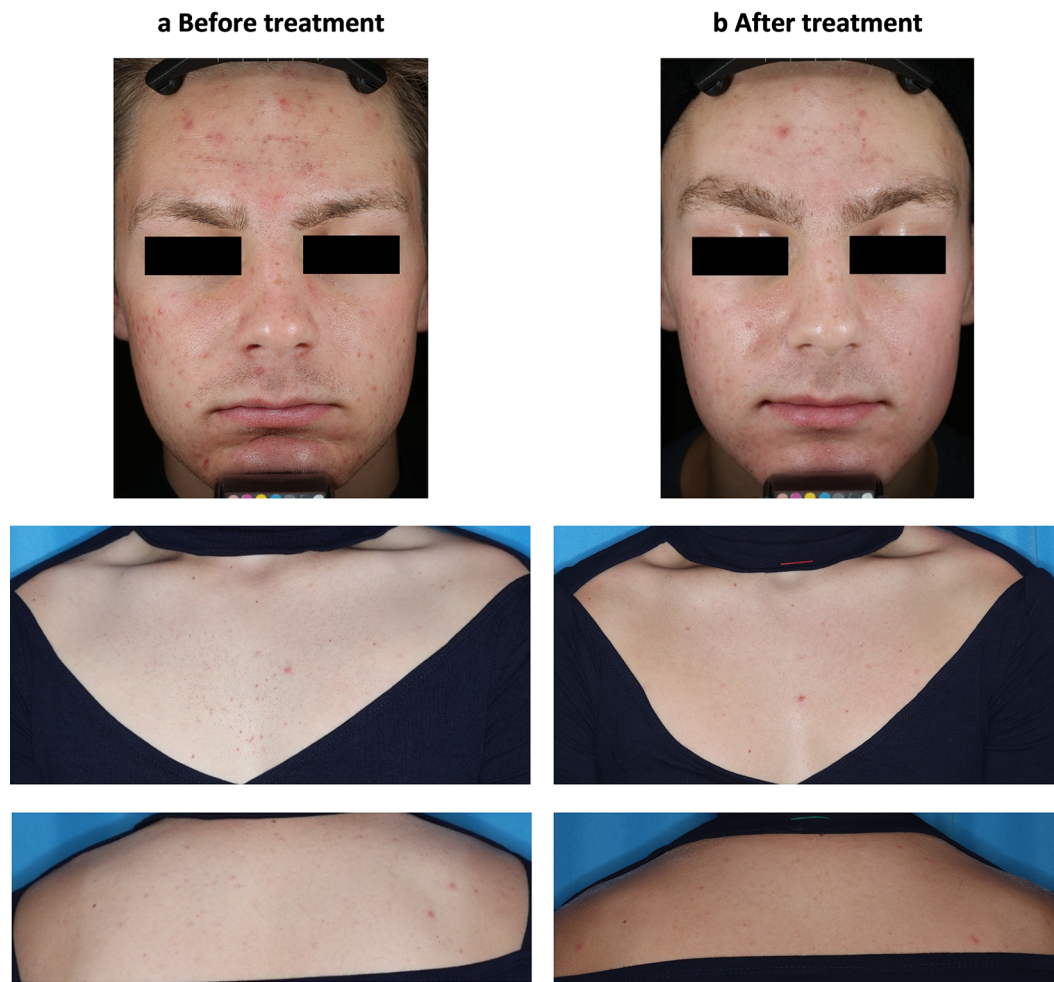
This subject had moderate facial and truncal acne vulgaris at the first assessment (Fig. 2) and achieved a 20% reduction in inflammatory lesions on his face and trunk and 22% reduction

in noninflammatory lesions after 12 weeks of treatment.

### Case Study 3

This 12-year-old female with Fitzpatrick skin type IV and moderate acne had acne for 2.5 years. She had a cDLQI score of 1 at baseline and 0 after 12 weeks of treatment, which can be interpreted as having no effect of acne on quality of life.

According to the satisfaction questionnaire completed at week 12, she indicated that she was satisfied with the treatment overall, satisfied with the time the treatment took to work and satisfied with the effectiveness of the



**Fig. 2** Case 2: photographs of a 17-year old male subject before (a) and after (b) 12 weeks of treatment with trifarotene 50 µg/g cream on the face and trunk

treatment for both the face and trunk. She was generally satisfied with how easy the treatment was to use. In response to the question “How do you feel about yourself since starting your treatment?”, she indicated she felt a lot better about herself since starting her treatment for both the face and trunk. She was bothered somewhat by treatment side effects on both her face and her trunk but indicated she used the provided moisturizer and it helped to reduce irritation on her face and trunk.

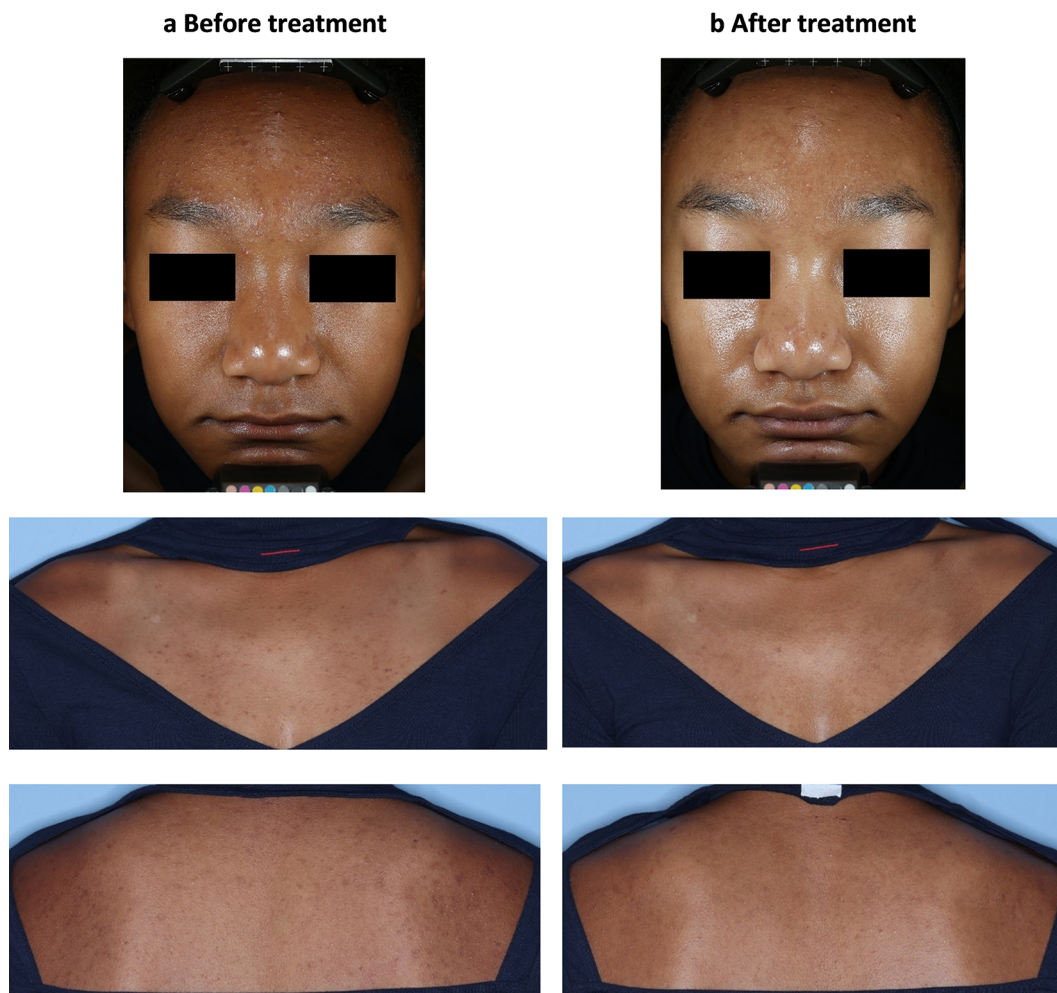
Although this subject had some mild erythema, scaling and dryness on her face and trunk during the first 4 weeks of treatment, the only tolerability parameter that was moderate was stinging/burning and scaling on the face at

week 1. She experienced no treatment-emergent adverse events.

The subject had moderate facial and truncal acne vulgaris before starting treatment (Fig. 3). After 12 weeks of treatment, the percentage reductions in lesions on her face and trunk were 66 and 34% for inflammatory and noninflammatory lesions, respectively.

## DISCUSSION

This case series fills a gap in patient-reported outcome evidence for the treatment of both facial and truncal acne (shoulders, upper back and upper anterior chest) reachable for self-



**Fig. 3** Case 3: photographs of a 12-year-old female subject before (a) and after (b) 12 weeks of treatment with trifarotene 50 µg/g cream on the face and trunk

application. All subjects indicated being overall satisfied with the trifarotene 50 µg/g topical treatment for both the face and trunk, satisfied with how easy it was to use and satisfied with the time the treatment took to work. Case 2 had a subjective improvement in QoL reflected by the DLQI questionnaire scores reported at baseline and after 12 weeks of treatment. Unfortunately, it is difficult to draw any conclusions from the DLQI data as one 16-year-old subject completed the DLQI at baseline instead of the cDLQI and another subject had a very low score even at baseline. Although QoL measures may help capture the patient's perspective, standardized questionnaires, such as the DLQI, may not be very suitable for measuring the QoL

of individual patients as the questions may have little relevance or importance to acne patients.

Trifarotene 50 µg/g cream was very well tolerated by all subjects on both the face and trunk. Interestingly, in this case series, all subjects started treatment at the start of summer (in May–June), and signs of mild sunburn and tanning can be seen in some of the photographs even at baseline, so this was not related to the treatment with trifarotene 50 µg/g cream. For case 2, the mild adverse event of sunburn on his shoulders during the study was also considered as not related to the study treatment due to the pattern of the sunburn mark and the timing of onset. It has been reported that ultraviolet radiation may have an anti-inflammatory role

in acne; however, it can also result in irritation from sunburn. Indeed, avoiding sun exposure was recommended to all subjects, as was appropriate use of non-comedogenic moisturizers with sun protection factor of  $\geq 30$ .

Case 2 was not bothered at all by treatment side effects on his face, despite experiencing moderate erythema. On his questionnaire, he reported that irritation was manageable with the use of the provided noncomedogenic moisturizer and gentle cleanser. As in the large-scale, pivotal studies, the implementation of routine standard skin care and dosing regimen adjustments were encouraged to mitigate any tolerability issues and ensure compliance [10]. All three cases used the provided moisturizing lotion and continued the treatment for the full 12 weeks, highlighting the importance of educating patients on how to manage irritation, which may occur during the first weeks of acne treatment, to improve treatment adherence, efficacy and patient satisfaction [14]. Case 1 had excellent tolerability, and signs and symptoms of irritation were mostly mild in the other two cases. The long-term safety study in 453 subjects, as reported by Blume-Peytavi et al. [12], demonstrated a manageable safety and tolerability profile with slightly better local tolerability on the trunk than on the face and high treatment compliance of 95.3% for both the face and trunk.

After the first 12 weeks of treatment with trifarotene 50  $\mu\text{g/g}$  cream, reductions in lesions, especially inflammatory lesions, were observed for all three cases, and this was visually demonstrated in the clinical photographs. Longer treatment may be expected to yield continuous improvement. In the single-arm, 52-week safety study, the beneficial effects of topical trifarotene on acne symptoms continued to improve after 12 weeks; the percentage of patients who reported a marked or complete improvement of facial acne was 41.4% at week 12, 54.8% at week 26 and 66.6% at week 52 [12]. Furthermore, the use of an applicator to apply medication on hard-to-reach areas of the back might be expected to further improve results for truncal acne.

The main limitation of these preliminary results is the limited number of cases. Although

aggregate results from the larger study will be of interest with respect to treatment efficacy, this case series is relevant to clinical practice as it provides valuable real-world input from the patient's perspective. From the physician's perspective, this paper is important to show that trifarotene 50  $\mu\text{g/g}$  is beneficial for the treatment of facial and truncal acne, and we would also like the readers to know that truncal acne is very common. When evaluating a patient with facial acne, one should also inquire about truncal acne and examine the face, neck, chest and back when performing a physical examination on a patient for acne. Future large-scale studies on trifarotene 50  $\mu\text{g/g}$  are now warranted, when used either as monotherapy or in combination treatment, to further understand individual responses and challenges when treating truncal acne.

## CONCLUSIONS

Truncal acne has been insufficiently studied, and trifarotene is a new retinoid molecule specifically developed and approved for the treatment of both facial and truncal acne. This case series, examining the treatment of facial and truncal acne with trifarotene 50  $\mu\text{g/g}$  cream, describes high overall subject satisfaction and excellent tolerability to support the use of this new retinoid for the treatment of acne vulgaris on both the face and trunk.

## ACKNOWLEDGEMENTS

The authors wish to thank the three subjects.

**Funding.** This study and the Rapid Service Fee were funded by Galderma SA (Lausanne, Switzerland).

**Editorial Assistance.** Editorial assistance in the preparation of this article was provided by Helen Simpson, PhD, of My Word Medical Writing and support for this assistance was funded by Galderma.

**Authorship.** All named authors meet the International Committee of Medical Journal Editors (ICMJE) criteria for authorship for this article, take responsibility for the integrity of the work as a whole, and have given their approval for this version to be published.

**Disclosures.** Sandra M. Johnson has served as a study investigator on acne studies for Casiopea, Gage, and Galderma and has received honoraria from Galderma as a speaker and advisor. Janet C. DuBois has served as a study investigator on acne studies for Boston, Botanic, Dermata, Galderma, Naked Biome, and Valeant. Rajeev Chavda is an employee of Galderma SA.

**Compliance with Ethics Guidelines.** All subjects, or their parent or guardian, provided written informed consent before participating in the study; ethics committee and/or institutional review board approval were obtained (IntegReview meeting held on February 18, 2019); and the study was performed in accordance with the Helsinki Declaration of 1964, and its later amendments. All data were de-identified. All subjects, or their parent or guardian, have provided written informed consent for publication of their clinical details and photographs.

**Data Availability.** The datasets generated during and/or analyzed during this case series study are not publicly available as results from the ongoing, larger study will be available at a later date.

**Open Access.** This article is licensed under a Creative Commons Attribution-NonCommercial 4.0 International License, which permits any non-commercial use, sharing, adaptation, distribution and reproduction in any medium or format, as long as you give appropriate credit to the original author(s) and the source, provide a link to the Creative Commons licence, and indicate if changes were made. The images or other third party material in this article are included in the article's Creative Commons licence, unless indicated otherwise in a credit line to the material. If material is not included

in the article's Creative Commons licence and your intended use is not permitted by statutory regulation or exceeds the permitted use, you will need to obtain permission directly from the copyright holder. To view a copy of this licence, visit <http://creativecommons.org/licenses/by-nc/4.0/>.

## REFERENCES

1. Claudel JP, Auffret N, Leccia MT, Poli F, Dréno B. Acne from the young patient's perspective. *J Eur Acad Dermatol Venereol*. 2020;34(5):942–7.
2. Tan JK, Tang J, Fung K, et al. Prevalence and severity of facial and truncal acne in a referral cohort. *J Drugs Dermatol*. 2008;7(6):551–6.
3. Del Rosso JQ, Bikowski JB, Baum E, et al. A closer look at truncal acne vulgaris: prevalence, severity, and clinical significance. *J Drugs Dermatol*. 2007;6(6):597–600.
4. Poli F, Auffret N, Leccia MT, Claudel JP, Dréno B. Truncal acne, what do we know? *J Eur Acad Dermatol Venereol*. 2020. <https://doi.org/10.1111/jdv.16634>.
5. Leyden J, Stein-Gold L, Weiss J. Why topical retinoids are mainstay of therapy for acne. *Dermatol Ther (Heidelb)*. 2017;7:293–304.
6. Thiboutot DM, Dréno B, Abanmi A, et al. Practical management of acne for clinicians: an international consensus from the Global Alliance to Improve Outcomes in Acne. *J Am Acad Dermatol*. 2018;78(2 Suppl 1):S1–S23.
7. Kassir M, Karagaiah P, Sonthalia S, et al. Selective RAR agonists for acne vulgaris: a narrative review. *J Cosmet Dermatol*. 2020;19(6):1278–83.
8. Aubert J, Piwnica D, Bertino B, et al. Non-clinical and human pharmacology of the potent and selective topical RAR- $\gamma$  agonist trifarotene. *Br J Dermatol*. 2018;179:442–56.
9. Thoreau E, Arlabosse J, Bouix-Peter C, et al. Structure-based design of Trifarotene (CD5789), a potent and selective RAR- $\gamma$  agonist for the treatment of acne. *Bioorg Med Chem Lett*. 2018;28:1736–41.
10. Tan J, Thiboutot D, Popp G, et al. Randomized phase 3 evaluation of trifarotene 50  $\mu$ g/g cream treatment of moderate facial and truncal acne. *J Am Acad Dermatol*. 2019;80(6):1691–9.



11. Wagner N, Benkali K, Alió Sáenz A, Poncet M, Graeber M. Clinical pharmacology and safety of trifarotene, a first-in-class RAR $\gamma$ -selective topical retinoid. *J Clin Pharmacol*. 2020;60(5):660–8.
12. Blume-Peytavi U, Fowler J, Kemény L, et al. Long-term safety and efficacy of trifarotene 50  $\mu$ g/g cream, a first-in-class RAR- $\gamma$  selective topical retinoid, in patients with moderate facial and truncal acne. *J Eur Acad Dermatol Venereol*. 2020;34(1):166–73.
13. US Food and Drug Administration. Summary of product characteristics. [https://www.accessdata.fda.gov/drugsatfda\\_docs/label/2019/211527s000lbl.pdf](https://www.accessdata.fda.gov/drugsatfda_docs/label/2019/211527s000lbl.pdf). Accessed 31 May 2020.
14. Myhill T, Coulson W, Nixon P, Royal S, McCormack T, Kerrouche N. Use of supplementary patient education material increases treatment adherence and satisfaction among acne patients receiving adapalene 0.1%/benzoyl peroxide 2.5% gel in primary care clinics: a multicenter, randomized controlled clinical study. *Dermatol Ther (Heidelb)*. 2017;7(4):515–24.