



## Case report

## The usage of a magnet-powered instrument in the extraction of metallic or magnetic aspirated foreign bodies: A case report

Mehdi Sarafi<sup>a</sup>, Mohsen Rouzrokh<sup>a</sup>, Saeed Sadr<sup>b</sup>, Seyed Alireza Mahdavi<sup>c</sup>,  
Nastaran Sadat Mahdavi<sup>c</sup>, Manoochehr Ebrahimian<sup>a,\*</sup>

<sup>a</sup> Pediatric Surgery Research Center, Research Institute for Children's Health, Shahid Beheshti University of Medical Sciences, Tehran, Iran

<sup>b</sup> Department of Pediatric Pulmonary Diseases, Mofid Children's Hospital, Shahid Beheshti University of Medical Sciences, Tehran, Iran

<sup>c</sup> Anesthesiology Research Center, Shahid Beheshti University of Medical Sciences, Tehran, Iran



## ARTICLE INFO

## Keywords:

Foreign bodies

Respiratory aspiration

Bronchoscopy

Magnets

Magnetics

## ABSTRACT

**Introduction and importance:** The unintended passage of foreign bodies into the airway, is a common problem among children which can lead to death. Prompt diagnosis and extraction of the entrapped object is the key of success in these cases. Unfortunately, in addition to various extraction methods, in some cases the bronchoscopy may not be successful, and exploratory thoracotomy is inevitable.

**Case presentation:** We describe the story of a 7-year-old preschooler boy who was taken to the emergency department complaining the sudden onset of cough and dyspnea. Initial investigations, showed an entrapped oval-shaped object in the right main bronchus. Several conventional bronchoscopic attempts were failed. We used a handmade magnet-powered instrument to extract the object.

**Conclusion:** Using the magnet-powered grasping forceps may be beneficial after repetitive failed attempts in the extraction process of airway foreign bodies. Although there is no specific evidence-based guideline for choosing the best removal technique, we recommend using this technique in round-shaped high weight metallic objects as the first removal technique.

## 1. Introduction

Swallowing foreign bodies in the pediatric population is a challenging problem that may lead to remarkable morbidities or even death. Evaluations indicate that this entity is more common among children under the age of 4 [1]. Although the majority of swallowed objects may pass through the gastrointestinal tract, in some children, the foreign body may enter the airway.

In comparison to adults, children are more susceptible to airway foreign bodies (AFB). This may be due to their underdeveloped and unsynchronized mastication processes [2].

The child may experience the sudden onset of symptoms like coughing, shortness of breath, cyanosis, wheezing, stridor, or choking. These symptoms with a confirmed history of ingested AFB usually mandate immediate intervention. Traditionally, rigid bronchoscopy is the modality of choice for cases with AFB. However, in patients with failure in bronchoscopic treatment, an open exploratory thoracotomy may be inevitable.

Here, we discuss on a 7-year-old child who had swallowed two oblong-shaped magnets, and presented with choking symptoms. After unsuccessful bronchoscopic interventions with ordinary graspers, we used a homemade magnetic trocar to remove the object.

This report has been written in line with the SCARE criteria [3].

## 2. Case presentation

A 7-year-old preschooler boy has been taken to the emergency department complaining of repetitive episodes of cough and cyanosis. His parents mentioned that the boy swallowed two oblong magnets last night, and developed sudden shortness of breath, choking, and skin discoloration. Fortunately, after abdominal thrusts maneuver by his parents, one of the magnets expelled out spontaneously, and the boy recovered immediately.

The patient was conscious and stable at the first impression. His vital signs were within the normal range. Also, blood oxygen saturation was at 97 %. On physical examination, slightly reduced pulmonary sounds

\* Corresponding author.

E-mail address: [manoochehrehbrahimian@sbmu.ac.ir](mailto:manoochehrehbrahimian@sbmu.ac.ir) (M. Ebrahimian).

<https://doi.org/10.1016/j.ijscr.2022.107629>

Received 19 August 2022; Received in revised form 2 September 2022; Accepted 7 September 2022

Available online 10 September 2022

2210-2612/© 2022 The Authors. Published by Elsevier Ltd on behalf of IJS Publishing Group Ltd. This is an open access article under the CC BY-NC-ND license (<http://creativecommons.org/licenses/by-nc-nd/4.0/>).

were detected on the right side. Plain chest x-ray showed a radiopaque oval-shaped artifact occupying proximal parts of the right main bronchus (Fig. 1). The patient was immediately taken to the operating theatre to remove the entrapped object.

After inducing the general anesthesia by volatile agents, a No. 4.0 rigid bronchoscope entered the trachea. The magnet was seen stuck in the right main bronchus. Several attempts were made using various endoscopic graspers such as conventional forceps, retrieval baskets, and Fogarty catheter. Unfortunately, all attempts were unsuccessful. Unhappily, the patient became unstable after bronchoscopic intervention, and O<sub>2</sub> saturation decreased to less than 70 %. Therefore, surgical removal tended to be inevitable due to the patient's unstable condition.

Before the surgery, anesthesiologists used a double-lumen endotracheal tube, ventilating the patient by his left lung. Then, a posterolateral thoracotomy was performed on the right side. The right main bronchus was isolated using a plastic tape. Although a small incision was made through the bronchus exactly on the object, we couldn't find it intra-operatively. Due to prolonged operation time, we decided to finish the procedure without any successful result. After that, the boy was sent to the pediatric intensive care unit (PICU), and monitored carefully. Unexpectedly, the control x-ray showed the foreign body stuck in the left main bronchus, suggesting magnet migration during the surgery (Fig. 2).

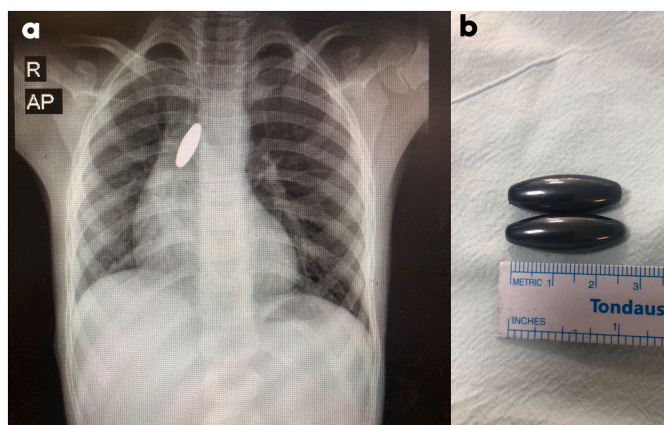
Two days later, the patient returned to the operating room again. This time, we decided to remove the foreign body with the aid of magnetic forceps. Given that no commercial magnet-powered bronchoscopic forceps is available, we decided to use our unique device (Fig. 3, Video 1). We used a plastic tube containing a powerful magnet sealing the tube's entrance. This tube was attached at the end of the bronchoscopic trocar. Also, this tube contains several 4 mm holes in its proximal part to let the air and light pass simultaneously. When this device approaches the metallic object, a magnetic field will change the distribution of electrons in the metal. Finally, this new arrangement of electrons will induce a powerful negative charge, and the object will be attracted to the magnet.

We used this technique properly, and the object was elevated successfully up to the level of cricoid, and then was extracted using conventional forceps.

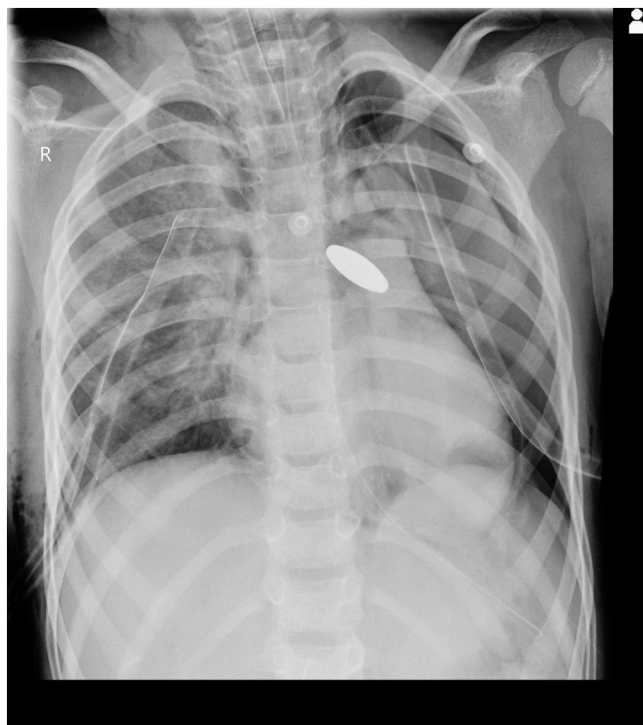After the surgery, the patient was sent back to the PICU, and discharged two days later with no complications. Moreover, in short-term follow up, the patient didn't complain any specific problems.

### 3. Discussion

Airway foreign bodies, also known as “foreign body aspiration,” refer to the entrance of an object into the upper or lower airway tracts during unintended swallowing. Although ingested foreign bodies may be



**Fig. 1.** a. Anteroposterior chest x-ray showing the oval-shaped foreign body. b. The oblong magnets.



**Fig. 2.** X-ray demonstrating the migration of entrapped magnet to the left main bronchus. Bilateral thoracostomy tubes are visible. Note the significant hyperlucency on the left side.



**Fig. 3.** The hand-made magnetic instrument.

associated with less catastrophic complications, AFBs usually present with respiratory signs requiring immediate intervention. It is estimated that the mortality rate in these cases may reach up to 7 % between 0 and 3 years. Moreover, it has been reported that this problem is more common in male children [4].

Soon after the aspiration, the child develops symptoms of respiratory tract irritation such as severe repetitive coughs, dyspnea, cyanosis, and abnormal breath sounds. However, in some cases, these symptoms may not be obvious due to the specific position of the entrapped object [5]. Usually, these symptoms force the parents to bring their infant to the hospital.

Diagnosis is made based on findings of history, physical examination, and imaging studies. A reliable history and the presence of respiratory signs will be enough in some cases. Nevertheless, plain radiography is the necessary step in diagnostic evaluations. Radiograms can show the

object's size, location, shape, and radiopacity. Besides, there may be a notable hyperlucency on the affected side due to entrapped air distal to the AFB. Even so, in cases in which AFB may not be visible in plain radiograms, low-dose computed tomography (CT) can be useful [6]. Also, CT can demonstrate the whole respiratory tree as well as pneumothorax and adjacent atelectasis. It should be noted that negative findings in both x-ray and CT cannot rule out the diagnosis. Therefore, in such circumstances, direct vision of upper airway is another choice [7].

As we mentioned earlier, bronchoscopy is the mainstay of treatment. Both rigid and flexible bronchoscopes can do this. Although physicians have used rigid bronchoscopy for the removal of AFBs for years, the usage of flexible bronchoscopy is trending worldwide [7,8]. After general anesthesia, the bronchoscope will be introduced into the trachea. A continuous suction-irrigation device will be attached to the scoping lumen. Then, the surgeon will inspect the trachea and main bronchi. Thus, the inspected object will be removed using various techniques [8].

The selection of techniques depends on the object's shape, size, context, and sharpness. In most cases, a grasping forceps can be convenient and successful. However, sharp-edged or smooth objects may not be grasped with conventional forceps. Retrieval baskets are used in these cases [9]. Finally, if the extraction process fails after repetitive attempts, a Fogarty catheter seems to be useful. The catheter will be inserted into the lumen, and inflated just after the entrapped object. Then, the gentle movement of the catheter toward the larynx will help to extract the AFB [10]. Unfortunately, in some patients (including ours), these techniques are not 100 % successful. Consequently, after several failed attempts, open exploratory thoracotomy is unavoidable.

This is not the first report of using magnetic forceps to remove magnetic or metallic objects. In some similar cases the authors reported identical techniques [11]. We hypothesize that there are some predicting factors for unsuccessful conventional removals. Due to their high density, metallic objects usually have higher weights than expected. Also, grasping round-shaped or smooth-edged metals seems more difficult. Moreover, A simple toothed forceps is a 15–30 cm long device working with the law of levers. These instruments are basically first class levers. This means that the distance between the load and the fulcrum is crucial. When the fulcrum is farther away from the load (just like graspers), we need much effort to move the load. This is one important point that should be noted in using these instruments. With all this in mind, using more powerful graspers in the extraction of high-density objects seems to be the key. In the lever example, less effort is needed to move the object if we put the fulcrum near the load. But this type of lever is unsafe for human procedures, which may harm the tissues in unintended or accidental efforts. However, the usage of magnetic forceps seems rational.

#### 4. Conclusion

Using the magnet-powered grasping forceps may be beneficial after repetitive failed attempts in the extraction process of airway foreign bodies. Although there is no specific evidence-based guideline for choosing the best removal technique, we recommend using this technique in round-shaped high weight metallic objects as the first removal technique.

Supplementary data to this article can be found online at <https://doi.org/10.1016/j.ijscr.2022.107629>.

#### Consent

Written informed consent was obtained from the patient for publication of this case report and accompanying images. A copy of the written consent is available for review by the Editor-in-Chief of this journal on request.

#### Provenance and peer review

Not commissioned, externally peer-reviewed.

#### Ethical approval

This article does not contain any studies with human participants or animals performed by any of the authors.

#### Funding

The authors didn't receive any financial support for this report.

#### Guarantor

Dr. Manoochehr Ebrahimian.

#### Research registration number

Not applicable.

#### CRediT authorship contribution statement

MS: Conceptualization & Surgery. MK: Writing - Review & editing. AF: Resources. AR: Writing - Original draft. MR: Supervision. ME: Project administration.

#### Declaration of competing interest

The authors declared no potential conflict of interests with respect to the research, authorship, and/or publication of this article.

#### Acknowledgments

We would like to express our special thanks of gratitude to Seyed Mohammad Hossein Jaddi Arani and Seyed Morteza Jaddi Arani (from Iranian Caspian Magnetic Co., Ltd) who helped us in crafting the instrument.

#### References

- [1] F. Brkic, et al., Death as a consequence of foreign body aspiration in children, *Med. Arch.* 72 (3) (2018) 220.
- [2] T. Adjeso, et al., Foreign body aspiration in northern Ghana: a review of pediatric patients, *Int. J. Otolaryngol.* 2017 (2017).
- [3] R.A. Agha, et al., The SCARE 2020 guideline: updating consensus surgical CAsE REport (SCARE) guidelines, *Int. J. Surg.* 84 (2020) 226–230.
- [4] S. Paksu, et al., Foreign body aspiration in childhood: evaluation of diagnostic parameters, *Pediatr. Emerg. Care* 28 (3) (2012) 259–264.
- [5] E. Kitcher, Foreign body inhalation: a review of patients at the Korle Bu teaching hospital, Accra, Ghana, *West Afr. J. Med.* 28 (6) (2009).
- [6] L. Gordon, et al., Diagnosis of foreign body aspiration with ultralow-dose CT using a tin filter: a comparison study, *Emerg. Radiol.* 27 (4) (2020) 399–404.
- [7] A.P. Chantzaras, et al., A systematic review of using flexible bronchoscopy to remove foreign bodies from paediatric patients, *Acta Paediatr.* 111 (7) (2022) 1301–1312.
- [8] H. Yüksel, et al., May the first-line treatment for foreign body aspiration in childhood be flexible bronchoscopy? *Turk. J. Emergency Med.* 21 (4) (2021) 184.
- [9] I.S. Sehgal, et al., Airway foreign bodies: rigid vs flexible approach, in: J.J. F. Turner, et al. (Eds.), *From Thoracic Surgery to Interventional Pulmonology: A Clinical Guide*, Springer International Publishing, Cham, 2021, pp. 91–104.
- [10] R. Nandan, et al., Fogarty catheter: an indispensable tool to complement the ingenuity of the endoscopist for extraction of airway "Foreign body with a Hole", *J. Indian Assoc. Paediatr. Surg.* 27 (1) (2022) 32–37.
- [11] S. Narang, et al., Use of a surface magnet in the extraction of another magnet aspirated into the bronchus of a 7-year-old girl, *BMJ Case Rep.* CP 12 (8) (2019), e230107.