

Spinal cervical extradural hemangioblastoma

ABSTRACT

Spinal cervical extradural and intra-extradural hemangioblastomas are exceptional, with only nine reported cases. This study reviews the diagnostic and surgical problems of this rare entity. Two female patients, aged 80 years and 25 years, respectively, one with Von Hippel–Lindau disease (VHLD), experienced brachial pain and weakness. On magnetic resonance imaging, a dumbbell intra-extraspinal hemangioblastoma was evidenced. The surgical resection through posterior laminectomy resulted in clinical remission of brachial pain and weakness. The magnetic resonance aspect of a dumbbell lesion suggests a neurogenic tumor; the correct preoperative diagnosis is possible in individuals with VHLD. The surgical problems include high tumor vascularity, vertebral artery control, and nerve root preservation. However, the surgical excision results in clinical remission.

Keywords: Dumbbell tumor, hemangioblastoma, spinal extradural hemangioblastoma

INTRODUCTION

Hemangioblastomas are benign, highly vascular neoplasms accounting for 2% of all intracranial tumors and 2%–10% of the primary spinal cord tumors.^[1,2] They may occur as sporadic forms (70%–80%) or in the contest of Von Hippel–Lindau disease (VHLD).^[3] The posterior fossa is the most common location (45%–50%),^[4] followed by the spinal cord (40%–45%)^[5,6] and brainstem (5%–10%).^[7]

Spinal hemangioblastoma are intramedullary (75%) or extramedullary (25%); extramedullary tumors are mainly located at the cauda equina, at the filum terminale, and, less frequently, in the spinal nerve root.^[8] Hemangioblastomas occurring at the neural foramen, in contact with the nerve root, may have an intradural component or may be purely extradural. The 40 reported cases of extradural hemangioblastomas were located mainly in the thoracic spine (54%), followed by the lumbar (33%) and cervical spine (13%).^[9]

This study reports two cases of spinal cervical foraminal hemangioblastomas and reviews the pertinent literature of cases with intra-extraforaminal

extension. The preoperative diagnosis and the surgical problems of these rare hemangioblastomas are discussed.

CASE REPORTS

Case 1

An 80-year-old woman was observed in 2010 for a 3-month history of pain in her left shoulder and progressive weakness of her left arm. The brachial pain suddenly worsened some days before the observation.

GIUSEPPE MARINIELLO¹, SERGIO CORVINO¹, GIUSEPPE CORAZZELLI¹, RADUAN AHMED FRANCA², MARIALaura DEL BASSO DE CARO², FRANCESCO MAIURI¹

¹Department of Neurosciences and Reproductive and Odontostomatological Sciences, Neurosurgical Clinic,

²Department of Advanced Biomedical Sciences, Section of Pathology, University “Federico II” of Naples, Naples, Italy

Address for correspondence: Dr. Sergio Corvino, Department of Neurosciences and Reproductive and Odontostomatological Science, Neurosurgical Clinic, “Federico II” University School of Medicine, 5, Via S. Pansini, Naples 80131, Italy.
E-mail: sercorvino@gmail.com

Submitted: 23-Nov-21


Accepted: 08-May-22

Published: 13-Jun-22

This is an open access journal, and articles are distributed under the terms of the Creative Commons Attribution-NonCommercial-ShareAlike 4.0 License, which allows others to remix, tweak, and build upon the work non-commercially, as long as appropriate credit is given and the new creations are licensed under the identical terms.

For reprints contact: WKHLRPMedknow_reprints@wolterskluwer.com

How to cite this article: Mariniello G, Corvino S, Corazzelli G, Franca RA, Caro MD, Maiuri F. Spinal cervical extradural hemangioblastoma. J Craniovert Jun Spine 2022;13:192-7.

Access this article online	
Website: www.jcvjs.com	Quick Response Code 
DOI: 10.4103/jcvjs.jcvjs_146_21	

Magnetic resonance of the cervical spine [Figure 1] revealed an extradural mass on the left side of the spinal canal at C4–C5, extending to the left C4–C5 vertebral foramen, which was enlarged. The mass was isointense on T1-weighted images and hyperintense on T2-weighted images and showed intralesional hemorrhagic spots and strong and homogeneous contrast enhancement. Marked spinal cord displacement was evident. The preoperative radiological diagnosis was schwannoma.

The neurological examination at admission showed gait impairment, weakness of the proximal muscles on the left arm, decreased bicipital reflex, and hypoesthesia in the left C4 territory.

At operation through C4–C5 laminectomy, a grayish, highly vascularized, wholly extradural mass with intralesional blood infiltration was found, displacing the spinal cord and extending to the left neural foramen. Complete tumor resection was obtained after easy dissection from the nerve root. The intradural exploration did not reveal residual tumor.

The postoperative course was characterized by pain remission and improvement of weakness in the left arm.

The histologic examination [Figure 2] revealed vascular proliferation mainly composed of small vessels arranged

in a lobular fashion and lacunar spaces, in the absence of cytological atypia and with moderate hemorrhage.

The immunohistochemical studies revealed positivity for CD34 and CD31 and partially positivity for factor VIII, while S100, glial fibrillary acidic protein, and European medicines agency were negative. The diagnosis was in favor of hemangioblastoma.

Postoperative magnetic resonance imaging (MRI) of the cervical spine confirmed the tumor removal and resolution of the spinal cord compression [Figure 1d].

At the last follow-up, 7 years after surgery, the patient was symptom-free, with no tumor recurrence.

Case 2

A 25-year-old woman with a familial history of VHL was referred to our neurosurgical unit in March 2018 for a 2-year history of left brachial pain not responsive to medical treatment. Magnetic resonance of the cervical spine showed a hyperintense extramedullary mass at C6–C7 level, occupying the left side of the spinal canal, with extension to the neural foramen and thickening of the C7 nerve root. However, the patient refused surgery. One year later, she was again observed for worsening of the clinical symptoms, onset of paresthesia on the left hand, and gait instability. The neurologic examination showed ataxic gait, weakness, and hypoesthesia of the left arm.

A postcontrast MRI of the cervical spine showed slight increase in the tumor size (15 mm × 28 mm), with inhomogeneous enhancement; the tumor extended toward the left C6–C7 vertebral foramen in the extradural space, causing enlargement of the neural foramen. Significant compression of the spinal cord was evident [Figure 3].

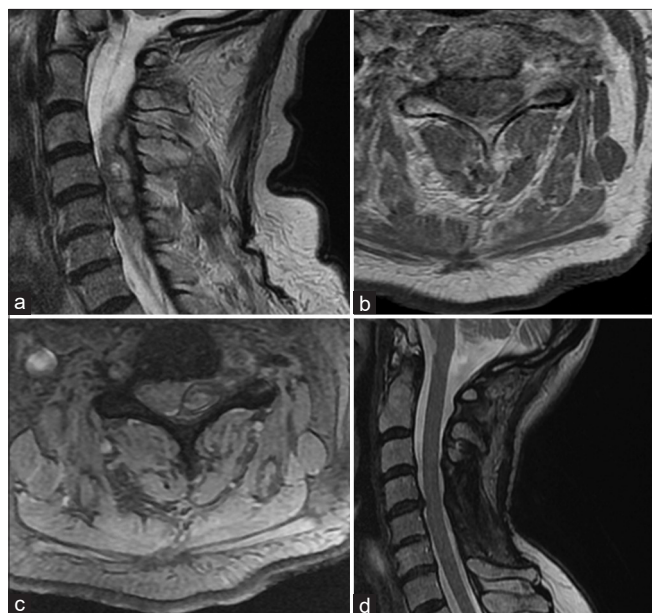


Figure 1: Preoperative MRI of the cervical spine. Sagittal (a) and axial. (b and c) sequences: Before (a) and after (b and c) contrast administration, a large, predominantly hyperintense extradural lesion at C4–C5 level, with heterogeneous prominent vascular flow voids and intralesional bleeding; it occupies the left side of the spinal canal, causing contralateral displacement of the spinal cord and extends through the left C4–C5 vertebral foramen in the parasagittal space. (d) Postoperative MRI, sagittal T2 sequence: Resolution of the spinal cord compression with slight residual hyperintense signal, MRI: Magnetic resonance imaging

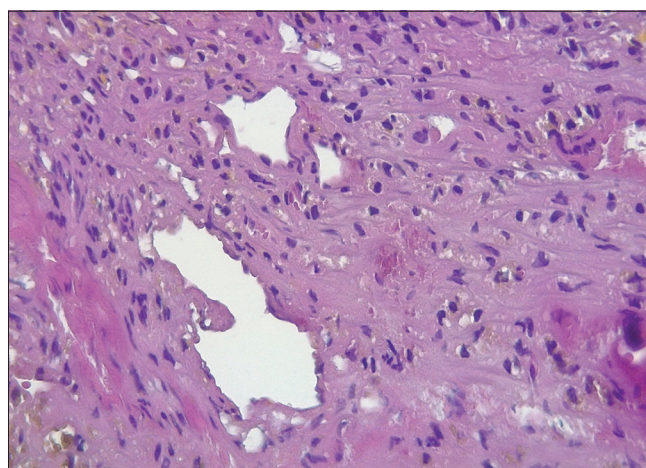


Figure 2: Histologic study of case 1: Vascular proliferation mainly composed of small vessels arranged in a lobular fashion and lacunar spaces. There is no cytological atypia. Moderate amount of hemorrhage was evident (H and E, ×40)

In April 2019, the patient underwent surgery through C6–C7 laminectomy. A fibrous capsulated vascular tumor was exposed in the left half of the spinal canal, extending into the radicular foramen. The wide foraminotomy allowed to expose the lateral tumor portion, mainly located extradurally. With the help of the intraoperative neurophysiological monitoring, the tumor mass was removed; however, a far lateral fragment strongly adherent to the extradural nerve root was left.

The postoperative course was characterized by the remission of the pain and hyposthenia of the left arm.

The histologic examination was consistent with cellular variant of hemangioblastoma [Figure 4].

At the last follow-up, 2 years after surgery, the patient is symptom-free with a stable residual tumor.

DISCUSSION

Spinal cervical hemangioblastomas extending extradurally into the vertebral foramina and in the paravertebral space are exceptional, with only nine reported cases in the English literature.^[8,10-16] The data of the 11 patients (including 2 of ours own) are summarized in Table 1. The patients where the data were completely available were 6 females and 3 males, with age ranging from 24 to 80 years (median 41 years). Eight cases were sporadic and three were familial in the context of VHLD. The distribution according to the spinal level from C4 to T1 was homogeneous. Brachial pain and/or brachial weakness due to nerve root compression were the initial clinical complaint in all cases; three out of 9 also had symptoms and signs of spinal cord compression.

On MRI, the tumor mass showed intense contrast enhancement with a highly vascular aspect. Variable widening of the nerve root foramen with bone erosion was found in all cases, whereas ventral displacement of the vertebral artery was evidenced in three with large extradural tumor component.

The complete surgical resection was obtained in four of the eight patients where this finding is specified; incomplete resections were decided to preserve the extradural nerve root.

The follow-up, specified in 7 cases, ranged from 6 to 84 months (median 23 months). Complete clinical remission was obtained in seven among eight patients. One patient experienced tumor recurrence at 2 years, treated by a second surgery.

Cervical foraminal extradural or intra-extradural hemangioblastomas are an exceptional cause of brachial pain and weakness. Although other far more common pathologies, mainly discoarthrotic, are involved, the presence of a foraminal hemangioblastoma should be suspected in individuals with VHLD who develop brachial pain.

Our patient of case 1 experienced sudden worsening of the brachial pain some days before the observation; at the operation, intralesional and extralesional bleeding was evidenced. Symptomatic bleeding is found from 2.9%^[17] to 5.5%^[18] of central nervous system hemangioblastomas, with a probability of 0.0024 per person per year.^[17]

The MRI appearance of a dumbbell intra-extraspinal tumor mass associated to enlargement of the intervertebral foramen first suggests a neurogenic tumor, such as schwannoma or neurofibroma.^[10,13,15,16] Hemangioblastoma shows intense and often irregular contrast enhancement due to the presence of prominent tumor vessels with dilated arteries and veins; on the other hand, schwannoma enhances intensely and fairly homogeneously. However, because of the very rare occurrence of dumbbell intra-extraspinal hemangioblastomas, the correct diagnosis is suspected only in patients with VHLD. Malignant tumors, such as metastases and malignant nerve sheath tumors, may be ruled out, as they are associated with erosion and infiltration of the bone structures.^[9]

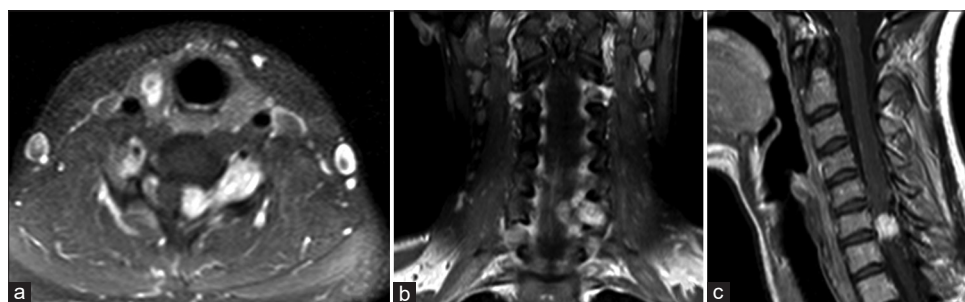


Figure 3: Preoperative cervical spine contrast-enhanced MRI. Axial (a), coronal (b) and sagittal (c) T1-weighted sequences: intravertebral extradural lesion, with non-homogenous contrast-enhancement, displacing contralaterally the spinal cord and extending through the left C6–C7 vertebral foramen in the extradural space, causing enlargement of the neural foramen

Table 1: Data of the reported cases of spinal cervical foraminal hemangioblastomas with extradural extension

Number of cases	Authors/year	Age/sex	Spinal level	VHLD	Clinical presentation	Widening of the root foramen	Nerve root relationship	Vertebral artery relationship	Surgical approach/resection	Follow-up	Outcome
1	Murota and Symon, 1989 ^[8]	38 female	Right C5 extradural	Yes	Weakness of the right hand	NS	Yes	NS	NS/incomplete resection	12 months	Unchanged
2	Bilgen <i>et al.</i> , 2001 ^[10]	24 female	Left C5-C6 intra-extradural	No	Left C6 weakness and paresthesia, spastic tetraparesis	Yes	Yes	Ventral displacement	NS/partial resection	NS	NS
3	Escott <i>et al.</i> , 2004 ^[11]	62 male	C8 extradural	No	Brachial lower limb weakness	Yes	Yes	No	PCA/complete resection	NS	Clinical remission
4	Barrey <i>et al.</i> , 2005 ^[12]	31 female	Right C5-C6 intra-extradural	No	Right C6 radicular pain, right arm and leg weakness	Yes	Yes	Displacement	ALCA/preoperative embolization	6 months	Clinical remission
5	Sid-Ahmed <i>et al.</i> , 2006 ^[13]	33 male	Right C8 intra-extradural	No	Right C8 radicular pain and weakness	Yes	Yes	No	Complete resection PCA + ALCA Preoperative embolization	8 months	Clinical remission
6	Gläsker <i>et al.</i> , 2005 ^[15]	52 male	Right C7 extradural	No	Right arm paresis and C7 paresthesia	Yes	Yes	Ventral displacement	PCA/partial resection	2 years	Clinical remission; symptomatic recurrence at 2 years
7	Doyle and Fletcher, 2014 ^[4]	NS	C8 extradural	Yes	NS	NS	NS	NS	NS	NS	Dead for renal cell carcinoma
8	Doyle and Fletcher, 2014 ^[4]	NS	NS	No	NS	NS	NS	NS	NS	NS	NS
9	Piquer-Belloch, 2021 ^[16]	27 female	Left C5-C6 extradural	No	Left brachial pain, sensory-motor radiculopathy	Yes	Yes	No	PCA/preoperative embolization, complete resection	3 years	Complete recovery
10	Present study	80 female	Left C4-C5 extradural	No	Left arm pain and weakness	Yes	Yes	No	PCA/complete resection	7 years	Clinical recovery
11	Present study	25 female	Left C6-C7 intra-extradural	Yes	Left brachial pain and ataxia	Yes	Yes	No	PCA/subtotal resection	2 years	Clinical remission

VHLD - Von Hippel-Lindau Disease, NS - Not specified, PCA - Posterior cervical approach, ALCA - Anterior lateral cervical approach

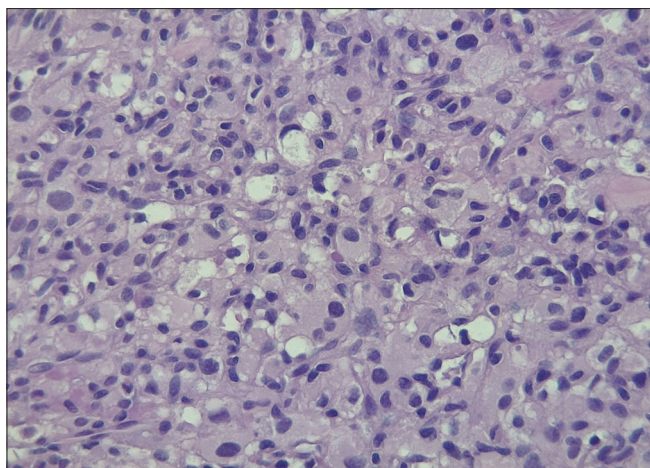


Figure 4: Histologic study of case 2: Highly vascular neoplasm predominantly composed of polygonal cells arranged in lobules with a clear cytoplasm. The finding suggests diagnosis of cellular variant of hemangioblastoma (H and E, x40)

The problems of the surgical resection include choice of approach, high tumor vascularity, vertebral artery control, and nerve root preservation.

The posterior approach through laminectomy was used in 5 of 7 reviewed cases (including ours) where this finding is specified. It allows good tumor control, but the separation of the tumor from the vertebral artery is performed blindly. Thus, cases with significant compression of the vertebral artery may require a lateral cervical approach;^[12] it allows to control of both the nerve root and the vertebral artery before the tumor resection, as well as eventual feeders to the tumor mass.

In three reviewed cases,^[12,13,16] the preoperative embolization of the highly vascular tumor mass was necessary. However, this procedure is not free of complications, including extravasation of embolic particles and bleeding. Besides, some large studies^[19,20] show that the amount of blood loss and the extent of resection were similar in cases with and without preoperative embolization. Thus, this procedure must be reserved to really high-risk cases for intraoperative bleeding.^[9]

CONCLUSION

Extradural and dumbbell intra-extraspinal cervical hemangioblastomas are exceptional lesions causing brachial pain and weakness. Their dumbbell intra-extraspinal radiological aspect suggests a neurogenic tumor; the correct diagnosis should be suspected in patients with VHLD. Complete surgical resection using circumferential dissection while preserving the nerve root is the treatment of choice and results in clinical remission.

Declaration of patient consent

The authors certify that they have obtained all appropriate patient consent forms. In the form, the patient(s) has/have given his/her/their consent for his/her/their images and other clinical information to be reported in the journal. The patients understand that their names and initials will not be published and due efforts will be made to conceal their identity, but anonymity cannot be guaranteed.

Financial support and sponsorship

Nil.

Conflicts of interest

There are no conflicts of interest.

REFERENCES

- Rachinger J, Buslei R, Prell J, Strauss C. Solid haemangioblastomas of the CNS: A review of 17 consecutive cases. *Neurosurg Rev* 2009;32:37-47.
- Bründl E, Schödel P, Ullrich OW, Brawanski A, Schebesch KM. Surgical resection of sporadic and hereditary hemangioblastoma: Our 10-year experience and a literature review. *Surg Neurol Int* 2014;5:138.
- Lonser RR, Butman JA, Huntoon K, Asthagiri AR, Wu T, Bakhtian KD, et al. Prospective natural history study of central nervous system hemangioblastomas in Von Hippel-Lindau disease. *J Neurosurg* 2014;120:1055-62.
- Constans JP, Meder F, Maiuri F, Donzelli R, Spaziante R, de Divitiis E. Posterior fossa hemangioblastomas. *Surg Neurol* 1986;25:269-75.
- Mandigo CE, Ogden AT, Angevine PD, McCormick PC. Operative management of spinal hemangioblastoma. *Neurosurgery* 2009;65:1166-77.
- Wang H, Zhang L, Wang H, Nan Y, Ma Q. Spinal hemangioblastoma: Surgical procedures, outcomes and review of the literature. *Acta Neurol Belg* 2021;121:973-81.
- Yin X, Duan H, Yi Z, Li C, Lu R, Li L. Incidence, prognostic factors and survival for hemangioblastoma of the central nervous system: Analysis based on the surveillance, epidemiology, and end results database. *Front Oncol* 2020;10:570103.
- Murota T, Symon L. Surgical management of hemangioblastoma of the spinal cord: A report of 18 cases. *Neurosurgery* 1989;25:699-707.
- Arumalla K, Deora H, Rao S, Shashidhar A, Rao MB. Spinal extradural hemangioblastoma: A systematic review of characteristics and outcomes. *J Craniovertebr Junction Spine* 2020;11:254-61.
- Bilgen IG, Yünter N, Demirtas E, Cagli S, Zileli M. Hemangioblastoma causing cervical neural foraminal widening. *J Neuroradiol* 2001;28:205-8.
- Escott EJ, Kleinschmidt-DeMasters BK, Brega K, Lillehei KO. Proximal nerve root spinal hemangioblastomas: Presentation of three cases, MR appearance, and literature review. *Surg Neurol* 2004;61:262-73.
- Barrey C, Kalamarides M, Polivka M, George B. Cervical dumbbell intra-extradural hemangioblastoma: Total removal through the lateral approach: Technical case report. *Neurosurgery* 2005;56:E625.
- Sid-Ahmed S, Seizeur R, Forlodou P, Dam-Hieu P, Quintin-Roue I, Person H, et al. Dumbell hemangioblastoma of the eighth cervical nerve root. *Neurochirurgie* 2006;52:533-6.
- Doyle LA, Fletcher CD. Peripheral hemangioblastoma: Clinicopathologic characterization in a series of 22 cases. *Am J Surg Pathol* 2014;38:119-27.
- Gläsker S, Berlis A, Pagenstecher A, Vougioukas VI, Van Velthoven V. Characterization of hemangioblastomas of spinal nerves. *Neurosurgery* 2005;56:503-9.
- Piquer-Belloch J, Rodríguez-Mena R, Llácer-Ortega JL, Riesgo-Suárez

- P, Rovira-Lillo V, Gamo AF, *et al.* A pure extradural hemangioblastoma mimicking a dumbbell nerve sheath tumor in cervical spine: Illustrative case. *J Neurosurg Case Lessons* 2021;2:CASE2192. Available from: <https://thejns.org/caselessons/view/journals/j-neurosurg-case-lessons/2/5/article-CASE2192.xml>. [Last accessed on 2022 May 17].
17. Gläsker S, Van Velthoven V. Risk of hemorrhage in hemangioblastomas of the central nervous system. *Neurosurgery* 2005;57:71-6.
 18. Ene CI, Morton RP, Ferreira M Jr., Sekhar LN, Kim LJ. Spontaneous hemorrhage from central nervous system hemangioblastomas. *World Neurosurg* 2015;83:1180.e13-7.
 19. Deng X, Wang K, Wu L, Yang C, Yang T, Zhao L, *et al.* Intraspinal hemangioblastomas: Analysis of 92 cases in a single institution: Clinical article. *J Neurosurg Spine* 2014;21:260-9.
 20. Ampie L, Choy W, Khanna R, Smith ZA, Dahdaleh NS, Parsa AT, *et al.* Role of preoperative embolization for intradural spinal hemangioblastomas. *J Clin Neurosci* 2016;24:83-7.