

Bilateral Neuroretinitis and a Unilateral Superior Hemivein Occlusion with Frosted Branch Angiitis Pattern Presenting Simultaneously in Behçet's Disease

Roy Schwartz^a Sara Borok^b Michaella Goldstein^a Anat Kesler^a
Keren Regev^c Ori Elkayam^b Zohar Habot-Wilner^a

^aOphthalmology Division, ^bRheumatology Unit, and ^cNeurology Division, Tel Aviv Sourasky Medical Center, The Sackler Faculty of Medicine, Tel Aviv University, Tel Aviv, Israel

Key Words

Behçet's disease · Brain · Frosted branch angiitis · Gastrointestinal · Hemivein occlusion · Neuroretinitis · Ocular Behçet's disease · Panuveitis

Abstract

Purpose: To report a unique case of Behçet's disease that presented with atypical ocular manifestations. **Methods:** Case report. **Results:** A 23-year-old homosexual male presented with bilateral anterior uveitis, vitritis, neuroretinitis and a unilateral superior hemivein occlusion with frosted branch angiitis pattern. These were accompanied by systemic findings of recurrent oral aphthous ulcers, erythema nodosum, and neurological and gastrointestinal involvement. A positive HLA-B51 examination supported the diagnosis of Behçet's disease. **Conclusion:** Neuroretinitis and frosted branch angiitis may be the clinical manifestations of Behçet's disease and may present simultaneously.

© 2016 The Author(s)
Published by S. Karger AG, Basel

Introduction

Behçet's disease (BD) is a chronic, relapsing inflammatory disorder of unknown etiology. It may be diagnosed using one of two main diagnostic systems. The first was suggested

by the Behçet's Research Committee of Japan, and the other by the International Study Group for Behçet's Disease. Both include the presence of oral ulceration, ocular manifestations, genital ulceration, and skin lesions. Ocular involvement includes a nongranulomatous inflammation with obliterative vasculitis in the anterior or posterior segment of the eye, but more commonly in both segments [1]. We present a unique case of BD, with rare ocular and systemic manifestations, posing a diagnostic and therapeutic challenge.

Case Report

A healthy 23-year-old homosexual male presented to the emergency room with complaints of vertigo, right facial weakness, and diplopia. Neurological examination found limitation in right abduction, right gaze nystagmus with marked oscillopsia, and right peripheral facial nerve paralysis. Brain MRI showed a hyperintense focus in the right pons, weakly enhanced, adjacent to the area of the abducens and facial nuclei. Frontal periventricular hyperintense foci were also demonstrated without enhancement.

The patient was hospitalized with a suspected inflammatory process, chiefly multiple sclerosis (MS). The differential diagnosis also included a vascular or neoplastic process. A lumbar puncture examination revealed pleocytosis with multiple lymphocytes, which normalized on repeat exam. Cytology and oligoclonal bands were normal. Blood tests for antinuclear antibody (ANA), C3, C4, anti-neutrophil cytoplasmic antibody (ANCA), and rheumatoid factor were normal. HIV was negative. Blood tests aimed at ruling out a vascular etiology, including antiphospholipid antibody (APLA), cardiolipin IgM and IgG, beta 2 glycoprotein, D-dimers, circulating anticoagulants, and a transcranial Doppler examination were normal. As no definite diagnosis of MS was reached, the patient was diagnosed with a clinically isolated syndrome, and was treated with IV solumedrol 500 mg/day for 5 days, followed by oral prednisone 20 mg/day, with marked improvement in his signs and symptoms.

A month later, following discontinuation of prednisone, the patient returned with a headache and worsening of diplopia and facial weakness, which again improved after recommencing 60 mg/day prednisone. Repeat MRI showed the pontine focus to be more enhanced, rendering the diagnosis of MS less plausible. Angiotensin-converting enzyme was negative; anti-Ro and anti-La were negative for neuro-Sjögren, and aquaporin 4 was negative as well, refuting a diagnosis of neuromyelitis optica. The patient was discharged with slow tapering off of prednisone treatment and with no definite diagnosis.

Ten months later, the patient complained of visual deterioration OD and constriction of his right lower visual field. On examination, best-corrected visual acuity (BCVA) was 20/100 OD and 20/20 OS. Intraocular pressure was normal in both eyes. There was a right afferent pupillary defect, and Ishihara color vision score was 1/12 OD and 12/12 OS. Nystagmus was still seen, but cranial nerve functions were normal. There was mild anterior uveitis OD with +1 cells and no flare. Mild vitritis, with few cells, was seen OU. Fundus examination of the right eye revealed superior optic disc edema accompanied by hemorrhages and blood vessel sheathing. The macula was elevated, with intraretinal hemorrhages in the upper half of the macula, and star-shaped exudates in its lower half. A superior hemivein occlusion was noted, composed of dilatations and tortuosity of the superior retinal veins, a frosted branch angiitis pattern, and hemorrhages in the upper half of the retina. Retinal hemorrhages were also seen inferior to the optic disc (fig. 1a). Fundus examination of the left eye revealed star-shaped exudates in the upper half of the macula.

Fluorescein angiography of the right eye demonstrated a superior hemivein occlusion with occlusive vasculitis (fig. 1b–d). Optical coherence tomography (OCT) demonstrated

vitreal cells and neuroretinitis findings in both eyes. Both eyes demonstrated different stages of neuroretinitis (fig. 1e, f). A 30-2 stimulus III visual field test showed an almost complete lower-half scotoma OD, fitting the superior distribution of retinal damage and a small superonasal central scotoma. OS visual field test demonstrated constriction of the superonasal quadrant and a small superotemporal central scotoma. The bilateral central pattern fitted a small central homonymous scotoma, possibly representing an insult to the tip of the occipital lobe.

Systemic physical examination revealed only a purple, flat, painful lump, approximately an inch across, on the right shin typical of erythema nodosum, and was otherwise normal. On further history-taking, the patient negated other uveitic signs and symptoms, including mouth or genital aphthae, gastrointestinal or respiratory symptoms, other rashes, travel to exotic areas, or exposure to animals.

Due to the finding of frosted branch angiitis in a young homosexual patient, a vitreal tap was performed to rule out CMV infection, and intravitreal ganciclovir 2 mg/0.1 ml was injected. A uveitic workup including a complete blood count and chemistry was normal; C-reactive protein (CRP) was high (88 mg/l, normal value 0–5 mg/l); ANA, C3, C4, C and P AN-CA were normal; a coagulation panel, including PT and PTT, was normal, β_2 glycoprotein was normal, and homocysteine was found to be elevated 4 times the normal level (59.8 $\mu\text{mol/l}$, normal level 5–15 $\mu\text{mol/l}$).

Blood serologies for infectious causes, including Venereal Disease Research Laboratory test, treponema pallidum hemagglutination, toxoplasma IgM and IgG and Bartonella IgM and IgG were negative. A repeat HIV test was negative, as well as vitreous PCR for CMV. Mantoux examination was anergic, and a chest radiograph and computed tomography were normal.

Treatment with folic acid and B vitamins was started due to homocysteinemia. The patient was treated with IV methylprednisolone 1 g/day for 3 days, followed by prednisone 60 mg/day, with gradual tapering. Three weeks later, BCVA was 20/28 OD, color vision significantly improved to 11/12, with significant clinical improvement (fig. 2a). OCT showed absorption of most of the subretinal fluid (fig. 2b). Eventually, on follow-up visits, the patient confessed to having had mouth aphthae 5 times a year for the past 3 years. HLA-B51 examination was taken and found positive, validating the diagnosis of BD. Prednisone was tapered down and azathioprine (Imuran, GlaxoSmithKline, Triangle Park, N.C., USA) 50 mg/day was started. Due to patient complaints of insufferable side effects, prednisone treatment was tapered off.

For the rest of the follow-up, the patient demonstrated repeat deteriorations whenever prednisone dosage was lowered, similar to the deterioration that occurred in the central nervous system disease after the discontinuation in prednisone. Two weeks following the cessation of prednisone and under a regimen of azathioprine 150 mg/day, the patient returned complaining of visual deterioration, this time OS. BCVA OS was 20/32. No anterior uveitis or vitritis were seen. Blurring of the nasal edge of the optic disc was noted and OCT demonstrated a small amount of subretinal fluid, representing recurrence of neuroretinitis. Prednisone 60 mg/day was recommenced, and azathioprine dosage was increased to 150 mg/day. A week later complete resolution of subretinal fluid was seen, and BCVA OS improved to 20/20.

A month later, while on prednisone 20 mg/day and azathioprine 150 mg/day, the patient presented to the emergency department with acute colitis involving his left colon and sigmoid colon. He refused to undergo colonoscopy and was treated with antibiotics and a prednisone dosage of 30 mg/day, with resolution of the bowel inflammation.

Five months later, under 12.5 mg/day prednisone and 150 mg/day azathioprine, the patient complained again of visual deterioration OS. BCVA OS was 20/100 and 20/22 OD. Few

cells were seen in the vitreous OS, accompanied by optic disc margin blurring with a pre-papillary exudate. The macula was elevated (fig. 3a). OCT demonstrated recurrence of neuroretinitis (fig. 3b). Prednisone dosage was increased to 60 mg/day, and azathioprine 150 mg/day was continued. A week later, substantial improvement was seen: BCVA improved to 20/25, and the macular edema and optic nerve lesion resolved (fig. 3c).

As the patient presented with several flare-ups under prednisone treatment of more than 10 mg/day and azathioprine 150 mg/day, treatment with azathioprine was replaced with infliximab (Remicade, Janssen Biotech, Malvern, Pa., USA). Under treatment with infliximab infusions and 20 mg/day prednisone, no flare-ups of uveitis or systemic manifestations of BD were noted.

Discussion

This patient presented with unique ocular and systemic manifestations posing a diagnostic challenge. He had bilateral anterior uveitis, vitritis, neuroretinitis, and a unilateral superior hemivein occlusion with frosted branch angiitis pattern. The systemic findings that finally corresponded with the diagnosis of BD included recurrent oral ulcers, erythema nodosum, and neurological and gastrointestinal involvement with a positive HLA-B51 examination.

Two main diagnostic systems for BD diagnosis are used in clinical practice: The International Study Group for Behçet's Disease system and the Behçet's Research Committee of Japan system. Both include the presence of oral ulceration, ocular manifestations, genital ulceration, and skin lesions. In addition, the Japanese system added minor criteria, including arthritis, intestinal ulcers, epididymitis, vasculitis or vasculopathy, and neuropsychiatric symptoms [1]. At first, our patient presented with nonspecific brain findings and several months later developed atypical ocular manifestations and erythema nodosum. Only after repeated history-taking he admitted to having mouth ulcers. Combining all of these systemic manifestations led us to a high suspicion of BD, though ocular manifestations were atypical. HLA-B51 haplotype examination was positive, which further validated BD diagnosis. Later on, gastrointestinal involvement appeared, also strengthening the diagnosis of BD.

Neurological syndromes in BD are most frequently due to a brainstem lesion, in addition to hemispheric involvement related to inflammatory infiltration of white and grey matter, both seen in our patient [2]. Gastrointestinal tract involvement in BD affects approximately 3–16% of patients. According to the 2nd edition of the Japanese consensus statement for the diagnosis and management of intestinal BD [3], diagnosis of intestinal BD can be made with ulcerations or inflammation in the small or large intestine, with other clinical findings meeting the diagnostic criteria of BD.

Our patient's ocular presentation was atypical for BD. In an observational case series on 1,567 eyes published by Tugal-Tutkun et al. [4], vitritis and retinal vasculitis were the most common findings. Other manifestations included hypopion, retinitis, retinal hemorrhages, and papillitis. Complications included macular edema and vein occlusion. Of note, no occurrence of either neuroretinitis or frosted branch angiitis is mentioned.

To date, only one case has been reported on a patient with BD that presented with bilateral nonsimultaneous frosted branch angiitis and unilateral papillitis and macular exudates [5]. In contrast to this case, our patient presented with a simultaneous bilateral anterior and intermediate uveitis, accompanied by simultaneous bilateral neuroretinitis, in addition to a unilateral superior hemivein occlusion with a frosted branch angiitis pattern. In addition, unlike our case, the systemic diagnosis of BD in this aforementioned case was easily made

thanks to disease criteria that were met on presentation, including recurrent mouth and genital ulcers, erythema nodosum, and brain involvement. Furthermore, in our case, BD was confirmed by the presence of a positive HLA-B51 test, which was not performed in the reported case. HLA-B51 or HLA-B5 is carried by one to two thirds of patients with BD and increases the risk of BD development by a factor of about 6 [6].

Literature review also confirms the scarcity of frosted branch angiitis as a manifestation of BD. It is mentioned as a single finding in BD in 7 cases only [7]. No report on neuroretinitis was found.

Our patient also presented a therapeutic dilemma. He experienced recurrences under treatment with low-dose systemic corticosteroid and 150 mg/day azathioprine. Immunomodulatory agents are typically used for long-term treatment of BD. These include mostly antimetabolites and calcineurin inhibitors. However, a proportion of patients does not respond well to these agents and may suffer from recurrent attacks and loss of vision. Biological agents, such as tumor necrosis factor antagonists (anti-TNF) and interferons, are being used for the treatment of ocular BD in recent years [8]. Moreover, a publication by Levy-Clarke et al. [9] suggests using anti-TNF- α as second- or first-line immunomodulatory agents. As our patient did not achieve uveitis quiescence under treatment with low-dose systemic corticosteroid and 150 mg/day azathioprine, treatment with an anti-TNF agent, infliximab (Remicade), was started. The patient demonstrated good response with resolution of ocular and systemic findings, and no flare-ups.

In summary, our case represents rare ophthalmologic and systemic manifestations of BD and underscores the complexity of this disease due to its rich array of manifestations.

Statement of Ethics

The authors have no ethical conflicts to disclose.

Disclosure Statement

None of the authors have any conflict of interest in regard to the material in this case report.

References

- 1 Foster CS VA: Diagnosis and Treatment of Uveitis, 2nd ed. Philadelphia, JP Medical Ltd., 2013.
- 2 Kidd D: Neurological complications of Behçet's syndrome. *Curr Neurol Neurosci Rep* 2012;12:675–679.
- 3 Hisamatsu T, Ueno F, Matsumoto T, Kobayashi K, Koganei K, Kunisaki R, et al: The 2nd edition of consensus statements for the diagnosis and management of intestinal Behçet's disease: indication of anti-TNF α monoclonal antibodies. *J Gastroenterol* 2014;49:156–162.
- 4 Tugal-Tutkun I, Onal S, Altan-Yaycioglu R, Huseyin Altunbas H, Urgancioglu M: Uveitis in Behçet disease: an analysis of 880 patients. *Am J Ophthalmol* 2004;138:373–380.
- 5 Al-Mujaini A, Wali UK: Frosted branch angiitis, neuroretinitis as initial ocular manifestation in Behçet disease. *Indian J Ophthalmol* 2011;59:240–241.
- 6 de Menthon M, Lavalley MP, Maldini C, Guillevin L, Mahr A: HLA-B51/B5 and the risk of Behçet's disease: a systematic review and meta-analysis of case-control genetic association studies. *Arthritis Rheum* 2009;61:1287–1296.
- 7 Kwon SJ, Park DH, Shin JP: Frosted branch angiitis as ocular manifestation of Behçet's disease: unusual case report and literature review. *Korean J Ophthalmol* 2013;27:466–469.
- 8 Hazirolan D, Stübiger N, Pleyer U: Light on the horizon: biologicals in Behçet uveitis. *Acta Ophthalmol* 2013;91:297–306.

- 9 Levy-Clarke G, Jabs DA, Read RW, Rosenbaum JT, Vitale A, Van Gelder RN: Expert panel recommendations for the use of anti-tumor necrosis factor biologic agents in patients with ocular inflammatory disorders. *Ophthalmology* 2014;121:785–796.

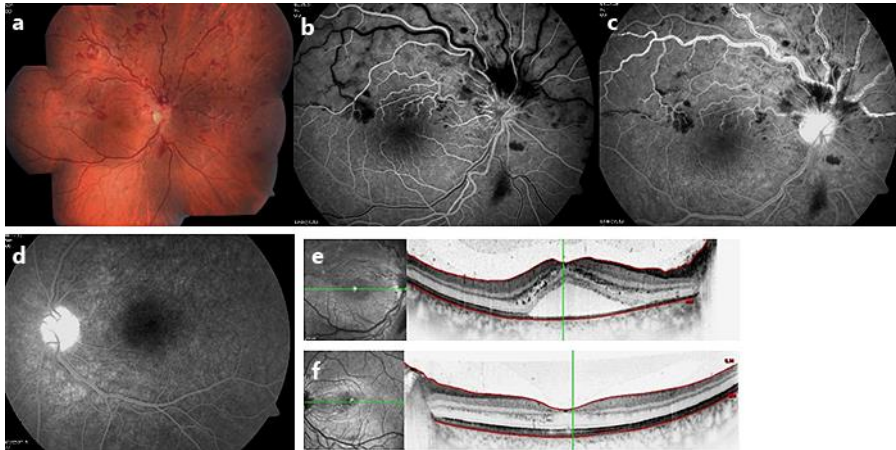


Fig. 1. **a** Color fundus photo mosaic. A superior hemivein occlusion, with frosted branch angiitis and neuroretinitis. Retinal hemorrhages inferior to the optic disc. **b–d** Fluorescein angiogram. **b** OD transit phase (25 s): late filing of the superior veins, accompanied by hypofluorescent foci due to blockage by retinal hemorrhages. **c** OD (5 min): hot disc, hyperfluorescent superior vein walls and capillary nonperfusion areas. No macular leakage was seen throughout the various angiographic stages. **d** OS (5 min): hot disc with no additional findings. **e, f** OCT. **e** OD. Hyperreflective foci in the vitreous corresponding to vitreal cells, an elevated foveal contour with subfoveal fluid, and hyperreflective foci mostly in the outer plexiform layer, corresponding to the star-shaped exudates seen clinically. **f** OS. Vitreal cells and hyperreflective foci in the outer plexiform layer corresponding to star-shaped exudates.

Schwartz et al.: Bilateral Neuroretinitis and a Unilateral Superior Hemivain Occlusion with Frosted Branch Angiitis Pattern Presenting Simultaneously in Behçet's Disease

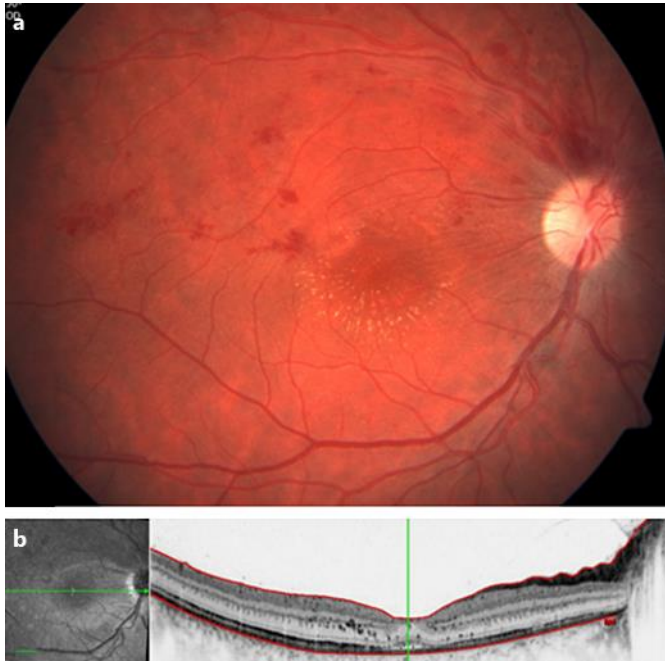


Fig. 2. **a** Color fundus image. Normal optic disc, remnants of retinal hemorrhages, and sclerosis of superior temporal vein. Prominent star-shaped exudates. **b** OCT image. Remnants of subretinal fluid and hyperreflective foci in the outer plexiform layer corresponding to star-shaped exudates.

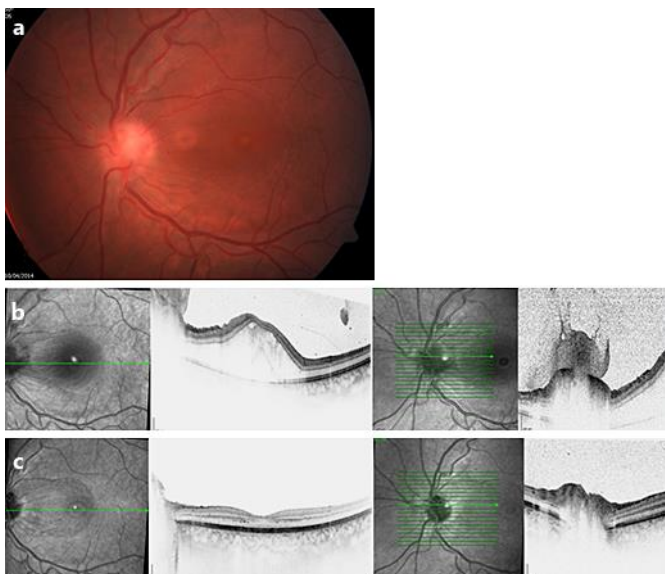


Fig. 3. **a** Fundus image OS. Blurring of disc margins, a gray lesion on the disc, and macular elevation. **b** OCT OS. Vitreal cells, retinal and subretinal fluid and an optic disc lesion. **c** Resolution of fluid and the optic disc lesion following prednisone re-initiation.