

Case Report

Leber's Hereditary Optic Neuropathy and Hypertrophic Cardiomyopathy

Thomas Morris Hey, MD, PhD,^{a,b} Søren Kristian Nielsen, MD,^b Ulrik Eriksen, MD, PhD,^a Frederikke Hansen, MD,^b and Jens Mogensen, MD, DMSc, PhD^{c,d}

^a Department of Cardiology, Lillebaelt Hospital—Vejle, Vejle, Denmark

^b Department of Cardiology, Odense University Hospital, Odense, Denmark

^c The Department of Cardiology, Aalborg University Hospital, North Denmark Region, Denmark

^d The Faculty of Health Science, The University of Southern Denmark, Odense, Denmark

ABSTRACT

Leber's hereditary optic neuropathy (LHON) is a mitochondrial condition that gradually affects the central vision. In the current case report, we present 2 relatives with LHON due to a pathogenic variant within *ND1* with a clinical phenotype resembling hypertrophic cardiomyopathy, including a short PQ-interval and hypertrophy on electrocardiogram as well as severe hypertrophy of the left ventricle on echocardiography. These findings highlight the importance of offering routine cardiac investigation to patients with LHON and their relatives carrying the *ND1* variant to hopefully improve correct diagnosis and clinical management of LHON patients.

RÉSUMÉ

La neuropathie optique héréditaire de Leber (NOHL) est une maladie mitochondriale qui affecte graduellement la vision centrale. Dans l'observation clinique actuelle, nous présentons deux proches atteints de la NOHL due à un variant pathogène dans le *ND1* associé à un phénotype clinique qui ressemble à une cardiomyopathie hypertrophique, notamment en raison d'un intervalle PQ court et d'une hypertrophie à l'électrocardiogramme, et d'une hypertrophie grave du ventricule gauche à l'échocardiographie. Ces conclusions illustrent l'importance de proposer des examens cardiaques systématiques aux patients atteints de NOHL et à leurs proches porteurs du variant *ND1* pour, espérons-le, améliorer les diagnostics justes et la prise en charge clinique des patients atteints de la NOHL.

Clinical Investigations of the Index-Patient

The male index-patient (Figure 1A, part II-1) was 53 years old when he suddenly became functionally blind, though his peripheral vision was spared, without any other complaints. The initial physical examination was unremarkable, including auscultation of the heart and lungs. He was a nonsmoker receiving no medication and had a normal body mass index of 25 m²/kg, as well as a blood pressure of 140/80 mm Hg. Magnetic resonance imaging of the brain showed demyelination of the posterior portion of the optical nerves consistent with a diagnosis of Leber's hereditary optic neuropathy (LHON). The results of neurologic investigations were otherwise normal. He had no cardiac symptoms, but he had a routine electrocardiogram (ECG) performed during his diagnostic workup in the neurology department.

His ECG showed left ventricular hypertrophy (LVH) and a short PR-interval of 130 ms, which is often associated with

mitochondrial disease (Fig. 1B). Echocardiography showed asymmetrical septal and apical hypertrophy of 29 mm (Fig. 1C). Repeated 48-hour Holter-recordings were normal.

Genetic Investigations

The index-patient underwent genetic investigations of 256 recognized or likely hypertrophic cardiomyopathy (HCM) genes by next-generation sequencing. A pathogenic mitochondrial variant within the gene for *ND1* (m.3460G > A) was identified, and no additional clinical actionable variants were identified.

Family Investigations

The sister (Fig. 1A, individual II-2) of the index-patient had normal findings upon ophthalmologic examination and had undergone cardiac investigations at the age of 54 years due to exercise-induced chest pain and shortness of breath. She had no history of palpitations or syncope, and her ECG was identical to the ECG of her brother with sinus rhythm short-PQ interval (Fig. 1B). Coronary angiography was normal, whereas her echocardiogram showed severe septal (23 mm) and apical hypertrophy (Fig. 1C). A 48-hour Holter recording revealed chronotropic incompetence with sinus bradycardia, an average pulse rate of 48, and only 70,000 beats/d. Due to chronotropic incompetence, the patient was

Received for publication April 28, 2022. Accepted June 13, 2022.

Ethics Statement: The research reported in this paper adhered to the guidelines of the Danish Committee on Health Research Ethics.

Corresponding author: Dr Thomas Morris Hey, Lillebaelt Hospital—Vejle, Kappeltoft 25, Vejle 7100, Denmark.

E-mail: thomas.morris.hey@rsyd.dk

See page 815 for disclosure information.

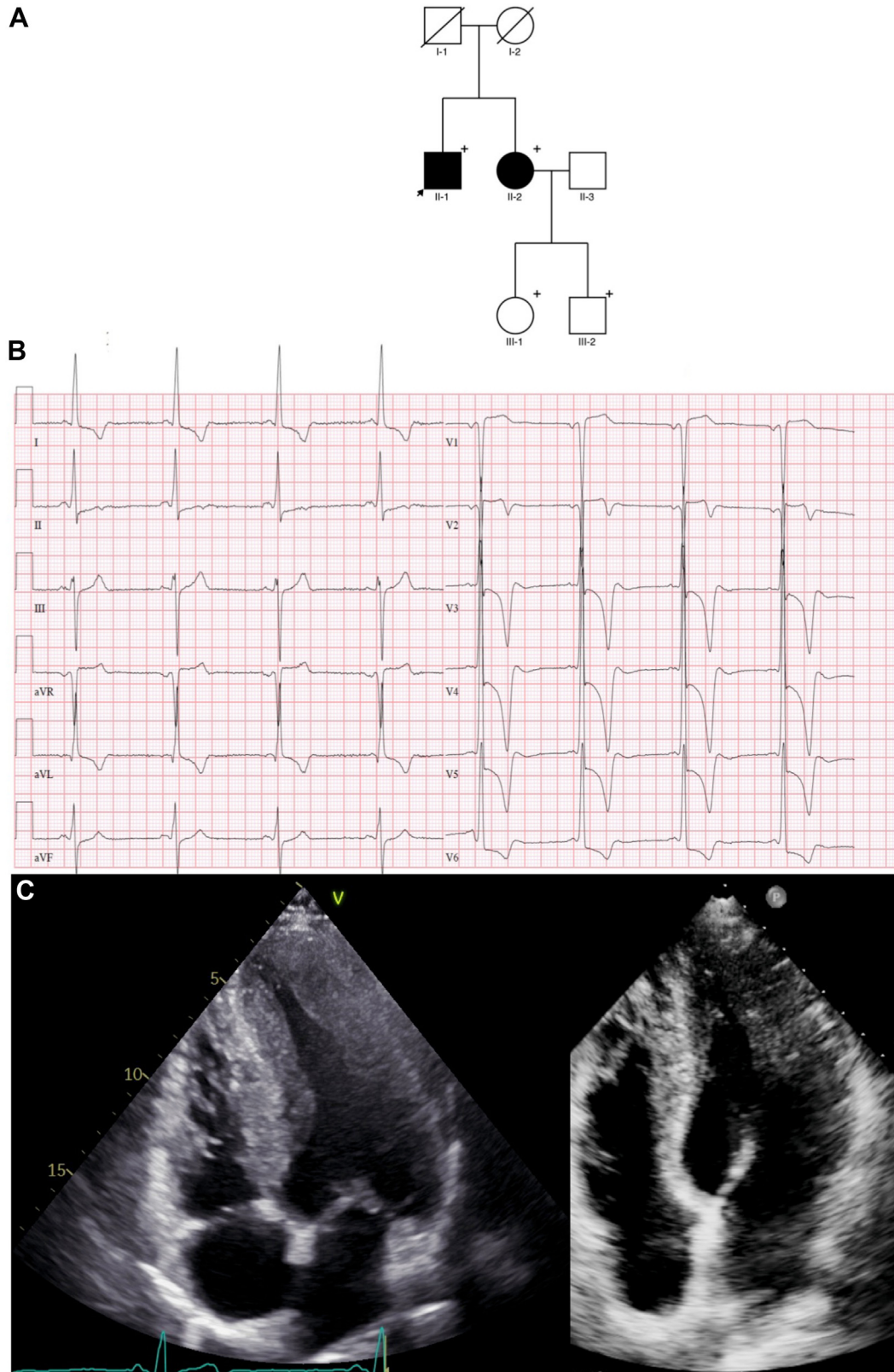


Figure 1. (A) Pedigree. The 2 affected individuals in the family were the index-patient (II-1) and his sister (II-2). The mother (I-2) of the index-patient died of cancer at the age of 68 years, and his father (I-1) died of natural causes at the age of 86 years. Both children (III-1 and III-2) of the affected sister (II-2) were obligate carriers of the *ND1* variant, but they remained healthy at their most recent clinical investigation at the ages of 34 and 37 years, respectively. (B) The electrocardiogram performed at diagnosis of the index-patient shows a short PQ interval of 130 ms, marked T-wave inversion in I, aVL, and V3-V6, and diphasic T-waves in V2. Furthermore, the QRS configuration suggests left ventricular hypertrophy. (C) An echocardiogram 4-chamber projection reveals severe mid-ventricular and apical hypertrophy (left: index-patient; right: affected sister).

offered pacemaker treatment, which she has refused for the time being.

Genetic investigations in 256 genes associated with HCM confirmed that she carried the same *NDI* variant as her brother, and no additional actionable variant was identified. Both her son and daughter (Fig. 1A; individual III-2 and III-1), who are obligate carriers, remain without cardiac symptoms and had normal echocardiography, ECG, ophthalmologic, and neurologic findings at the ages of 34 and 37 years, respectively.

Discussion and Clinical Implications

LHON is a rare mitochondrial condition characterized by loss of the central vision that affects about 50% of male carriers and 10% of female carriers.¹ Systemic manifestations are rare and may resemble the disease expression in patients with multiple sclerosis.² Ninety percent of cases are explained by 1 of 3 pathogenic variants in the mitochondrial genes for *NDI* (m.3460G > A), *ND4* (m.11778G > A), or *NG6* (m.14484T > C).¹

In the current study, we report that a pathogenic variant in *NDI* (m.3460G > A) is associated with the development of an HCM phenotype in patients with LHON.

So far, only one previous study has performed systematic cardiac investigations in patients with LHON.³ The authors reported that 5 of 11 carriers of the same *NDI* variant identified in the present study also had LVH resembling HCM, of whom 3 had cardiac symptoms including palpitations, syncope, angina, and dyspnoea. A total of 8 *NDI* carriers had ECG abnormalities with T-wave inversion (n = 6), LVH (n = 5), and/or ST-segment abnormalities (n = 8). One patient had sinus node dysfunction and received a pacemaker. Another patient died suddenly at the age of 50 years.³

Mortality and morbidity among patients with LHON were recently investigated in a nationwide Danish study of 141 LHON patients, who also underwent genetic investigations. The study was based solely on International Classification of Diseases, 10th edition, codes from The Danish Cause of Death Register and The Danish National Patient Registry, as no clinical data were available. Genetic investigations revealed that the previously recognized pathogenic sequence variant within *ND4* (m.11778G > A) was most frequent (n = 103), followed by *NDI* (m.3460G > A; n = 20), and *NG6* (m.14484T > C; n = 12), and 6 patients had a normal genotype. Patients with LHON were shown to have an all-cause mortality rate twice as high as the background population, as well as significantly higher incidences of heart-related diseases and stroke (12.4/1000 vs 5.2/1000 patient-years).⁴

The results from these previous studies suggest that LHON is associated with the development of cardiac manifestations, at least in carriers of the recognized pathogenic *NDI* variant (m.3460G > A), although data from cardiac investigations were available in only one study.^{1,3} These findings suggest that patients with LHON and their relatives carrying *NDI* variants should be offered routine cardiac investigation, including ECG and echocardiography. Further clinical studies including ECG, echocardiography, and Holter

Novel Teaching Points

- Cardiac manifestations are frequent in patients with LHON and may be indistinguishable from those seen in sarcomeric HCM.
- Patients with LHON and their relatives carrying *NDI* variants should be offered clinical cardiology investigation as part of their diagnostic workup.
- Inclusion of the *NDI* gene in the screening of HCM patients should be considered.

monitoring of LHON patients will elucidate whether the development of cardiac manifestations is also associated with sequence variants within *ND4* and *NG6*.

Given that the cardiac manifestations in patients with LHON mirror the clinical findings in HCM caused by pathogenic variants in sarcomere genes, at least *NDI* should be considered for inclusion in genetic investigation of HCM patients. This approach will ensure correct genetic diagnosis and appropriate counselling of LHON families, which is important because of the frequent involvement of multiple organs in mitochondrial disease and the maternal pattern of inheritance.

Conclusion

Cardiac manifestations are frequent in patients with LHON carrying *NDI* variants and resemble HCM caused by mutations in sarcomeric genes, which necessitates routine cardiac investigation of carriers of the *NDI* variant, to avoid adverse disease complications. Furthermore, inclusion of *NDI* in the genetic investigation of HCM patients may be considered, to ensure correct diagnosis, genetic counselling, and management of patients with LHON.

Funding Sources

Funding was provided by the Department of Cardiology at Odense University Hospital and Lillebaelt Hospital Vejle.

Disclosures

The authors have no conflicts of interest to disclose.

References

1. Duran J, Martinez A, Adler E. Cardiovascular manifestations of mitochondrial disease. *Biology (Basel)* 2019;8:34.
2. Harding AE, Sweeney MG, Miller DH, et al. Occurrence of a multiple sclerosis-like illness in women who have a Leber's hereditary optic neuropathy mitochondrial DNA mutation. *Brain* 1992;115:979-89.
3. Sorajja P, Sweeney MG, Chalmers R, et al. Cardiac abnormalities in patients with Leber's hereditary optic neuropathy. *Heart* 2003;89:791-2.
4. Vestergaard N, Rosenberg T, Torp-Pedersen C, et al. Increased mortality and comorbidity associated with Leber's hereditary optic neuropathy: a nationwide cohort study. *Invest Ophthalmol Vis Sci* 2017;58:4586-92.