

Original Article

## Role of vitamin D in Wnt pathway activation for colonic epithelial cell differentiation



Satrio Wibowo, M.Sc<sup>a,\*</sup>, Krisni Subandiyah, Ph.D<sup>a</sup>, Kusworini Handono, Ph.D<sup>b</sup> and Sri Poeranto, Ph.D<sup>c</sup>

<sup>a</sup> Department of Pediatrics, Faculty of Medicine, University of Brawijaya, Malang, Indonesia

<sup>b</sup> Department of Clinical Pathology, Faculty of Medicine, University of Brawijaya, Malang, Indonesia

<sup>c</sup> Department of Parasitology, Faculty of Medicine, University of Brawijaya, Malang, Indonesia

Received 21 November 2020; revised 15 January 2021; accepted 29 January 2021; Available online 4 March 2021

### المخلص

**أهداف البحث:** مرض التهاب الأمعاء هو حالة طبية تمثل شكلاً مرضياً من الالتهابات التي تلحق الضرر بالغشاء المخاطي القولوني. قد يساعد العلاج المساعد بفيتامين د في مرض التهاب الأمعاء على تنشيط مسار بيتا-كاتنين الذي يؤدي إلى تمايز الخلايا ويعزز انتشار الخلايا عبر إشارات الخلايا الجذعية. تهدف هذه الدراسة إلى تقييم تأثير فيتامين د على بيتا-كاتنين والكيراتين الخلوي. ٢٠ كعلامات على تفعيل مسار بيتا-كاتنين لإصلاح الخلايا القولونية.

**طرق البحث:** في المختبر التجريبي، استخدمنا ٣٠ من سلالات الفئران العضلية، تم تقسيمها إلى خمس مجموعات. المجموعة التحكم وأربع مجموعات أخرى حيث تم تحريض التهاب القولون بواسطة كيريات ديكستران لمدة سبعة أيام. وفي اليوم السابع، أعطيت المجموعات الثلاث المتبقية فيتامين د بجرعة أولية قدرها ٠.٢ ميكروغرام/٢٥ غرام، و٠.٤ ميكروغرام/٢٥ غرام، و٠.٦ ميكروغرام/٢٥ غرام حتى اليوم الرابع عشر. وكان من الضروري وجود مؤشر موضوعي لنشاط المرض ودرجة في النسيج كعلامات للالتهاب لتقييم نتائج التجارب السريرية.

**النتائج:** أظهرت بيتا-كاتنين والكيراتين الخلوي-٢٠ زيادة كبيرة في مؤشر انتشار فيتامين د بجرعة قدرها ٠.٦ ميكروغرام/٢٥ غرام مقارنة بمجموعة التهاب القولون.

**الاستنتاجات:** أظهرت هذه الدراسة أن فيتامين د يمكن أن يستخدم كعامل تحريضي لتفعيل مسار بيتا-كاتنين للشفاء من الغشاء المخاطي للمستعمرة عن طريق الخلايا الجذعية متعددة القدرات.

**الكلمات المفتاحية:** مؤشر نشاط المرض، مرض التهاب الأمعاء، الخلايا الجذعية متعددة القدرات، فيتامين د، مسار بيتا-كاتنين،

### Abstract

**Objectives:** Inflammatory bowel disease (IBD) is a medical condition that represents a pathological form of inflammation, causing damage to the colonic mucosa. Adjunctive vitamin D therapy may activate the Wnt/ $\beta$ -catenin pathway that results in cell differentiation and proliferation via stem cell signalling. This study aims to evaluate the effect of vitamin D on  $\beta$ -catenin and cyto-keratin 20 (KRT20) as markers of Wnt pathway activation for colonic cell repair.

**Methods:** For the experiment, we used 30 musculus mice strains of BALB/c, which were categorised into five groups; the control group (K-) and four other groups, where colitis was induced by dextran sulphate sodium (DSS) for seven days. On the seventh day, the remaining three groups were administered vitamin D with an initial dose of 0.2  $\mu$ g/25.0 g, 0.4  $\mu$ g/25.0 g and 0.6  $\mu$ g/25.0 g until day 14. An objective index of disease activity and a histological score were required as markers of inflammation to evaluate the results of the clinical trials.

**Results:**  $\beta$ -catenin and KRT20 showed a significant increase in the proliferation index of vitamin D at a dose of 0.6  $\mu$ g/25.0 g ( $91.50 \pm 4.09$  and  $48.75 \pm 2.28$ , respectively;  $p < 0.05$ ) compared to the colitis group.

**Conclusions:** This study demonstrates that vitamin D could be used as an induction agent of Wnt activation for healing colonic mucosa via multipotent stem cells.

\* Corresponding address: Jl. Ciliwung no. 24, P.O. Box 65122, Malang, Indonesia.

E-mail: [satrio\\_wibowo@ub.ac.id](mailto:satrio_wibowo@ub.ac.id) (S. Wibowo)

Peer review under responsibility of Taibah University.



**Keywords:** Disease activity index; Inflammatory bowel disease; Multipotent stem cell; Vitamin D; Wnt pathway

© 2021 The Authors.

Production and hosting by Elsevier Ltd on behalf of Taibah University. This is an open access article under the CC BY-NC-ND license (<http://creativecommons.org/licenses/by-nc-nd/4.0/>).

## Introduction

Inflammatory bowel disease (IBD) is a chronic and recurrent inflammation of the intestine that has two forms: Crohn's disease (CD) and ulcerative colitis (UC). Various epidemiological studies have concluded that family factors, environment, nutrition, age at diagnosis and disease activity influence the prognosis of IBD.<sup>1–3</sup> IBD has become a global challenge in terms of general well-being, with regions such as Asia and South America registering an increasing incidence. In Europe, the incidence rate of UC is 0.6–24.3/100,000 population per year, whereas in Asia and the Middle East, it is 0.1–6.3/100,000 population per year. With regard to CD, the incidence rate in Europe has reached 0.3–12.7/100,000 population per year, while in Asia and the Middle East, it is 0.04–5.0/100,000 population per year.<sup>4,5</sup>

Currently, classical therapy for IBD treatment, with anti-inflammatory drugs—such as aminosalicylates or steroids—and immunosuppressants, often does not provide optimal results. On the contrary, it could have adverse side effects in the long term. In addition, 20–40% of the patients treated with these drugs had to undergo colon resection because of the side effects of long-term treatment.<sup>6,7</sup> Experts launched IBD therapy efforts that found remission was dependent on clinical, biochemical and mucosal healing. Aligned with these efforts, several regions have provided vitamin D<sub>3</sub> as adjuvant therapy in adult patients in recent years. Adjuvant therapy improves the intestinal brush-border constituent proteins, reduces apoptosis incidence and extends colonic mucosal cell proliferation.<sup>8,9</sup> The administration of vitamin D<sub>3</sub> helps activate the Wnt/ $\beta$ -catenin pathway through the vitamin D<sub>3</sub> receptor (VDR). Briefly, canonical Wnt signalling plays an important role in epithelial maintenance, which can generate transcriptional activity, cell differentiation and trigger cell proliferation. Research by Hu et al. demonstrated that 1,25(OH)<sub>2</sub>D<sub>3</sub> binding to the VDR could induce  $\beta$ -catenin, extracellular signal-regulated kinase (ERK) and signal transducer and activator of transcription 5 (STAT5) to activate the Wnt/ $\beta$ -catenin pathway as markers of the intestinal signalling activity of stem cells.<sup>10,11</sup> Furthermore, cytokeratin 20 is also used as a marker for the formation of mature enterocytes.<sup>12</sup> Accordingly, it is necessary to examine the role of vitamin D<sub>3</sub> in the activation and initiation of cell proliferation by  $\beta$ -catenin and cytokeratin 20, which would naturally lead to the renewal process through repair of the damaged colon mucosal epithelium.

## Materials and Methods

### Animals

Thirty healthy male mice with BALB/c requirements, weighing 20–25 g and aged six weeks, were sourced from the Food and Agriculture Service of Bandung, Indonesia. The mice were reared in a controlled environment in terms of temperature, light and humidity and were allowed ad libitum access to food and water.

### Protocol induction of UC and treatment with vitamin D

The dextran sulfate sodium (DSS) used in this study was purchased from MP Biomedical™ (Surabaya, Indonesia). Colitis was induced by DSS 5% with a molecular weight of 36,000–50,000 Da added to drinking water. The mice were randomly categorised into five groups. The first group, namely, the control (K–) group, was administered only Aquadest. In the second group (K+), colitis was induced with DSS 5% for seven days and followed up with distilled water for another seven days. The remaining three groups were also induced by providing drinking water containing DSS 5%. After seven days of UC induction, these three groups were administered vitamin D<sub>3</sub> (calcitriol) in different dosages. The dosages included 0.2  $\mu$ g/25.0 g/day (P1), 0.4  $\mu$ g/25.0 g/day (P2) and 0.6  $\mu$ g/25.0 g/day (P3), respectively, per round daily for seven days. All the samples were euthanised on day 14.<sup>13</sup>

### Disease Activity Index

The Disease Activity Index (DAI) was used to determine UC under protocol scoring systems published by Murthy et al. with little modification. The DAI consists of three categories: (i) weight loss, (ii) stool consistency and (iii) occult/gross rectal bleeding. The weight of the mice was measured from day 1, and weight loss was counted (in percentage) the following day. Overall DAI scores were calculated using the following equation:  $DAI = (\text{Weight loss} + \text{Stool consistency} + \text{Occult rectal bleeding})$ , and the overall score was divided by 3.<sup>14</sup>

### Histopathological score

After the mice were confirmed dead, necropsy was performed by removing the required organ (colon). Colonic tissue was then cleaned and temporarily stored in a 10% buffered formalin solution. For tissue fixation, the paraffin method was employed. Subsequently, the degree of colonic mucosa damage was examined. Haematoxylin-eosin (HE) staining was observed visually using a light microscope (Olympus BX51) with a magnification of 100 $\times$ , followed by 600 $\times$  magnification to examine changes in the cells of the colon of all treatment groups of mice. The score was verified using the Mouse Colitis Histology Index (MCHI). The MCHI score formula is as follows:  $1 \times (\text{Type of goblet cell}$

loss) + 2 × (Type of crypt density) + 2 × (Type of crypt hyperplasia) + 3 × (Type of mucosal infiltration).<sup>15</sup>

### Immunofluorescence analysis

The colonic epithelial tissues of mice were used in this study. Each tissue sample was sliced into 4 μm thickness. Immunohistochemistry was determined against the expression of β-catenin detected using the β-catenin (B-9) antibody sc-79663 (Santa Cruz Biotechnology, Inc.) and basic cytokeratin antibody sc-57004PE (Santa Cruz Biotechnology, Inc.). Double immunofluorescence staining was performed on the sample, and it was incubated for unspecified protein blocking using a double-staining blocking kit (anti-Stro-1-FITC) and monoclonal rabbit SMAD3-rhodamine. The substrate was subsequently stained with AP—namely LVBlue—for 40 min, dried and covered with glass. The sample was examined by laser scanning confocal microscopy using FluoView FV-1000 (v.1.7; Olympus).

### Statistical analysis

Statistical analysis was performed using SPSS (v.24.0; IBM Corp., Armonk, NY), and the results of measurements of control and treatment mice were statistically analysed with a significance level of 0.05 ( $\alpha = 0.05$ ) or a 95% confidence level. Parametric data were analysed using one-way analysis of variance (ANOVA), which was followed by Tukey's multiple-comparison post hoc test. To analyse nonparametric data, Kruskal–Wallis and post hoc Mann–Whitney tests were applied to compare the differences among the groups.

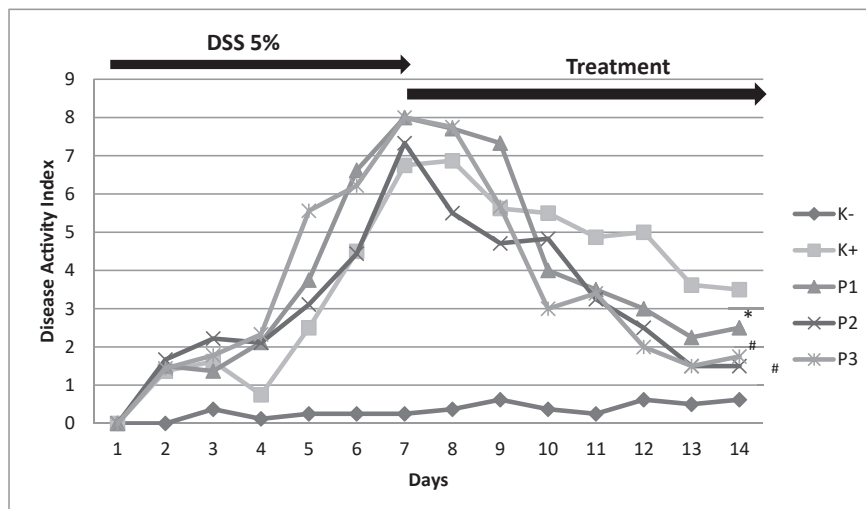
### Results

DAI was used in our study to estimate the health status of the registered mice. The line chart (Figure 1) shows that the UC model treated with DSS 5% for seven days was successful, showing the highest score in each group. The

DAI score was significantly different using the Kruskal–Wallis test ( $p = 0.016$ ;  $p < 0.05$ ) from day 1 to day 7, indicating that the mice induced by DSS would experience a rise in DAI scores. After seven days of vitamin D treatment, the scores lowered significantly in the three groups ( $p = 0.026$ ;  $p < 0.05$ ), especially at a dose of 0.4 μg/25.0 g ( $1.50 \pm 1.19$ ) and 0.6 μg/25.0 g ( $1.75 \pm 0.25$ ), which was significantly different ( $p < 0.005$ ) from the DSS-induced group ( $6.00 \pm 1.41$ ). This result shows that the group that received vitamin D<sub>3</sub> in a certain dose compared to the group induced by DSS registered improvement, clinically marked by a reduction in the DAI score, although the condition did not return to normal.

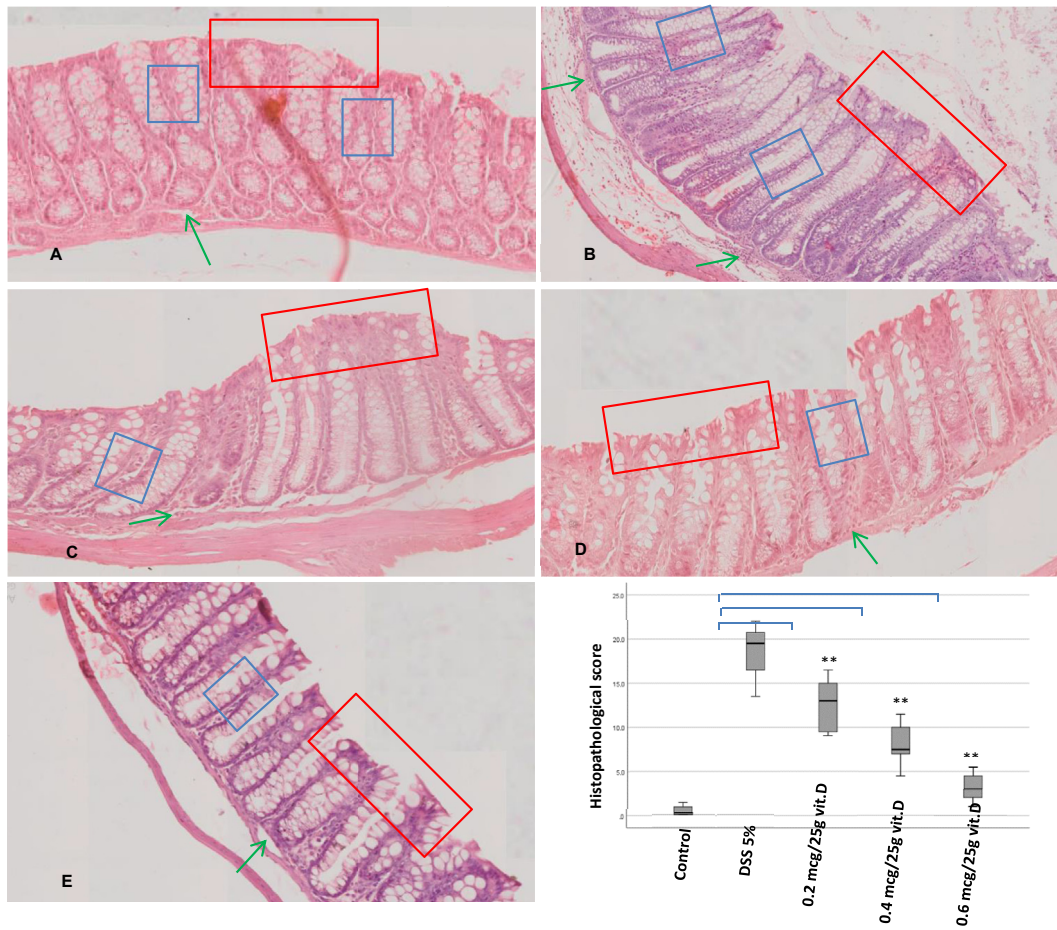
Figure 2 shows the results of HE staining in each group in the trial. The DSS-induced group showed the decay of crypt density and hyperplasia, as well as submucosal infiltration at a large extent and small numbers of goblet cells (Figure 2B). It also had the highest mean histopathological score, which was  $20.30 \pm 0.64$ . Crypt density damage and hyperplasia declined inversely with increasing doses of vitamin D administered. Crypt and goblet cells were found lined up regularly, with valid crypt density and no hyperplasia, but mild submucosal infiltration was still observed in Figures 2D and 2E compared to the control group. It is shown that vitamin D treatment ameliorated the UC condition induced by DSS. However, inflammatory cells were still observed in the mucosa, implying that the colon tissue damage caused by inflammatory cell infiltration was not completely restored. There was a significant difference in the histopathological score ( $p < 0.001$ ) among the groups administered with vitamin D, which was consistently higher than that of the UC group, indicating an excellent therapeutic effect in the repairing process of colonic mucosal tissue (Figure 2F).

To confirm the role of Wnt pathway in tissue repair, we used immunofluorescence on β-catenin to activate progenitor stem cells with vitamin D. Immunofluorescence staining revealed that vitamin D significantly enhances the activation marker of β-catenin compared to the UC group (Figure 3C–

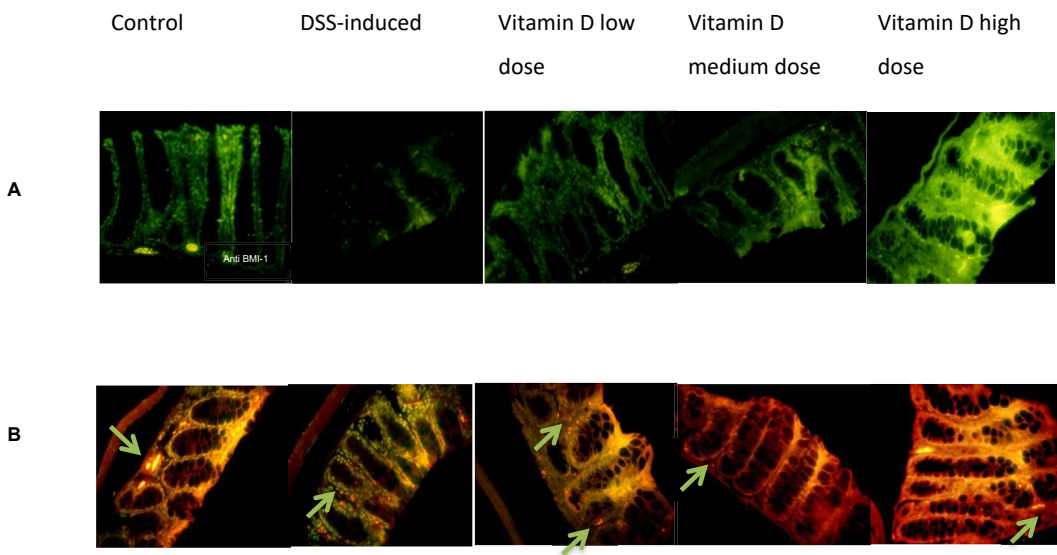


**Figure 1:** Disease Activity Index (DAI) of mice. The untreated group showed no improvement after 14 days, while treatment with D<sub>3</sub> concentration significantly improved the DAI score of colitis mice. Note: Control group (K-), DSS-induced (K+), vitamin D low dose (P1), vitamin D medium dose (P2), vitamin D high dose (P3). n = 5; \* $p < 0.05$ . # $p < 0.005$  compared with DSS-induced group in day 8 to day 14.





**Figure 2:** Histopathological image of the colon. Haematoxylin and eosin staining was performed, and the results were observed at a magnification of 400×, rod scale 50 μm. The blue box indicates crypt density; the red box indicates the presence or absence of hyperplasia; the green arrow indicates submucosal infiltration. Groups are shown as follows: (A) Control, (B) DSS-induced, (C) vitamin D low dose, (D) vitamin D medium dose, (E) vitamin D high dose. (F). Comparison of histopathological scores based on blind histopathological analysis. Values are expressed as mean ± SD. \*\*P < 0.001 compared with DSS-induced group in day 8-day 14.



**Figure 3:** Immunofluorescence staining of stem cells. (A) β-catenin. Uptake of DAPI by cells is indicated by blue coloration in cells, and anti BMI-1 staining is indicated by green fluorescence in colonic stem cells; (B) Cytokeratin 20. Anti-cytokeratin 20 staining is indicated by red fluorescence. The composite image is a combination of DAPI, anti BMI-1 and anti-cytokeratin 20 staining. The green arrows indicate colonic stem cells expressing cytokeratin 20, which glow yellow.

E). The amount of anti-Bmi staining on the vitamin D group linearly rose with the doses administered. The expression of protein  $\beta$ -catenin in the DSS-induced group ( $34.25 \pm 3.06$ ) compared to the vitamin D group with various doses reveals a significant difference ( $p < 0.05$ ).

Cytokeratin 20 (KRT20) is widely studied as a marker of differentiation in typical epithelial and colorectal cancers. This study demonstrates the appearance of this marker as an indication of successful activation and proliferation of progenitor stem cells through the Wnt/ $\beta$ -catenin pathway. Using immunofluorescence staining, the number of cell that expressing KRT20 are different between group observed. There were significant difference between control and DSS-induced group. ( $p = 0.004$ ;  $p < 0.05$ ). There were also significant enhancement of KRT20 in vitamin D groups along with the dose of vitamin D compare with DSS-induced group. There were also significant difference in number of KRT20 in DSS vs medium dose vitamin D group ( $18.75 \pm 4.66$  vs  $40.00 \pm 2.08$ ) ( $p = 0.001$ ;  $p < 0.05$ ) and in DSS vs high dose vitamin D ( $18.75 \pm 4.66$  vs  $48.75 \pm 2.28$ ) ( $p = 0.000$ ;  $p < 0.05$ ). However, the patterns of expression varied as shown in Figure 3B. The control group was sporadically expressed throughout the crypt at low and top levels of colon mucosa, whereas DSS-induced expression was enriched in the medium crypts. Meanwhile, the vitamin D group also showed a different pattern, whereas the expression of KRT20 was detected at base crypts and extended along the crypt axis. In summary, these data suggest that vitamin D may accelerate progenitor stem cell activation induced by  $\beta$ -catenin and promote the production of mature enterocytes induced by KRT20.

## Discussion

The association of vitamin D deficiency with the risk and severity of clinically relevant bowel diseases, such as IBD, led us to analyse its therapeutic effects in the management of the severity of colonic inflammation. The synthesis of active vitamin D requires renal  $1\alpha$ (OH)ase, which is encoded by Cyp27B1; thus, it can catalyse the conversion of  $25(\text{OH})\text{D}_3$  into  $1,25(\text{OH})_2\text{D}_3$ .<sup>16,17</sup> This active form of vitamin D binds to the VDR and induces transcription factors to modulate the expression of genes in a tissue-specific manner.<sup>18,19</sup> Mice lacking the VDR gene to bind to  $1,25(\text{OH})_2\text{D}_3$  have shown increased severity of experimentally induced UC.<sup>8</sup> In this study, all the groups of mice treated with vitamin D also showed a significant reduction in histopathological scores ( $p < 0.001$ ) compared to the DSS-induced group. The group with the highest dose of vitamin D had the lowest score, close to that of the control group. The histopathological characteristics at a dose of  $0.6 \mu\text{g}/25.0 \text{ g}$  also had best view similar to that of the control group, except for the submucosal inflammatory cell infiltration. The healing process in mice was observed on the fifth day of peak proliferation, while the maturation and remodelling phase was observed the following day.<sup>31</sup> Therefore, vitamin D has a therapeutic effect in mice with UC but cannot achieve the histological appearance of a healthy mucosa. Other studies have also described the link between vitamin D and colonic inflammation. A study conducted by Meckel et al. demonstrated that serum  $25(\text{OH})\text{D}_3$  concentrations were

inversely correlated with endoscopic and histological inflammation and disease activity in a cross-sectional study.<sup>20</sup> Several studies have also stated that vitamin  $\text{D}_3$  in the blood is inversely related to various inflammation markers, such as TNF- $\alpha$ , IL-6 and C-reactive protein.<sup>21–23</sup>

The provision of vitamin  $\text{D}_3$  is considered to improve intestinal brush-border constituent proteins, reduce the incidence of apoptosis and increase the proliferation of colonic mucosal cells in order to repair the colonic mucosa.<sup>18,24</sup> In this study, we found that the DSS-induced group had increased  $\beta$ -catenin without being induced by vitamin D. It was most likely triggered by stress on the colonic mucosa and the body's defence system to maintain the balance of homeostasis. In this study, improvement of mucosal repair increase along with the dose of vitamin D. Furthermore, research by Choi et al. found that activation of Wnt/ $\beta$ -catenin signalling had an effect on progenitor cell proliferation in the interfollicular epidermis under homeostatic conditions. Mucosal signalling networks in the intestine regulate the competence of the epithelial barrier to resist injury and mediate repair after damage.<sup>25–27</sup> The increasing expression of cytokeratin in this study shows progenitor cells for mature enterocytes to tissue repair after inflammation by DSS. Several studies have reported that mesenchymal stem cells can restore epithelial barrier integrity, Mesenchymal stem cells not only stimulate progenitor cells to increase epithelial regeneration but are also embedded in damaged tissues so that they can differentiate into colonic interstitial cells.<sup>28,29</sup> On the basis of the unique capability of this pathway to promote tissue repair, multipotent stem cell treatment is a promising strategy to improve mucosal healing in patients with IBD. However, there are limitations in terms of knowing the appropriate therapeutic dose and dose toxicity in this study, which have opposite effects on IBD. According to a study by Ghaly et al., the severity of UC induced by DSS would occur with high doses of vitamin D ( $\text{D}++$ ,  $10,000 \text{ IU/kg}$ ).<sup>30</sup> Further research is needed to determine the dosage range that has a perfect therapeutic effect and does not cause side effects that aggravate IBD.

## Conclusion

Vitamin D deficiency is common in people with IBD. This study found a significant association between vitamin D administration and decreased disease activity and histopathological scores. The data presented in this article explain the activation of Wnt pathway signalling to differentiate mature enterocytes from  $1,25\text{D}$ . It also provides a mechanistic basis for the therapeutic intervention of inducing potential stem cells in targeted clinical studies.

## Recommendations

In future research, it is advisable to increase the dose of vitamin D or lengthen the duration of administration. It will be sufficient to examine vitamin D levels before and after vitamin D administration so that we can determine its levels in the blood. To further verify the therapeutic effect of vitamin D, researchers could use a mouse model that is already deficient in vitamin D and subsequently induced with colitis.

## Source of funding

This research did not receive any specific grant from funding agencies in the public, commercial or not-for-profit domains.

## Conflict of interest

The authors have no conflicts of interest to declare.

## Ethical approval

This study was evaluated and approved by the Ethical Commission of Health Research, Faculty of Medicine, Universitas Brawijaya no.279/EC/KEPK-S3/10/2019.

## Authors contributions

SW conceived, designed and conducted this study, collecting, organising, analysing and interpreting the data, and also drafted the manuscript. KS collected the data, prepared the original draft and critically reviewed the draft manuscript. KH and SP provided research material and revised the draft manuscript. All authors have critically reviewed and approved the final draft and are responsible for the content and similarity index of the manuscript.

## References

- Peyrin-Biroulet L, Panés J, Sandborn WJ, Vermeire S, Danese S, Feagan BG, et al. Defining disease severity in inflammatory bowel diseases: current and future directions. *Clin Gastroenterol Hepatol* **2016**; 14(3): 348–354. <https://doi.org/10.1016/j.cgh.2015.06.001>. e17.
- Piovani D, Danese S, Peyrin-Biroulet L, Nikolopoulos GK, Lytras T, Bonovas S. Environmental risk factors for inflammatory bowel diseases: an umbrella review of meta-analyses. *Gastroenterology* **2019**; 157(3): 647–659. <https://doi.org/10.1053/j.gastro.2019.04.016>. e4.
- Lee SH, Kwon JE, Cho ML. Immunological pathogenesis of inflammatory bowel disease. *Intest Res* **2018**; 16(1): 26–42. <https://doi.org/10.5217/ir.2018.16.1.26>.
- Ng SC, Shi HY, Hamidi N, Underwood FE, Tang W, Benchimol EI, et al. Worldwide incidence and prevalence of inflammatory bowel disease in the 21st century: a systematic review of population-based studies. *Lancet* **2018**; 390(10114): 2769–2778. [https://doi.org/10.1016/S0140-6736\(17\)32448-0](https://doi.org/10.1016/S0140-6736(17)32448-0) [published correction appears in *Lancet*. 2020 Oct 3;396(10256):e56].
- Ye Y, Pang Z, Chen W, Ju S, Zhou C. The epidemiology and risk factors of inflammatory bowel disease. *Int J Clin Exp Med* **2015**; 8(12): 22529–22542.
- Sales-Campos H, Basso PJ, Alves VB, Fonseca MTC, Bonfa G, Nardini V, et al. Classical and recent advances in the treatment of inflammatory bowel diseases. *Braz J Med Biol Res* **2015**; 48(2): 96–107. <https://doi.org/10.1590/1414-431X20143774>.
- Garud S, Peppercorn MA. Ulcerative colitis: current treatment strategies and future prospects. *Therap Adv Gastroenterol* **2009**; 2(2): 99–108. <https://doi.org/10.1177/1756283X09102329>.
- Fletcher J, Cooper SC, Ghosh S, Hewison M. The role of vitamin D in inflammatory bowel disease: mechanism to management. *Nutrients* **2019**; 11(5): 1019. <https://doi.org/10.3390/nu11051019>.
- Kong J, Zhang Z, Musch MW, Ning G, Sun J, Hart J, et al. Novel role of the vitamin D receptor in maintaining the integrity of the intestinal mucosal barrier. *Am J Physiol Gastrointest Liver Physiol* **2008**; 294(1): G208–G216. <https://doi.org/10.1152/ajpgi.00398.2007>.
- Hu L, Bikle DD, Oda Y. Reciprocal role of vitamin D receptor on  $\beta$ -catenin regulated keratinocyte proliferation and differentiation. *J Steroid Biochem Mol Biol* **2014**; 144 Pt A: 237–241. <https://doi.org/10.1016/j.jsbmb.2013.11.002>.
- Shi J, Chi S, Xue J, Yang J, Li F, Liu X. Emerging role and therapeutic implication of Wnt signaling pathways in autoimmune diseases. *J Immunol Res* **2016**; 2016: 9392132. <https://doi.org/10.1155/2016/9392132>.
- Moll R, Zimbelmann R, Goldschmidt MD, Keith M, Laufer J, Kasper M, et al. The human gene encoding cytokera- tin 20 and its expression during fetal development and in gastrointestinal carcinomas. *Differentiation* **1993**; 53(2): 75–93. <https://doi.org/10.1111/j.1432-0436.1993.tb00648.x>.
- Chassaing B, Aitken JD, Malleshappa M, Vijay-Kumar M. Dextran sulfate sodium (DSS)-induced colitis in mice. *Curr Protoc Immunol* **2014**; 104: 15.25.1–15.25.14. <https://doi.org/10.1002/0471142735.im1525s104>.
- Murthy SN, Cooper HS, Shim H, Shah RS, Ibrahim SA, Sedergran DJ. Treatment of dextran sulfate sodium-induced murine colitis by intracolonic cyclosporin. *Dig Dis Sci* **1993**; 38(9): 1722–1734. <https://doi.org/10.1007/BF01303184>.
- Kitajima S, Takuma S, Morimoto M. Histological analysis of murine colitis induced by dextran sulfate sodium of different molecular weights. *Exp Anim* **2000**; 49(1): 9–15. <https://doi.org/10.1538/expanim.49.9>.
- Pike JW, Meyer MB. The vitamin D receptor: new paradigms for the regulation of gene expression by 1,25-dihydroxyvitamin D(3). *Endocrinol Metab Clin N Am* **2010**; 39(2): 255–269. <https://doi.org/10.1016/j.ecl.2010.02.007>.
- Lu R, Wu S, Xia Y, Sun J. The vitamin D receptor, inflammatory bowel diseases, and colon cancer. *Curr Colorectal Cancer Rep* **2012**; 8(1): 57–65. <https://doi.org/10.1007/s11888-011-0114-1>.
- Ardesia M, Ferlazzo G, Fries W. Vitamin D and inflammatory bowel disease. *BioMed Res Int* **2015**; 2015: 470805. <https://doi.org/10.1155/2015/470805>.
- Byers SW, Rowlands T, Beildeck M, Bong YS. Mechanism of action of vitamin D and the vitamin D receptor in colorectal cancer prevention and treatment. *Rev Endocr Metab Disord* **2012**; 13(1): 31–38. <https://doi.org/10.1007/s1154-011-9196-y>.
- Meckel K, Li YC, Lim J, Kocherginsky M, Weber C, Almoghrabi A, et al. Serum 25-hydroxyvitamin D concentration is inversely associated with mucosal inflammation in patients with ulcerative colitis. *Am J Clin Nutr* **2016**; 104(1): 113–120. <https://doi.org/10.3945/ajcn.115.123786>.
- Dadaei T, Safapoor MH, Aghdaei HA, Balaii H, Pourhoseingholi MA, Naderi N, et al. Effect of vitamin D3 supplementation on TNF- $\alpha$  serum level and disease activity index in Iranian IBD patients. *Gastroenterol Hepatol Bed Bench* **2015**; 8(1): 49–55.
- De Vita F, Lauretani F, Bauer J, Bautmans I, Shardell M, Cherubini A, et al. Relationship between vitamin D and inflammatory markers in older individuals. *Age (Dordr)* **2014**; 36(4): 9694. <https://doi.org/10.1007/s11357-014-9694-4>.
- López-Muñoz P, Beltrán B, Sáez-González E, Alba A, Nos P, Iborra M. Influence of vitamin D deficiency on inflammatory markers and clinical disease activity in IBD patients. *Nutrients* **2019**; 11(5): 1059. <https://doi.org/10.3390/nu11051059>.

24. Dou R, Ng K, Giovannucci EL, Manson JE, Qian ZR, Ogino S. Vitamin D and colorectal cancer: molecular, epidemiological and clinical evidence. **Br J Nutr** 2016; 115(9): 1643–1660. <https://doi.org/10.1017/S0007114516000696>.
25. Choi YS, Zhang Y, Xu M, Yang Y, Ito M, Peng T, et al. Distinct functions for Wnt/ $\beta$ -catenin in hair follicle stem cell proliferation and survival and interfollicular epidermal homeostasis. **Cell Stem Cell** 2013; 13(6): 720–733. <https://doi.org/10.1016/j.stem.2013.10.003>.
26. Iizuka M, Konno S. Wound healing of intestinal epithelial cells. **World J Gastroenterol** 2011; 17(17): 2161–2171. <https://doi.org/10.3748/wjg.v17.i17.2161>.
27. Nava P, Koch S, Laukoetter MG, Lee WY, Kolegraff K, Capaldo CT, et al. Interferon-gamma regulates intestinal epithelial homeostasis through converging beta-catenin signaling pathways. **Immunity** 2010; 32(3): 392–402. <https://doi.org/10.1016/j.immuni.2010.03.001>.
28. MacDonald BT, Tamai K, He X. Wnt/beta-catenin signaling: components, mechanisms, and diseases. **Dev Cell** 2009; 17(1): 9–26. <https://doi.org/10.1016/j.devcel.2009.06.016>.
29. Sémont A, Demarquay C, Bessout R, Durand C, Benderitter M, Mathieu N. Mesenchymal stem cell therapy stimulates endogenous host progenitor cells to improve colonic epithelial regeneration. **PloS One** 2013; 8(7):e70170. <https://doi.org/10.1371/journal.pone.0070170>.
30. Ghaly S, Kaakoush NO, Lloyd F, McGonigle T, Mok D, Baird A, et al. High dose vitamin D supplementation alters faecal microbiome and predisposes mice to more severe colitis. **Sci Rep** 2018; 8: 11511. <https://doi.org/10.1038/s41598-018-29759-y>.
31. Langner C, Magro F, Driessen A, Ensari A, Mantzaris GJ, Villanacci V, et al. The histopathological approach to inflammatory bowel disease: a practice guide. **Virchows Arch** 2014; 464(5): 511–527. <https://doi.org/10.1007/s00428-014-1543-4>.

**How to cite this article:** Wibowo S, Subandiyah K, Handono K, Poeranto S. Role of vitamin D in Wnt pathway activation for colonic epithelial cell differentiation. *J Taibah Univ Med Sc* 2021;16(4):575–581.