

# A case series of orf infection after the religious sacrifice feast Eid al-Adha



Dana Saade, MD, Catherine Higham, MD, and Neelam Vashi, MD  
Boston, Massachusetts

**Key words:** Muslim holiday; orf infection; zoonotic infection.

## INTRODUCTION

Orf is a viral infection first described by Newsome and Cross in 1934.<sup>1</sup> It is a zoonotic, self-limited, cutaneous disease. Commonly encountered in animal handlers such as veterinarians and farmers, it is transmitted by sheep or goats and typically has no long-term sequelae. Here we describe 3 cases of another common yet missed scenario encountered by physicians: the appearance of characteristic lesions after the yearly celebration of Eid al-Adha (alternatively known as the Sacrifice Feast), a practice by Muslim patients. In this religious ceremony, sheep are sacrificed to God, as a symbol of devotion, faith, and commemoration of Ibrahim sacrificing his son for God.

## CASE 1

A 42-year-old man presented urgently to the dermatology clinic for an abnormal growth on his right index finger. He reported sustaining a minor cut at the site a few weeks prior with subsequent growth of a pustule despite proper wound care. He reported that the pustule then evolved into a large, red nodule. Upon further questioning, the patient admitted to slaughtering a sheep for the Eid al-Adha Muslim holiday. He denied lesion pain but did indicate right axilla pain. On physical examination, a 1.5-cm targetoid nodule was noted at the medial proximal second phalange. It had an erythematous infiltrated rim with a pale center and no associated discharge or bleeding (Fig 1). Erythema along the lymphatics was noted (Fig 1), and a large tender lymph node was palpated in the right axillae. Shave biopsy findings with hematoxylin-eosin stain were

consistent with an orf infection. The patient was sent home with topical antibiotics and observation. No complications occurred subsequently.

## CASE 2

A 45-year-old man presented to the emergency department with a 10-day history of painless lesions on his left forearm. He reported onset 3 days before presentation. Only upon further questioning did the patient bring about a history of being scratched in the affected area by a sheep while slaughtering it for the religious celebration, Eid al-Adha. He denied any systemic symptoms. On physical examination, there were 5 edematous erythematous nodules with surrounding erythema arranged in a sporotrichoid pattern on the patient's left forearm. Light pink erythema extended up his left arm in a lymphangitic distribution (Fig 2). Two 4-mm punch biopsy sections were taken from the larger nodules. Pathology findings were suggestive of a viral infection such as orf. Periodic acid–Schiff stain was negative for fungal organisms. Real-time polymerase chain reaction analysis confirmed the presence of parapoxvirus. Wound culture grew methicillin-sensitive *Staphylococcus aureus*. The patient was treated with levofloxacin for suspected secondary bacterial cellulitis. On follow-up 2 weeks later, the lesions were resolving without complication. Postinflammatory hypopigmentation was noted.

## CASE 3

Our third patient was a 66-year-old man who presented to the dermatology clinic for 2 lesions growing on his thumb. He reported that 2 weeks

From the Department of Dermatology, Boston University School of Medicine.

Funding sources: None.

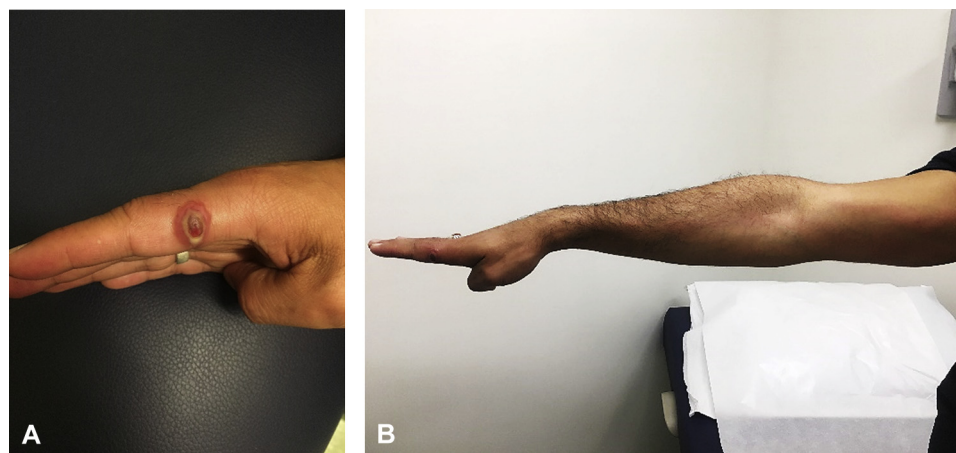
Conflicts of interest: None disclosed.

Correspondence to: Neelam A. Vashi, MD, Assistant Professor of Dermatology, Director, Boston University Center of Ethnic Skin, and Director of Research in Cosmetic and Laser Medicine, Boston University School of Medicine, 609 Albany St, J108, Boston, MA 02118. E-mail: [nvashi@bu.edu](mailto:nvashi@bu.edu).

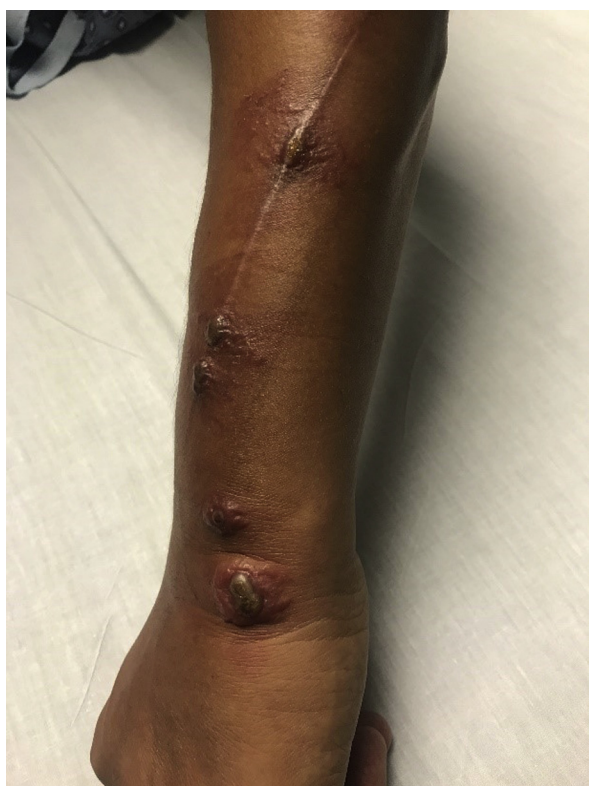JAAD Case Reports 2018;4:489-92.  
2352-5126

© 2018 by the American Academy of Dermatology, Inc. Published by Elsevier, Inc. This is an open access article under the CC BY-NC-ND license (<http://creativecommons.org/licenses/by-nc-nd/4.0/>).

<https://doi.org/10.1016/j.jdc.2018.01.007>



**Fig 1.** **A**, Rapidly growing nodule with an erythematous infiltrated rim and pale white center on the index finger of the right hand. **B**, Lymphangitis along the arm is observed.



**Fig 2.** Sporotrichoid distribution of erythematous nodules with a central dusky center over the left arm.

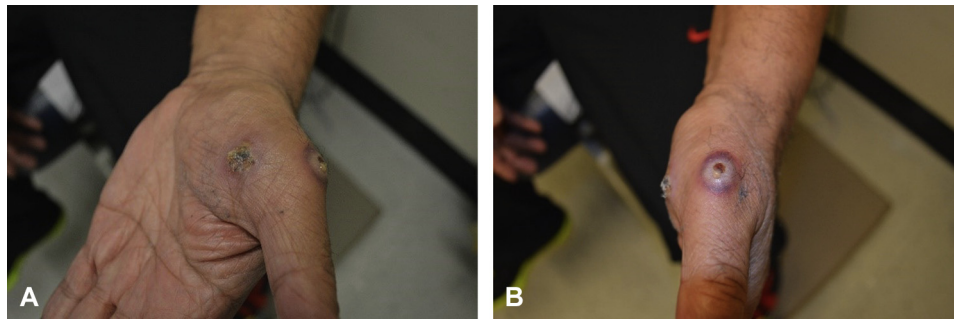
prior, he noticed an initial lesion on the palmar side of his thumb followed by the appearance of a second lesion on the dorsal aspect of his thumb. They were somewhat painful to touch. The patient reported a history of contact with sheep 2 weeks before the appearance of the growths. It coincided with the Eid al-Adha celebration, and the patient acknowledged handling sheep at that time. On physical examination, a single erythematous nodule covered by

yellow dry crust was noted on the left palmar thumb with a larger nodule surrounded by violaceous rim on the dorsal thumb (Fig 3). Orf was clinically diagnosed. The patient was reassured about the self-limiting nature of the condition and advised to wait for its resolution, which occurred within 2 weeks.

## DISCUSSION

Orf, or ecthyma contagiosum, is an infection that usually infects sheep and goats. The virus belongs to the parapox genus of DNA viruses.<sup>2</sup> It can be transmitted to humans by direct inoculation causing a zoonotic infection.<sup>2</sup> The typical orf cutaneous manifestation is usually a solitary nodule at the site of inoculation, most often a cut or abrasion at the distal extremities (hands, fingers) sustained by the patient. The nodule appears a few days after contact and progresses through 6 stages.<sup>3</sup> Each stage lasts a week, and eventually the infection self-resolves after approximately 6 weeks. The first stage is the maculopapular stage appearing as a red nodular lesion, followed by a targetoid stage, then the acute phase with hemorrhage and weeping, and finally regenerative, papillomatous, and repressive stages take place until resolution of the lesion.<sup>3</sup> To the best of our knowledge, our second case describes the first description of orf in a sporotrichoid fashion, presenting linearly along the left arm's lymphatics.

Proper history is vital in such cases. Exposure to animals, particularly sheep or goats, is essential to narrow the differential and obtain an accurate diagnosis. Biopsy may be helpful to confirm the diagnosis when history or clinical examination is not persuasive. The differential diagnosis of orf should



**Fig 3.** **A**, Crusted nodule over the palmar hand. **B**, A larger weeping nodule at the base of the thumb of the left hand.

include milker's nodule (caused by paravaccinia virus), fish tank granuloma, pyogenic granuloma, keratoacanthoma, fungal infection, and cutaneous anthrax.

Treatment is usually not necessary, and reassurance should be provided to the patient. However, this benign disease can be complicated by pain, bacterial superinfections, lymphangitis, and regional lymphadenitis.<sup>3</sup> Treatment is based on keeping the lesion free of any superinfection and treating with antibiotics at any sign of bacterial infection. Treatment may be deemed necessary in persistent cases such as those in immunocompromised patients. Case reports have described successful treatment in both immunocompromised and immunocompetent patients with imiquimod application.<sup>4,5</sup> Cidofovir antiviral, administered topically or intravenously, has also been used with positive results.<sup>6</sup> Interferon-2b intralesional injections, along with oral acyclovir or interferon- $\alpha$  systemically have been used in cases of "giant" orf in immunocompromised patients.<sup>7,8</sup> Surgical management is usually reserved for resistant cases with a shave excision helping to confirm the diagnosis and relieve pain or a distraught patient.<sup>3</sup> Cryotherapy with liquid nitrogen has been reported to help speed the recovery.<sup>9</sup> Curettage and electrodesiccation is a final resort in persistent cases.<sup>3</sup>

Although orf infections are usually encountered in farmers and veterinarians, reports of orf seen after a particular Muslim holiday, Eid al-Adha, are not unusual. During the Sacrifice Feast, it is customary to sacrifice a sheep for Allah, God, as a reinterpretation of when God asked Ibrahim to sacrifice his son Isaac.<sup>10</sup> Eid al-Adha falls on different dates every year, as Muslim holidays follow the lunar Islamic calendar. It typically falls on the 10th day of Dhu al-Hijjah, the 12th and final month in the Islamic calendar, moving approximately 11 days earlier

each year. It is important for dermatologists and clinicians encountering such rare cases to keep in mind the patients' religious backgrounds and practices. These 3 cases show the importance of the dermatology consultation with clinical examination and knowledge of certain cultural practices. Often patients are unaware or embarrassed to reveal associated practices. Patients may not think that a certain act was associated with the skin findings, as it is a yearly tradition with no history of similar sequelae. In addition, the appearance of orf can be quite striking with both the primary lesion and lymphangitic spread that can be associated. This can lead to unnecessary hospital admissions, procedures, and treatments by clinicians who have little awareness about this disease entity and typical presentations. In this time of proper resource allocation, increasing health care costs, and increasing antibiotic resistance, proper prompt and correct diagnosis is important. By knowledge of the associations of Eid al-Adha and proper history taking, patients can be saved unnecessary treatments, procedures, and inpatient stays.

#### REFERENCES

1. Newsome IE, Cross F. Sore mouth in sheep transmissible to man. *J Am Vet Med Assoc.* 1934;84:790-802.
2. Bergqvist C, Kurban M, Abbas O. Orf virus infection. *Rev Med Virol.* 2017;27(4), 10.1002/rmv.1932.
3. Georgiades G, Katsarou A, Dimitroglou K. Human ORF (ecthyma contagiosum). *J Hand Surg Br.* 2005;30(4):409-411.
4. Erbağci Z, Erbağci I, Almıla Tuncel A. Rapid improvement of human orf (ecthyma contagiosum) with topical imiquimod cream: report of four complicated cases. *J Dermatolog Treat.* 2005;16(5-6):353-356.
5. Lederman ER, Green GM, DeGroot HE, et al. Progressive ORF virus infection in a patient with lymphoma: successful treatment using imiquimod. *Clin Infect Dis.* 2007;44(11): e100-e103.
6. De Clercq E. Clinical potential of the acyclic nucleoside phosphonates cidofovir, adefovir, and tenofovir in treatment of DNA virus and retrovirus infections. *Clin Microbiol Rev.* 2003; 16(4):569-596.

7. Ran M, Lee M, Gong J, Lin Z, Li R. Oral acyclovir and intralesional interferon injections for treatment of giant pyogenic granuloma-like lesions in an immunocompromised patient With human orf. *JAMA Dermatol.* 2015;151(9):1032-1034.
8. Ertekin SS, Gurel MS, Erdemir AVT, Leblebici C. Systemic interferon alfa injections for the treatment of a giant orf. *Cutis.* 2017;99(5):E19-E21.
9. Ocampo Candiani J, González Soto R, Welsh Lozano O. Orf nodule: treatment with cryosurgery. *J Am Acad Dermatol.* 1993;29(2 Pt 1):256-257.
10. Carter C, Alkhshali H. 5 things to know about the Muslim holiday of Eid al-Adha. Thu September 24, 2015 <http://www.cnn.com/2012/10/26/world/eid-5-things/index.html>. Accessed 09, 2017.