

Case Report

Therapy with propylthiouracil for T3-predominant neonatal Graves' disease: a case report

Emi Hamajima¹, Masahiro Noda¹, Emina Nai¹, Satoka Akiyama¹, Yoji Ikuta¹, Natsuko Obana¹, Takahiro Kawaguchi¹, Kenta Hayashi¹, Kunihiro Oba¹, Tomohiro Yoshida¹, Tatsuo Katori¹, and Masayuki Kokaji¹

¹ Department of Pediatrics, Showa General Hospital, Tokyo, Japan

Abstract. This case report describes a male neonate with Graves' disease. The mother's pregnancy was complicated by poorly controlled Graves' disease. The neonate was diagnosed with thyroxine (T3)-predominant Graves' disease with low free triiodothyronine (T4) and high free T3 during antithyroid drug therapy. The patient also presented with persistent pulmonary hypertension of the newborn due to hyperthyroidism and airway stenosis caused by goiter. It was difficult to control thyroid function and maintain free T4 levels with inorganic iodine, thiamazole, and levothyroxine sodium hydrate. We successfully controlled thyroid function using the previous treatments in combination with propylthiouracil. Propylthiouracil suppresses type 1 iodothyronine deiodinase, and its pharmacological action suppresses the conversion of T4 to T3. Therefore, we used propylthiouracil at an earlier stage of intervention in this case. We ceased administration of antithyroid drugs on day 85 of life. Subsequently, as the TRH loading test revealed central hypothyroidism, oral administration of levothyroxine sodium hydrate was continued. Its administration was discontinued at the age of 1 yr. Thyroid-stimulating hormone recovered to normal values, and his development had progressed without complications by the age of 2 yr.

Key words: T3-predominant Graves' disease, propylthiouracil, central hypothyroidism, airway stenosis, persistent pulmonary hypertension of the newborn

Introduction

Maternal thyroid autoantibody and therapeutic drugs can be transferred to the fetus transplacentally in a pregnancy complicated by Graves' disease, and the fetus may develop neonatal Graves' disease. The majority of

neonates born to women with Graves' disease do not require treatment. However, approximately 2% develop neonatal Graves' disease (1, 2). These neonates may also develop transient central hypothyroidism because a hyperthyroid fetal environment impairs the maturation of the fetal hypothalamic-pituitary-thyroid system (3).

Neonatal Graves' disease can be treated with an antithyroid drug and inorganic iodine. In addition, beta blockers for tachycardia and levothyroxine sodium hydrate (LT4) are also used if free triiodothyronine (T4) (FT4) levels decline. Common complications of neonatal Graves' disease include arrhythmia, heart failure, airway stenosis due to goiter, and craniosynostosis.

Received: January 4, 2017

Accepted: March 19, 2018

Corresponding author: Dr. Emi Hamajima, Department of Pediatrics, Showa General Hospital, 8-1-1 Hanakoganei, Kodaira-shi, Tokyo 187-8510, Japan
E-mail: emi.tam988@gmail.com

This is an open-access article distributed under the terms of the Creative Commons Attribution Non-Commercial No Derivatives (by-nc-nd) License <<http://creativecommons.org/licenses/by-nc-nd/4.0/>>.

Case Presentation

Patient

A male neonate at day 0 of life.

The course of the mother's pregnancy

The mother was 38 yr old, gravida 4, para 2. She developed thyroxine (T3)-predominant Graves' disease (T3-P-GD) 3 yr prior to the current pregnancy. Her thyroid-stimulating hormone (TSH) receptor antibody (TRAb) level was high (382 IU/L). TRAb measurement was performed using a commercial 3rd-generation electro-chemiluminescence immunoassay kit. Her TSH stimulating antibody (TSAb) level was 825%. TSAb was measured using the Bioassay radioimmunoassay method. Despite oral administration of thiamazole 15 mg/d (methimazole [MMI]), her thyroid function was poorly controlled, and pregnancy was not recommended by her physician. The mother did not report her pregnancy to her attending physician in early gestation. She visited our hospital at 14 wk of gestation. At that time, she was experiencing palpitations and was in a state of thyrotoxicosis. Her physician prescribed oral potassium iodide (KI) and later increased the MMI dose. At 21 wk of gestation, her FT4 was low; thus, her physician prescribed oral LT4, after which her free T3 (FT3) became elevated. At 28 wk of gestation, the fetus developed tachycardia, cardiomegaly, and goiter, as on ultrasonography. We diagnosed fetal Graves' disease, and her physician subsequently ceased oral administration of LT4 and used MMI alone for control. The fetal tachycardia and cardiomegaly subsequently improved. At 35 wk and 4 d of gestation, the mother was hospitalized for the onset of labor and underwent an emergency cesarean section due to a breech presentation (Fig. 1).

History of present illness

At birth, polypnea and depressed respiration were observed. The Apgar scores were 4 (pulse 2, activity 2) and 7 (appearance 1, grimace 1, pulse 2, activity 2, respiration 1) at the 1- and

5-min test, respectively. He was admitted to the neonatal intensive care unit (NICU) because of prematurity, low birth weight, and respiratory distress.

Physical findings: Birth weight, 2,147 g; birth height, 48.1 cm; and head circumference, 31.0 cm.

Vital signs: Body temperature, 36.7°C; heart rate, 187 bpm; blood pressure, 66/33 mmHg; respiratory rate, 52/min; and oxygen saturation (SpO₂) 90% (FiO₂, 0.3). General status: no irritability was observed. Head: the anterior fontanel was flat, and exophthalmos was mild. Cervical region: enlargement of the thyroid gland was observed (Fig. 2A). Chest: air entry was poor on auscultation. The abdominal palpation was flat and soft with no hepatosplenomegaly. External genitalia: male, with no apparent external malformations.

Results

Based on the blood test results, his venous blood gas showed signs of metabolic acidosis, while the other blood test results were normal. His thyroid functions were not clearly abnormal at the time of birth, but his thyroid autoantibody levels were high. (Table 1)

Cardiomegaly, with a cardiothoracic ratio of 69%, was diagnosed based on a chest X-ray; reticular granular shadows were observed in the lung fields. The stable microbubble test result was rated as weak. No cardiovascular malformation was observed on cardiac ultrasound. The ejection fraction was 66%. The estimated right ventricular pressure obtained from tricuspid valve regurgitation was 69 mmHg. End-systolic ventricular septal flattening was noted. Pulmonary hypertension was confirmed. The ductus arteriosus and foramen ovale showed a bidirectional shunt. Thyroid enlargement (0.63 cm at the isthmus and 4.1 cm in transverse diameter) and a marked increase in thyroid blood flow were confirmed by ultrasonography (Fig. 2B).

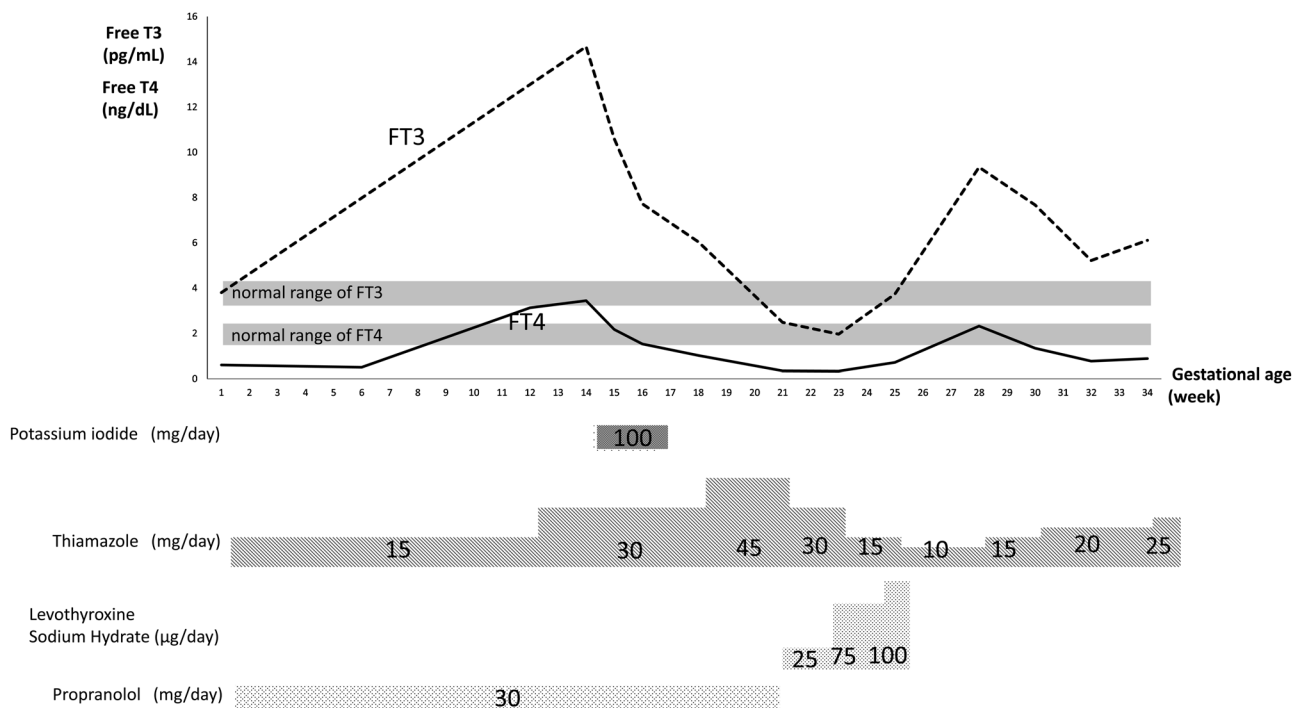


Fig. 1. Course of the mother’s pregnancy. She was in a state of thyrotoxicosis, when she visited our hospital at 14 wk of gestation. After that, it was difficult to control her thyroid function. We diagnosed fetal Graves’ disease at 28 wk gestation. At 35 wk and 4 d of gestation, the mother underwent an emergency cesarean section due to a breech presentation.

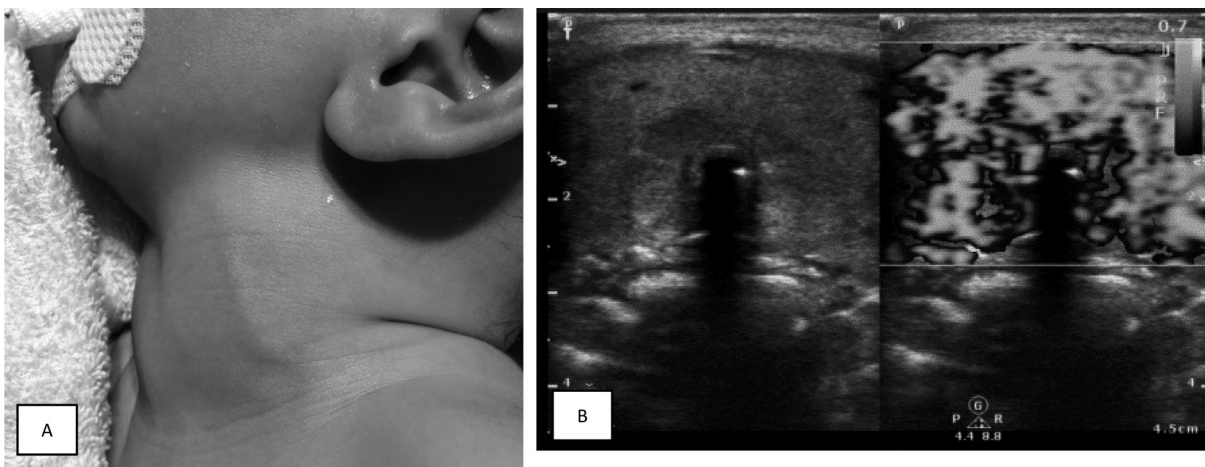


Fig. 2. A: enlargement of the thyroid gland. His thyroid gland enlargement from birth. B: marked increase in thyroid blood flow. The blood flow of the thyroid gland was diffusely increased.

Course of treatment

After admission to the NICU, we diagnosed the patient with neonatal respiratory distress syndrome, based on the chest X-ray and the

stable microbubble test. Therefore, we performed endotracheal intubation with ventilator management and administered surfactant. We also administered sodium bicarbonate

Table 1. Blood test results at the time of birth

Blood biochemistry		Blood count		Thyroid function	
TP	5.7 g/dL	Hb	18.6 g/dL	TSH (CLIA)	0.01 μ IU/mL (0.5–5.0)
ALb	3.6 g/dL	RBC	$521 \times 10^4 /\mu\text{L}$	FT4 (CLIA)	0.88 ng/dL (0.9–1.7)
T-Bil	2.6 mg/dL	Ht	58.5 %	FT3 (CLIA)	4.6 pg/mL (2.3–4.0)
ALP	536 IU/L	PLT	$20.9 \times 10^4 /\mu\text{L}$	<u>TR-Ab</u> (ECLIA)	<u>196.7</u> IU/mL (< 1.9)
AST	25 IU/L	WBC	16850 $/\mu\text{L}$	<u>TSAb</u> (Bioassay EIA)	<u>3800</u> % (< 120)
ALT	6 IU/L			<u>TSBAb</u> (Bioassay EIA)	<u>173.9</u> % (< 31.7)
LD	369 IU/L	Venous blood gas			
CK	215 IU/L				
Na	140 mEq/L	pH	<u>7.07</u>		
K	5.1 mEq/L	pCO ₂	<u>73.3</u> mmHg		
Cl	106 mEq/L	HCO ₃	<u>20.8</u> mmol/L		
Ca	9.5 mg/dL	BE	<u>-11.4</u> mmol/L		
IP	6.8 mg/dL	GLu	72 mg/dL		
Mg	2.2 mg/dL	Lac	3.1 mg/dL		
BUN	5 mg/dL				
CRE	0.43 mg/dL				
CRP	< 0.01 mg/dL				

to treat prominent mixed acidosis. However, the respiratory status remained poor, and hypoxemia persisted. SpO₂ differed between the upper and the lower limbs, and pulmonary hypertension had worsened on ultrasonography. Therefore, we diagnosed persistent pulmonary hypertension of the newborn (PPHN). We started nitric oxide (NO) inhalation, and the treatment was ceased after confirming left-to-right shunt flow conversion.

This neonate did not show hyperthyroid symptoms at birth. However, irritability and tachycardia developed and due to increased thyroid function serum levels on day 2 of life, oral administration of KI and MMI was started. The following day, oral administration of KI was stopped since thyroid function was significantly decreased. As thyroid function continued to decline and FT4 levels fell, we began oral administration of LT4. However, FT3 rose again on day 8 of life, and tachycardia was identified. Therefore, we administered oral KI and propranolol. Nonetheless, FT3 again became prominently elevated when FT4 normalized with oral administration of LT4. Tachycardia developed, and we found cardiac dilatation on

the chest X-ray on day 16 on life. We started oral administration of digoxin for reducing the heart load. Conversely, FT4 became prominently decreased when FT3 normalized with increases in the dosages of KI and MMI. Control of thyroid function was difficult to achieve in this patient using combination therapy with KI and MMI. Therefore, we began oral administration of propylthiouracil (PTU) combined with MMI at day 22 of life with the consent of his parents, and control of thyroid function was subsequently obtained. We monitored the side effects of MMI and PTU once a week, and the neutrophil and liver enzyme levels were always normal, with no symptoms suggesting vasculitis, fever, eruption, etc.

With regard to nursing, breastfeeding had ceased at the discretion of the mother's endocrinologist, and with the mother's consent. Tube feeding was started after birth, and low-birth-weight infant formula was used to promote weight gain from day 8 of life. At approximately 3 weeks after birth, accompanied by the stabilization of thyroid function and the commencement of oral feeding, the patient's weight was observed to have increased.

During treatment, airway stenosis symptoms appeared due to a goiter. When we attempted decannulation on day 5 and day 14 of life, we performed reintubation due to airway stenosis. We then performed decannulation on day 28 of life. After treatment, the condition of the patient improved, and he was discharged on day 50 of life.

His TRAb decreased to 4.9 IU/L by day 63 of life. We ceased administration of KI on day 63, MMI on day 74, and PTU on day 85 of life. One week later, we confirmed that TRAb was negative. We discontinued the oral administration of LT4; as a result, the FT4 levels subsequently decreased. Therefore, we resumed oral administration of LT4. TSH also continued to decrease. Since central hypothyroidism was revealed by the results of the TRH loading test, oral administration of LT4 was continued. After that, the LT4 dosage was gradually decreased, and its administration was discontinued at the age of 1 yr. By the age of 2 yr, TSH had recovered to normal levels, and his development was progressing without complications (Fig. 3).

Discussion

The risk of neonatal Graves' disease is known to be higher in the context of a maternal TSAb level greater than 500% of the baseline level (2). Our patient was born to a mother whose thyroid function was under poor control, with a TRAb level of 382 IU/L and a TSAb level of 825%. The infant was previously diagnosed as having fetal Graves' disease and was at high risk of developing neonatal Graves' disease.

In the neonatal period, FT4 is essential for the myelination of glial cells in the brain (4, 5). It was, however, difficult to control thyroid function while maintaining FT4 in the normal range in our case. Based on the treatment course, T3-P-GD was diagnosed.

T3-P-GD presents with prominently elevated type 1 iodothyronine deiodinase (D1) activity and type 2 iodothyronine deiodinase (D2)

activity. In this case of Graves' disease, FT3 was elevated; this is known to be difficult to manage in adults (6–8). Oral administration of PTU was initiated, as it suppresses D1 activity, and its pharmacological action suppresses conversion of T4 to T3 (9). As the mother had T3-P-GD and the neonate appeared to have high D1 activity like his mother, we selected PTU at an earlier stage of intervention in the present case. We anticipated that thyroid function might deteriorate if MMI therapy was stopped before the efficacy of PTU was established. Thus, we opted for combination therapy with MMI and PTU. As a result, we managed to control the neonatal thyroid function while maintaining FT4 levels.

In 2012, Takagi *et al.* reported the use of combination therapy with MMI and PTU in Japanese adults with T3-P-GD (10). However, this regimen has not been reported in children or neonates.

In contrast, because PTU often has more severe side effects than MMI, the current guidelines indicate that it should be used exceptionally (11). Therefore, cases of using PTU for neonatal Graves' disease are rare, and only 1 case has been reported by Aida *et al.* in 2002 (12). We were unable to control thyroid function using MMI and used PTU for various reasons described earlier. We found no adverse events due to PTU in this case but more careful monitoring of other parameters, including renal function and urinalysis, is recommended.

In this case, TRAb became negative. However, the FT4 level was low, and TSH expression continued to be suppressed beyond our expectation. As central hypothyroidism after transient hyperthyroidism has been reported in newborns (12), the TRH loading test was performed, and the results revealed central hypothyroidism. We hypothesized that a hyperthyroid fetal environment impairs the maturation of the fetal hypothalamic-thyroid system. Therefore, if the thyroid hormone excess-state subsequently disappears, or even if the patient goes into thyroid hormone

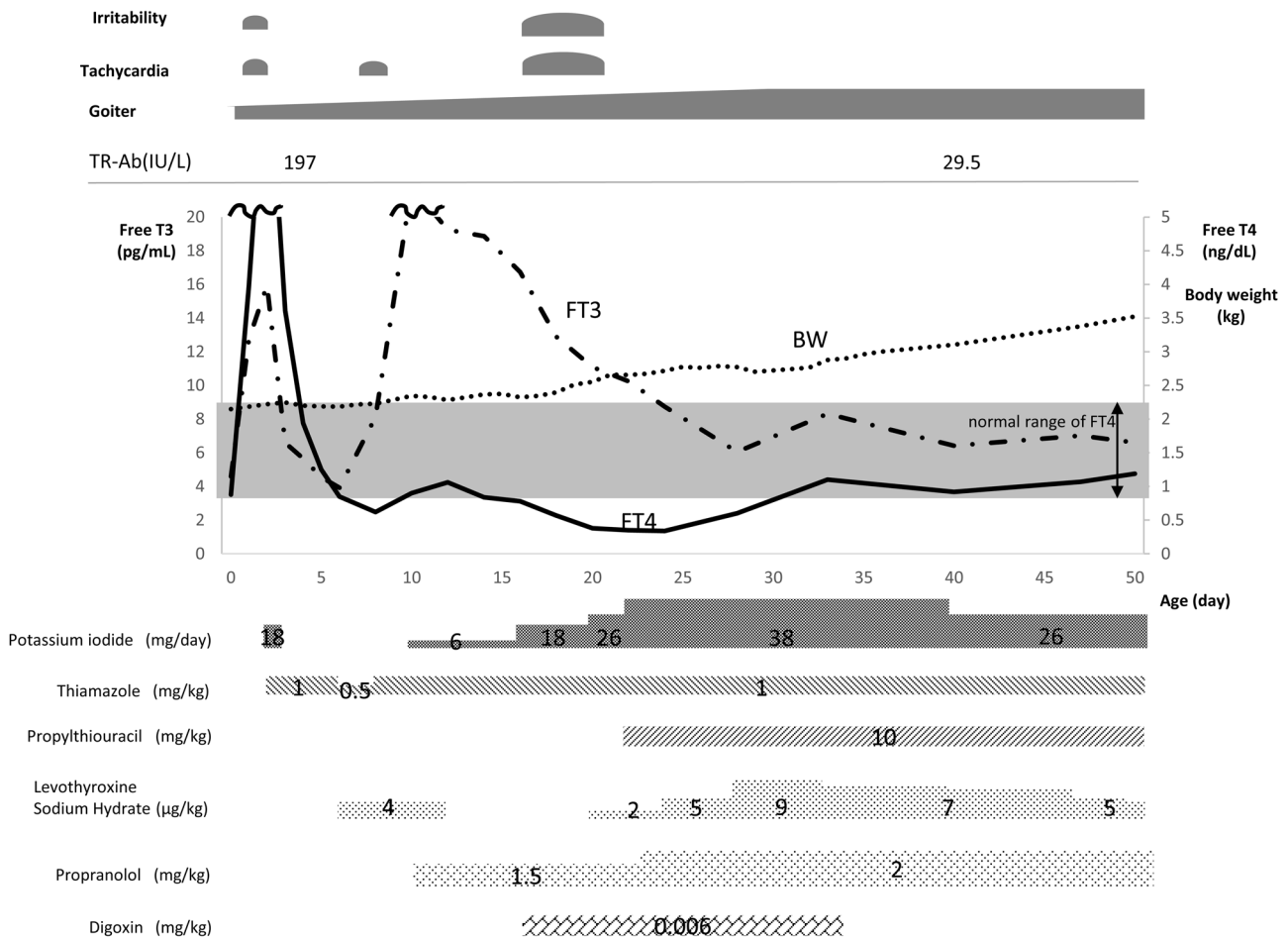


Fig. 3. Clinical course, symptoms, thyroid function, and treatments in hospital. The neonate developed hyperthyroidism from day 2 of life, and the thyroid function was difficult to control using combination therapy with KI and MMI. In addition, PTU started from 22 d of life; subsequently, it was possible to control his thyroid function while maintaining his FT4 levels. He was discharged on day 50 of life.

secretion failure, it is presumed that the TSH secretion ability of the pituitary gland possibly cannot be recovered (3, 12). In addition, not only hyperthyroidism in the fetal stage but also postnatal hyperthyroidism caused by high maternal anti-thyroid antibody level can result in subsequent central hypothyroidism.

The child required oral administration of LT4 after birth to 1 yr of age. As mentioned previously, LT4 is essential for neurodevelopment in children; thus, we believe that careful monitoring of his neurological prognosis will be necessary in the future.

Moreover, our patient had severe

complications, including neonatal asphyxia, PPHN, and airway stenosis caused by goiter. In terms of the neonatal asphyxia, fetal hypoxemia and ischemia were not evident, and therefore neonatal Graves' disease was considered to be a cause. The relationship between pulmonary hypertension and hyperthyroidism is well known in adults. We presume that the primary factor in the exacerbation of the PPHN was hyperthyroidism in our case as well. Increased metabolism in hyperthyroidism causes chronic hypoxemia during the fetal and neonatal periods, and hypertrophy of unstrained pulmonary arterial muscle results in PPHN

(13). Thyroglobulin produces NO synthase inhibitors and reduces the expression of thyroid transcription factor-1, which is responsible for the production of surfactant (13, 14). We assume that a combination of the above factors led to PPHN. In our case, PPHN persisted for approximately 1 month and subsided as control of the thyroid function was achieved. Obeid *et al.* (13) and Oden *et al.* (14) also reported a case in which they administered NO by inhalation to patients with PPHN caused by neonatal Graves' disease. In our case, endotracheal intubation was necessary due to airway stenosis caused by a growing goiter after birth.

As this was a case of T3-P-GD, thyroid function was difficult to control while maintaining FT4 levels. Eventually, we successfully managed to maintain FT4 levels using PTU.

Many cases of neonatal Graves' disease naturally achieve remission without treatment. However, severe pathologies such as PPHN and airway stenosis may present in cases in which the mother's thyroid function is poorly controlled, as in our case. In addition, the condition may also exhibit central hypothyroidism even after completing the treatment for neonatal Graves' disease. Therefore, comprehensive care may be required. Careful monitoring is essential when treating neonatal Graves' disease.

Conflict of Interest: None of the authors received any support in the form of grants, equipment, or drugs.

References

- Huang SA, LaFranchi SH. Congenital hyperthyroidism. In: Kliegman RM, Stanton BF, St. Gene JW, Schor NF, Behrman RE, editors. Nelson textbook of Pediatrics. 20th ed. Elsevier; 2016. p. 2684, 2685.
- Lafranchi S, Hanna CE. Hyperthyroidism in the neonatal period and childhood. In: Braverman LE, Cooper DS, editors. Werner and Ingbar's the thyroid -- A fundamental and Clinical text. 10th ed. Lippincott Williams and Wilkins; 2013. p.803.
- Kempers MJE, van Tijn DA, van Trotsenburg ASP, de Vijlder JJ, Wiedijk BM, Vulsmas T. Central congenital hypothyroidism due to gestational hyperthyroidism: detection where prevention failed. *J Clin Endocrinol Metab* 2003;88: 5851–7. [[Medline](#)] [[CrossRef](#)]
- Santisteban P, Bernal J. Thyroid development and effect on the nervous system. *Rev Endocr Metab Disord* 2005;6: 217–28. [[Medline](#)] [[CrossRef](#)]
- Zoeller RT, Rovet J. Timing of thyroid hormone action in the developing brain: clinical observations and experimental findings. *J Neuroendocrinol* 2004;16: 809–18. [[Medline](#)] [[CrossRef](#)]
- Ito M, Toyoda N, Nomura E, Takamura Y, Amino N, Iwasaka T, *et al.* Type 1 and type 2 iodothyronine deiodinases in the thyroid gland of patients with 3,5,3-triiodothyronine-predominant Graves disease. *Eur J Endocrinol* 2011;164: 95–100. [[Medline](#)] [[CrossRef](#)]
- Laurberg P, Vestergaard H, Nielsen S, Christensen SE, Seefeldt T, Helleberg K, *et al.* Sources of circulating 3,5,3-triiodothyronine in hyperthyroidism estimated after blocking of type 1 and type 2 iodothyronine deiodinases. *J Clin Endocrinol Metab* 2007;92: 2149–56. [[Medline](#)] [[CrossRef](#)]
- Harvengt J, Boizeau P, Chevenne D, Zenaty D, Paulsen A, Simon D, *et al.* Triiodothyronine-predominant Graves disease in childhood: detection and therapeutic implications. *Eur J Endocrinol* 2015;172: 715–23. [[Medline](#)] [[CrossRef](#)]
- Bianco AC, Kim BW. Intracellular pathways of iodothyronine metabolism/ Implications of deiodination for thyroid hormone action. In: Braverman LE, Cooper DS, editors. Werner and Ingbar's the thyroid --A fundamental and clinical text. 10th ed. Lippincott Williams and Wilkins; 2013. p.107, 108.
- Takagi S, Konishi Y, Komatsu Y, Nishimura Y, Miyazaki T, Furuya R, *et al.* Two cases of combination therapy with Thiamazole and Propylthiouracil for untreated thyroid crisis. *Folia Endocrinologica Japonica* 2012;88: 507 (In

- Japanese).
11. Sato K, Sasaki N, Harada S, Tanaka T, Akasu F, Asayama K, *et al.* Guideline for childhood-onset Graves' disease 2008. *J Jpn Pediatr Soc* 2008;112: 946–52 (In Japanese).
 12. Aida T, Egashira M, Itou M, Imamura Y, Kan Y, Kan N, *et al.* A Case of central hypothyroidism following transient neonatal hyperthyroidism. *J Jpn Pediatr Soc* 2002;106: 1020–4.
 13. Obeid R, Kalra VK, Arora P, Quist F, Moltz KC, Chouthai NS, *et al.* Neonatal thyrotoxicosis presenting as persistent pulmonary hypertention. *BMJ Case Rep.* 2012. doi: 10.1136/bcr.02.2012.5939.
 14. Oden J, Cheifetz IM. Neonatal thyrotoxicosis and persistent pulmonary hypertension necessitating extracorporeal life support. *Pediatrics* 2005;115: e105–8. [[Medline](#)] [[CrossRef](#)]