



A novel lozenge containing bupivacaine as topical alleviation of oral mucositis pain in patients with head and neck cancer: a pilot study

Stine Mogensen^{a,*}, Charlotte Trelde^a, Kolbrún Sveinsdóttir^a, Kenneth Jensen^b, Claus A. Kristensen^c, Torben S. Mogensen^a, Janne Petersen^{a,d}, Ove Andersen^a

Abstract

Introduction: Oral mucositis induces severe oral pain in head and neck cancer patients. There is at this point no effective pain treatment without considerable side effects.

Objective: The aim of this pilot study was to investigate pain reduction in oral cavity and pharynx in patients with head and neck cancer (HNC) with oral mucositis, the location of anesthetic effect, and duration of pain relief, after a single-dose administration of a 25 mg bupivacaine lozenge.

Methods: Ten patients with HNC suffering from oral mucositis pain were included. The patients assessed pain in the oral cavity and pharynx on a visual analogue scale (from 0 to 100 mm) at baseline and up to 3 hours after the lozenge was dissolved. Possible adverse events were registered.

Results: The baseline pain was 51 mm (range: 30–73 mm) in the oral cavity and 58 mm (range: 35–70 mm) in the pharynx. When the lozenge was dissolved, both oral (–27 mm; range: –3 to –52 mm; $P = 0.0003$) and pharynx pain (–20 mm; range: –3 to –45 mm; $P = 0.008$) were significantly reduced. After 180 minutes, the mean reduction in pain was significant in the oral cavity (–18 mm; range: –8 to –30 mm; $P < 0.0001$) but not in the pharynx (–8 mm; range: +4 to –23 mm; $P = 0.12$). No adverse events were observed.

Conclusion: The results indicate that the bupivacaine lozenge has a clinically significant and long-lasting pain-relieving effect on pain because of oral mucositis in patients with HNC.

Keywords: Pain management, Bupivacaine lozenge, Local anesthetic, Oral mucositis, Palliative care, Head and neck cancer

1. Introduction

Oral mucositis induces severe oral pain as a serious and very unpleasant complication primarily due to cancer treatment, but can also be due to immunodeficiency caused by infections and systemic inflammatory diseases. The vast majority of patients undergoing radiation therapy with or without high-dose chemotherapy for head

and neck cancer (HNC) will develop oral mucositis in degrees ranging from minor erythema of the oral mucosa to large debilitating and painful ulcers.^{12,17,18,22} The first visible indication of oral mucositis is erythema, which may appear within the first 2 weeks after the beginning of radiation therapy. The symptoms may continue for weeks after the treatment has ended.³⁰

Patients report oral mucositis as one of the worst side effects of cancer therapy.²⁰ The pain associated with oral mucositis makes it difficult for the patient to eat, speak, or socialize without pain, resulting in malnutrition and social withdrawal.¹⁰ The loss of normal oral function leads to a high rate of parenteral nutrition with the use of gastric feeding tube because of swallowing difficulties and dysphagia, affecting food and fluid intake.²⁸ Furthermore, oral mucositis increases the risk of treatment delays, interruptions, or dose reductions in chemotherapy and radiotherapy.^{4,27,29}

Mild oral pain can be treated with topical viscous lidocaine and systemic nonsteroidal antiinflammatory drugs (NSAIDs), paracetamol (acetaminophen), or gabapentin.^{5,31} For severe pain, morphine is used as systemic pain relief,^{3,35} however, opiates are not very effective.²⁶ Topical oral formulations with different local analgesic agents exists and has been examined, however, no conclusive beneficial effect has been demonstrated on severe mucositis pain.^{25,34}

Sponsorships or competing interests that may be relevant to content are disclosed at the end of this article.

^a Clinical Research Centre, Copenhagen University Hospital, Hvidovre, Denmark,

^b Department of Oncology, Aarhus University Hospital, Aarhus, Denmark, ^c Department of Oncology, Rigshospitalet, Copenhagen, Denmark, ^d Department of Biostatistics, University of Copenhagen, Copenhagen, Denmark

*Corresponding author. Address: Clinical Research Centre, Copenhagen University Hospital, Kettegaard Alle 39, DK-2650 Hvidovre, Denmark. Tel.: +45 38 62 60 77; fax: +45 38 62 37 97. E-mail address: stine_mogensen@hotmail.com (S. Mogensen).

Copyright © 2016 The Authors. Published by Wolters Kluwer Health, Inc. on behalf of The International Association for the Study of Pain. All rights reserved. This is an open access article distributed under the Creative Commons Attribution-No Derivatives License 4.0, which allows for redistribution, commercial, and non-commercial, as long as it is passed along unchanged and in whole, with credit to the author.

PR9 1 (2016) e571

<http://dx.doi.org/10.1097/PR9.0000000000000571>

A new lozenge containing 25 mg bupivacaine as a local oromucosal and pharyngeal anesthetic has been developed and earlier tested in phase 1 trials with 10 healthy subjects and phase 2A trials with 10 patients with HNC. In these studies, absorption of bupivacaine and the risk of aspiration were investigated and no toxic plasma concentrations or signs of aspiration were observed, whereas the results indicated that a bupivacaine lozenge is safe to use.^{14,15}

The effect of bupivacaine administered as a lozenge has earlier been tested in 2 other phase 2 trials. The 25 mg lozenge was tested for its anesthetic effect in patients undergoing unsedated upper gastrointestinal endoscopy,²⁴ and a 5 mg bupivacaine lozenge was examined in patients with burning mouth syndrome,³² both trials with positive results and no side effects were registered.

Bupivacaine was chosen as the active ingredient in the lozenge because it is expected to adapt a long duration because of physicochemical properties.⁶ The purpose of pain management with a lozenge is to maintain and enhance patient's nutritional status by anesthetizing the oral cavity before meals and to improve the quality of life for the patient by providing sufficient pain relief.

Aim of this pilot study was to investigate pain reduction in oral cavity and pharynx because of oral mucositis in patients with HNC. The location of anesthetic effect and duration of pain relief was examined, after administration of a single-dose 25 mg bupivacaine lozenge.

2. Materials and methods

2.1. Participants

Patients diagnosed with a HNC undergoing curative (<6 month duration of disease) radiation therapy were included in this uncontrolled pilot study. The inclusion criteria for the patients were a diagnosis with HNC, age more than 18 years, oral pain from oral mucositis, and the ability to speak and read Danish. The exclusion criteria were known allergies to bupivacaine or other local anesthetics of the amide type.

2.2. Ethics

The study was approved by the Danish Health and Medicine Authority (EudraCT 2010-024648-14), the National Committee on Health Research Ethics (H-1-2011-003, notification 34449 and 40739), and the Danish Data Protection Agency (J. no. 2011-41-5711). Furthermore, it was monitored by the Good Clinical Practice unit at Copenhagen University Hospitals.

2.3. Measurements

The World Health Organization's grading scale of mucositis was used for the assessment of oral mucositis based on subjective and objective symptoms,¹⁹ where 0 = no objective symptoms; 1 = erythema ± soreness, no ulcerations; 2 = erythema and ulcerations; 3 = ulceration and distinct erythema, the patient cannot swallow solid food; and 4 = oral mucositis to a degree that makes normal nutrition impossible.

The patients assessed pain in the oral cavity and the pharynx on a visual analogue scale (VAS) from 0 (no pain) to 100 mm (worst possible pain). The mean maximum reduction (pain alleviation) was calculated by the mean of the differences between the minimum pain (VAS) measured and the baseline pain (VAS) ($E[\text{pain}_{\text{baseline}}(\text{VAS}) - \text{pain}_{\text{minimum}}(\text{VAS})]$).

To assess where the anesthetic effect was located, the patients were asked (yes/no) if they felt anesthetized on the anterior part of the tongue, back of the tongue, tongue sides, hard

palate, lips, cheeks, and pharynx, but they were not asked about the duration of the anesthetic effect.

2.4. Study medicine

The study medicine was produced by the Capital Region Pharmacy, Denmark. The lozenges were manufactured by direct powder compression and contained bupivacaine 25 mg as local anesthetic agent, licorice powder as taste masking, and aspartame as sweetener.

2.5. Study procedure

The patients assessed pain on VAS at baseline before administration of a 25 mg bupivacaine lozenge (baseline), immediately after the bupivacaine lozenge was dissolved, and continuously thereafter for 3 hours (every 15 minutes for 2 hours and then every 30 minutes for the last hour). Furthermore, the patients registered where they felt anesthetized in the oral cavity and pharynx immediately after the lozenge was completely dissolved. Possible adverse events were registered during the studies, and the participants were instructed to contact the clinician if adverse events occurred in the 24 hours after lozenge administration.

2.6. Statistical analysis

The power calculation was based on a 1-sample *t* test with a minimum clinical relevant reduction in pain of 20 mm on the VAS. We assumed a power of 80%, a significance level of 5%, and a SD of 20 mm for differences between repeated measures of VAS, which lead to a sample size of 10 patients.

All demographic data are given as median and ranges. The immediate effect of the lozenge on the pain is reported as the mean reduction from the VAS score measured at baseline to the time where the lozenge was dissolved. The change in pain was analyzed with a paired *t* test. *P*-values less than 5% were considered significant.

3. Results

Ten patients diagnosed with HNC (<6 month duration of disease) and oral pain from mucositis were included in the study from the oncology department at the Department of Oncology at Rigshospitalet, Copenhagen, Denmark, from November 2014 to June 2015. Demographic data and baseline characteristics are given in **Table 1**. No adverse reactions were observed in any of the patients during the study or in the following 24 hours.

The patients were not administrated any pain medication (eg, paracetamol, NSAIDs, morphine, or local anesthetics) for a minimum of 2 hours before study start. They assessed their pain at a mean baseline VAS of 51 mm (30–73 mm) in the oral cavity and 58 mm (35–70 mm) in the pharynx, all patients experienced pain in the oral cavity, and 7 of them also experienced pain in the pharynx (VAS >0 mm). The median time for the lozenge to be dissolved was 39 minutes (range: 17–60 minutes) and the individual times for the lozenge to be dissolved are presented in **Figure 1** as the time before the dotted line. **Figure 1** shows the patients' individual pain assessments and the mean assessment from baseline to 3 hours after the lozenge was dissolved in the oral cavity (**Fig. 1A**) and the pharynx (**Fig. 1B**). There was a significant reduction in pain assessment in both the oral cavity and pharynx immediately after the lozenge was completely dissolved. The mean reduction in oral pain was –27 mm (range: –3 to –52 mm; *P* < 0.001) and –20 mm

Table 1
Demographic data and baseline characteristics.

	HNC patients (n = 10)
Sex, male/female	5/5
Age, y, median (range)	62 (42–78)
BMI, kg/m ² , median (range)	20.1 (16.6–28.4)
Completed radiation fractions, median (range)	24 (7–33)
Oral mucositis, WHO grade, median (range)	3 (1–4)
Baseline oral pain, VAS mm, mean (range)	51 (30–73)
Baseline pharynx pain, VAS mm, mean (range)	58 (35–70)

BMI, body mass index; HNC, head and neck cancer patients; VAS, visual analogue scale; WHO, World Health Organization.

(range: –3 to –45 mm; $P = 0.008$) in the pharynx. Five of the patients had a clinically significant^{11,13} pain reduction (≥ 30 mm) immediately after the lozenge was dissolved. The mean maximal reduction in oral pain was –39 mm (range: –21 to –52 mm; $P < 0.001$), and the

mean maximal reduction in pharynx pain was –36 mm (range: –13 to –53 mm; $P < 0.001$).

The mean time for maximal pain reduction after the lozenge was dissolved was 42 minutes (range: 0–90 minutes) in the oral cavity and 77 minutes (range: 45–105 minutes) in the pharynx. There was still a significant reduction in mean pain of –18 mm (range: –8 to –30 mm; $P < 0.001$) in the oral cavity after 180 minutes, whereas the similar reduction in the pharynx was –8 mm (range: 4 to –23 mm; $P = 0.12$), and not significant (**Fig. 1A and B**).

The lozenges had the most pronounced effect on the anterior part of the tongue where all patients experienced an anesthetic effect, followed by the posterior part of the tongue where 80% of the patients experienced an anesthetic effect (**Fig. 2**).

4. Discussion

The results of this pilot study indicate that the bupivacaine lozenge, as a single dose of 25 mg bupivacaine, which is still investigational, can be used by patients with oral mucositis for pain alleviation with

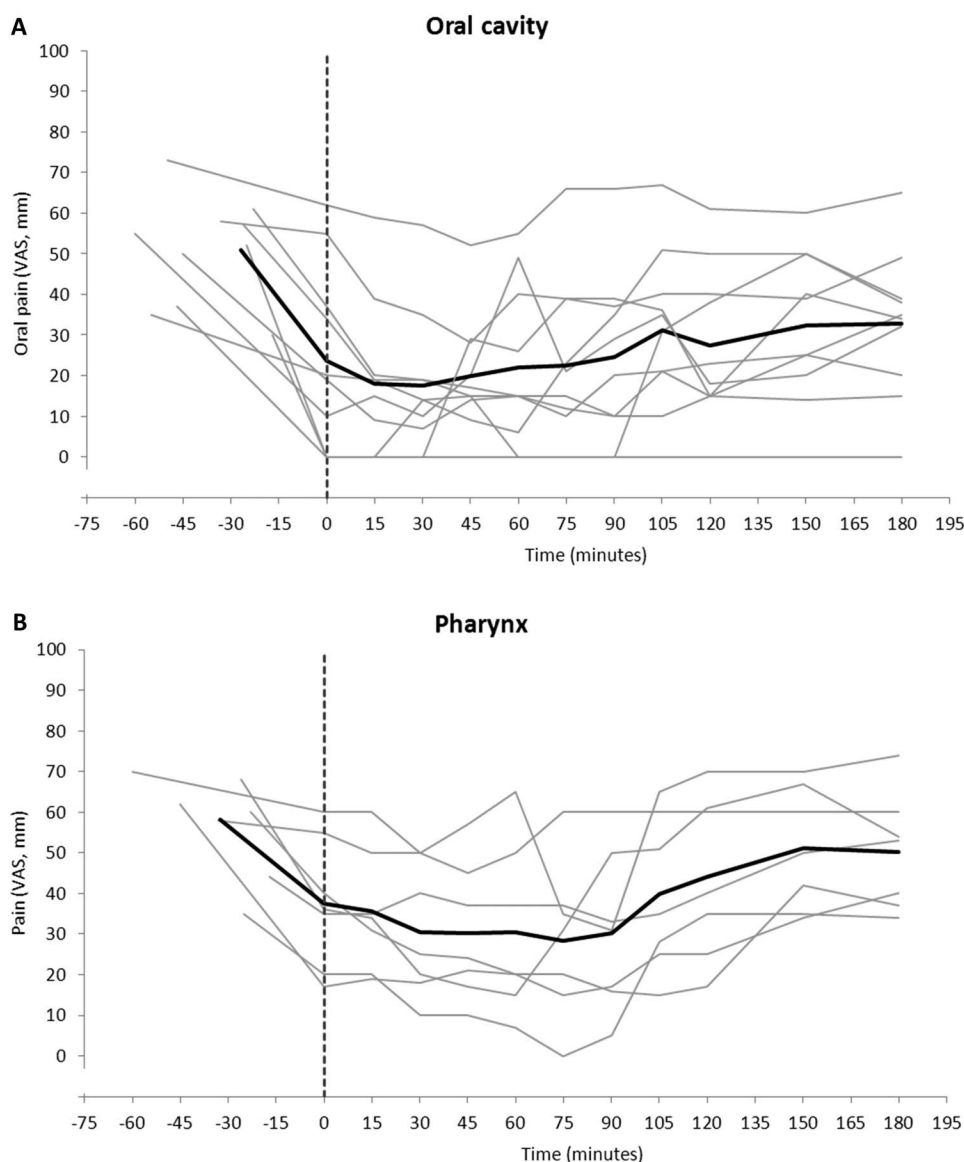


Figure 1. Patient assessment of pain in the oral cavity (A) and the pharynx (B) scored on a VAS (ranging from 0 to 100 mm). The gray curve shows the pain assessment for each patient, the black curves show the mean assessments, and the dotted lines represent the time to dissolve the lozenges completely. These times are presented on the left side of the dotted line.

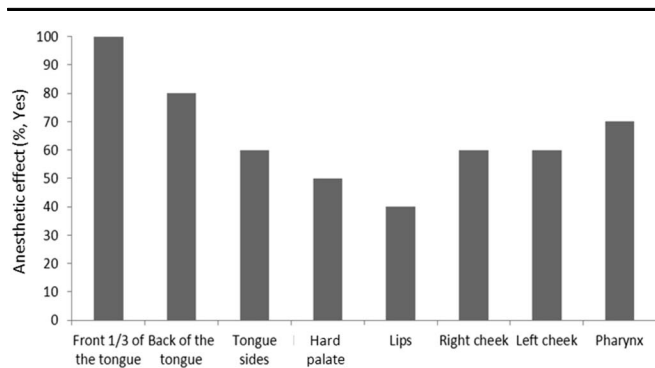


Figure 2. The anesthetic effect in different areas of the oral cavity of patients assessed by yes/no replies after the lozenge was completely dissolved.

clinical effect in the oral cavity for a minimum of 3 hours. Furthermore, the patients experienced no side effects. The mean pain reduction immediately after the lozenge was dissolved was -27 mm in oral pain and -20 mm in pharynx using a VAS pain score. The mean maximum pain reduction was -39 mm in the oral cavity and -36 mm in the pharynx.

All patients received systemic pain medication per need, including paracetamol, NSAIDs, and morphine, however, their mean VAS baseline pain was 51 mm in the oral cavity and 58 mm in the pharynx. Although patients were asked not to take any pain medication 2 hours before study start, the high baseline pain score indicates insufficient pain treatment for breakthrough pain. The baseline pain assessments are in line with similar studies in patients with HNC and oral mucositis, where baseline pain scores on a VAS were found to be between 47 and 67 mm.^{2,8,31} Previous studies have shown that a minimum baseline VAS score of >30 mm is necessary to be able to measure pain relief,³¹ and that a reduction in pain intensity of minimum -13 mm has a clinical significance for patients with pain.⁹ No other studies have investigated the effect of a lozenge with a local anesthetic in patients with HNC. However, some studies have investigated the effect of different local anesthetics such as tetracaine, cocaine, and lidocaine. In 1 study, tetracaine was administered as an oral gel and showed a positive effect on oral mucositis-related pain.¹ The use of a cocaine solution has, in a case report, been reported as effective in 2 patients.¹⁶ Lidocaine is effective when administered as an oral cream in a concentration of 1% lidocaine in patients with acute oral mucosal pain caused by a trauma or an aphthous ulcer and as a lozenge containing 8 mg lidocaine for treatment of acute pharyngitis.^{7,36} In addition, various systemic drugs have led to similar pain reductions, ie, mouthwashes with the tricyclic antidepressant doxepin, ketamine, or morphine.^{8,23,24} All of these drugs exert systemic action. These studies suggested a positive effect on oral pain, but ketamine in particular had severe side effects such as mild confusion, hallucinations, nausea, and dizziness.²¹

Morphine is widely used in the palliative setting, but studies on morphine and the doxepin mouthwash have concluded that additional testing is necessary; the authors of the morphine study stated that more effort must be made for the development of alternative oral mucositis pain treatments.³³ Most of the studies with different drugs and formulations have had a positive effect on pain, but none of them are used routinely for oral mucositis patients. This study indicates that the lozenge may be an effective alternative to the existing pain management regimen, or as an add-on therapy. Furthermore, no side effects from the bupivacaine lozenge were reported, and the texture and taste were found to be acceptable (data not shown).

Patient pain scores were significantly reduced in both the oral cavity and the pharynx after administration of the lozenge. However, when asked in which areas they could feel the anesthetic effect, only 5 of the 10 patients reported an anesthetic effect in the pharynx. This distinction might result from the fact that the lozenge has more contact with the mucosa in the mouth than with the mucosa of the pharynx; however, the pain-relieving effect was still present in the pharynx.

The low number of patients included and the fact that the study was not placebo-controlled does not allow for definitive conclusions regarding the pain-relieving effect, but the significant reduction in pain for a long duration indicates that this 25 mg bupivacaine lozenge could be an option in future pain management. When assessing the effect of a local anesthetic drug, it is difficult to perform a placebo-controlled study because the active lozenge has an immediate effect in the oral cavity and pharynx as shown in this study. Our study was a small phase 2A study, with no control group. This issue will be addressed in an already initiated larger randomized controlled phase 2 trial with patients diagnosed with HNC. Oral mucositis can be due to other causes than radiation, eg, high-dose chemotherapy or infections. The effect of the bupivacaine lozenge has not been tested in patients with other causes for oral mucositis, whereas further studies are needed to elucidate the effect of the bupivacaine lozenge in these conditions.

The patients included in this study may have taken pain medication with a long duration before the 2 hours before study start. However, when looking at the baseline VAS scores, all patients had severe pain although the patients were under the influence of pain medication taken 2 hours before study start.

5. Conclusion

The results indicate that the bupivacaine lozenge induces long-lasting pain alleviation in patients with oral mucositis. This result makes the bupivacaine lozenge a promising tool in the treatment of pain in patients with oral mucositis, a condition currently difficult to treat. Further testing in a larger patient population is required to determine whether the lozenge can be sufficient as pain management without systemic opioids.

Conflict of interest statement

S. Mogensen, C. Tredal, T. S. Mogensen, and O. Andersen are stockholders in Oracain II Aps and have an issued patent application on the bupivacaine lozenge. The other authors have no conflicts of interest to declare. The development has been supported by SEED capital in the period 2010–2014. The IP was licensed to Moberg Pharma Sweden in 2014, in charge of further development. Clinical Research Centre, Copenhagen University Hospital, Hvidovre, Denmark did after this part of the study was finished get an unrestricted grant to research in pain from Moberg Pharma in 2014 amount 131.800 EUR.

Article history:

Received 21 May 2016

Received in revised form 9 August 2016

Accepted 12 August 2016

References

- [1] Alterio D, Jereczek-Fossa BA, Zuccotti GF, Leon ME, Sale EO, Pasetti M, Modena T, Perugini P, Mariani L, Orecchia R. Tetracaine oral gel in patients treated with radiotherapy for head-and-neck cancer: final results of a phase II study. *Int J Radiat Oncol Biol Phys* 2006;64:392–5.

- [2] Berger A, Henderson M, Nadoolman W, Duffy V, Cooper D, Saberski L, Bartoshuk L. Oral capsaicin provides temporary relief for oral mucositis pain secondary to chemotherapy/radiation therapy. *J Pain Symptom Manage* 1995;10:243–8.
- [3] Cerchietti LCA, Navigante AH, Bonomi MR, Zaderajko MA, Menéndez PR, Pogany CE, Roth BMC. Effect of topical morphine for mucositis-associated pain following concomitant chemoradiotherapy for head and neck carcinoma. *Cancer* 2002;95:2230–6.
- [4] Cheng KKF, Leung SF, Liang RHS, Tai JWM, Yeung RMW, Thompson DR. Severe oral mucositis associated with cancer therapy: impact on oral functional status and quality of life. *Support Care Cancer* 2010;18:1477–85.
- [5] Clark GT, Ram S. Orofacial pain and neurosensory disorder and dysfunction in cancer patients. *Dent Clin North Am* 2008;52:183–202.
- [6] Covino BG, Giddon DB. Pharmacology of local anesthetic agents. *J Dent Res* 1981;60:1454–9.
- [7] Descroix V, Coudert AE, Vigé A, Durand JP, Toupenay S, Molla M, Pompignoli M, Missika P, Allaert FA. Efficacy of topical 1% lidocaine in the symptomatic treatment of pain associated with oral mucosal trauma or minor oral aphthous ulcer: a randomized, double-blind, placebo-controlled, parallel-group, single-dose study. *J Orofac Pain* 2011;25:327–32.
- [8] Epstein JB, Truelove EL, Oien H, Allison C, Lee ND, Epstein MS. Oral topical doxepin rinse: analgesic effect in patients with oral mucosal pain due to cancer or cancer therapy. *Oral Oncol* 2001;37:632–7.
- [9] Gallagher EJ, Liebman M, Bijur PE. Prospective validation of clinically important changes in pain severity measured on a visual analog scale. *Ann Emerg Med* 2001;38:633–8.
- [10] Hjermstad MJ, Mia Bergenmarc M, Fisher SE, Monte S, Nicolatou-Galitisif O, Raber-Durlacherg J, Singerh S, Verdonck-de Leeuw I, Weisj J, Yaromk N, Herlofsonm BB. The EORTC QLQ-OH17: a supplementary module to the EORTC QLQ-C30 for assessment of oral health and quality of life in cancer patients. *Eur J Cancer* 2012;48:2203–11.
- [11] Kelly AM. The minimum clinically significant difference in visual analogue scale pain score does not differ with severity of pain. *Emerg Med J* 2001;18:205–7.
- [12] Köstler WJ, Hejna M, Wenzel C, Zielinski CC. Oral mucositis complicating chemotherapy and/or radiotherapy: options for prevention and treatment. *CA Cancer J Clin* 2001;51:290–315.
- [13] Lee JS, Hobden E, Stiell IG, Wells GA. Clinically important change in the visual analog scale after adequate pain control. *Acad Emerg Med* 2003;10:1128–30.
- [14] Mogensen S, Sverrisdóttir E, Sveinsdóttir K, Trelidal C, Jensen K, Jensen AB, Kristensen CA, Jacobsen J, Kreilgaard M, Petersen J, Andersen O. Absorption of bupivacaine after administration of a lozenge as topical treatment for pain from oral mucositis. *Basic Clin Pharmacol Toxicol* 2016 [epub ahead of print]. DOI: 10.1111/bcpt.12644.
- [15] Mogensen S, Sveinsdóttir K, Trelidal C, Jensen K, Nygård A, Mohammad A, Jensen FK, Kristensen CA, Petersen J, Andersen O. No risk of aspiration of new bupivacaine lozenge to healthy subjects and head and neck cancer patients with oral mucositis. *J Int Res Med Pharm Sci* 2016;10:78–82.
- [16] Newport K, Coyne P. Topical cocaine for relief of mucosal pain. *J Pain Palliat Care Pharmacother* 2010;24:149–51.
- [17] Parulekar W, Mackenzie R, Bjarnason G, Jordan RCK. Scoring oral mucositis. *Oral Oncol* 1998;34:63–71.
- [18] Peterson DE. New strategies for management of oral mucositis in cancer patients. *J Support Oncol* 2006;4:9–13.
- [19] Pico JL, Avila-Garavito A, Naccache P. Mucositis: its occurrence, consequences, and treatment in the oncology setting. *Oncologist* 1998;3:446–51.
- [20] Quinn B, Potting CMJ, Stone R, Blijlevens NMA, Fliedner M, Margulies A, Sharp L; a joint taskforce on behalf of the European Group for Blood and Marrow Transplantation (EBMT) and the European Oncology Nursing Society (EONS). Guidelines for the assessment of oral mucositis in adult chemotherapy, radiotherapy and haematopoietic stem cell transplant patients. *Eur J Cancer* 2008;44:61–72.
- [21] Rasmussen KG, Ritter MJ. Some considerations of the tolerability of ketamine for ECT anesthesia, a case series and review of the literature. *J ECT* 2014;30:283–6.
- [22] Rubenstein, EB, Peterson DE, Schubert M, Keefe D, McGuire D, Epstein J, Elting LS, Fox PC, Cooksley C, Sonis ST. Clinical practice guidelines for the prevention and treatment of cancer therapy-induced oral and gastrointestinal mucositis. *Cancer* 2004;100(9 suppl):2026–46.
- [23] Ryan AJ, Lin F, Atayee RS. Ketamine mouthwash for mucositis pain. *J Palliat Med* 2009;12:989–91.
- [24] Salale N, Trelidal C, Mogensen S, Rasmussen M, Petersen J, Andersen O, Jacobsen J. Bupivacaine lozenge compared with lidocaine spray as topical pharyngeal anesthetic before unsedated upper gastrointestinal endoscopy: a randomized, controlled trial. *Clin Med Insights Gastroenterol* 2014;7:55–9.
- [25] Saunders DP, Epstein JB, Elad S, Allemano J, Bossi P, van de Wetering MD, Rao NG, Potting C, Cheng KK, Freidank A, Brennan MT, Bowen J, Dennis K, Lalla RV; For The Mucositis Study Group of the Multinational Association of Supportive Care in Cancer/International Society of Oral Oncology (MASCC/ISOO). Systematic review of antimicrobials, mucosal coating agents, anesthetics, and analgesics for the management of oral mucositis in cancer patients. *Support Care Cancer* 2013;21:3191–207.
- [26] Slatkin NE, Rhiner M. Topical ketamine in the treatment of oral mucositis. *Pain Med* 2003;4:298–303.
- [27] Sonis ST. Oral mucositis in cancer therapy. *J Support Oncol* 2004;2 (suppl 3):3–8.
- [28] Sonis ST. Pathobiology of oral mucositis: novel insights and opportunities. *J Support Oncol* 2007;5:3–11.
- [29] Sonis ST. Mucositis: the impact, biology and therapeutic opportunities of oral mucositis. *Oral Oncol* 2009;45:1015–20.
- [30] Sonis ST. Oral mucositis. *Anticancer Drugs* 2011;22:607–12.
- [31] Todd KH, Funk KG, Funk JP, Bonacci R. Clinical significance of reported changes in pain severity. *Ann Emerg Med* 1996;27:485–9.
- [32] Trelidal C, Jacobsen CB, Mogensen S, Rasmussen M, Jacobsen J, Petersen J, Lyrne Pedersen AM, Andersen O. Effect of a local anesthetic lozenge in relief of symptoms in burning mouth syndrome. *Oral Dis* 2016;22:123–32.
- [33] Vayne-Bossert P, Escher M, de Vaubault CG, Dulguerov P, Allal A, Desmeules J, Hermann FR, Pautex S. Effect of topical morphine (mouthwash) on oral pain due to chemotherapy- and/or radiotherapy-induced mucositis: a randomized double-blinded study. *J Palliat Med* 2010;13:125–9.
- [34] Viet CT, Corby PM, Akinwande A, Schmidt BL. Review of preclinical studies on treatment of mucositis and associated pain. *J Dent Res* 2014;93:868–75.
- [35] White MC, Hommers C, Parry S, Stoddart PA. Pain management in 100 episodes of severe mucositis in children. *Pediatr Anesth* 2011;21:411–16.
- [36] Wonnemann M, Helm I, Stauss-Grabo M, Röttger-Luer P, Tran CT, Canenbley R, Donath F, Nowak H, Schug BS, Blume HH. Lidocaine 8 mg sore throat lozenges in the treatment of acute pharyngitis. A new therapeutic option investigated in comparison to placebo treatment. *Arzneimittelforschung* 2007;57:689–97.