

Received: 2016.02.16  
Accepted: 2016.04.04  
Published: 2016.11.18

# Experimental Application of Bone Marrow Mesenchymal Stem Cells for the Repair of Intervertebral Disc Annulus Fibrosus

Authors' Contribution:  
Study Design A  
Data Collection B  
Statistical Analysis C  
Data Interpretation D  
Manuscript Preparation E  
Literature Search F  
Funds Collection G

AB 1 **Xiaohe Li\***  
BD 2 **Yunfeng Zhang\***  
DE 3 **Bin Song**  
F 1 **He En**  
DE 1 **Shang Gao**  
EG 1 **Shaojie Zhang**  
EG 1 **Yongqiang Cai**  
CFG 1 **Zhi-jun Li**  
CF 4 **Cunbao Li**  
E 5 **Weiping Wang**  
B 1 **Xin Wang**  
BE 1 **Haiyan Wang**  
BF 1 **Zhiqiang Wang**  
B 1 **Qi Zhang**  
CF 1 **Jierong Ma**

1 Department of Anatomy, Basic Medical College, Inner Mongolia Medical University, Huhhot, Inner Mongolia, P.R. China  
2 Department of CT Center, The Second Hospital of Inner Mongolia Medical University, Huhhot, Inner Mongolia, P.R. China  
3 Department of Orthopedics, The First People's Hospital of Wuxue, Wuxue, Hubei, P.R. China  
4 Department of Biochemistry, Basic Medical College, Inner Mongolia Medical University, Huhhot, Inner Mongolia, P.R. China  
5 Second Affiliated Hospital of Xinxiang Medical College, Xinxiang, Henan, P.R. China

\* Xiaohe Li and Yunfeng Zhang are co-first authors or contributed equally to this work

Zhijun Li, e-mail: [lizhijunmail@sina.com](mailto:lizhijunmail@sina.com), Cunbao Li, e-mail: [798242742@qq.com](mailto:798242742@qq.com)

**Corresponding Authors:**

**Source of support:**

National Science Foundation of China (81460330; 81560348,81260269); Science Foundation of Inner Mongolia (2012MS1117); Inner Mongolia Education Bureau Youth Elite of Science and Technology (NJYT-15-B05); Science and Technology Group of Inner Mongolia Medical University

**Background:** This study provides experimental results on the applicability of bone marrow mesenchymal stem cells (BMSCs) for the repair of intervertebral disc annulus fibrosus in rabbits.


**Material/Method:** Thirty healthy rabbits were randomized into an observation group (n=15) and a control group (n=15). Both groups underwent degeneration of intervertebral disc annulus fibrosus. The observation group was treated with a solution of BMSCs and dexamethasone sodium phosphate, while the control group was treated with dexamethasone sodium phosphate only.

**Results:** The two groups were compared for efficacy and pathological conditions after treatment. Both disc height index and level of type II collagen in nucleus pulposus were significantly higher in the observation group than in the control group at 2, 4, 8, and 12 weeks after degeneration ( $p < 0.05$  for all comparisons). The percentages of grade 0 and grade 1 were significantly higher in the observation group than in the control group ( $p < 0.05$  for both grade 0 and 1 comparisons), while the percentage of grade 4 and grade 5 were significantly lower in the observation group than in the control group ( $p < 0.05$  for both grade 4 and 5 comparisons).

**Conclusions:** BMSCs cultured *in vitro* can effectively repair intervertebral disc annulus fibrosus, which is of positive significance, and thus is clinically recommended.

**MeSH Keywords:** **Behavior, Animal • Intervertebral Disc Degeneration • Mesenchymal Stromal Cells**

**Full-text PDF:** <http://www.medscimonit.com/abstract/index/idArt/898062>

 1563

 3

 2

 13



## Background

The intervertebral disc is an elastic gel-like substance consisting of several rings of multilayer annulus fibrocartilaginous that surround an inner center, the nucleus pulposus. Disc degeneration is often associated with patient age, sex, lifestyle, bad posture, and occupation [1]. It is difficult to cure once it develops, and can seriously affect a patient's health and daily life. Currently, replacement therapy is a commonly used clinical treatment, however, foreign body rejection often develops [2]. It can also be ineffective when there is a large area of defect. Therefore, its restorative treatment value remains a problem in medical practice. Thus, it is important to find an alternative reasonably effective treatment. It has been reported that bone marrow stem cells have some restorative effects in treating diseases of intervertebral disc annulus fibrosus [3]. In view of this, our study investigated the effects of bone marrow mesenchymal stem cells (BMSCs) on repairing intervertebral disc annulus fibrosus in rabbits.

## Material and Methods

### Materials

Thirty 6-month-old healthy New Zealand white rabbits were provided by the Experimental Animal Center of Inner Mongolia University. The animals were certified by the Center of Inner Mongolia University, Certificate number: 20130241. They were randomized into an observation group and a control group (both  $n=15$ ). The observation group included eight females and seven males, with an average body weight of  $2.5\pm 0.5$  kg. The control group included seven females and eight males, with an average weight of  $2.5\pm 0.4$  kg. The two groups had no significant differences in sex ratio, age, or species ( $p>0.05$ ), and thus were comparable.

### Methods

#### *Intervertebral disc degeneration in rabbits*

Both groups underwent surgical disc degeneration, which was performed as follows. (1) All rabbits were fasted for 6 hours before surgery, weighed, anesthetized by injection of 20% urethane (4 mL/kg) via the ear vein, and fixed on the operating table. (2) After the rabbits were shaved over the center of peritoneum, a small longitudinal incision of 6-8 cm was made, the subcutaneous tissue was bluntly dissected, and the intestinal canal was pushed aside to expose L3-L4 and L4-L5 discs. (3) 5 mL of disc nucleus pulposus was extracted from the discs under sterile conditions.

#### *Culturing of rabbit BMSCs*

Under sterile conditions, 5 mL of bone marrow was extracted from 1-month-old healthy New Zealand rabbits. The extracted bone marrow cells were cultured to the third generation by adherent culture, and observed for growth under a microscope.

### Treatment

Two weeks after surgery, 50  $\mu$ L of BMSCs ( $2.0\times 10^5$  cells/mL) mixed with 5 mg of dexamethasone sodium phosphate (Zhengzhou Zhuofeng Pharmaceutical Co. Ltd.; National Approval Number: H41020055) was injected into the impaired L3-4 and L4-5 discs of rabbits in the observation group; while only 5 mg of dexamethasone sodium phosphate was administered to rabbits in the control group. The two groups of rabbits were compared at 2, 7, and 12 weeks after surgery.

### Determination of disc height index (DHI)

The anterior, middle, and posterior heights of disc (DH), upper vertebral body (UB), and lower vertebral body (LB) were measured. The DHI was calculated as follows:

$$DHI = (DH1 + DH2 + DH3) \times 2 / (LB1 + LB2 + LB3 + UB1 + UB2 + UB3)$$

### Determination of type II collagen

A sample of 0.5 mL of nucleus pulposus was diluted with acetic acid to 50 mL. Then 20 mL of the mixture was centrifuged at 4000 r/min for 10 minutes for immunohistochemistry. Type II collagen expression was detected using a rabbit anti-mouse type II collagen antibody (Cell Signaling Technology, USA) and a type II collagen immunohistochemistry kit (Jingmei Biological Engineering Co., Ltd., China) and observed under a microscope.

### Pathological grading

Grade 0: normal structure of intervertebral disc annulus fibrosus, with no defects; grade 1: mild distortions of intervertebral disc annulus fibrosus, with fissures; grade 2: moderate distortions of intervertebral disc annulus fibrosus, with fissures; grade 3: mild inward protrusion of intervertebral disc annulus fibrosus; grade 4: significant inward protrusion of intervertebral disc annulus fibrosus; grade 5: messy and obscure structure of intervertebral disc annulus fibrosus.

### Statistical methods

Statistical analysis was performed using SPSS 13.0. Enumeration data were analyzed by  $\chi^2$  test and measurement data by t-test;  $p<0.05$  was considered statistically significant.

**Table 1.** Comparison of disc height index after shaved over the center of peritoneum ( $\bar{x}\pm s$ ).

Group	Number	Before surgery	2 weeks	4 weeks	8 weeks	12 weeks
Observation group	15	95.05±4.06	82.05±3.21*	78.04±2.89*	77.46±2.88*	81.51±2.26*
Control group	15	94.95±3.76	73.88±3.08	69.25±3.07	62.45±2.67	60.72±3.64
t	–	0.070	7.113	8.074	14.803	18.793
P	–	0.945	0.000	0.000	0.000	0.000

\*  $P<0.05$  compared with the control group, there was a significant difference in DHI between 2, 4, 8, and 12 weeks after surgery.

**Table 2.** Comparison of level of type II collagen after shaved over the center of peritoneum (mg/mL,  $\bar{x}\pm s$ ).

Group	Number	Before surgery	2 weeks	4 weeks	8 weeks	12 weeks
Observation group	15	5.05±0.16	4.38±0.24*	4.36±0.16*	4.72±0.23*	4.78±0.32*
Control group	15	4.98±0.26	3.23±0.12	3.33±0.15	3.29±0.16	3.15±0.12
t	–	0.888	16.599	18.189	19.767	18.472
P	–	0.382	0.000	0.000	0.000	0.000

\*  $P<0.05$  compared with the control group. there was a significant difference in level of type II collagen between 2, 4, 8, and 12 weeks after surgery.

## Results

### DHI comparison after treatment

DHI was 82.05±3.21, 78.04±2.89, 77.46±2.88, 81.51±2.26, respectively, at 2, 4, 8, and 12 weeks after surgery in the observation group, which were significantly higher than 73.88±3.08, 69.25±3.07, 62.45±2.67, and 60.72±3.64 in the control group ( $p<0.05$ ). The higher DHI indicated better clinical rehabilitation in the observation group, which is of positive significance. Moreover, DHI was significantly higher before surgery than at 2, 4, 8, and 12 weeks after surgery in both the observation and control groups. In the observation group, there was a significant difference in DHI between each time point. Results are shown in Table 1.

### Comparison of level of type II collagen in nucleus pulposus (Unit: mg/mL)

The level of type II collagen in nucleus pulposus was 4.38±0.24, 4.36±0.16, 4.72±0.23, 4.78±0.32, respectively, at 2, 4, 8, and 12 weeks after surgery in the observation group, which were significantly higher than 3.23±0.12, 3.33±0.15, 3.29±0.16, and 3.15±0.12, respectively, in the control group ( $p<0.05$ ). Moreover, the level of type II collagen was significantly higher before surgery than at 2, 4, 8, and 12 weeks after surgery in both the observation and control groups. In the observation group, there was a significant difference in the level of type II collagen between each time point, except between 2 and 4 weeks, and between 8 and 12 weeks. In the control group, there was

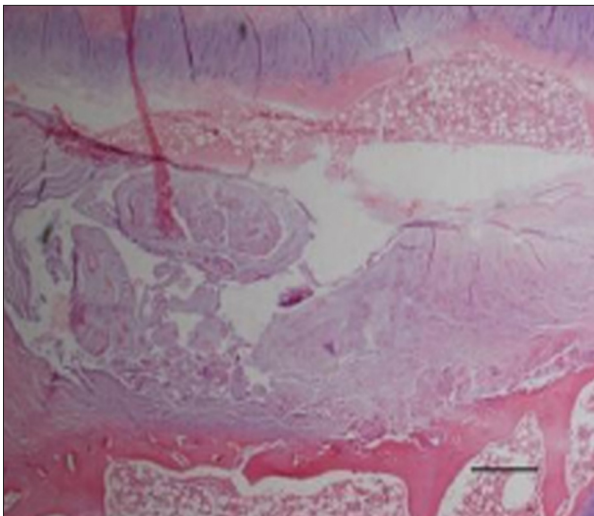
significant difference between 2, 4, 8, and 12 weeks. Results are shown in Table 2.

### Pathological comparison 12 weeks after surgery between the two groups

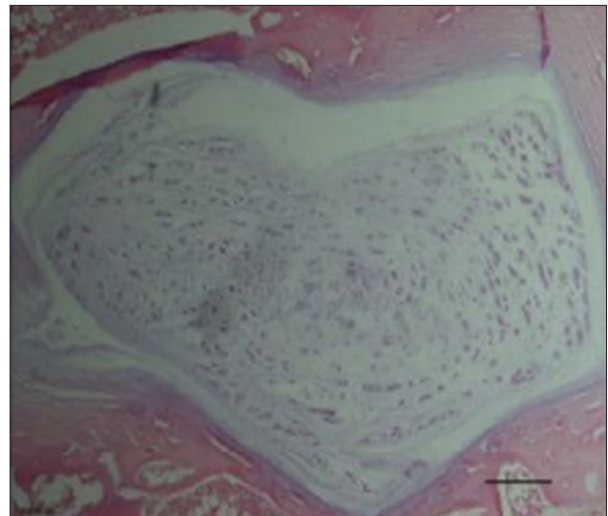
The percentages for rabbits at grade 0 and grade 1 were 40.00% (6/15) and 46.67% (7/15), respectively, in the observation group, which were significantly higher than 0.00% (0/15) and 0.00% (0/15) in the control group (both  $p<0.05$ ); while the percentages for rabbits at grade 4 and grade 5 were 0.00% (0/15) and 0.00% (0/15), respectively, in the observation group, which were significantly lower than 33.33% (5/15) and 26.67% (4/15) in the control group (both  $p<0.05$ ) (Figures 1, 2; Table 3). The above results indicated that the treatment given to the observation group was effective in repairing intervertebral disc annulus fibrosus, which is of significant importance.

## Discussion

Nowadays, people often suffer from damage to the bone structure, especially to the lumbar intervertebral disc, due to overwork or accidental injuries, which has a great impact on patients [4,5]. Significant treatment effects have been achieved with the clinical application of replacement therapy. However, replacement therapy involves the implantation of an inanimate foreign material into the body, which may cause complications. Although it has been reported that patients had significantly improved physical condition and quality of life after



**Figure 1.** Pathology of control group at 12 weeks after exposure to bone marrow mesenchymal stem cells for repairing intervertebral.



**Figure 2.** Pathology of observation group at 12 weeks after bone marrow mesenchymal stem cells to repairing intervertebral.

**Table 3.** Pathological comparison 12 weeks after after shaved over the center of peritoneum (%).

Group	Number	Grade 0	Grade 1	Grade 2	Grade 3	Grade 5
Observation group	15	6 (40.00)*	7 (46.67)*	1 (6.67)	1 (6.67)	0 (0.00)*
Control group	15	0 (0.00)	0 (0.00)	2 (13.33)	4 (26.67)	5 (33.33)
$\chi^2$	–	7.500	9.130	0.370	2.160	6.000
<i>P</i>	–	0.006	0.003	0.543	0.142	0.014

\*  $P < 0.05$  compared with the control group. there were a significant difference in *Pathological grade* between grade from Grade 0 to 5 after surgery.

replacement therapy, some patients developed rejection and needed medication [6]. Moreover, in addition to the high severity and incidence of the disease, it is also a prevalent disease in the elderly population. Clinical recovery is often slow in the elderly due to poor metabolism. The disease may cause compression on surrounding tissues and complications in the later stages, which may pose a threat to the lives and health of patients, and might even be life-threatening [7]. Therefore, it is very important to find a new effective treatment that not only allows timely treatment of damaged discs, but also prevents further progress, thus alleviating the suffering of patients early on, improving outcomes, and thereby curing the disease [8].

In this study, BMSCs combined with dexamethasone sodium phosphate, and dexamethasone sodium phosphate alone were injected into rabbit discs. As shown in Table 1, although DHI was decreased after surgery in both groups, it was significantly higher in the observation group than in the control group at 2, 4, 8, and 12 weeks after surgery. Moreover, it increased week by week in the observation group while it decreased in the control group. The results indicated that transplantation of

BMSCs was effective in repairing intervertebral disc annulus fibrosus, which is consistent with the findings of Chen et al. [9]. As shown in Table 2, although the level of type II collagen was decreased after surgery in both groups, it was significantly higher in the observation group than in the control group at 2, 4, 8, and 12 weeks after surgery, which is consistent with the findings of Yi et al. [10]. In the control group, the level of type II collagen slightly increased at 4 weeks compared to 2 weeks when the treatment began, but then gradually decreased. This may be related to the anti-inflammatory and antitoxic effects of dexamethasone sodium phosphate, which slowed the disease progress to a certain extent, but did not treat the root cause of the disease [11]. In addition, as shown in Table 3, most rabbits were at grades 0 and 1 in the observation group, while at grades 4 and 5 in the control group, which is consistent with the findings of Liu et al. [12]. This may be related to the strong differentiation and proliferation of BMSCs, which allows effective filling and repairing of the damaged annulus fibrosus without rejection, and thus restoring its function [13].

## Conclusions

In summary, BMSCs cultured *in vitro* can effectively repair intervertebral disc annulus fibrosus, which is of positive significance, and can hopefully be applied clinically and be widely recommended in major hospitals.

## References:

- Xu J, Li Z, Hou Y et al: Potential mechanisms underlying the Runx2 induced osteogenesis of bone marrow mesenchymal stem cells. *Am J Transl Res*, 2015; 12(12): 2527–35
- Dongdong H, Lingyuan Z, Chuan X et al: [Repairing articular cartilage defects in the knee of rabbits using type I/III-collagen membrane combined with autologous bone marrow mesenchymal stem cells.] *Chinese Journal of Tissue Engineering Research*, 2012, 16(38): 7031–36 [in Chinese]
- Juhl M, Tratwal J, Follin B et al: Comparison of clinical grade human platelet lysates for cultivation of mesenchymal stromal cells from bone marrow and adipose tissue. *Scand J Clin Lab Invest*, 2016; 76(2): 93–104
- Zhang C, He X, Li H: Chondroitinase ABC plus bone marrow mesenchymal stem cells for repair of spinal cord injury. *Neural Regeneration Research*, 2013; 8(11): 965–74
- Wang R: [Effect of bone marrow mesenchymal stem cells on the proliferation of bone marrow CD34+ cells *in vitro*.] *China Medical Abstracts (Internal Medicine)*, 2013; 32(6): 474–78 [in Chinese]
- Cheng Y, Xuhua L: [Osteogenic differentiation of fibroblasts in degenerative cervical intervertebral disc annulus fibrosus and cervical spondylosis.] *Journal of Spine Surgery*, 2013; 11(3): 182–85 [in Chinese]
- Li X, Dou Q, Kong Q: [Repair and regenerative therapies of the annulus fibrosus of the intervertebral disc.] *J Coll Physicians Surg Pak*, 2016; 26(2): 138–44 [in Chinese]
- Tavassoli A, Matin MM, Niaki MA et al: Mesenchymal stem cells can survive on the extracellular matrix-derived decellularized bovine articular cartilage scaffold. *Iran J Basic Med Sci*, 2015; 18(12): 1221–27
- Cai F, Wu XT, Xie XH et al: Evaluation of intervertebral disc regeneration with implantation of bone marrow mesenchymal stem cells (BMSCs) using quantitative T2 mapping: a study in rabbits. *Int Orthop*, 2015; 39(1): 149–59
- Willems N, Tellegen AR, Bergknut N et al: Inflammatory profiles in canine intervertebral disc degeneration. *BMC Vet Res*, 2016; 12(1): 10–13
- Wei HK, Yang SD, Bai ZL et al: Levofloxacin increases apoptosis of rat annulus fibrosus cells via the mechanism of upregulating MMP-2 and MMP-13. *Int J Clin Exp Med*, 2015; 8(11): 20198–207
- Freitag J, Ford J, Bates D et al: Adipose derived mesenchymal stem cell therapy in the treatment of isolated knee chondral lesions: Design of a randomised controlled pilot study comparing arthroscopic microfracture versus arthroscopic microfracture combined with postoperative mesenchymal stem cell injections. *BMJ Open*, 2015; 5(12): e009332
- O'Connell GD, Leach JK, Klineberg EO: Tissue engineering a biological repair strategy for lumbar disc herniation. *Biores Open Access*, 2015; 4(1): 431–45

## Conflict of interest

The authors declare no conflict of interest