

# Use of Triple Microcatheters for Endovascular Treatment of Wide-Necked Intracranial Aneurysms: A Single Center Experience

Young Dae Cho, MD<sup>1</sup>, Jong Kook Rhim, MD<sup>1</sup>, Hyun-Seung Kang, MD, PhD<sup>2</sup>, Jeong Jin Park, MD<sup>3</sup>, Jin Pyeong Jeon, MD<sup>4</sup>, Jeong Eun Kim, MD, PhD<sup>2</sup>, Won Sang Cho, MD, PhD<sup>2</sup>, Moon Hee Han, MD, PhD<sup>1, 2</sup>

Departments of <sup>1</sup>Radiology and <sup>2</sup>Neurosurgery, Seoul National University Hospital, Seoul National University College of Medicine, Seoul 03080, Korea; <sup>3</sup>Department of Radiology, Samsung Medical Center, Sungkyunkwan University School of Medicine, Seoul 06351, Korea; <sup>4</sup>Department of Neurosurgery, Kangwon National University Hospital, Kangwon National University College of Medicine, Chuncheon 24289, Korea

**Objective:** The dual microcatheter technique is common practice for coil embolization of a wide-necked aneurysm, due to safety and efficacy. However, technical limitations of some complex configurations may necessitate additional microcatheters to bolster coil stability, compact the coil, or for protection. Described herein is a triple microcatheter technique for endovascular management of wide-necked intracranial aneurysms.

**Materials and Methods:** Data accruing prospectively between January 2006 and October 2014 on simultaneously executed triple microcatheter coil embolization procedures done in 38 saccular aneurysms were reviewed. Clinical and morphological outcomes were assessed, with emphasis on technical aspects of treatment.

**Results:** The triple microcatheter technique was successfully applied to all 38 saccular aneurysms, involving the posterior communicating artery (n = 13), the middle cerebral artery (n = 10), the basilar tip (n = 7), the anterior cerebral artery (n = 5), and the internal carotid artery (n = 3). Stent protection was added in four patients and balloon remodeling in one. Dual microcatheters (n = 24) were usually deployed to deliver the coil within sacs of aneurysms, with the additional microcatheter used for protection. Otherwise, triple microcatheters were deployed for coil delivery (n = 11) or coils were delivered via a single microcatheter, with dual microcatheters deployed for protection (n = 3). Successful occlusion of aneurysms was achieved in 89.5% of cases, with no procedure-related morbidity or mortality. Stable occlusion was maintained in 72.2% (26/36) of the aneurysms at the final follow-up (mean interval, 30.2 ± 22.7 months).

**Conclusion:** The outcomes of this limited study suggest that the triple microcatheter technique may be an effective and safe therapeutic option for wide-necked aneurysms, using technical strategies tailored to complex angio-anatomic configurations.

**Index terms:** Aneurysm; Coil; Embolization; Protective; Technique

Received February 20, 2015; accepted after revision May 21, 2015.

**Corresponding author:** Moon Hee Han, MD, PhD, Department of Radiology, Seoul National University Hospital, 101 Daehak-ro, Jongno-gu, Seoul 03080, Korea.

- Tel: (822) 2072-3602 • Fax: (822) 743-6385
- E-mail: aronnn@empal.com

This is an Open Access article distributed under the terms of the Creative Commons Attribution Non-Commercial License (<http://creativecommons.org/licenses/by-nc/3.0>) which permits unrestricted non-commercial use, distribution, and reproduction in any medium, provided the original work is properly cited.

## INTRODUCTION

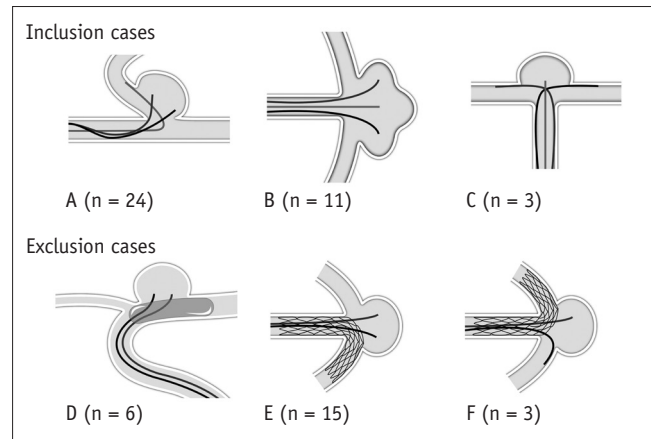
Endovascular coil embolization of intracranial aneurysms is now widely used after initial validation was given by the International Subarachnoid Aneurysm Trial and by the International Study of Unruptured Intracranial Aneurysms (1, 2). Improved protective devices and advanced coiling techniques, such as balloon remodeling and stenting, have enabled coil embolization of aneurysms with complex

configurations (3-7). Using dual microcatheters for coil embolization compared with stenting or balloon protection is advantageous in terms of procedural complications and post-procedural antiplatelet maintenance (8, 9). In particular, this approach is considered safer for ruptured aneurysms, based on its relatively low complication rate. Dual microcatheters may be applied as follows: 1) both microcatheters dedicated to intrasaccular delivery of the coil (so-called “double microcatheter technique”) (10, 11) or 2) one microcatheter placed within aneurysmal sac and the other advanced into a branching artery to prevent coil protrusion (so-called “microcatheter protective technique”) (12). Because this strategy may be technically limited for some lesions with complex configurations, an additional microcatheter may be required to improve coil stability, to promote compact coil packing, or to enhance the protective effect. Herein, the clinical and radiological outcomes of endovascular coil embolization are detailed for simultaneous deployment of three microcatheters (triple microcatheter technique) in wide-necked aneurysms, and the technical aspects of such a treatment are addressed.

## MATERIALS AND METHODS

### Study Population

A total of 3349 intracranial aneurysms in 2898 patients were treated by endovascular coil embolization at our institution between January, 2006 and October, 2014. Of this population, multiple microcatheters (i.e., two or more) were utilized for coil embolization in 1064 aneurysms (31.8%), with microcatheter protection in 238 lesions. However, the simultaneous triple microcatheter technique was applied in just 38 patients (26 females and 12 males; mean age,  $60.1 \pm 9.6$  years), whom we selected for this study. Six aneurysms subjected to dual microcatheters plus balloon protection and 18 aneurysms treated via dual microcatheters plus stent protection (i.e., microcatheter jailing) were excluded (Fig. 1). Non-saccular aneurysms (i.e., dissecting, fusiform, or blood blister-like aneurysms) and pseudoaneurysms were also excluded. All aneurysms (except three) were unruptured (seven recanalized after coiling), and nearly all lesions (except five) had wide necks, with depth-to-neck ratios  $< 1.0$  (mean,  $0.90 \pm 0.38$ ; range, 0.42–2.7; median, 0.82). All lesions (except three) had small diameters ( $< 10$  mm maximum). Therapeutic decisions were rendered through consensus of two neurosurgeons and nonsurgical neurointerventionists, and informed consent



**Fig. 1. Schematic depiction of inclusion/exclusion criteria used to study use of simultaneous triple microcatheters.**

**A-C.** Eligible patients. **A.** Dual microcatheters for delivering coil within aneurysmal sac and single microcatheter for protection. **B.** Triple microcatheter delivery of coil within aneurysm. **C.** Single microcatheter for delivering coil within aneurysmal sac and dual microcatheters for protection. **D-F.** Ineligible patients. **D.** Balloon remodeling and dual microcatheters for delivering coil. **E.** Stent protection and dual microcatheters for delivering coil (both microcatheters jailed). **F.** Stent protection and microcatheter protective technique (both microcatheters jailed).

was obtained from all patients after the treatment and related risks were adequately explained. This study was approved by the Institutional Review Board of our hospital. Clinical and radiographic features of the cohort are shown in Table 1.

### Therapeutic Strategy

As illustrated in Figure 1, the tactical strategies for simultaneous triple microcatheter deployment were as follows: 1) dual microcatheter delivery of the coil within the aneurysmal sac, with a single microcatheter for protection; 2) triple microcatheters used only for delivering the coil within the aneurysm; and 3) single microcatheter coil delivery within the aneurysmal sac, plus dual microcatheter protection of both branching arteries.

The first option was useful in cases where a coil frame formed using a double microcatheter that repeatedly protruded into a branching artery (Fig. 2A, B), or where a coil frame formed was unstable using microcatheter protection (Fig. 2C, D). The second option was commonly applied if the initial coil frame configured by a double microcatheter was unstable (Fig. 3A, B) or if some portion of the sac went unfilled due to intrinsic complexities, such as trilobulation (Fig. 3C, D). The third and final option was applied sparingly if both branching arteries were broadly or evenly incorporated by the aneurysm and the coil

**Table 1. Characteristics of Patients Subjected to Coil Embolization via Simultaneous Triple Microcatheter Technique**

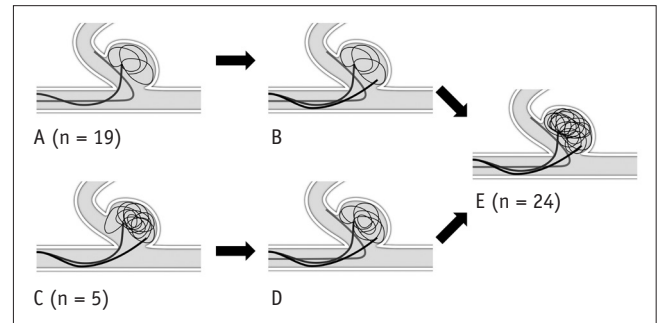
No. of patients and aneurysms	38 patients, 38 aneurysms
Mean age (years) (mean ± SD)	60.1 ± 9.6
Gender (female:male)	26:12
Aneurysm status	
Presentation	
Ruptured	3
Unruptured	35
Aneurysm status	
Initial	31
Recanalized	7
Aneurysm location	
PcomA	13
MCA	10
MCA bifurcation	7
M1	3
Basilar tip	7
ACA	5
AcomA	4
A2-3	1
ICA	3
AchoA	2
Paraclinoid	1
Aneurysm size (except 7 recanalized aneurysms)	
< 5 mm	8
5 mm to 10 mm	20
> 10 mm	3
Depth-to-neck ratio	
< 1.0	33
1.0 to 1.5	3
> 1.5	2
Technique	
Dual coiling + single protection	24
Triple coiling	11
Single coiling + dual protection	3
Initial occlusion result	
Complete occlusion	8
Residual neck	26
Residual aneurysm	4
Follow-up occlusion result (n = 36)	
Complete occlusion	26
Minor recanalization	3
Major recanalization	7

ACA = anterior cerebral artery, AchoA = anterior choroidal artery, AcomA = anterior communicating artery, ICA = internal carotid artery, MCA = middle cerebral artery, PcomA = posterior communicating artery

protruded into unprotected branch arteries, despite use of microcatheter protection (Fig. 4A, B).

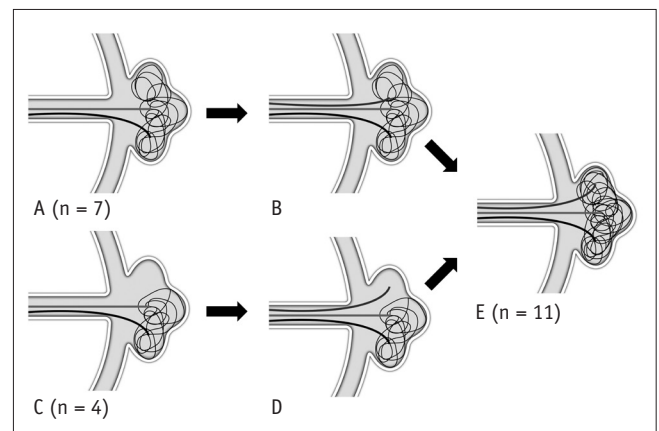
### Endovascular Procedure

All endovascular procedures were performed under general anesthesia. All patients underwent cerebral angiography and rotational angiography with three-dimensional image reconstruction using the Integris V (Philips Medical Systems, Best, the Netherlands) and Innova IGS 630 (General



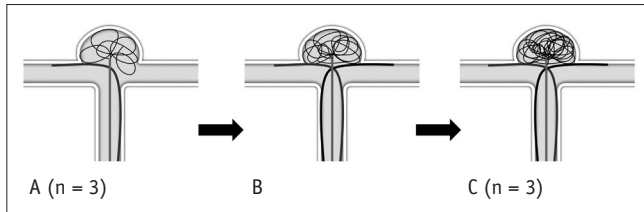
**Fig. 2. Schematic illustration (I) of technical strategies using triple microcatheter technique based on angio-anatomical configuration: dual microcatheters for delivering coil within aneurysmal sac and single microcatheter for protection.**

**A.** Unstable coil frame (without protrusion) configured via microcatheter protective technique. **B.** Microcatheter added for delivering coil into aneurysmal sac. **C.** Coil impingement on branching artery with dual microcatheters. **D.** Microcatheter added to protect branching artery. **E.** Proper coil frame configuration by combining dual microcatheter delivery of coil with single microcatheter protection.



**Fig. 3. Schematic illustration (II) of technical strategies using triple microcatheter technique based on angio-anatomical configuration: triple microcatheter delivery of coil within aneurysm.**

**A.** Unstable coil frame configured using dual microcatheter technique. **B.** Microcatheter added to supplement delivery of coil into aneurysmal sac. **C.** Portion of aneurysm left unfilled by initially delivering coil frame with dual microcatheters (despite proper configuration and no coil protrusion). **D.** Additional microcatheter placed within void. **E.** Proper coil frame configuration within aneurysm using triple microcatheter technique.



**Fig. 4. Schematic illustration (III) of technical strategies using triple microcatheter technique based on angio-anatomical configuration: single microcatheter for coil delivery within aneurysmal sac and dual microcatheters for protection.**

**A.** Coil protruding into unprotected branching artery using microcatheter protective technique. **B.** Additional microcatheter inserted to protect exposed branch. **C.** Proper coil frame configured by combining single microcatheter delivery of coil using dual microcatheters for protection.

Electric, Milwaukee, WI, USA) biplane systems. All patients were managed with an antiplatelet agent before coiling in a relatively consistent scheme at our institution. A 300 mg loading dose of clopidogrel was given the day before the procedure for all patients with unruptured aneurysms, and an additional 75 mg clopidogrel was given in the morning of the day of the procedure. A 300-mg loading dose of aspirin was added for inpatients with a poor response to clopidogrel, based on the VerifyNow P2Y12 assay (Accumetric, Elizabethtown, KY, USA) (i.e., P2Y12 reactivity units > 285) (13). Dual-agent antiplatelet therapy was administered if stent protection was anticipated. Cilostazol was added in patients with a poor response to clopidogrel. After placing a femoral sheath, systemic heparinization was started with a 3000 IU loading dose and was maintained with a 1000 IU dose on an hourly basis. Antiplatelet medication was not administered prior to the procedure in patients with an acutely ruptured aneurysm. In these cases, systemic heparinization was initiated shortly after adequate protection of the aneurysm. It was mandatory to place a 7-Fr guiding catheter in the internal carotid artery in cases when triple microcatheters were expected to be applied simultaneously. If possible, use of three different microcatheters was used to distinguish each microcatheter. After the procedure, antiplatelet medications were not prescribed routinely for maintenance except in cases of stent protection, coil protrusion, composite atherosclerotic narrowing, and procedural thromboembolism.

#### Angiographic Outcomes and Follow-Up

Immediate angiographic results after coil embolization were evaluated by two experienced neurointerventionists. Therapeutic outcomes were classified as follows using the

3-point Raymond scale: complete occlusion (no residual filling of the aneurysm with contrast medium), residual neck (limited residual contrast at the base of the aneurysm), or residual aneurysm (any contrast filling of the aneurysmal sac) (14).

Clinical outcomes were scored using the Glasgow outcome scale (GOS), which was applied throughout the hospitalization period and at the last available clinical follow-up. Magnetic resonance angiography (MRA) with three-dimensional reconstruction and/or plain radiography was recommended for all patients 6, 12, 24, and 36 months after coil embolization. Conventional angiography was recommended when aneurysmal recanalization was suspected by a noninvasive evaluation, such as MRA or plain radiography, to decide if further treatment was necessary.

Anatomic outcomes at follow-up were categorized as follows based on the Raymond scale: complete occlusion, minor recanalization, or major recanalization (15). Repeat embolization was advocated for patients showing major recanalization.

## RESULTS

Selective endovascular coil embolization was performed successfully using three microcatheters simultaneously in patients with saccular aneurysms of the posterior communicating artery ( $n = 13$ ), middle cerebral artery (MCA) ( $n = 10$ ), basilar tip ( $n = 7$ ), anterior cerebral artery ( $n = 5$ ), and internal carotid artery ( $n = 3$ ). In one patient with a basilar tip aneurysm, dual guiding catheters were deployed due to a limited vertebral arterial diameter. A combination of dual microcatheter coil delivery/single microcatheter protection was primarily applied ( $n = 24$ ), followed by inserting the coil via all three microcatheters ( $n = 11$ ), and single microcatheter coil delivery/dual microcatheter protection ( $n = 3$ ) (Figs. 2-4). After building a proper coil frame through using triple microcatheters, additional coils were inserted via the microcatheter(s) in each instance; stents were placed in four patients and a balloon in one patient during this process. Immediately following coil embolization, 34 aneurysms were occluded satisfactorily (eight complete occlusion and 26 neck remnant), and four retained small residual sacs. No procedure-related morbidity or mortality was observed, although an asymptomatic thrombus occurred in two patients. The thrombotic incidents were related to protruding coils (not directly related to the triple microcatheter technique), and they

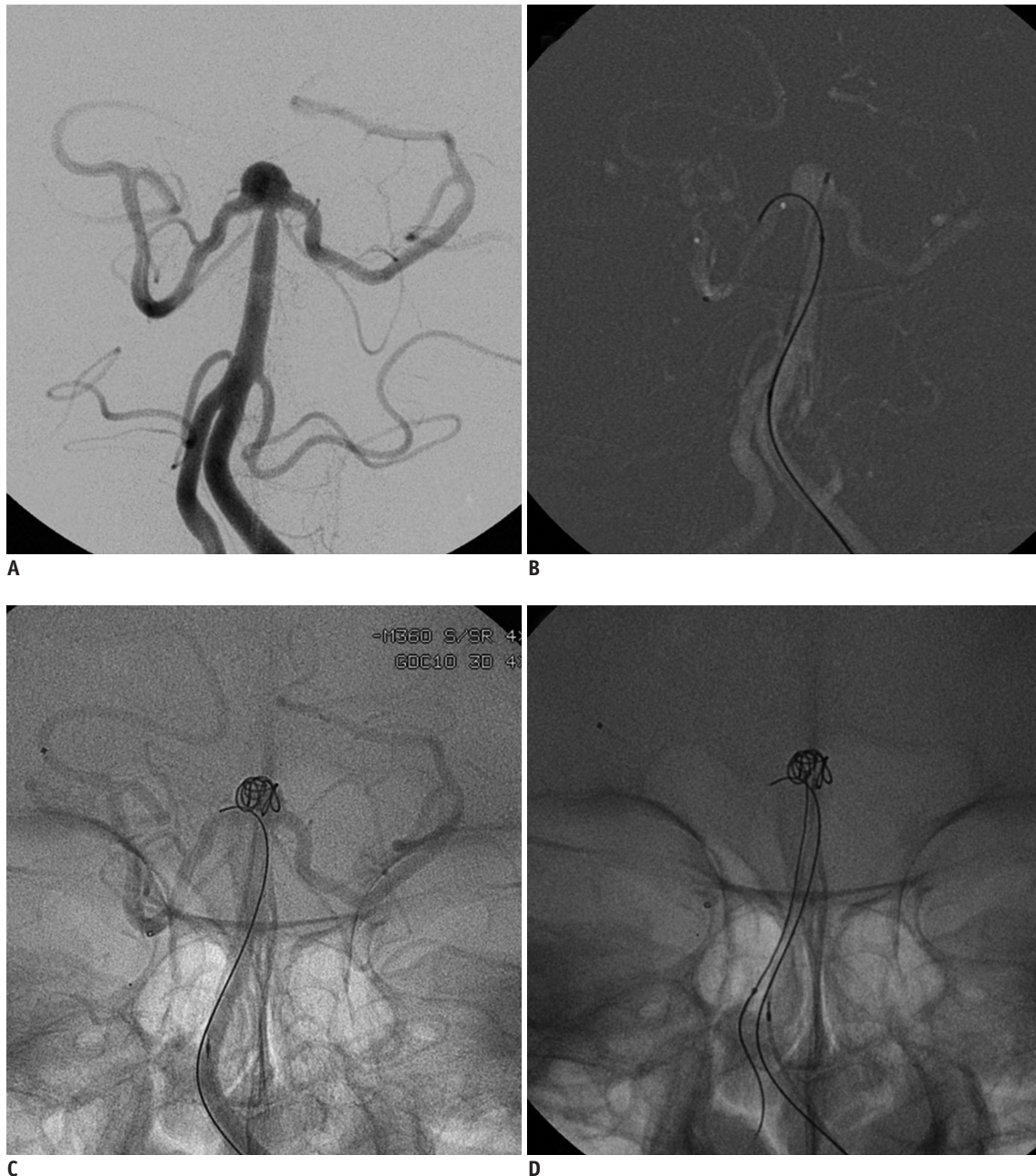
resolved after intra-arterial infusion of tirofiban. All patients were neurologically intact (GOS 5) at the time of discharge. Thirty-six patients (excluding two treated recently) underwent follow-up evaluations at > 6 months (mean, 30.2 ± 22.7 months; median, 36 months), including magnetic resonance and conventional angiography. Twenty-six maintained stable coil configurations, whereas the remaining 10 showed minor (n = 3) or major

recanalization (n = 7). None of the patients experienced delayed complications (i.e., thromboembolic infarction or hemorrhage).

### Illustrative Cases

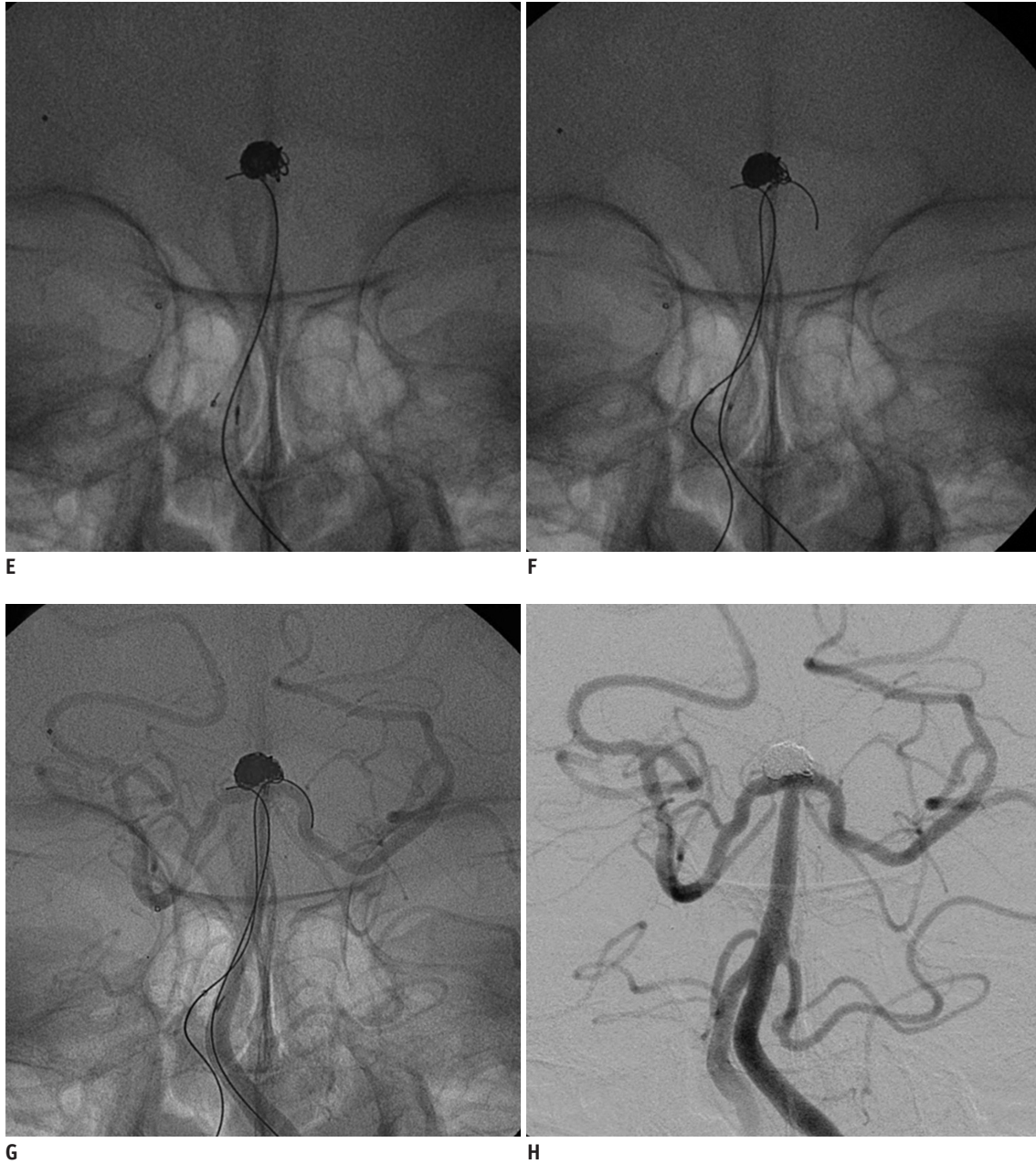
#### Case 1

A 68-year-old female was admitted for endovascular



**Fig. 5. Illustrative case 1.**

**A.** Wide-necked basilar tip aneurysm seen on conventional angiography (note incorporation of both posterior cerebral artery [PCA] orifices by aneurysm). **B, C.** Coil frame (no protrusion but unstable) configured using microcatheter protective technique (right PCA). **D.** Microcatheter added to aneurysmal sac through additional guiding catheter in contralateral vertebral artery.

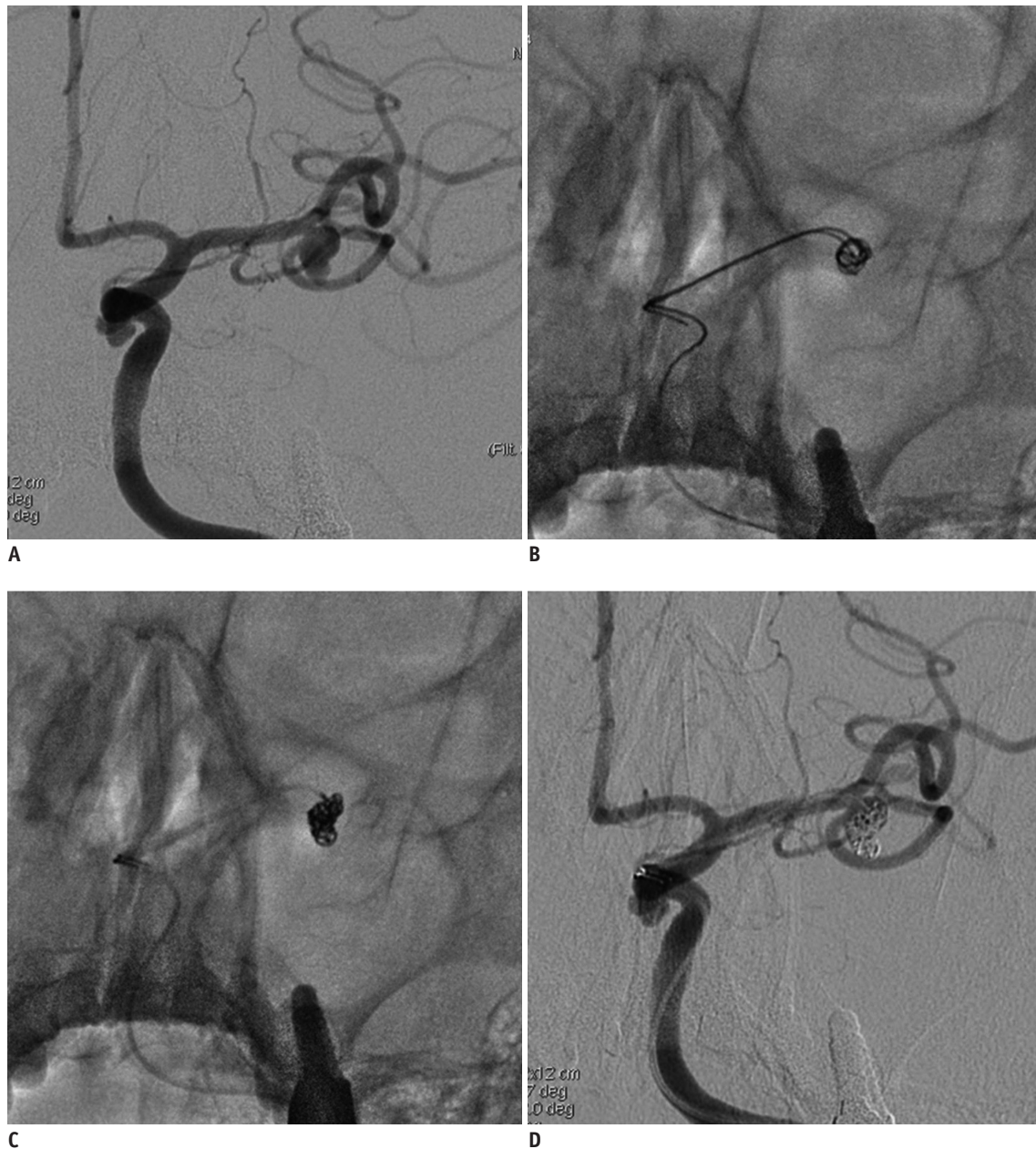


**Fig. 5. Illustrative case 1.**

**E.** Intractable coil protrusion (left posterior cerebral artery [PCA]) during delivery of filler coil. **F.** Microcatheter repositioned from aneurysmal sac to left PCA for protection. **G.** Coil added via single microcatheter under dual microcatheter protection. **H.** Complete occlusion of aneurysm.

treatment of an unruptured basilar tip aneurysm detected during investigation of headache. Conventional angiography revealed a wide-necked aneurysm (Fig. 5A), so a 6-Fr guiding catheter was placed in the cervical segment of the left vertebral artery (VA). Our initial plan called for a microcatheter protective technique, positioning one catheter within the sac to deliver the coil and passing the other into right posterior cerebral artery (PCA) for protection (Fig. 5B). An initial coil frame was formed

through persistent efforts without the coil protruding into the parent artery; however, it appeared unstable (Fig. 5C). Another 5-Fr guiding catheter was advanced into the right VA, and a third microcatheter was placed within the sac (Fig. 5D). A frame coil was then added to intermix with the existing framing coil to enhance its stability. Later, an errant loop of the filler coil protruded into the left PCA (Fig. 5E). One of the two microcatheters was subsequently withdrawn from the sac and was passed into the left PCA



**Fig. 6. Illustrative case 2.**

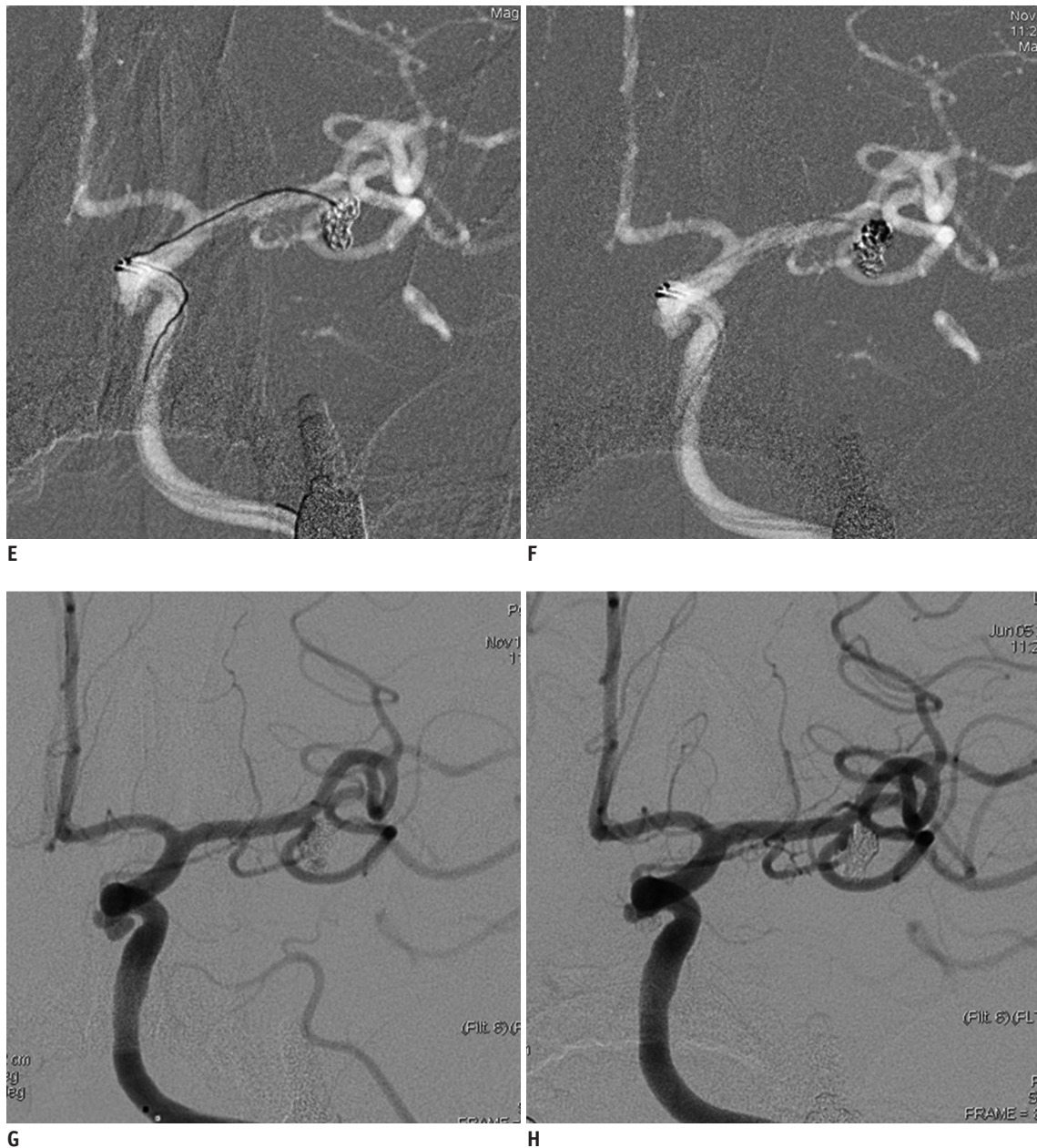
**A.** Middle cerebral artery (MCA) bifurcation aneurysm on conventional angiography (note incorporation of inferior division of MCA by wide-necked shallow aneurysm). **B.** Dual microcatheters positioned in inferior aneurysmal sac. **C, D.** Proper coil frame (without protrusion) configured with dual microcatheters, leaving void in superior aneurysmal sac.

for protection (Fig. 5F). An additional coil was added under dual microcatheter protection of the PCA (bilaterally) (Fig. 5G) to occlude the aneurysm (Fig. 5H). The patient was discharged the next day without complications.

### Case 2

A 68-year-old female was admitted for endovascular treatment of an unruptured aneurysm, located at the MCA bifurcation. The aneurysm broadly incorporated the orifice

of the inferior division, originating at an acute angle (Fig. 6A). In this setting, passing a microcatheter to deliver a stent seemed technically difficult. A 7-Fr guiding catheter was placed in the cervical segment of the left internal carotid artery, and dual microcatheters were placed in the inferior portion of the aneurysm to deliver the coil (Fig. 6B). Two coils were inserted, and a coil frame formed with considerable effort that did not protrude into the inferior division (Fig. 6C, D). Unfortunately, the superior



**Fig. 6. Illustrative case 2.**

**E, F.** Microcatheter added to superior aneurysmal sac, creating supplemental and initial coil frame mix. **G.** After withdrawing one microcatheter (inferior side), coil was added via dual microcatheters to successfully occlude aneurysm. **H.** Stably occluded aneurysm 6-month follow-up angiography.

segment of the aneurysm lacked an initial coil frame (Fig. 6E), so another microcatheter was placed within the void (Fig. 6F). A third coil was ultimately delivered to blend with the existing coils. Thereafter, one microcatheter was removed and additional filling coils were inserted via dual microcatheters. The lesion was satisfactorily occluded (Fig. 6G) without complication. Conventional angiography performed at the 6-month follow-up revealed stable occlusion of the aneurysm (Fig. 6H).

## DISCUSSION

Improvements in protective devices and coiling techniques, including balloon remodeling and stent protection have rendered many previously ineligible aneurysms with difficult configurations amenable to selective endovascular treatment (16). However, angio-anatomic complexities, including extreme vessel tortuosity or intricate vascular arrangements occasionally prohibit



using these techniques (17). Dual microcatheter coil embolization, pioneered by Baxter et al. (10), may be a viable alternate technical strategy for challenging wide-neck intracranial aneurysms (11, 12, 18, 19), although two microcatheters are occasionally insufficient to form a stable coil frame without protrusion or to protect the parent artery from impingement. Hence, a third microcatheter may be added for these purposes. Three microcatheters may also help to meticulously fill every nook of an aneurysm with a coil for optimal compaction through even distribution when used in some large-sized or trilobulated lesions. Indeed, the triple microcatheter technique may be helpful and effective in aneurysms where customary dual microcatheters or microcatheter protective measures have failed or are inadequate to construct a proper coil frame. In addition, balloons or stents may be avoided in some aneurysms with prohibitive angio-anatomic features (i.e., arterial tortuosity and small arterial size). In contrast, thromboembolic risk is heightened by this number of microcatheters within a parent artery or a guiding catheter. To reduce this threat, each microcatheter is withdrawn once its contribution to proper, stable coil frame configuration (without protrusion or voids) is completed.

Kwon et al. (11) were the first to report coil embolization using three or more microcatheters. According to their description, deploying multiple microcatheters was used only to deliver the coil; thus, enhancing stability of the coil frame. Our series demonstrates that strategic variations may easily be adopted to accommodate specific angio-anatomic restrictions, including utilization of one or two microcatheters as protective devices. Such variations may be necessary to compensate for deficiencies in coil embolization.

Although uncommon, limitations of this triple microcatheter technique include distal aneurysms with small-sized parent arteries or crowding within guiding catheters or parent arteries that hampers control of microcatheter tension. In one of our patients with a distal anterior communicating artery (ACA) aneurysm, triple microcatheters posed no problem due to an azygous-ACA A2 segment of sufficient caliber. Another patient required a dual guiding system (via double femoral punctures) because flow in the dominant VA could not be maintained with a 7-Fr guiding catheter in place. Throngs of a guiding microcatheters and parent arteries may also increase the chance for thromboembolic complications during the procedure. Thus, we recommend that each microcatheter be

withdrawn after serving its purpose, such as stabilizing or protecting the coil. Finally, interlocking or stretching coils may be problematic when multiple coils are manipulated (11), although this did not occur in the present cohort.

This technique is not recommended as a first-line strategy. However, collective outcomes in this small series of patients suggest that coil embolization via three microcatheters may be safely and effectively implemented after tailored technical modifications for some wide-necked saccular aneurysms, where circumstances are not conducive to stent or balloon protection (i.e., complex angio-anatomic configurations or rupture). The clinical and anatomic outcomes are particularly encouraging.

In conclusion, this triple microcatheter technique may have value in settings where traditional remodeling or protective techniques are precluded by aneurysmal configuration and vascular anatomy and where traditional coiling in wide-necked shallow aneurysms proves difficult through technical strategies that address such angio-anatomic challenges. Long-term study of a larger patient series is needed to confirm the preliminary safety and efficacy seen here.

#### Acknowledgments

We thank Ms. Yoon-Kyung Choi for preparation of the illustrations.

#### REFERENCES

1. Molyneux A, Kerr R, Stratton I, Sandercock P, Clarke M, Shrimpton J, et al. International Subarachnoid Aneurysm Trial (ISAT) of neurosurgical clipping versus endovascular coiling in 2143 patients with ruptured intracranial aneurysms: a randomised trial. *Lancet* 2002;360:1267-1274
2. Wiebers DO, Whisnant JP, Huston J 3rd, Meissner I, Brown RD Jr, Piepgras DG, et al. Unruptured intracranial aneurysms: natural history, clinical outcome, and risks of surgical and endovascular treatment. *Lancet* 2003;362:103-110
3. Shapiro M, Babb J, Becske T, Nelson PK. Safety and efficacy of adjunctive balloon remodeling during endovascular treatment of intracranial aneurysms: a literature review. *AJNR Am J Neuroradiol* 2008;29:1777-1781
4. Pierot L, Cognard C, Spelle L, Moret J. Safety and efficacy of balloon remodeling technique during endovascular treatment of intracranial aneurysms: critical review of the literature. *AJNR Am J Neuroradiol* 2012;33:12-15
5. Biondi A, Janardhan V, Katz JM, Salvaggio K, Riina HA, Gobin YP. Neuroform stent-assisted coil embolization of wide-neck intracranial aneurysms: strategies in stent deployment and midterm follow-up. *Neurosurgery* 2007;61:460-468; discussion

468-469

6. Lee SJ, Cho YD, Kang HS, Kim JE, Han MH. Coil embolization using the self-expandable closed-cell stent for intracranial saccular aneurysm: a single-center experience of 289 consecutive aneurysms. *Clin Radiol* 2013;68:256-263
7. Mangubat EZ, Johnson AK, Keigher KM, Lopes DK. Initial Experience with Neuroform EZ in the Treatment of Wide-neck Cerebral Aneurysms. *Neurointervention* 2012;7:34-39
8. Starke RM, Durst CR, Evans A, Ding D, Raper DM, Jensen ME, et al. Endovascular treatment of unruptured wide-necked intracranial aneurysms: comparison of dual microcatheter technique and stent-assisted coil embolization. *J Neurointerv Surg* 2015;7:256-261
9. Pan J, Xiao F, Szeder V, Yan M, Fan W, Gu J, et al. Stent, balloon-assisted coiling and double microcatheter for treating wide-neck aneurysms in anterior cerebral circulation. *Neurol Res* 2013;35:1002-1008
10. Baxter BW, Rosso D, Lownie SP. Double microcatheter technique for detachable coil treatment of large, wide-necked intracranial aneurysms. *AJNR Am J Neuroradiol* 1998;19:1176-1178
11. Kwon OK, Kim SH, Kwon BJ, Kang HS, Kim JH, Oh CW, et al. Endovascular treatment of wide-necked aneurysms by using two microcatheters: techniques and outcomes in 25 patients. *AJNR Am J Neuroradiol* 2005;26:894-900
12. Lee JY, Seo JH, Cho YD, Kang HS, Han MH. Endovascular treatment of wide-neck intracranial aneurysms using a microcatheter protective technique: results and outcomes in 75 aneurysms. *AJNR Am J Neuroradiol* 2011;32:917-922
13. Kang HS, Kwon BJ, Kim JE, Han MH. Preinterventional clopidogrel response variability for coil embolization of intracranial aneurysms: clinical implications. *AJNR Am J Neuroradiol* 2010;31:1206-1210
14. Raymond J, Guilbert F, Weill A, Georganos SA, Juravsky L, Lambert A, et al. Long-term angiographic recurrences after selective endovascular treatment of aneurysms with detachable coils. *Stroke* 2003;34:1398-1403
15. Kang HS, Han MH, Kwon BJ, Kwon OK, Kim SH, Choi SH, et al. Short-term outcome of intracranial aneurysms treated with polyglycolic acid/lactide copolymer-coated coils compared to historical controls treated with bare platinum coils: a single-center experience. *AJNR Am J Neuroradiol* 2005;26:1921-1928
16. Cho YD, Kang HS, Kim JE, Ahn JH, Jung SC, Kim CH, et al. Microguidewire protection of wide-necked aneurysms incorporating orifices of tortuous acute-angled vessels: a novel approach. *Neuroradiology* 2014;56:553-559
17. Cho YD, Lee WJ, Kim KM, Kang HS, Kim JE, Han MH. Endovascular coil embolization of middle cerebral artery aneurysms of the proximal (M1) segment. *Neuroradiology* 2013;55:1097-1102
18. Durst CR, Starke RM, Gaughen JR Jr, Geraghty S, Kreitel KD, Medel R, et al. Single-center experience with a dual microcatheter technique for the endovascular treatment of wide-necked aneurysms. *J Neurosurg* 2014;121:1093-1101
19. Kim DJ, Kim BM, Park KY, Ihm EH, Baek JH, Kim DI. Coil embolization of overwide and undertall small intracranial aneurysms with double microcatheter technique. *Acta Neurochir (Wien)* 2014;156:839-846