

A hyperkeratotic drug reaction in a patient on antiretroviral therapy



Kayla H. Felix, MS, Omar Sangueza, MD, Steven R. Feldman, MD, PhD, and Maria Mariencheck, MD, PhD
Winston-Salem, North Carolina

Key words: antiretroviral therapy; drug reaction; HIV; hyperkeratosis; syphilis.

INTRODUCTION

Cutaneous adverse drug reactions can present with a multitude of morphologies. In the treatment of patients with HIV, reported adverse dermatologic reactions are more common than in the general population, and characterization has been widely variable.^{1,2} A novel fixed-dose combination drug containing bictegravir, emtricitabine, and tenofovir alafenamide (BIC/F/TAF) was approved in 2018 by the Food and Drug Administration as a first-line therapy for HIV. In clinical trials, this combination did not cause major cutaneous reactions, although other antiretroviral therapies, including emtricitabine alone, have been implicated.²⁻⁴ There is currently a lack of published material describing the potential dermatologic reactions resulting from its use. As a result, in a setting with multiple dermatologic risk factors, the diagnosis of a cutaneous drug reaction to BIC/F/TAF may prove challenging.

We describe a 57-year-old African American male who presented with worsening hyperkeratosis of the hands and feet after initial antiretroviral therapy with BIC/F/TAF.

CASE DESCRIPTION

A 57-year-old African American male presented to the clinic with a 3-week history of worsening skin sloughing on the hands and feet. His medical history included a recent diagnosis of HIV 4 months prior, initiation of an antiretroviral therapy with BIC/F/TAF

Abbreviation used:

BIC/F/TAF: bictegravir, emtricitabine, tenofovir alafenamide

2 months prior, and recent hospitalization and treatment for neurosyphilis 5 weeks prior to this visit. Though the patient noticed these worsening skin changes over the 3 weeks preceding this visit, hyperkeratosis and discoloration of the palms had been noted during his hospitalization for neurosyphilis. Treatment with intravenous penicillin G for syphilis at the time did not improve the rash.

In addition to the skin sloughing of the hands and feet, he also complained of dry skin on the chest and back and a rash at the hairline. He denied experiencing constitutional or arthritic symptoms and had no known history of an inflammatory disease.

On examination, the patient had hyperpigmentation and plaque-like hyperkeratosis of the bilateral palms and soles, which extended onto the lateral and dorsal surfaces, with minimal signs of inflammation (Fig 1). Along the hairline, scaling and hyperpigmentation with hyperkeratosis were observed, although less severe than those observed on the hands and feet. The thorax was xerotic, without inflammation or hyperkeratosis, and the knees and elbows had no visible lesions. Laboratory results included a CD4 count of 410 cells/ μ L, with an unremarkable urinalysis and metabolic panel. The patient's occupation entailed stacking cardboard

From the Department of Dermatology, Wake Forest School of Medicine, Winston-Salem, North Carolina.

Funding sources: None.

Conflicts of interest: Dr Feldman has received research, speaking, and/or consulting support from companies, including Galderma, GSK/Stiefel, Almirall, Alvotect, Leo Pharma, BMS, Boehringer Ingelheim, Mylan, Celgene, Pfizer, Ortho Dermatology, Abbvie, Samsung, Janssen, Lilly, Menlo, Merck, Novartis, Regeneron, Sanofi, Novan, Quriat, National Biological Corporation, Caremark, Advance Medical, Sun Pharma, Suncare Research, Informa, UpToDate, and National Psoriasis Foundation. He consults for others through Guidepoint Global and Gerson Lehrman. He is a founder of and majority owner of

www.DrScore.com and is a founder and part owner of Causa Research. Kayla Felix, Dr Sangueza, and Dr Mariencheck have no conflicts of interest to declare.

Correspondence to: Kayla H. Felix, MS, 4618 Country Club Rd, Winston-Salem, NC 27104. E-mail: kfelix@wakehealth.edu.

JAAD Case Reports 2020;6:1239-41.

2352-5126

© 2020 by the American Academy of Dermatology, Inc. Published by Elsevier, Inc. This is an open access article under the CC BY-NC-ND license (<http://creativecommons.org/licenses/by-nc-nd/4.0/>).

<https://doi.org/10.1016/j.jidcr.2020.10.001>

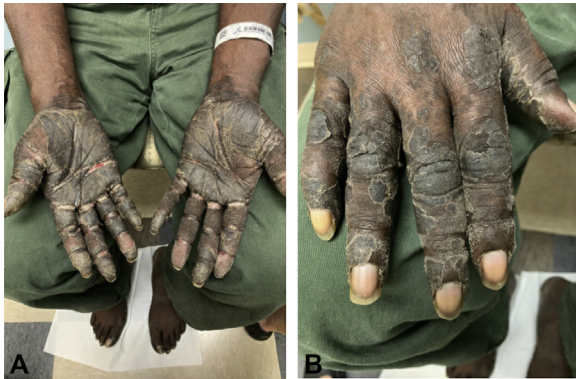

Fig 1. Hyperkeratosis and hyperpigmentation of the bilateral palms (**A**) and the dorsal surface (**B**) of a patient with HIV undergoing retroviral therapy.

boxes, and he did not undergo a patch test because he had not experienced any recent changes in terms of occupation or exposure.

A 3-mm punch biopsy of the right hand was performed. Histopathologic findings included acanthosis, papillomatosis, focal parakeratosis, spongiosis, vacuolar changes, and postinflammatory changes with prominent melanophages, features that are consistent with those of a cutaneous adverse drug reaction (Fig 2).

The patient was prescribed 0.1% triamcinolone acetonide compounded with 1% silver sulfadiazine (3:1) for topical application to the hands and feet 3 times daily. His antiretroviral therapy was switched from BIC/F/TAF to darunavir/cobicistat/emtricitabine/tenofovir alafenamide. A follow-up physical examination after 5 months revealed significant improvement in the hyperkeratosis of the bilateral hands and feet and in the xerosis throughout. Hyperpigmentation and distal onycholysis with onychomadesis persisted.

DISCUSSION

BIC/F/TAF was approved in 2018, so its adverse event profile may not have been fully characterized. With the use of emtricitabine alone, cases of hyperpigmentation without hyperkeratosis of the palms and soles have been reported, especially in African-American patients.⁴ However, this report highlights a case of severe hyperpigmentation and hyperkeratosis secondary to BIC/F/TAF use in a setting with both HIV and syphilis infection. As a result, the cutaneous presentation may be confused with other dermatologic conditions with morphologic similarities.

The differential diagnosis in this case is broad because of the combination of risk factors that this patient had for a variety of dermatologic conditions. The patient's history of HIV put him at a risk of more

severe and refractory presentations of inflammatory conditions such as psoriasis and atopic dermatitis.^{5,6} Contact dermatitis, secondary to his occupation, was considered, although the distribution of the lesions and involvement of the soles and forehead was less consistent with this diagnosis. Palmoplantar psoriasis could present similarly, with hyperkeratosis of the palms and soles, and could have been worsened by the patient's occupation, which involved frequent handling of boxes. The morphology and distribution of the lesions was also consistent with keratoderma blennorrhagica, which may be a component of reactive arthritis. Keratoderma blennorrhagica is similar in appearance to palmoplantar psoriasis and can be associated with sexually transmitted infections; however, mucocutaneous and ocular involvement is common, which was not observed in this patient.⁷

Immune reconstitution inflammatory syndrome was also considered in the differential diagnosis. Despite the temporal association with the initiation of antiretroviral therapy, there were no systemic inflammatory symptoms, constitutional symptoms, or findings consistent with the features of an opportunistic infection. Additionally, the histopathologic findings in this patient were not suggestive of such an inflammatory condition. Acrokeratosis neoplastica was also a differential diagnosis; however, the lack of constitutional symptoms or other systemic findings made an underlying malignancy less likely.

This patient also simultaneously had syphilis, which further complicated the diagnosis. Secondary syphilis can cause syphilitic keratoderma, which can also result in hyperkeratotic symmetric lesions on the palms and soles.⁸ Its histopathology is variable but typically reveals a mononuclear infiltrate extending into the dermis as well as endothelial involvement, including vascular proliferation and swelling.⁹ In this case, the changes were confined mainly to the epidermis. The skin lesions due to syphilis are often improved or resolved by the treatment of the infection; yet, this patient experienced worsening of the hyperkeratosis even after the treatment with intravenous penicillin.

Despite the several possible etiologies suggested for this patient's presentation, a cutaneous adverse drug reaction should always be considered in patients with HIV presenting with new skin findings. Patients with HIV can be 10-100 times more likely to experience an adverse drug reaction than patients without HIV.² Along with the risk of adverse reactions, there is an increased risk of coinfection with other sexually transmitted diseases. Timely characterization and the diagnosis of cutaneous findings can allow for the proper

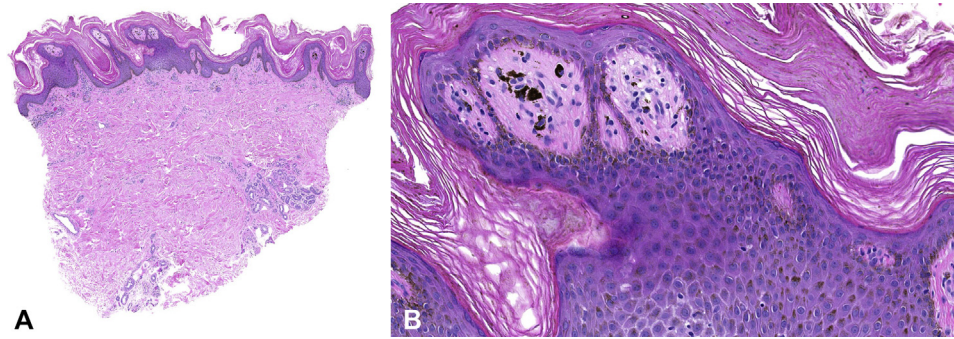


Fig 2. **A**, A skin biopsy shows acanthosis, papillomatosis, and hyperkeratosis. **B**, A higher magnification shows spongiosis and perivascular infiltrates associated with prominent post-inflammatory changes with numerous melanophages.

treatment of concomitant infections or optimization of the antiretroviral medical regimen for the reduction of adverse effects.

REFERENCES

1. Borrás-Blasco J, Navarro-Ruiz A, Borrás C, Casterá E. Adverse cutaneous reactions associated with the newest antiretroviral drugs in patients with human immunodeficiency virus infection. *J Antimicrob Chemother.* 2008;62(5):879-888.
2. Carr A, Cooper DA. Adverse effects of antiretroviral therapy. *Lancet.* 2000;356(9239):1423-1430.
3. Hill L, Smith SR, Karris MY. Profile of bictegravir/emtricitabine/tenofovir alafenamide fixed dose combination and its potential in the treatment of HIV-1 infection: evidence to date. *HIV AIDS (Auckl).* 2018;10:203-213.
4. Shirasaka T, Tadokoro T, Yamamoto Y, et al. Investigation of emtricitabine-associated skin pigmentation and safety in HIV-1-infected Japanese patients. *J Infect Chemother.* 2011; 17(5):602-608.
5. Tan J, Pina A, Borges-Costa J. Skin diseases in the era of highly active antiretroviral therapy: a retrospective study of 534 patients. *J Int Assoc Provid AIDS Care.* 2018;17:2325957417752255.
6. Ceccarelli M, Venanzi Rullo E, Vaccaro M, et al. HIV-associated psoriasis: epidemiology, pathogenesis, and management. *Dermatol Ther.* 2019;32(2):e12806.
7. Calin A. Keratoderma blennorrhagica and mucocutaneous manifestations of Reiter's syndrome. *Ann Rheum Dis.* 1979; 38(Suppl 1):68-72.
8. Bittencourt Mde J, Brito AC, Nascimento BA, Carvalho AH, Nascimento MD. A case of secondary syphilis mimicking palmoplantar psoriasis in HIV infected patient. *An Bras Dermatol.* 2015;90(3):216-219.
9. Engelkens HJ, Ten Kate FJ, Vuzevski VD, Van der Sluis JJ, Stolz E. Primary and secondary syphilis: a histopathological study. *Int J STD AIDS.* 1991;2(4):280-284.