

# Endovascular coiling in the treatment of patients with renal artery aneurysms

Louise M. Finch, MBChB, MPhil,<sup>a</sup> Harry V. M. Spiers, MBBS, BSc,<sup>c</sup> Rajkumar Chinnadurai, MBBS, MRCP, PhD,<sup>a</sup> Amit Herwadkar, MBBS, FRCR,<sup>d</sup> Ganapathy Anantha-Krishnan, MBBS, FRCR,<sup>b</sup> and Titus Augustine, MBBS, MS, FRCSEd,<sup>a,e</sup> *Manchester, Cambridge, and Salford, United Kingdom*

## ABSTRACT

Endovascular coiling is a percutaneous endovascular technique used in the management of arterial aneurysms with high success rates and minimal associated morbidity. We present a series of three patients with incidental renal artery aneurysms treated successfully with endovascular coiling, despite comorbidities. One patient had an aneurysm associated with a solitary kidney. The decision to use this technique becomes critical when the aneurysm involves a single functioning kidney. Each renal artery aneurysm was successfully coiled by combining vascular and neurointerventional techniques. The results from the present case series also highlight the challenges faced in therapeutic decision-making in complex situations with limited error margins. (*J Vasc Surg Cases and Innovative Techniques* 2021;7:307-10.)

**Keywords:** Aneurysm; Case report; Endovascular; Renal artery; Solitary kidney

Renal artery aneurysms (RAAs) are rare, with an incidence estimated at 0.01%.<sup>1</sup> Usually, RAAs will be incidentally detected during imaging studies.<sup>2</sup> With the increase in diagnostic imaging, it is likely that clinicians will encounter greater numbers of RAAs. Spontaneous rupture is a serious complication, with mortality rates as high as 80% and the loss of the associated kidney in the survivors.<sup>3</sup> In general, intervention is advisable for aneurysms >2 cm in diameter and those that are symptomatic.<sup>2</sup> Surgical techniques were the mainstay of treatment before the advent of endovascular interventions.<sup>4</sup>

Endovascular repair includes embolization or stent grafting. Although complications include end organ perfusion deficits,<sup>5</sup> the benefits include the avoidance of surgery, lower complication rates, and shorter hospital stays.<sup>6</sup> The management decisions must be considered judiciously, especially for comorbid patients at greater

risk of complications and patients with a solitary kidney. Any morbidity associated with the intervention could lead to kidney loss, requiring renal replacement therapy. We report the cases of three patients, including one patient with a solitary functioning kidney, in whom the RAAs were managed using endovascular coiling techniques. All three patients provided written informed consent for the report of their case.

## CASE REPORT

**Patient 1.** A 68-year-old man had been referred with an incidental finding of a right RAA with normal renal function (estimated glomerular filtration rate [eGFR], >90 mL/min/1.73 m<sup>2</sup>).

Renal angiography demonstrated a 2-cm saccular, wide-necked aneurysm arising at the bifurcation of the right renal artery (*Fig 1, a*). After a multidisciplinary team (MDT) discussion considering surveillance, endovascular intervention, or surgery, the patient chose RAA embolization. We obtained 8F catheter access to allow for advancement of the catheter into the right renal artery. A double microcatheter technique was used, with the coils interlocked to prevent prolapse into the parent vessel. Two Excelsior SL-10 microcatheters (Stryker, Kalamazoo, Mich) were placed in the aneurysm, deploying the bare platinum coils under “road maps” to maintain branch vessel patency (*Fig 1, b* and *c*). The coils were preselected according to the computed tomography (CT) and angiographic measurements and availability. The findings from completion angiograms were satisfactory, with a good nephrogram. A total of 65 mL of contrast was used. The patient had an uneventful postprocedural course, and the eGFR was >90 mL/min/1.73 m<sup>2</sup> after 2 years.

**Patient 2.** A 69-year-old man had been referred with a left RAA incidentally found on CT colonography (*Fig 2, a*). He was a smoker with a previous stroke, chronic obstructive pulmonary disease, type 2 diabetes mellitus, and hypercholesterolemia. These comorbidities placed him at significant risk of complications and mortality with surgical intervention. An MDT considered

---

From the Department of Renal and Pancreas Transplantation,<sup>a</sup> and Department of Interventional Radiology<sup>b</sup>, Manchester University NHS Foundation Trust, Manchester; the Department of Surgery, Addenbrooke's Hospital, Cambridge University Hospitals NHS Foundation Trust, Cambridge<sup>c</sup>; the Department of Interventional Neuroradiology, Salford Royal NHS Foundation Trust, Salford<sup>d</sup>; and the Division of Diabetes, Endocrinology and Gastroenterology, School of Medical Sciences, Faculty of Biology, Medicine and Health, Manchester Academic Health Science Centre, University of Manchester, Manchester.<sup>e</sup>

Author conflict of interest: none.

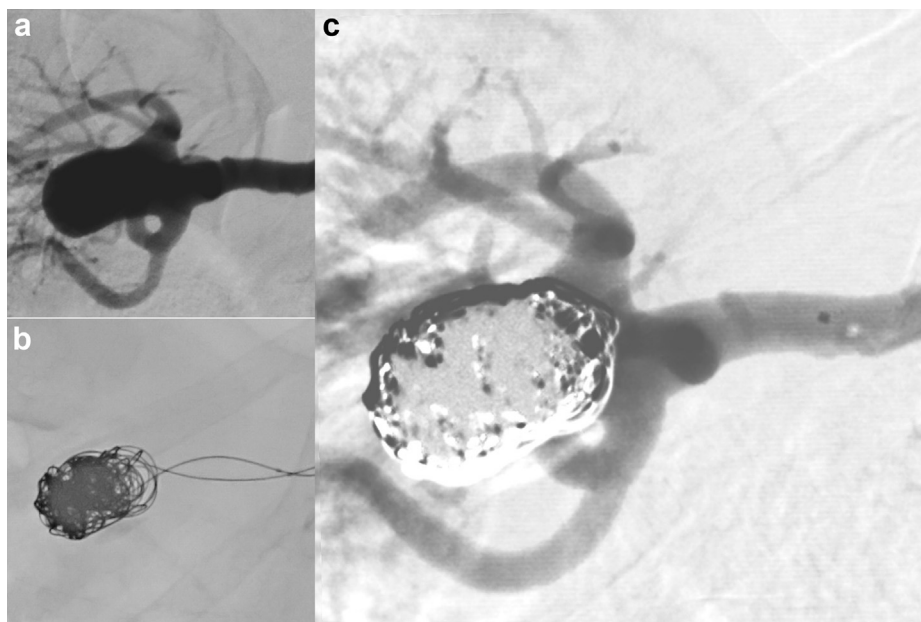
Correspondence: Louise M. Finch, MBChB, MPhil, Department of Renal and Pancreas Transplantation, Manchester, University NHS Foundation Trust, Oxford Rd, Manchester M13 9WL, United Kingdom (e-mail: [Louise.finch5@nhs.net](mailto:Louise.finch5@nhs.net)).

The editors and reviewers of this article have no relevant financial relationships to disclose per the Journal policy that requires reviewers to decline review of any manuscript for which they may have a conflict of interest.

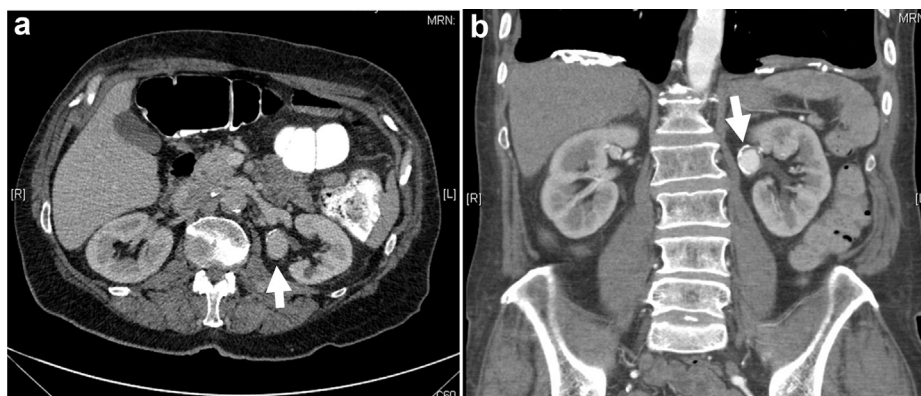
2468-4287

© 2021 The Authors. Published by Elsevier Inc. on behalf of Society for Vascular Surgery. This is an open access article under the CC BY-NC-ND license (<http://creativecommons.org/licenses/by-nc-nd/4.0/>).

<https://doi.org/10.1016/j.jvscit.2021.03.006>



**Fig 1.** Patient 1, with double catheter coiling technique. **a**, Pre-embolization angiogram of 2-cm renal artery aneurysm (RAA). **b**, Two microcatheters in different positions were used to interlock the coils within the RAA. **c**, Postembolization angiogram.

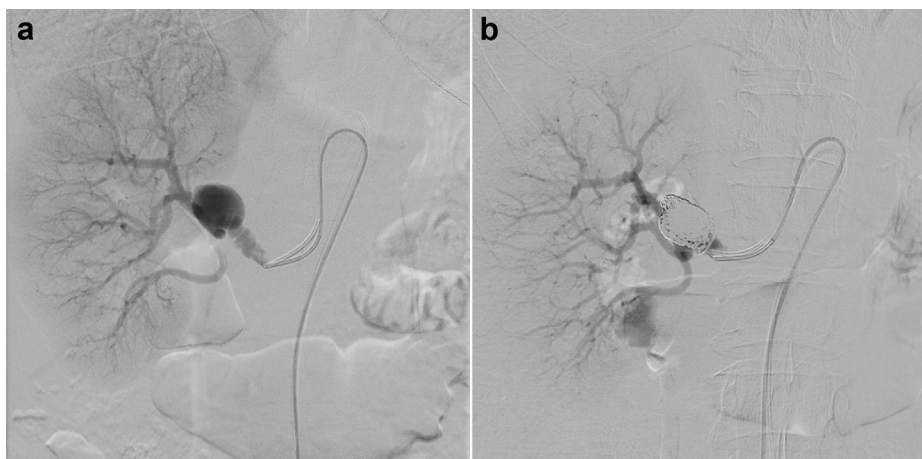


**Fig 2.** Computed tomography (CT) imaging of patient 2. **a**, Incidental left renal artery aneurysm (RAA; arrow) seen on CT colonography. **b**, CT angiogram showing a left 2.5-cm  $\times$  1.8-cm RAA (arrow).

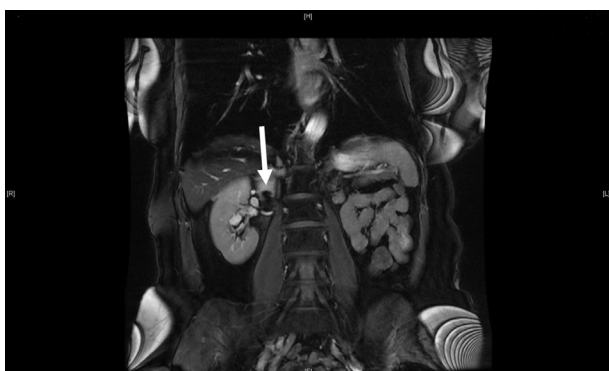that endovascular intervention would provide the best risk/benefit option. CT angiography demonstrated a 1.8  $\times$  2.5-cm aneurysm arising from the upper pole branch of the left renal artery and a second 8-mm aneurysm at the hilum of the right kidney (Fig 2, b). The preprocedure eGFR was preserved (89 mL/min/1.73 m<sup>2</sup>). The left renal artery was accessed with a 6F long sheath catheter and selectively cannulated before being embolized using multiple Azur CX peripheral coil systems (Terumo, Somerset, NJ), requiring 70 mL of contrast. No postprocedural complications developed. The CT scan at 1 month revealed successful embolization with patent side branches. His renal function at 2 years was preserved (eGFR, 86 mL/min/1.73 m<sup>2</sup>).

**Patient 3.** A 53-year-old woman with hypertension had presented with intermittent left loin pain of 4 months' duration. A CT

scan showed a right RAA that was eccentric, incorporating both upper and lower pole branches. The main branch was supplying the upper pole of the kidney, and the lower two arteries were of small caliber. Fibromuscular dysplasia of the renal artery and an atrophic left kidney were present. A dimercaptosuccinic acid scan evaluating the split renal function showed 98% function in the right kidney, with only 2% in the left. Given the preserved renal function (eGFR, 81 mL/min/1.73 m<sup>2</sup>), which was almost entirely maintained by the kidney with the aneurysmal arterial supply, conservative management was considered. The surveillance magnetic resonance angiogram at 1 year demonstrated unchanged size and morphology. Despite this, the patient's anxiety regarding the potential for rupture and subsequent renal failure or mortality prompted her to opt for definitive management. It was thought that with an endovascular stent, the branch would



**Fig 3.** Patients 3, with double catheter coiling technique. **a**, Catheter angiogram of 2-cm  $\times$  1.4-cm renal artery aneurysm (RAA) before coiling. **b**, Catheter angiogram of RAA after coiling.



**Fig 4.** Good renal perfusion was present at 6 months after embolization. Magnetic resonance imaging scan at 6 months of follow-up showing patent right renal artery with good perfusion of the entire kidney and the thrombosed aneurysm sac with the coils satisfactorily excluded from circulation (arrow).

be compromised, leading to significant nephron loss; hence, a shared decision was made to proceed with double catheter coiling.

Bilateral groin access was achieved using a 5F system, and 5F sidewinder catheters were placed within the right renal artery. Three-dimensional angiography confirmed a 2  $\times$  1.4-cm wide-necked RAA. Framing baskets were obtained using coils, which were interlocked to allow for parent and branch vessel patency. Twelve coils were deployed, and satisfactory obliteration of the aneurysm was achieved, with preservation of the main artery and side branches (Fig 3). The total contrast required was 50 mL.

Her postprocedure course was uneventful, and at 3 years, her renal function was preserved. The magnetic resonance angiogram demonstrated a patent right renal artery with good perfusion of the entire kidney (Fig 4).

## DISCUSSION

No well-defined criteria are available for intervention of RAAs.<sup>7</sup> Abdominal aortic aneurysms, in contrast, have

well-defined criteria for intervention.<sup>8</sup> The decision between surveillance and intervention becomes critical when the RAA is asymptomatic, especially in the context of a solitary functioning kidney. Henke et al<sup>2</sup> demonstrated in 168 patients that all RAAs  $>2$  cm, most of those 1.5 to 2 cm, and those  $>1$  cm with difficult-to-control hypertension should be considered for intervention. The decision not to proceed with embolization should be made by an MDT with consideration of the patient factors, including comorbidities, and technical factors, including branch aneurysms, a wide neck, and perceived high risk of renal loss. In the present cohort, the decision for definitive treatment, despite the small risk of rupture was, to an extent, by patient choice.

The endovascular technique has the advantages of being minimally invasive, requiring a short stay, and the use of a percutaneous approach. Various endovascular options exist for RAAs, each have their advantages and disadvantages<sup>3,4,9-12</sup> (Table). Coil embolization, as in patient 2, is ideal for a sac-like aneurysm with a narrow neck.<sup>9</sup>

The double microcatheter technique, used for patients 1 and 3, is more commonly used in neurointerventional radiology.<sup>10</sup> Two microcatheters are fed through one guiding sheath in which two or more coils can be deployed. The key advantage is that the initial coil does not have to be detached from the catheter while positioning the second coil, providing a stable frame, which can be imaged using biplanar screening, preventing coil migration.<sup>10</sup> Goto et al<sup>13</sup> reported three cases of RAAs managed with the double microcatheter technique, with no complications. The findings from our patients have added to this body of evidence, indicating the favorability of the double catheter technique.

For patient 3, we reported the successful endovascular management of an RAA in a solitary functioning kidney. Three previous cases of management of an RAA in a solitary kidney have been reported, including the use of a pipeline embolization device,<sup>14</sup> balloon-assisted coil

**Table.** Advantages and disadvantages of endovascular options for treatment of RAAs

Technique	Indication	Advantages	Disadvantages
Coil embolization	Sac-like narrow neck	Used most often <sup>9</sup>	Risk of segmental branch occlusion <sup>9</sup> ; risk of coil migration
Covered stent graft	Main renal artery	Used in fusiform aneurysms; preserves flow through main artery <sup>4</sup>	Cannot be used at bifurcation; cannot be used in presence of atherosclerosis; risk of graft occlusion <sup>4</sup>
Liquid embolization	Sac-like; narrow neck	Complete aneurysm sac obliteration <sup>3</sup>	Risk of liquid migration <sup>3</sup>
Balloon-assisted coil and liquid embolization	Wide neck	Prevents coil migration <sup>11</sup>	Risk of aneurysm rupture due to balloon inflation near neck <sup>11</sup>
Stent-assisted coil and liquid embolization	Wide neck	Maintains flow through branch vessels <sup>9</sup>	Not feasible in small, tortuous vessels <sup>9</sup>
Flow diverter stents	Complex aneurysms, branch vessels <sup>12</sup>	Maintains flow through branch vessels <sup>12</sup>	Lack of occlusion requiring reintervention, risk of emboli, requires double antiplatelet treatment <sup>12</sup>
Double microcatheter technique	Complex aneurysms, wide neck, branch vessels	Deployment of second stent without release of first, producing a stable frame <sup>10</sup>	Risk of coil migration <sup>10</sup>

RAA, Renal artery aneurysm.

embolization,<sup>11</sup> and a robotic surgical technique with partial RAA excision and tailored repair.<sup>15</sup> Our report of an RAA in a single functioning kidney has demonstrated successful management with the double catheter embolization technique.

## CONCLUSIONS

The management of RAAs is evolving, with increasing usage of endovascular techniques. For patients in whom a solitary kidney provides most of the function, the margin of error is an extremely low to prevent the need for renal replacement therapy. The techniques used for cerebrovascular aneurysms can be used in the management of complex RAAs, even in solitary kidneys. The therapeutic decision-making process requires input from the patient and an MDT.

## REFERENCES

- Stanley JC, Rhodes EL, Gewertz BL, Chang CY, Walter JF, Fry WJ. Renal artery aneurysms: significance of macroaneurysms exclusive of dissections and fibrodysplastic mural dilations. *Arch Surg* 1975;110:1327-33.
- Henke PK, Cardneau JD, Welling TH, Upchurch GR, Wakefield TW, Jacobs LA, et al. Renal artery aneurysms: a 35-year clinical experience with 252 aneurysms in 168 patients. *Ann Surg* 2001;234:454-63.
- Abath C, Andrade G, Cavalcanti D, Brito N, Marques R. Complex renal artery aneurysms: liquids or coils? *Tech Vasc Interv Radiol* 2007;10:299-307.
- González J, Esteban M, Andrés G, Linares E, Martínez-Salamanca JI. Renal artery aneurysms. *Curr Urol Rep* 2014;15:376.
- Coleman DM, Stanley JC. Renal artery aneurysms. *J Vasc Surg* 2015;62:779-85.
- Buck DB, Curran T, McCallum JC, Darling J, Mamtani R, Van Herwaarden J, et al. Management and outcomes of isolated renal artery aneurysms in the endovascular era. *J Vasc Surg* 2016;63:77-81.
- Bastounis E, Pikoulis E, Georgopoulos S, Alexiou D, Leppaniemi A, Boulafendis D. Surgery for renal artery aneurysms: a combined series of two large centers. *Eur Urol* 1998;33:22-7.
- Moll FL, Powell JT, Fraedrich G, Verzini F, Haulon S, Waltham M, et al. Management of abdominal aortic aneurysms clinical practice guidelines of the European Society for Vascular Surgery. *Eur J Vasc Endovasc Surg* 2011;41(Suppl 1):S1-58.
- Wang Y, Song S, Zhou G, Liu D, Xia X, Liang B, et al. Strategy of endovascular treatment for renal artery aneurysms. *Clin Radiol* 2018;73:414.e1-5.
- Kwon SC, Shin YS, Kim HS, Kim SY. A double catheter technique for elongated middle cerebral artery bifurcation aneurysm: a case report. *Interv Neuroradiol* 2006;12:41-4.
- Das JP, Asadi H, Kok HK, Phelan E, O'Hare A, Lee MJ. Balloon-assisted coil embolization (BACE) of a wide-necked renal artery aneurysm using the intracranial sceptor C compliant occlusion balloon catheter. *CVIR Endovasc* 2018;12:1-4.
- Eldem G, Erdoğan E, Peynircioğlu B, Arat A, Balkancı F. Endovascular treatment of true renal artery aneurysms: a single center experience. *Diagn Interv Radiol* 2019;25:62-70.
- Goto T, Shimohira M, Ohta K, Suzuki K, Sawada Y, Shibamoto Y. Combination of the double-microcatheter technique and triaxial system in coil packing for visceral and renal artery aneurysms. *Acta Radiol* 2019;60:1057-62.
- Adrahtas D, Jasinski P, Koullias G, Fiorella D, Tassiopoulos AK. Endovascular treatment of a complex renal artery aneurysm using coils and the pipeline embolization device in a patient with a solitary kidney. *Ann Vasc Surg* 2016;36:291.e5-9.
- Abreu AL, Medina LG, Chopra S, Gill K, Cacciamani GE, Azhar RA, et al. Robotic renal artery aneurysm repair. *Eur Urol* 2020;78:87-96.

Submitted Oct 22, 2020; accepted Mar 22, 2021.