



Contents lists available at ScienceDirect

## International Journal of Surgery Case Reports

journal homepage: [www.casereports.com](http://www.casereports.com)

# Neuroendocrine tumor of the appendix inside an incarcerated Amyand's hernia



Khaled Y. Elbanna<sup>a</sup>, Hassan A. Alzahrani<sup>b,\*</sup>, Fahad Azzumeea<sup>a</sup>, Hyetham A. Alzamel<sup>c</sup>

<sup>a</sup> Medical Imaging Department, King Fahad National Guard Hospital, King Abdulaziz Medical City (KAMC), Riyadh 11426, Saudi Arabia

<sup>b</sup> Department of Surgery, Faculty of Medicine, King Khalid University (KKU), Abha 61421, Saudi Arabia

<sup>c</sup> Department of Surgery, King Fahad National Guard Hospital, King Abdulaziz Medical City (KAMC), Riyadh 11426, Saudi Arabia

## ARTICLE INFO

## Article history:

Received 22 April 2015

Received in revised form 29 July 2015

Accepted 30 July 2015

Available online 5 August 2015

## Keywords:

Neuroendocrine

Carcinoid

Amyand

Hernia

## ABSTRACT

Amyand's hernia is a rare type of hernia where the vermiform appendix is within an inguinal hernia sac. Tumors of the appendix are quite uncommon. The coincidence of an Amyand's hernia with neuroendocrine tumor of the appendix, as in our case, is even more rarely reported.

We report the case of an 81-year-old male who presented with an incarcerated right inguinal hernia. After resuscitation, the clinical diagnosis was confirmed by computed tomography. It showed an incarcerated right inguinal hernia which contained the distal ileum, cecum, thickened appendix, as well as a small amount of fluid. Subsequently, the patient was prepared for emergency surgery. During the operation, the hernia sac was found and opened. The appendix was swollen. Therefore, appendectomy was performed. The inguinal defect was repaired using the Modified Bassini Technique. The patient had an uneventful postoperative recovery and surprisingly the histopathology of the appendix revealed a 1.5 cm well-differentiated low grade neuroendocrine tumor (carcinoid) of the appendix tip.

An incidental finding of neuroendocrine tumor of the appendix in a patient with a hernia is extremely rare. A high index of suspicion is the key to diagnose such a coincidence in order to safely and optimally treat such a condition.

© 2015 The Authors. Published by Elsevier Ltd. on behalf of Surgical Associates Ltd. This is an open access article under the CC BY-NC-ND license (<http://creativecommons.org/licenses/by-nc-nd/4.0/>).

## 1. Background

An Amyand's hernia is a rare occurrence where the vermiform appendix is found within an inguinal hernia sac [1]. It was first described by a distinguished French surgeon, Claudius Amyand (1660–1740). Amyand's hernia is classically described as occurring in 1% of all inguinal hernias. Appendicitis in an Amyand's hernia accounts for 0.1% of all cases of appendicitis. Its clinical presentation is similar to that of an incarcerated hernia, and thus it is difficult to diagnose clinically. It can be diagnosed preoperatively using ultrasound and computed tomography. The appendix can remain within the hernia sac without symptoms throughout a patient's lifetime. It is possible that strangulation can occur at the neck of the hernia resulting in vascular obstruction, inflammation and even perforation of the appendix [2].

Neoplasms of the appendix are quite uncommon, accounting for only 0.4% of gastrointestinal tumors [3]. The occurrence of these two conditions together is even more rarely reported [4]. Here we present a case with the incidental finding of a neuroendocrine tumor of the appendix within an incarcerated Amyand's hernia.

## 2. Case report

An 81-year-old male presented to our emergency department complaining of painful right groin swelling for 12 h. He had a history of reducible right inguinal hernia for the previous 8 years. He complained that the pain was progressively worsening, but he denied any history of vomiting or constipation. The patient was known to have chronic obstructive pulmonary disease, Alzheimer disease and benign prostatic hyperplasia.

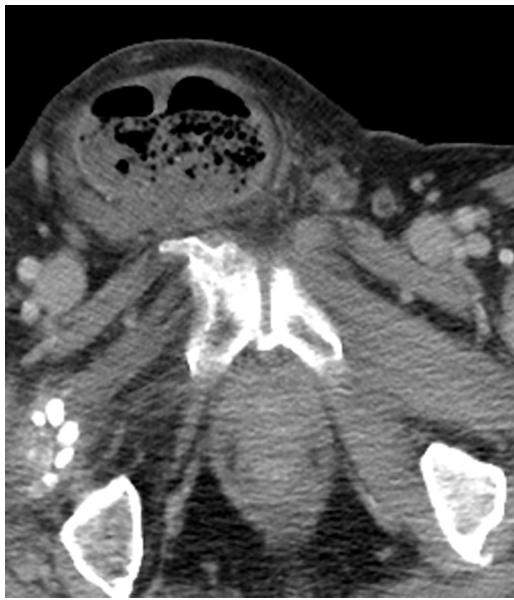On physical examination the patient was distressed with temperature of 36.5 °C, respiratory rate of 20/min, heart rate of 67/min and blood pressure of 84/59 mmHg. The abdominal examination revealed a 10 × 8 cm right inguinal swelling, which was tender and irreducible. The rest of the abdomen was soft. Digital rectal examination revealed an enlarged, firm prostate.

On laboratory workup, he was found to have WBC of 7.3/L, hemoglobin of 11.8 g/L, platelet count of 471 × 10<sup>9</sup>/L, Sodium 135 mmol/L, Potassium 5.1 mmol/L, and Creatinine 66 μmol/L.

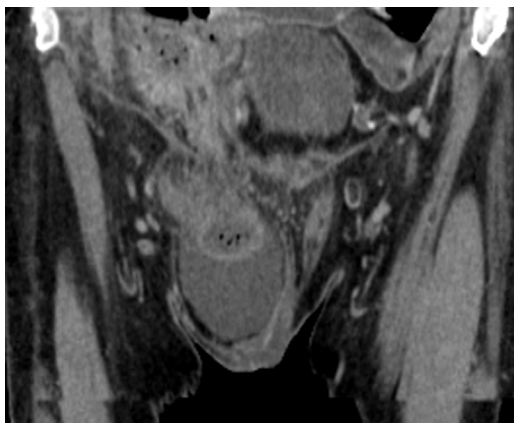
The patient had a rapid resuscitation with intravenous fluids and analgesia. Computed tomography of the abdomen and pelvis was done after only intravenous contrast injection as the patient couldn't tolerate oral contrast. The images demonstrated incarcerated right inguinal hernia containing the distal ileum, cecum, and appendix together with a small amount of fluid within the hernia

\* Corresponding author.

E-mail address: [hassanali304@hotmail.com](mailto:hassanali304@hotmail.com) (H.A. Alzahrani).



**Fig. 1.** Axial image; the right inguinal hernia sac containing cecum.

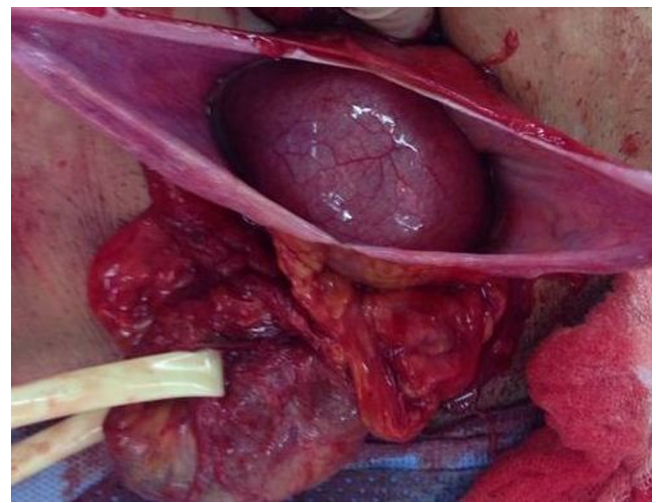


**Fig. 2.** Reconstructed coronal image showing the hernia.

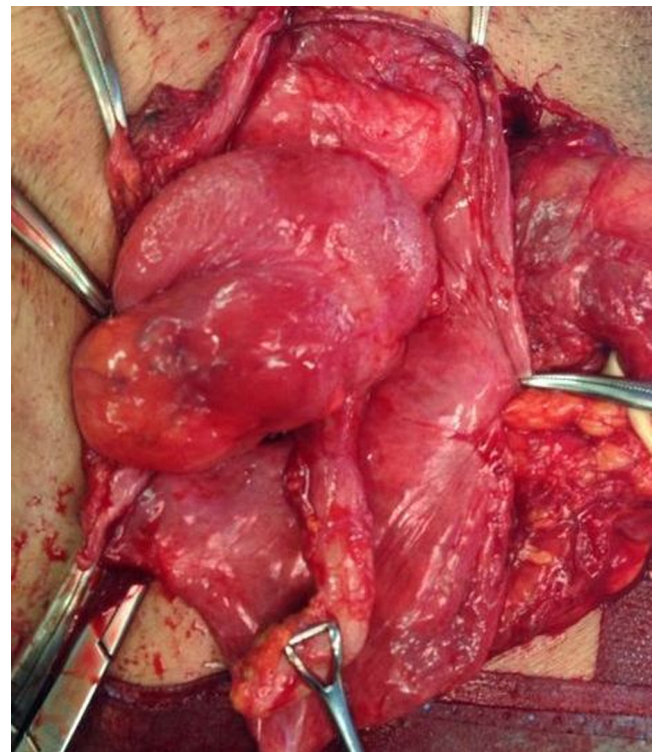
sac. The appendix was slightly edematous; however, no appendicular masses were identified and there were no signs of bowel obstruction or ischemia (Figs. 1 and 2). Our radiological diagnosis was an incarcerated Amyand's hernia.

The patient was taken to the operating room. An emergency right anterior inguinal exploration was performed and revealed an indirect inguinal hernia. The hernia sac contained cecum, appendix and a small amount of free fluid. There was no bowel ischemia or gangrene, however the appendix was inflamed (Figs. 3 and 4). Therefore, an appendectomy was done and the cecum was freed from adhesion to the sac and reduced into the abdominal cavity. The hernia sac was ligated and excised then the inguinal defect was repaired using the Modified Bassini Technique. The patient had an uneventful postoperative recovery and was discharged one week after surgery.

Histopathology revealed a 1.5 cm well-differentiated, low grade neuroendocrine tumor (carcinoid) of the appendix tip. It was invading the submucosa, muscularis propria and subserosa but not the visceral peritoneum or the mesoappendix. There was no lymphovascular invasion and resection margin was free from tumor.



**Fig. 3.** Intraoperative picture of the hernia sac and healthy cecum.



**Fig. 4.** Intraoperative picture of the appendix looking unhealthy.

### 3. Discussion

Inguinal hernia may contain the omentum or small bowel. Certain unusual contents may be encountered, such as the bladder, a Meckel's diverticulum (Littre's hernia) [5], or a portion of the circumference of the bowel (Richter's hernia) [6]. When an appendix was found in a hernia sac, it was named Amyand's hernia [1].

Classically, it accounts for 1% of all inguinal hernias or even less (between 0.4% and 0.6% according to two recent studies by Psarras et al., and Gurer et al.,) [7,8]. Amyand's hernia is, as expected, more common in male patients and presents as a bimodal age distribution in neonates and in patients above 70 years. Coexistence of Amyand's hernia with a benign or malignant condition has been described rarely in the literature [2].

According to a report published by the National Cancer Institute appendiceal neoplasms account for approximately 0.4% of gastrointestinal tumors [3]. The most common tumors of the appendix are neuroendocrine tumors (NETs). Appendiceal NETs make up to 20% of all NETs of the gastrointestinal tract. They usually present in the 3rd to 5th decade. Females are more frequently affected than males. Most NETs of the appendix are found incidentally in appendectomy specimens from patients with appendicitis [9]. The gold standard treatment is surgical treatment by resection of the whole appendix for carcinoids located around the tip. In cases where the tumor is larger than 2 cm or located at the base of the appendix, a wider resection has to be performed with right hemicolectomy [10] [11].

After reviewing the English literature, there is only one reported case of such a rare coincidence (by Wu, C. and Yu, C.). The case was diagnosed clinically as incarcerated inguinal hernia. Therefore, emergency hernioplasty was arranged without preoperative radiological investigations for the hernia. The histologic finding was unexpected, as in our case, and revealed adenocarcinoid tumor of the appendix. The tumor measured about 2.5 cm in length and about 1 cm in diameter with free resection margin at the base of the appendix [4].

Preoperative clinical diagnosis of Amyand's hernia is difficult without specific signs or symptoms. The most common presentation is irreducible painful hernia (83%) [12]. Using ultrasound and Computed tomography (CT) make preoperative diagnosis of Amyand's hernia feasible [2]. The ultrasound image is that of a blind-ended tubular structure with thickened wall in connection with the cecum within the hernia sac [13] [14]. CT allows direct visualization of the appendix inside the inguinal canal and even if this is not possible, location of the cecum in proximity to the hernia sac is indicative of Amyand's hernia [15] [16]. Amyand's hernia has also been diagnosed incidentally with barium enema [17].

Preoperative imaging allows some understanding of the situation of the appendix inside the hernia: fluid in the right scrotum, heterogeneous tissue edema on ultrasound, and gas on CT are probably indicative of perforation. Use of these modalities has allowed a satisfactory percentage of preoperative diagnosis. However, the preoperative imaging does not change the surgical management of Amyand's hernia [2].

The surgical management of Amyand's hernia is based on the Losanoff and Basson classification [18]. A type 1 Amyand hernia has a normal appendix. A hernia reduction and mesh repair without appendectomy is done. For type 2 with acute appendicitis but no abdominal sepsis, an appendectomy is performed through the hernia and also a primary repair with no mesh. Type 3 with acute appendicitis and abdominal wall or peritoneal sepsis requires a laparotomy, appendectomy, and primary repair of hernia. For type 4, where acute appendicitis is associated with a related or unrelated pathology, the management is the same as for types 2 and 3 hernias but the second pathology should be investigated and treated appropriately.

Today prosthetic repairs are accepted to be superior to “non-mesh” suture repairs. A recent meta-analysis revealed that the Shouldice herniorrhaphy is the best non-mesh technique in terms of recurrence, though it is more time consuming and needs a slightly longer postoperative hospital stay. Nevertheless, the use of mesh is associated with a lower rate of recurrence [19].

The use of mesh in emergency repair of complicated hernias is debatable. Recent evidences is in favor of mesh use in cases with incarceration. However, prosthetic repair creates a risk for surgical site infection in cases where a gangrenous intestine is met and a resection-anastomosis is required [20]. The biologic meshes may gain importance in the future because they may be used in contaminated areas. However, they are extremely expensive which is the main factor limiting their use [21].

#### 4. Conclusion

The incidental finding of an appendiceal neuroendocrine tumor in a patient with Amyand's hernia is extremely rare, High index of suspicion is the key to diagnose such a coincidence, in order to safely and optimally treat such a condition.

#### Conflict of interest

The authors declare that there is no conflict of interest regarding the publication of this paper.

#### Sources of funding

The source of fund is self-funded by the authors.

#### Ethical approval

This paper was ethically approved by the IRB of the King Abdulaziz Medical City.

#### Consent

The patient was appropriately consented and agreed to publication of this paper.

#### Author contribution

1. Khaled Y. Elbanna – Contributed in data collection and writing the paper.
2. Fahad Azzumeea – Contributed in data interpretation.
3. Hyetham A. Alzamel – Contributed in study concept.
4. Hassan A. Alzahrani – Contributed in data collection and writing the paper.

#### Guarantor

Hassan A. Alzahrani: Assistant Professor of Surgery King Khalid University, P.O. Box 641, Abha 61421, Kingdom of Saudi Arabia.

#### Acknowledgement

The authors would like to thank all the colleagues who contributed to management of this patient. We appreciate Dr. John Patrick O'Brien for his contribution.

#### References

- [1] C. Amyand, Of an inguinal rupture, with a pin in the appendix caeci, Incrusted with stone; and some observations on wounds in the guts, *Philos. Trans. R. Soc. Lond.* 39 (1736) 329–336.
- [2] A. Michalinos, D. Moris, S. Vernadakis, Amyand's hernia: a review, *Am. J. Surg.* 207 (2014) 989–995.
- [3] S.J. Connor, G.B. Hanna, F.A. Frizelle, Retrospective clinicopathologic analysis of appendiceal tumors from 7970 appendectomies, *Dis. Colon Rectum* 41 (1) (1998) 75–80.
- [4] C. Wu, C. Yu, Amyand's hernia with adenocarcinoid tumor, *Hernia J. Hernias Abdom. Wall Surg.* 14 (2010) 423–425.
- [5] A. Littre, Observation sur une nouvelle espèce de hernie, *Mémoires de mathématique et de physique de l'Académie royale des sciences* 3502 (1700) 300–311.
- [6] W.A. Tito, W.C. Allen, Richter and Littre hernia, in: J.B. Nyhus, R.E. Condon (Eds.), *Hernia*, 3rd edn., Lippincott, Philadelphia, 1989, pp. 305–310.
- [7] K. Psarras, M. Lalountas, M. Baltatzis, et al., Amyand's herniada vermiform appendix presenting in an inguinal hernia: a case series, *J. Med. Case Rep.* 5 (2011) 463.
- [8] A. Gurer, M. Ozdogan, N. Ozlem, A. Yildirim, H. Kulacoglu, R. Aydin, Uncommon content in groin hernia sac, *Hernia* (2005) 1–4.
- [9] G. Kloppel, M. Anlauf, Epidemiology, tumour biology and histopathological classification of neuroendocrine tumours of the gastrointestinal tract, *Best Pract. Res. Clin. Gastroenterol.* 19 (4) (2005) 507–517.

- [10] S.N. Pinchot, K. Holen, R.S. Sippel, H. Chen, Carcinoid tumors, *Oncologist* 13 (2008) 1255–1269.
- [11] L. Ellis, M.J. Shale, M.P. Coleman, Carcinoid tumors of the gastrointestinal tract: trends in incidence in England since 1971, *Am. J. Gastroenterol.* 105 (2010) 2563–2569.
- [12] G. Ranganathan, R. Kouchupapy, S. Dias, An approach to the management of Amyand's hernia and presentation of an interesting case report, *Hernia* 15 (2011) 79–82.
- [13] R. Singal, A. Mittal, A. Gupta, et al., An incarcerated appendix: report of three cases and a review of the literature, *Hernia J. Hernia Abdom. Wall Surg.* 16 (2012) 91–97.
- [14] A. Celik, O. Ergün, S.S. Ozbek, et al., Sliding appendiceal inguinal hernia: preoperative sonographic diagnosis, *J. Clin. Ultrasound* 31 (2003) 156–158.
- [15] L. Ash, S. Hatem, G.A.M. Ramirez, et al., Amyand's hernia: a case report of prospective ct diagnosis in the emergency department, *Emerg. Radiol.* 11 (2005) 231–232.
- [16] Z.V. Maizlin, A.C. Mason, C. Brown, et al., CT findings of normal and inflamed appendix in groin hernia, *Emerg. Radiol.* 14 (2007) 97–100.
- [17] K.S. Hindle, A. Huang, Soft-tissue images. Appendiceal inguinal hernia, *Can. J. Surg. J. Can. Chir.* 45 (2002) 277.
- [18] J.E. Losanoff, M.D. Basson, Amyand hernia: a classification to improve management, *Hernia* 12 (3) (2008) 325–326.
- [19] B. Amato, L. Moja, S. Panico, G. Persico, C. Rispoli, N. Rocco, et al., Shouldice technique versus other open techniques for inguinal hernia repair, *Cochrane Database Syst. Rev.* 4 (2009) CD001543.
- [20] M.M. Elsebae, M. Nasr, M. Said, Tension-free repair versus Bassini technique for strangulated inguinal hernia: a controlled randomized study, *Int. J. Surg.* 6 (2008) 302–305.
- [21] M.E. Franklin Jr, J.J. Gonzalez Jr, J.L. Glass, Use of porcine small intestinal submucosa as a prosthetic device for laparoscopic repair of hernias in contaminated fields: 2-year follow-up, *Hernia* 8 (2004) 186–189.

#### Open Access

This article is published Open Access at [sciendoirect.com](http://sciendoirect.com). It is distributed under the [IJSCR Supplemental terms and conditions](#), which permits unrestricted non commercial use, distribution, and reproduction in any medium, provided the original authors and source are credited.