



Since January 2020 Elsevier has created a COVID-19 resource centre with free information in English and Mandarin on the novel coronavirus COVID-19. The COVID-19 resource centre is hosted on Elsevier Connect, the company's public news and information website.

Elsevier hereby grants permission to make all its COVID-19-related research that is available on the COVID-19 resource centre - including this research content - immediately available in PubMed Central and other publicly funded repositories, such as the WHO COVID database with rights for unrestricted research re-use and analyses in any form or by any means with acknowledgement of the original source. These permissions are granted for free by Elsevier for as long as the COVID-19 resource centre remains active.

## Methotrexate pneumonitis in a patient with Crohn's disease, during the COVID pandemic: An unusual clinical case and review of the literature<sup>☆</sup>



### Neumonitis por metotrexato en paciente con enfermedad de Crohn, durante la pandemia COVID: un caso clínico inusual y revisión de la literatura

We present the case of a 60-year-old woman with a history of Crohn's disease (A2L3B2) and rheumatoid arthritis, for which she had been started on treatment with methotrexate (MTX) three months earlier. She came to the A&E department with spiking fever of up to 38 °C, dry cough and dyspnoea on exertion that progressively increased until she was at rest, with baseline oxygen saturation of 88%. On auscultation of the lungs, dry crackles were heard in both lung bases. Blood tests showed elevation of inflammatory markers, with C-reactive protein (CRP) reading of 10 mg/dl and leucocytosis with neutrophilia.

A chest X-ray showed no abnormalities, but chest computed tomography (CT) revealed ground-glass opacities in both lungs.

Pneumonia associated with active COVID-19 infection was ruled out after three negative PCR tests, although the serology (ELISA) was compatible with past infection (positive IgG antibodies). The patient had shown symptoms suggestive of COVID at the beginning of the lockdown during the pandemic three months before her admission, which were not investigated at the time. Spirometry was requested, only showing a moderate decrease in lung diffusion capacity. Finally, bronchoscopy with bronchoalveolar lavage (BAL) showed an increase in lymphocyte cellularity (30%). As MTX pneumonitis was suspected, the MTX was withdrawn and treatment started with methylprednisolone 60 mg/24h, with clear clinical improvement, no fever and gradual improvement in the patient's dyspnoea, supporting the diagnosis of MTX-induced hypersensitivity pneumonitis.

MTX is an effective immunosuppressive agent in both induction and maintenance of remission in Crohn's disease and rheumatoid arthritis. Although it has a high incidence of adverse effects (in up to 50% of patients), commonly in the skin, gastrointestinal tract or central nervous system, most are mild. However some, like pneumonitis, despite being very rare, can be serious.

Although MTX-induced pulmonary toxicity is unpredictable, various risk factors have been identified, including advanced age, diabetes, hypoalbuminaemia, previous lung disease, altered respiratory function tests prior to treatment, and previous kidney or liver damage.<sup>1</sup> The mechanisms by which lung injury occurs are unknown, but the pathogenesis is probably multifactorial, including a hypersensitivity reaction, a direct toxic effect, and impaired host resistance to acquired or latent viral infection. There

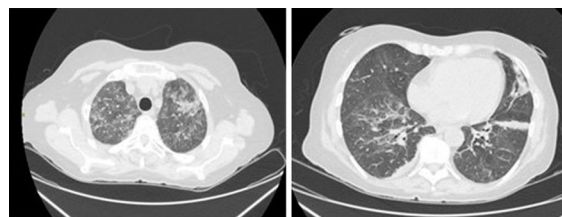


Figure 1 (A) Bilateral ground-glass opacities in the upper lobes of both lungs. (B) Subpleural consolidation in both lower lobes and lingula with a certain collapse component and the presence of bronchiectasis.

does not seem to be any association with the cumulative dose, the route used or the posology (Fig. 1).

In most patients, pulmonary toxicity develops within the first year (most often in the first months) and can present in an acute, subacute or chronic form, the subacute being the most common. Patients typically develop a non-productive cough, dyspnoea, fever and general malaise.<sup>2</sup> Findings on physical examination include tachypnoea, cyanosis and crackles on auscultation. The diagnosis is made from clinical history and suggestive laboratory and radiological results, and after ruling out infections with a similar radiological pattern including, particularly at the moment, the COVID-19 virus. Chest CT may show ground-glass opacities, consolidation, centrilobular lung nodules or traction bronchiectasis. Bronchoscopy with BAL usually detects the presence of lymphocytes and/or eosinophils and an increase in the CD4/CD8 ratio.<sup>3</sup> Although rarely necessary, lung biopsy typically shows alveolitis with epithelial cell hyperplasia and, possibly, small granulomas and eosinophilic infiltration.<sup>1</sup> Treatment of pneumonitis caused by MTX consists of its definitive withdrawal and the use of oral or intravenous corticosteroids, which should be started after ruling out an infectious cause. However, there are no clear guidelines as to the optimal dose or duration of steroid therapy. Clinical improvement after discontinuation of MTX and/or response to corticosteroid treatment help confirm the diagnosis. The respiratory prognosis is generally favourable, with complete radiological and functional recovery in most cases. However, progression to pulmonary fibrosis occurs in 10% of patients and the approximate mortality rate is 1%.<sup>4</sup>

## References

1. Golpe R, Suárez-Valor M, Castro-Añón O. Methotrexate pneumonitis in Crohn's disease. *Arch Bronconeumol*. 2018;54:528–41.
2. Margagnoni G, Papi V, Aratari A, Triolo L, Papi C. Methotrexate-induced pneumonitis in a patient with Crohn's disease. *J Crohn's Colitis*. 2010;4:211–4.
3. Trivedi I, Raj R, Hanauer S. Hyperacute methotrexate pneumonitis in a patient with Crohn's disease. *Clin Gastroenterol Hepatol*. 2016;14:A29–30.
4. D'Andrea N, Triolo L, Margagnoni G, Aratari A, Sanguinetti CM. Methotrexate-induced pneumonitis in Crohn's disease: case report and review of the literature. *Multidiscip Respir Med*. 2010;5:312–9.

<sup>☆</sup> Please cite this article as: de los Mozos Ruano A, Casas Deza D, Calvo Galindo R, Solana Hidalgo MP, Aguirre Portu N, Aranda Alonso Á, et al. Neumonitis por metotrexato en paciente con enfermedad de Crohn, durante la pandemia COVID: un caso clínico inusual y revisión de la literatura. *Gastroenterol Hepatol*. 2021;44:302–303.

Andrea de los Mozos Ruano<sup>a,\*</sup>, Diego Casas Deza<sup>b</sup>, Roberto Calvo Galindo<sup>a</sup>, María Patricia Solana Hidalgo<sup>a</sup>, Nerea Aguirre Portu<sup>a</sup>, Ángel Aranda Alonso<sup>a</sup>, Erardo Ernesto Meriño Ibarra<sup>c</sup>, Santiago García López<sup>d</sup>

<sup>a</sup> *Servicio de Medicina Interna, Hospital Universitario Miguel Servet, Zaragoza, Spain*

<sup>b</sup> *Servicio de Aparato Digestivo, Hospital Universitario Miguel Servet, Grupo de Investigación de Biología del Tejido Adiposo y Complicaciones Metabólicas de la Obesidad (ADIPOFAT), Instituto de Investigación Sanitaria (IIS), Zaragoza, Spain*

<sup>c</sup> *Servicio de Reumatología, Hospital Universitario Miguel Servet, Zaragoza, Spain*

<sup>d</sup> *Servicio de Aparato Digestivo, Hospital Universitario Miguel Servet, Instituto de Investigación Sanitaria (IIS), Zaragoza, Spain*

\* Corresponding author.

E-mail address: [andri.9495@hotmail.com](mailto:andri.9495@hotmail.com)

(A. de los Mozos Ruano).

2444-3824/ © 2020 Elsevier España, S.L.U. All rights reserved.