

Contents lists available at [ScienceDirect](http://www.sciencedirect.com)

International Journal of Surgery Case Reports

journal homepage: www.casereports.com

Penetrated sigmoid colon by air gun pellet could be life threatening: A case report



Avdyll S. Krasniqi^{a,b,*}, Astrit R. Hamza^{a,b}, Valon A. Zejnullahu^b, Fatos E. Sada^{a,c},
Besnik X. Bicaj^{a,b}

^a Faculty of Medicine, University of Prishtina, 10000 Prishtina, Kosovo

^b Department of Abdominal Surgery, University Clinical Centre of Kosova, 10000 Prishtina, Kosovo

^c Department of Anesthesiology and Reanimation, University Clinical Centre of Kosova, 10000 Prishtina, Kosovo

ARTICLE INFO

Article history:

Received 22 August 2014

Received in revised form 7 November 2014

Accepted 12 November 2014

Available online 18 November 2014

Keywords:

Air gun pellet

Sigmoid colon perforation

Peritonitis

ABSTRACT

INTRODUCTION: Air and paintball guns have been in existence for over 400 year. Although serious injury or death can result from the use of such guns, previous literature has not mentioned the issue of the penetration of the sigmoid colon by an air gun pellet.

PRESENTATION OF CASE: We report a rare case of a 44-year-old Caucasian woman referred to abdominal surgery after an accidental small wound had occurred in the lower left abdominal quadrant that was caused by an air gun pellet. The blood and biochemical analyses were normal but the CT scan revealed the presence of a foreign body – an air gun pellet in the left iliac region of the abdomen. Clinically, during the initial 24 h significant changes were not noticed. After 42 h, however, pain and local tenderness in the lower left abdominal quadrant was expressed. A laparotomy revealed a retained pellet in the wall of the sigmoid colon and a small leak with colonic content with consecutive local peritonitis also occurred. The foreign body was removed and the opening edges in the colon were excised and closed with the primary suture.

DISCUSSION: The hollow organs of the digestive tract, albeit very rarely penetrated by an air gun pellet, do not typically show all signs of an acute abdomen in the early posttraumatic phase. Such injuries can lead to a pronounced infection, which may cause septic shock if not appropriately treated.

CONCLUSION: For correct diagnosis, a careful approach and several daily clinical observations are required.

© 2014 The Authors. Published by Elsevier Ltd. on behalf of Surgical Associates Ltd. This is an open access article under the CC BY-NC-ND license (<http://creativecommons.org/licenses/by-nc-nd/3.0/>).

1. Background

Air powered weapons were first produced in the middle of the 16th century, and thus have been in existence for over 400 years.¹ Air and paintball guns are popular and more than 3.2 million air guns are purchased in the United States annually,² and over 10 million Americans participate in paintball activities each year.³ Serious injury or death, however, can result from the use of these guns.⁴ Non-powder guns employ the power of compressed air to launch a projectile. Non-powder guns can be classified by the type of projectile they fire, the propulsion mechanism, as well as the type of barrel. The type of projectile can be lead, brass, steel, copper, or, most recently, a paintball⁴. Numerous reports of air gun injuries and deaths have been recounted in the medical literature. Overall, 50% of air gun injuries occur in children 5–14 years old, and 80% occur in young people between 5 and 24 years of age,⁴ where

the majority of the victims are male.^{5,6} In our case, however, an adult woman was accidentally injured with air gun pellet in her abdomen.

According to the literature, the approach taken for abdominal injuries from small rifles has been changed.⁷ In the past, any patient with suspected peritoneal violation was taken to laparotomy, but for properly selected patients nonoperative approaches are gaining favor.^{8–15}

2. Case report

A 44-year-old woman was admitted to the Emergency Department of The University Clinical Center of Kosovo because of a sudden piercing pain in the left lower quadrant during a hike in the mountains with her husband. She denied hearing any gunfire sounds and intentional injury. During the admissions process the patient did not exhibit any evident abnormalities in regard to her vital signs. Although a physical examination of the abdomen revealed a small entry wound in the left lower quadrant (LLQ), an exit wound was not detected. The entry wound was localized in the left lower quadrant of the abdomen 6 cm from the umbilicus.

* Corresponding author at: Faculty of Medicine, University of Prishtina, 10000 Prishtina, Kosovo. Tel.: +377 44507776.

E-mail address: avdyll.krasniqi@yahoo.com (A.S. Krasniqi).

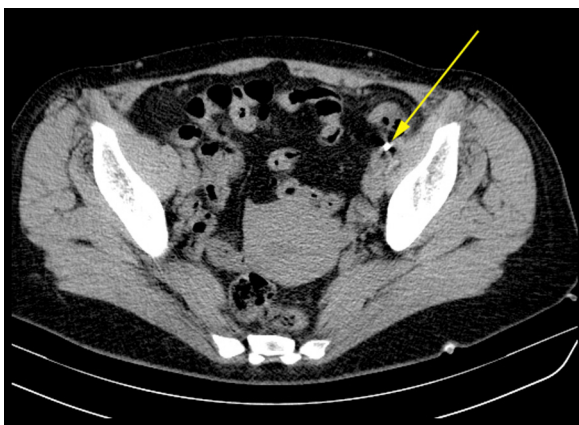

Fig. 1. Computed tomography of the lower abdomen showing an air gun pellet in the left iliac region.

Computerized tomography of the abdomen described the presence of a metallic foreign body in the left iliac region. The bone structures were not affected and free liquid in the peritoneal space was not present (Fig. 1). The laboratory tests results were found to be normal. According to her report, the physical examination of her abdomen, and the computerized tomography (Fig. 1), it was thought that the her pain might have been caused by an accidental air gun pellet. No information was provided regarding the type of used gun.

The patient was admitted to the abdominal surgery ward for further examination and clinical observation. After 42 h, abdominal pain, tenderness, and evident signs of local peritoneal irritation were revealed.

The patient was admitted to the abdominal surgery ward for further examination and clinical observation. However, after 42 h, abdominal pain, tenderness, and evident signs of local peritoneal irritation were revealed. A midline lower laparotomy was

performed. The exploration of the abdominal cavity showed that the pellet had penetrated the abdominal wall, created a small hole (1.5 cm in size) in the parietal peritoneum of the hypo gastric region, caused a small rupture in the left ovary as well, and finally ceased in the anterior wall of the sigmoid colon (Fig. 2). The pellet had impacted the wall, and it was surrounded by a small amount of colonic content leakage into the peritoneal cavity, thus causing a localized peritonitis. The local surgical treatment consisted of the removal of the pellet, an excision of the perforation, a primary closure with PDS 3.0 and peritoneal lavage with saline (Fig. 3). The extracted pellet confirmed the etiology of the injury (Fig. 4). The postoperative period was without complications and the patient left the hospital six days after the operation.

3. Discussion

Air guns, both modern and traditional models, are powerful weapons that are capable of causing serious or even life-threatening injuries, albeit modern models tend to be low-powered due to safety concerns and legal restrictions.¹⁶ Emergency health care providers often underestimate the potential danger of such pellet and BB guns in regard to inflicting life-threatening penetrating injuries.¹⁷ More than 30,000 air gun injuries occur annually in the United States. While in the past these injuries were usually not serious unless an eye was injured, technological advances have resulted in the creation of air guns with the capability to maim and kill.¹⁸ Penetrating abdominal injuries involving hollow viscera or major blood vessels need prompt exploration and repair,¹⁹ despite the fact that there is a reported case of a patient who experienced an air gun pellet injury to the right colon which was treated conservatively, and the pellet was passed per rectum 12 h after the injury.²⁰ In the literature, we could not find the evidence of colon perforation caused by air gun pellet that was treated surgically. The colon is the second most commonly injured organ in penetrating trauma due to gunshot wounds. Colon injuries occur less frequently than small bowel injuries, probably due to several factors,

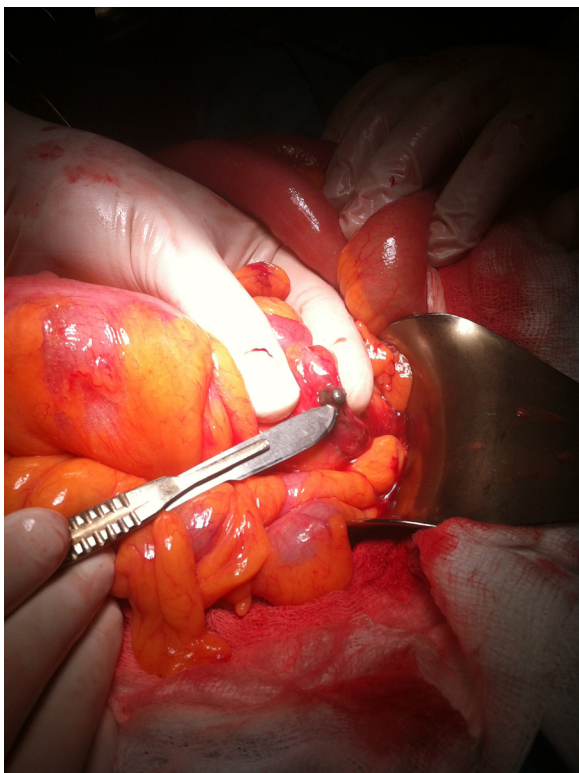


Fig. 2. The air gun pellet ceased in the anterior wall of the sigmoid colon.

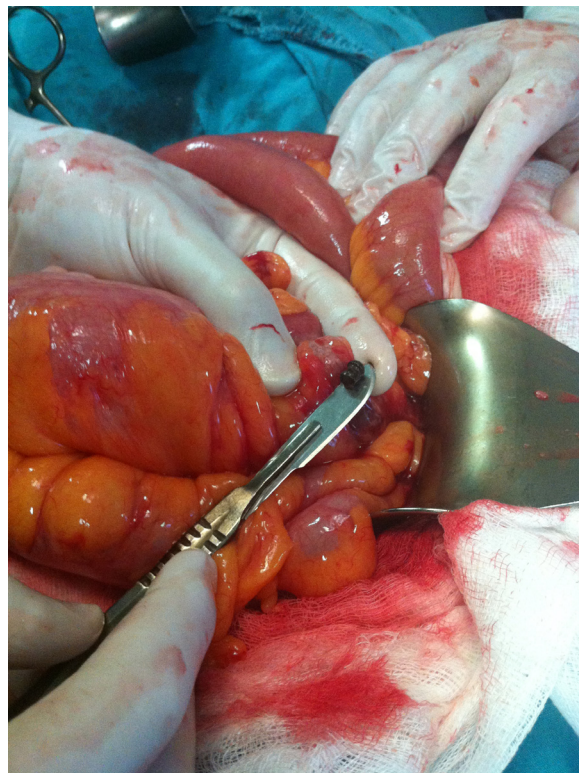


Fig. 3. The sigmoid colon perforation after the air gun pellet extraction.



Fig. 4. The extracted air gun pellet.

including location and lack of redundancy, which prevents the formation of closed loops. The management of gunshot injuries to the abdomen has remained unchanged for many decades, with mandatory laparotomy being the standard practice. However, this practice has been challenged and some centers with extensive experience with penetrating injuries employ selective nonoperative management. Approximately 30% of abdominal gunshot wounds to the anterior abdomen and about 67% of gunshot wounds to the back can safely be managed nonoperatively.²¹ Como⁷ concluded that a routine laparotomy after an abdominal gun wound is indicate in cases with hemodynamic instability, peritonitis, or evisceration.

The staff of our hospital has considerable experience with gun related injuries and usually the approach taken for abdominal injuries from small rifles is initially nonoperative. Urgent surgery is undertaken in cases involving peritoneal irritation, meanwhile, cases with retained rifle bullets without peritoneal irritation will be prepared for elective surgery.

In conclusion, the hollow organs of the digestive tract, albeit very rarely can be penetrated by an air gun pellet, do not typically show all signs of acute abdomen in the early posttraumatic phase. Such injuries can lead to a pronounced infection, which may cause septic shock if not appropriately treated. Therefore, a careful approach and, if abdominal urgent exploration is not indicated, several daily clinical observations are required.

Conflicts of interest

The authors declare that they have no conflicts of interest.

Funding

No funding for this research.

Open Access

This article is published Open Access at sciedirect.com. It is distributed under the [IJSCR Supplemental terms and conditions](#), which permits unrestricted non commercial use, distribution, and reproduction in any medium, provided the original authors and source are credited.

Ethical approval

Approved by the Ethics Committee of Faculty of Medicine, University of Prishtina, Kenova. Written informed consent was obtained from the patient for the publication of this case report and any accompanying images. A copy of the written consent is available for review by the Editor-in-Chief of this journal.

Author contributions

AK contributed substantially to the conception and design of the manuscript. He drafted the article, analyzed data, and revised them critically. AH assisted in the conception of the manuscript and contributed to the data acquisition and interpretation. VZ helped with the composition of the article and also contributed to its design. FS assisted with improving the quality of the discussion section in that he critically revised that component. BB helped to draft the manuscript and provided assistance with conceiving and designing the manuscript. All authors approved the final version of the manuscript.

References

- Milroy CM, Clark JC, Carter N, Rutty G, Rooney N. Air weapon fatalities. *J Clin Pathol* 1998;**51**:525.
- Nguyen M, Anest J, Mercy J, Ryan G, Fingerhut L. Trends in BB/pellet gun injuries in children and teenagers in the United States 1985–99. *Inj Prev* 2002;**8**:185.
- Alliman K, Smiddy W, Banta J, Qureshi Y, Miller D, Schiffman J. Ocular trauma and visual outcome secondary to paintball projectiles. *Am J Ophthalmol* 2009;**147**(2):239.
- Laraque D. Injury risk of nonpowder guns. *Pediatrics* 2004;**5**:114.
- Christoffel KK, Tanz R, Sagerman S. Childhood injuries caused by nonpowder firearms. *Am J Dis Child* 1984;**138**:557.
- Bowen DI, Magauran DM. Ocular injuries by air gun pellets: an analysis of 105 cases. *BMJ* 1973;**1**:333.
- Como JJ, Bokhari F, Chiu WC, Duane TM, Holevar MR, Tandoh MA, et al. Practice management guidelines for selective nonoperative management of penetrating abdominal trauma. *J Trauma* 2010;**68**(3):721.
- Pryor JP, Reilly PM, Dabrowski GP, Grossman MD, Schwab CW. Nonoperative management of abdominal gunshot wounds. *Ann Emerg Med* 2004;**43**(3):344.
- Demetriades D, Hadjizacharia P, Constantinou C, Brown C, Inaba K, Rhee P, et al. *Ann Surg* 2006;**244**(4):620.
- Ahmed N, Whelan J, Brownlee J, Chari V, Chung R. The contribution of laparoscopy in evaluation of penetrating abdominal wounds. *J Am Coll Surg* 2005;**201**(2):213.
- Velmahos GC, Demetriades D, Toutouzias KG, Sarkisyan G, Chan LS, Ishak R, et al. Selective nonoperative management in 1856 patients with abdominal gunshot wounds: should routine laparotomy still be the standard of care? *Ann Surg* 2001;**234**(3):395.
- Leppaneim AK, Voutilainen PE, Haapiainen RK. Indications for early mandatory laparotomy in abdominal stab wounds. *Br J Surg* 1999;**86**(1):76.
- Nagy K, Roberts R, Joseph K, An G, Barret J. Evisceration after abdominal stab wounds: is laparotomy required? *J Trauma* 1999;**47**(4):622.
- Arikan S, Kokacusak A, Yucel AF, Adas G. A prospective comparison of the selective observation and routine exploration methods for penetrating abdominal stab wounds with organ or omentum evisceration. *J Trauma* 2005;**58**(3):526.
- Alzamel HA, Cohn SM. When is it safe to discharge asymptomatic patients with abdominal stab wounds? *J Trauma* 2005;**58**(3):523.
- Hosseini M, Keramati RM, Heidari A, Olad-Ghobad MK. Entrapment of an air gun pellet between the thyroid cartilage and the lining mucosa in a patient with a penetrating neck injury: a case report. *J Med Case Rep* 2012;**6**:184.
- DiGiulio GA, Kulick RM, Garcia VF. Penetrating abdominal air gun injuries: pitfalls in recognition and management. *Ann Emerg Med* 1995;**26**(2):224.
- Naude GP, Bongard FS. From deadly weapon to toy and back again: the danger of air rifles. *J Trauma* 1996;**41**(6):1039.
- Ceylan H, McGowan A, Stringer MD. Air weapon injuries: a serious and persistent problem. *Arch Dis Child* 2002;**86**:234.
- Oshodi TO, Bowrey D. Uncomplicated penetrating colonic injury. *J Accid Emerg Med* 1996;**13**:296.
- Demetriades D, Hadjizacharia P, Constantinou C, Brown C, Inaba K, Rhee P, et al. Selective nonoperative management of penetrating abdominal solid organ injuries. *Ann Surg* 2006;**244**(4):620.