



Case report

Surgical management of erosive adenomatosis of the nipple: A case report

Freddy Houéhanou Rodrigue Gnangnon^{a,*}, Yacoubou Imorou Souaibou^a,
 Dansou Gaspard Gbessi^a, Tiani Marie Gaston Agbo^a, Francis Moïse Dossou^b,
 Delphin Kuassi Méhinto^a

^a Department of Visceral Surgery, National Teaching Hospital-Hubert Koutoukou Maga, Cotonou, Benin

^b Department of General Surgery, University Regional Hospital of Ouémé-Plateau, Porto-Novo, Benin

ARTICLE INFO

Keywords:

Erosive adenomatosis
 Breast neoplasm
 Nipple
 Surgery
 Paget's disease
 Case report

ABSTRACT

Introduction and importance: Known as a very uncommon disease, erosive adenomatosis of the nipple is a benign neoplasm of the breast. However, its destructive process can have a considerably negative impact on patient's quality of life.

Case presentation: We report the case of a 45-year-old woman who presented at the visceral surgery department of the National Teaching Hospital of Cotonou-Benin (CNHU-HKM) for a burgeoning mass of the left nipple. She was diagnosed an erosive adenomatosis of the nipple and underwent a nipple resection with reconstruction.

Clinical discussion: Erosive adenomatosis is one differential diagnosis for lesion of the nipple. Clinically, it should be discussed with malignant nipple tumours including Paget's disease.

Conclusion: Surgery is the cornerstone of the treatment, and the prognosis is excellent.

1. Introduction

Erosive adenomatosis of the nipple (EAN), also known as florid papillomatosis of the nipple or papillary nipple adenoma, is a benign lesion arising from the lactiferous sinus of the nipple [1]. Historically, it seems that the first case was reported by Jones in 1955 [2]. EAN has an excellent prognosis after surgery, but it raises a problem of differential diagnosis with nipple malignant pathologies including Paget's disease [1,3]. We here report a case of EAN of the left breast surgically managed in a 45-year-old woman at the visceral surgery department of the National Teaching Hospital of Cotonou-Benin (CNHU-HKM). Our final objective is to recall the clinical and therapeutic aspects surrounding this rare breast disease. This case report has been reported in line with the SCARE Criteria [4].

2. Case presentation

A 45-year-old black woman presented, in April 2020, at the visceral surgery department of the National Teaching Hospital of Cotonou-Benin (CNHU HKM), with a 2-year history of a mass over the left nipple. The lesion had started as an area of erythema which gradually became burgeoning and finally invaded all the nipples. There was no family

history of breast cancer. She had no history of tobacco or drug consumption. Physical examination revealed a two-centimetre budding mass with soft consistency, painless extended to the left nipple (Fig. 1A). On examination, there was no breast lump or enlarged lymph nodes. Ultrasound scanning and mammography were negative. A biopsy was performed, and pathology concluded to an EAN with no sign of malignancy. In June 2020, she underwent a nipple resection with reconstruction by a consultant surgical oncologist and was discharged the same day (Fig. 1). The surgery, performed under local anaesthesia, was well tolerated with minimal blood loss. On final pathology report, margins were clear. The immediate post-operative course was uneventful and twelve months after surgery there is no evidence of recurrence (Fig. 2). The patient stated that she was satisfied with the aesthetic result.

3. Discussion

Erosive nipple adenomatosis is a benign condition rarely described in the literature [3]. Jones seems to be the first, in 1955, to describe the disease under the topic of "florid papillomatosis of the nipple ducts" [2]. Although benign, its destructive process and frequent recurrence can have a considerably negative impact on patient's quality of life [5];

* Corresponding author.

E-mail address: fredgnangn@yahoo.fr (F.H.R. Gnangnon).

<https://doi.org/10.1016/j.ijscr.2021.106234>

Received 13 June 2021; Received in revised form 17 July 2021; Accepted 20 July 2021

Available online 22 July 2021

2210-2612/© 2021 Published by Elsevier Ltd on behalf of IJS Publishing Group Ltd. This is an open access article under the CC BY-NC-ND license

(<http://creativecommons.org/licenses/by-nc-nd/4.0/>).

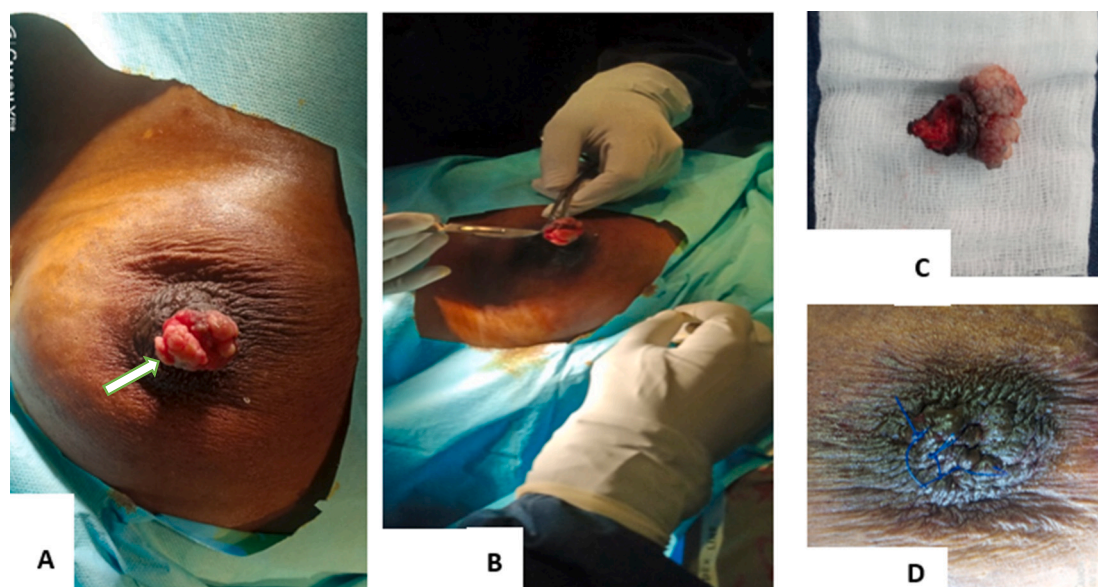


Fig. 1. Surgical management.

A: operative view; B: resection of the nipple, C: the resected specimen with macroscopic clear margins, D: reconstruction.

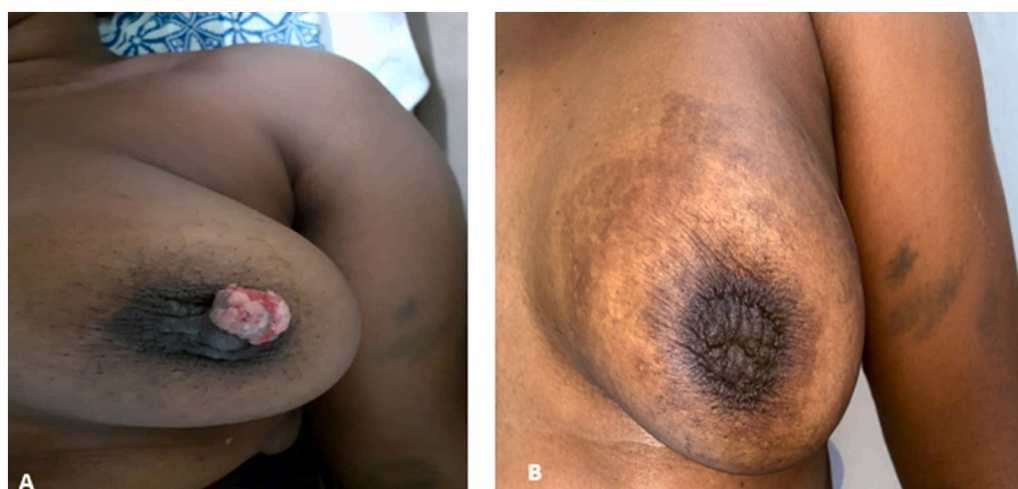

Fig. 2. Aesthetic outcome.

A: prior to surgery; B twelve months after surgery.

particularly in women of childbearing age who need to retain intact nipples. Fortunately, it is most often found in women during the fifth decade. However, a few cases have been described in children [3] and even in men [6]. Our patient was 45; and, to the best of our knowledge, this is one of the very few cases described in black women from sub-Saharan Africa. Localization on supernumerary breast is possible, although exceptional [7].

EAN is usually described as an erosive or fissured florid lesion of the nipple. It may be associated with nipple discharge. In our case, there was no history of nipple discharge. The diagnosis is usually made by pathology on biopsy specimens. The tumour typically appears as a glandular epithelial proliferation with a double cell layer eroding the epidermis, and a papillary protrusion that may fill the lumen. A dermal mononuclear or plasma cell infiltrate is often present around the proliferation [3]. The basement membrane is well individualised [8].

The differential diagnosis mainly arises in the clinic with Paget's disease of the nipple, which is a malignant and unfortunately more common disease [3]. Pathologically, EAN can be mistaken for a tubular carcinoma [7]. Other differential diagnoses such as contact dermatitis,

psoriasis and galactophoric ectasia should also be ruled out at initial evaluation [8]. The microscopic findings are the most valuable evidence in differentiating EAN from these other diseases [5]. Pathology is usually supplemented by immunohistochemistry although this is not mandatory for the diagnosis according to Matos et al. [3]. In immunohistochemistry, the anti-actin antibody shows consistent labelling of myoepithelial cells in the periphery of the ductal structures, allowing differential diagnosis with a well-differentiated carcinoma. In our case, Immunohistochemistry was not available.

Radiologically, EAN is usually not apparent due to its small size [8].

The main treatment for EAN is complete excisional surgery, with a good prognosis [1]. Some authors advocate tissue sparing techniques like Mohs micrographic surgery or cryosurgery particularly for women of childbearing age [1].

Regular follow-up is recommended, regardless of the therapeutic method, as EAN has a risk of reoccurring or progressing into a malignancy [1].

4. Conclusion

EAN is a rare benign nipple disease with an excellent prognosis that should be considered in any tumour of the nipple. Histological examination, with eventually immunohistochemistry, will rule out malignant pathologies of the nipple. Surgery remains the key treatment.

List of abbreviations

EAN Erosive adenomatosis of the nipple

Provenance and peer review

Not commissioned, externally peer-reviewed.

Sources of funding

This research did not receive any specific grant from funding agencies in the public, commercial, or not-for-profit sectors.

Ethical approval

Not applicable.

Consent for publication

Written informed consent was obtained from the patient for publication of this case report and accompanying images. A copy of the written consent is available for review by the Editor-in-Chief of this journal on request.

Authors' contributions

Study conception and design: FHR Gnangnon, Y Souaïbou Imorou, and TM Agbo.

Acquisition of data: FHR Gnangnon, Y Souaïbou Imorou and DG Gbessi.

Analysis and interpretation of data: FHR Gnangnon and DK Méhinto.

Drafting of manuscript: FHR Gnangnon and DG Gbessi.

Critical revision: FM Dossou and DK Méhinto.

Research registration

Not applicable.

Guarantor

Dr. Freddy Houéhanou Rodrigue Gnangnon.

Declaration of competing interest

The authors declare that they have no known competing financial interests or personal relationships that could have appeared to influence the work reported in this paper.

Acknowledgements

We would like to thank Dr Romulus Takin (pathology department, Hospital of Troyes, Troyes-France).

References

- [1] S. Ying, H. Fang, J. Qiao, Erosive adenomatosis of the nipple: a clinical diagnostic challenge, *Clin. Cosmet. Investig. Dermatol.* 13 (2020) 587–590.
- [2] Florid Papillomatosis of the Nipple Ducts. 5.
- [3] M. Matos, A. Maruani, L. Renjard, et al., Une lésion érosive du mamelon, *Ann. Dermatol. Vénéréol.* 133 (2006) 1015–1016.
- [4] R.A. Agha, T. Franchi, C. Sohrabi, et al., The SCARE 2020 guideline: updating consensus surgical Case REport (SCARE) guidelines, *Int. J. Surg.* 84 (2020) 226–230.
- [5] K.-N. Bae, K. Shin, W.-I. Kim, et al., Cryosurgery as a minimally invasive alternative treatment for a patient with erosive adenomatosis of the nipple, *Ann. Dermatol.* 33 (2021) 182.
- [6] H. Jia, X. Gu, G. Wang, et al., Erosive adenomatosis of the nipple in a man, *Indian J. Dermatol. Venereol. Leprol.* 81 (2015) 68.
- [7] Y. Shioi, S. Nakamura, S. Kawamura, et al., Nipple adenoma arising from axillary accessory breast: a case report, *Diagn. Pathol.* 7 (2012) 162.
- [8] S. Miladi, E. Bahloul, S. Charfi, et al., Adénomatose érosive du mamelon, *Ann. Dermatol. Vénéréol.* 147 (2020) 236–238.