

Surgery for Proliferative Diabetic Retinopathy: New Tips and Tricks

Patrick Oellers, MD; Tamer H. Mahmoud, MD, PhD

Duke Eye Center, Duke University School of Medicine, Durham, NC, USA

Abstract

Over the recent years, retina specialists have enjoyed significant improvements in the surgical management of proliferative diabetic retinopathy including improved preoperative planning, vitreoretinal instrumentation and new surgical maneuvers. In this review, we present new tips and tricks such as preoperative pharmacotherapy approaches including pegaptanib injection and biodegradable dexamethasone implantation, bimanual vitrectomy techniques and the concept of mixing small gauges as well as valved cannulas and intraoperative optical coherence tomography. With advanced surgical planning and sophisticated operative maneuvers tailored to the individual patient, excellent outcomes can be achieved even in severe cases of diabetic tractional detachment.

Keywords: Proliferative Diabetic Retinopathy; Tractional Retinal Detachment; Vitrectomy; Pegaptanib; Macugen; Dexamethasone; Ozurdex; 27 Gauge; Bimanual Surgery; Chandelier; Valved Cannula; Microscope Integrated Optical Coherence Tomography

J Ophthalmic Vis Res 2016; 11 (1): 93-99.

INTRODUCTION

The global epidemic of diabetes is a significant challenge for public health and ophthalmology in particular. The estimated worldwide prevalence of diabetes is 2.8%, which is projected to reach 4.4% by 2030.^[1] The overall estimated crude prevalence for diabetic retinopathy among patients with diabetes in the United States is 40.3%^[2] and up to 82.3% for type 1 diabetes.^[3] Diabetes is the most common cause of legal blindness among individuals 20 to 74 years of age.^[4]

The Diabetes Control and Complications Trial (DCCT)^[5] and the United Kingdom Prospective Diabetes

Study (UKPDS)^[6] established that glycemic and blood pressure control can prevent or delay the progression of diabetic retinopathy. However, despite optimal control and due to the fact that some patients still present with uncontrolled disease, many eyes require surgical intervention for visual rehabilitation.

This review presents recent vitreoretinal surgery advances and discusses new tips and tricks for proliferative diabetic retinopathy surgery.

INDICATIONS FOR SURGERY

The classic role of surgery for diabetic retinopathy was defined in 1990 by the Diabetic Retinopathy Vitrectomy Study (DRVS), which randomized 616 eyes with recent vitreous hemorrhage and visual acuity of 5/200 or less for at least 1 month, to undergo early vitrectomy within 6 months versus observation. The greatest benefit from

Correspondence to:

Tamer H. Mahmoud, MD, PhD. Duke Eye Center, 2351 Erwin Road, Durham, NC 27710, USA.
E-mail: tamer.mahmoud@duke.edu

Received: 25-08-2015

Accepted: 15-09-2015

Access this article online

Quick Response Code:



Website:

www.jovr.org

DOI:

10.4103/2008-322X.180697

This is an open access article distributed under the terms of the Creative Commons Attribution-NonCommercial-ShareAlike 3.0 License, which allows others to remix, tweak, and build upon the work non-commercially, as long as the author is credited and the new creations are licensed under the identical terms.

For reprints contact: reprints@medknow.com

How to cite this article: Oellers P, Mahmoud TH. Surgery for proliferative diabetic retinopathy: New tips and tricks. *J Ophthalmic Vis Res* 2016;11:93-9.

surgery was found in type 1 diabetics, who tended to be younger and had more severe disease.^[7] The DRVS also established the surgical indication for severe fibrovascular proliferation.^[8,9] Tractional retinal detachment (TRD) involving or threatening the macula represents another primary surgical indication.^[10-12] Other less common indications for vitrectomy are ghost-cell glaucoma, dense premacular hemorrhage and macular edema with tractional component. Rubeosis iridis or neovascular glaucoma can also represent a surgical indication in select cases with media opacity, however, this is less commonly performed in the era of anti-vascular endothelial growth factor (VEGF) agents.^[13] Since the DRVS and early tractional retinal detachment studies, outcomes of PDR surgery have steadily improved, likely owing to advances in vitreoretinal instrumentation, techniques, perioperative medical management, and associated changes in practice patterns with earlier intervention in some eyes with better vision.^[14,15]

Non-clearing Vitreous Hemorrhage

Several factors are important when evaluating non-clearing vitreous hemorrhage. As portended by the DRVS, non-clearing vitreous hemorrhage in type 1 diabetes warrants earlier vitrectomy than type 2 diabetes, which can often be safely observed for longer durations, especially if adequate panretinal photocoagulation (PRP) had been performed. Nowadays, criteria for timing and decision for surgery in vitreous hemorrhage are flexible and several factors need to be included in the decision making progress. In general, we observe vitreous hemorrhage in type 1 diabetes for 1 month and schedule vitrectomy if there are no signs of clearing; on the other hand we often monitor vitreous hemorrhage in type 2 diabetes for 2-4 months. Earlier intervention may be considered in the absence of adequate prior PRP, or in the presence of dense premacular hemorrhage, coexisting tractional retinal detachment involving or threatening the macula, recurrent vitreous hemorrhage associated with prolonged intermittent visual impairment, poor vision of the eye, poor vision of the fellow eye, as well as patient preferences for earlier visual rehabilitation. In the presence of significant diabetic macular edema (DME) or systemically poorly controlled diabetes, we sometimes delay surgical intervention for medical stabilization.

Severe Fibrovascular Proliferation

Progressive fibrovascular proliferation despite maximum PRP may represent another indication for vitrectomy and may often coexist with tractional retinal detachment. Less commonly, vitrectomy is performed in cases with macula dragging or media opacity due to fibrovascular tissue overlying the macula.^[16,17]

Tractional Retinal Detachment

Tractional retinal detachment involving the macula is a classic primary indication for vitrectomy.^[10,11] With improved techniques and outcomes, tractional detachment threatening the macula has also become a common indication for vitrectomy, but it is important to note that tractional retinal detachment not involving or threatening the macula can be safely observed.^[18] Combined tractional-rhegmatogenous detachments however, even if not close to the macula, should receive prompt surgery and we have a much lower threshold for operative intervention in these cases due to the risk of rapid progression.^[19]

PREOPERATIVE PLANNING

Systemic Considerations

Glycemic, blood pressure, and cholesterol control should be optimized before surgery in close cooperation with the patient's primary care physician or internist. In patients with poor control despite medication adherence, referral to an endocrinologist may be of importance. In patients with severe renal impairment, surgery should be coordinated according to the hemodialysis schedule. Preoperative evaluation by the anesthesiologist should take place several days prior to surgery to avoid unnecessary delays or cancellations on the day of surgery. We routinely ask patients to stay on their prescribed anticoagulants or antiplatelet agents, which do not increase the risk of intraoperative or postoperative vitreous hemorrhage.^[20] To avoid the risk of retrobulbar hemorrhage, a cut down subtenon block instead of a retrobulbar block can be administered.

Diabetes is a systemic disease with many systemic vascular complications. Five-year survival of patients undergoing diabetic vitrectomy is only 68%, especially if they have coexisting heart disease.^[21] We demonstrated that 5 years prior to diabetic vitrectomy, 39% of patients have already suffered a stroke, 28% a heart attack, and 43% developed renal failure.^[22] Many patients need to stay on anticoagulants and antiplatelets and preoperative planning is the key to a successful outcome.

Optical Coherence Tomography and Fluorescein Angiography

Spectral domain optical coherence tomography (SD-OCT) imaging of the outer retinal microarchitecture, namely integrity of the external limiting membrane (ELM) and ellipsoid zone (EZ), has been shown to correlate well with postoperative best corrected visual acuity (BCVA), while central foveal thickness and enlarged foveal avascular zone only exhibit a weak correlation.^[23] Such

information can be crucial to set the stage for realistic patient expectations prior to surgery.

Preoperative Pharmacotherapy

The advent of anti-vascular endothelial growth factor (VEGF) pharmacotherapy has revolutionized the treatment of many retinal diseases. Preoperative injection of bevacizumab (Genentech, South San Francisco, CA, USA) 7 days prior to surgery has shown promising results.^[24,25] However, the hope that preoperative bevacizumab may dramatically improve postoperative outcomes by regressing neovascularization has sobered quite a bit, specifically due to fear of the so called “*crunch syndrome*”, i.e. worsening tractional retinal detachment and development of denser fibrotic connections between the retina and overlying tissue, making it harder to identify tissue planes.^[26] This is especially critical in the more systemically ill diabetic retinopathy population, who often need to delay or cancel surgery due to systemic complications, in which case the consequences of an anti-VEGF induced tractional retinal detachment may not be fixable for a prolonged time with loathsome visual consequences.

Pegaptanib

We have good preliminary experience with preoperative intravitreal pegaptanib (Macugen, Bausch and Lomb, Bridgewater, NJ, USA). Pegaptanib is a pegylated aptamer that only inhibits the VEGF isoform 165^[27] and thus has an effect on the neovascularization with less tractional responses and lower systemic risks. In our hands, pegaptanib works well to regress neovascularization, and reduces the risk of intraoperative bleeding. We have not seen the crunch tractional retinal detachment that can be observed with the pan anti-VEGF effect of bevacizumab [Figure 1]. This allows injection of

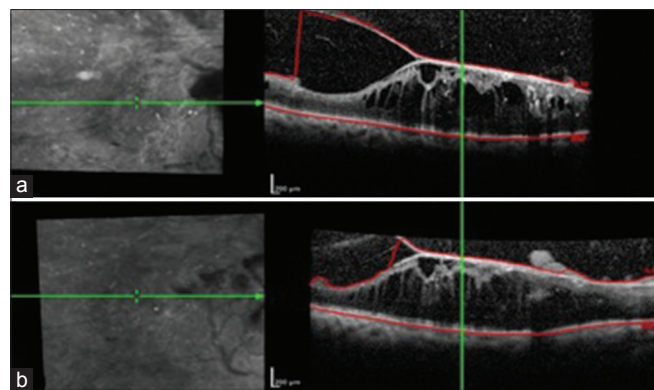


Figure 1. Use of preoperative pegaptanib (Macugen). (a) Spectral-domain (SD) optical coherence tomography (OCT) demonstrates tractional retinal detachment threatening the macula. (b) Corresponding SD-OCT image 2 months after pegaptanib injection reveals stable retinal detachment without further traction at the macula.

pegaptanib at any given time prior to surgery, even in the form of multiple injections, awaiting clearance and good timing for surgery. Pegaptanib may also be systemically advantageous due to the lower risk of vascular accidents in these high-risk patients.^[27]

Dexamethasone

Preoperative insertion of a dexamethasone implant (Ozurdex, Allergan, Dublin, Ireland) provides many advantages in selected cases. Ozurdex is a biodegradable 0.7 mg dexamethasone implant that is injected intravitreally via 22 gauge needle and has been approved by the Food and Drug Administration (FDA) for treatment of DME.^[28] We have injected Ozurdex preoperatively for PDR tractional retinal detachments in high risk patients with extensive systemic vascular disease. Ozurdex facilitates regression and consolidation of neovascularization in addition to inhibiting other inflammatory cytokines [Figure 2].

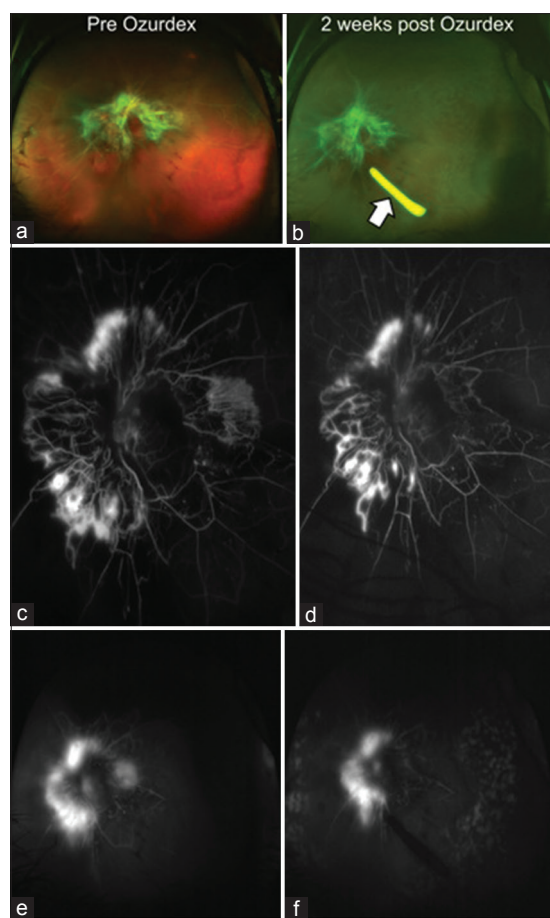


Figure 2. Use of preoperative biodegradable dexamethasone implant (Ozurdex). (a) Wide-field photograph demonstrates proliferative diabetic retinopathy and tractional retinal detachment with severe fibrovascular proliferation. (b) Two weeks after Ozurdex (arrow) injection, proliferative diabetic retinopathy appears more quiescent. (c-f) Corresponding early and late frame fluorescein angiograms before and after Ozurdex show consolidation of neovascularization.

Unlike anti-VEGF agents, there is no increased risk of systemic complications or tractional responses. Also, tissue planes are more distinct and not changed into flat fibrovascular tissue, which are very difficult to dissect, as can be the case following administration of anti-VEGF agents. Due to these properties, flexible operative clearance planning is achieved with ample time for preoperative clearance. In addition, Ozurdex releases the active drug over a period of 6 months^[28] and therefore keeps the eyes quiet and inactive in the postoperative period. Caution needs to be taken as the implant may become mobile within the vitreous cavity during vitrectomy. Ideally, we keep the implant in the inferior vitreous base away from any dissection and leave it intact at that location under silicone oil [Figure 3].

SURGICAL TIPS AND TRICKS

The operative principles for PDR surgery in sequential order are clearing the vitreous hemorrhage, release of anterior-posterior traction, dissection of fibrovascular proliferation by segmentation and delamination (or sometimes en-bloc dissection in appropriate cases), drainage of fluid through retinal holes or breaks (if any exist), endolaser panretinal photocoagulation and retinal reattachment with or without the use of tamponading agents. For cases with severe peripheral anterior-posterior traction and rhegmatogenous etiology, an adjuvant scleral buckle should be considered, especially in phakic patients. In select cases, additional internal limiting membrane (ILM) peeling can help release tangential retinal traction to flatten the posterior pole. Large retinotomies and retinectomies are reserved for very severe cases with extensive retinal contraction, especially those combined with proliferative vitreoretinopathy (PVR), where retinal flattening cannot be achieved by membrane peeling alone. In combined cases of tractional and rhegmatogenous detachment, perfluorocarbon liquids (PFCL) can aid in draining subretinal fluid through a peripheral retinotomy or



Figure 3. Intraoperative photo demonstrating Ozurdex implant in the vitreous cavity. Note that the implant (arrow) may become mobile during surgery. It is best to keep it in place after surgery at the inferior vitreous base and under silicone oil.

break, stabilizing and flattening the retina. Care should be taken since PFCL can easily slip through existing posterior holes into the subretinal space; and in such cases fluid air exchange would be a better option. Cases with re-proliferation under silicone oil may benefit from additional membrane peeling under oil. This is a much safer approach nowadays with availability of valved cannulas, where oil can be added to keep the pressure up during bimanual dissection under oil. Tamponading agents are needed for combined rhegmatogenous-tractional detachments.

Tremendous advances have been made in vitreoretinal surgical instrumentation over the recent years which have directly improved our ability to operate on PDR. Vitrectomy instruments are now available in 23, 25, and 27 gauge with improved instrument stiffness and enhanced instrument navigation through extremely narrow tissue planes as vitrectomy cutting speeds simultaneously have reached 7,500-8,000 cuts per minute (CPM) enabling extremely precise cutting.^[29] Illuminated instruments and chandelier lighting permit bimanual techniques when needed and most recently, intraoperative OCT was introduced for live tomographic rendering of the vitreoretinal microarchitecture.^[30]

Vitrectomy Instrumentation

Ultra-high cutting rates allow precise vitrector cutting in close proximity to the neurosensory retina with reduced risk of retinal tear formation, especially when used in conjunction with low vacuum settings. The combination of high cutting speeds with 25 or 27 gauge instruments allows precise segmentation and delamination.^[29] In combination with low flow rates causing minimal tissue movement and in some cases adjuvant proportional reflux hydrodissection^[31] or viscodissection,^[32] small-gauge vitrectomy cutters can be used to delaminate tightly adherent preretinal tissue, in some cases abolishing the need for additional instruments such as picks and scissors. However, in general, lifting and cutting in a unimanual or bimanual technique is a safer option for tightly adherent preretinal plaques than pushing through as in proportional reflux and viscodissection.

Bimanual Techniques

For tightly adherent fibrovascular membranes, bimanual techniques are often necessary to achieve tissue separation. This can best be accomplished by using chandelier lighting systems or illuminating instruments such as the lighted pick.^[16] Typical bimanual instruments used to dissect fibrovascular membranes include forceps and scissors. However, several combinations depending on the pathology at hand are available, such as forceps with vitrectomy probe, which can be more efficient in many cases. Diabetic dissection is mainly based on

scissors use rather than peeling; however, peeling may be needed in combined tractional and rhegmatogenous components with PVR and in cases of premacular hemorrhage with tightly adherent hyaloid where a lighted pick combined with a vitrectomy probe presents the best combination.

Small Gauge Vitrectomy and the Concept of Mixing Gauges

Complex tractional retinal detachments, especially with anterior pathology, have traditionally required 20 gauge due to its superior stiffness and wider variety of available instruments. However, 23 or 25 gauge equipment has improved steadily and 23- or 25-gauge instruments with adequate stiffness now represent our preferred approach to reach anterior pathology. When treating posterior fibrovascular membranes with narrow spaces between tight tissue planes, 27 gauge cutters can be advantageous due to their ability to reach into narrow spaces and safer maneuverability.^[29] However, current 27 gauge instruments still lack stiffness required for optimal reach of peripheral pathology as compared to 23/25 gauge systems. Mixing gauges can facilitate dissection in such cases. The use of 23/25 gauge system allows the use of diffusion light pipes and vertical scissors when needed, pneumatic or manual. The 27 gauge probe can be introduced through any 23/25 gauge (valved) cannulas with minimal outflow, keeping control of the pressure, but allowing reach to posterior and anterior peripheral pathology.

A flowchart describing our approach from the preoperative phase to surgery, instrumentation and tamponade choice is depicted in Figure 4.

Valved Cannulas

Valved cannulas allow stable intraoperative fluidics and IOP control. Temporary IOP elevation during vitrectomy enables hemostasis in many cases without the need for diathermy, or the need to use the 20 gauge tissue manipulator that was once required for tough diabetic dissections. The stable fluidics of valved cannulas also allows for dissection of membranes under silicone oil or PFCL in an essentially closed system that inhibits any trans-cannula leakage, even during instrument exchange. However, we advise caution not to overfill PFCL beyond the site of cannula insertion height, which may lead to sequestration of PFCL in the anterior chamber, lens capsule or ciliary sulcus and secondary postoperative retention.^[33] Care should also be taken in cases of old non-clearing vitreous hemorrhage, where very thick old hemorrhage can wrap around the vitrectomy probe when passed through the cannulas. This potentially leads to a locked position of the probe within the cannula where the probe cannot be moved in and out and eventual pulling of the whole cannula with the probe; which

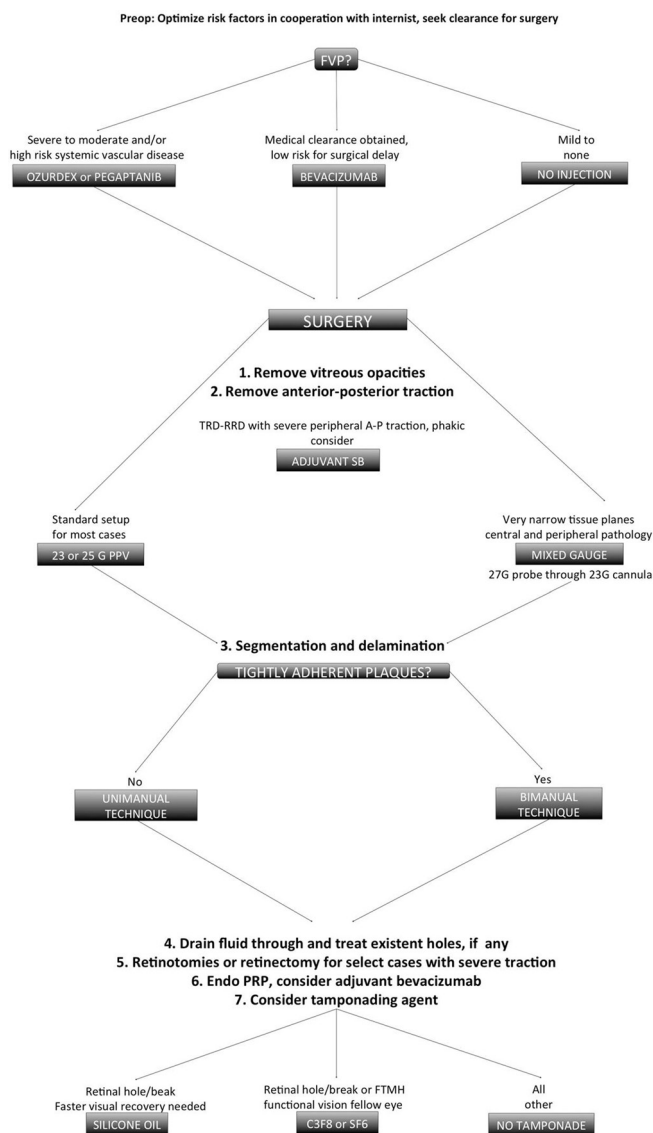


Figure 4. Flowchart algorithm describing our approach to patients with proliferative diabetic retinopathy with tractional retinal detachment. FVP, fibrovascular proliferation; TRD-RRD, combined tractional and rhegmatogenous retinal detachment; A-P, anterior-posterior, PRP, panretinal photocoagulation; G, gauge; C₃F₈, perfluoropropane gas; SF₆, sulfur hexafluoride gas.

invariably results in peripheral retinal or even giant breaks. Avoiding such a situation requires better outflow through the cannula, by the use of non-valved systems, or smaller gauge probes than the cannulas or use of open sclerotomies.

Intraoperative OCT

Intraoperative OCT is a new imaging technology that serves the surgeon with live cross sectional micro-architectural information.^[34] The first system introduced was a hand-held (HH) SD-OCT system, which was followed by microscope integrated (MI) SD-OCT machines with heads up display abilities.^[30,35]

Swept source (SS) MI-OCT systems are in preclinical testing and will surpass current technologies due to enhanced resolution, imaging acquisition speed, and 3D rendering. At this time, we use intraoperative OCT for selected complex cases to identify tissue planes, residual subclinical epiretinal membranes or internal limiting membranes and to diagnose inadvertent macular hole formation. OCT information and direct surgeon feedback can alter surgical strategies, for instance additional peeling maneuvers for residual subclinical membranes or use of gas tamponade and patient positioning instructions in cases of occult macular hole. We predict that more sophisticated MI-OCT systems will play an ever increasing role by providing dynamic and live feedback of microarchitectural tissue alterations and instrument – vitreous-retina interface interactions.

SUMMARY

Surgery for PDR remains challenging, but has advanced due to improved surgical instrumentation. Careful preoperative and operative planning, including the choice of instruments, gauge and tamponade is the key for successful surgery, often enabling meaningful visual rehabilitation even in severe cases.

Financial Support and Sponsorship

Nil.

Conflicts of Interest

There are no conflicts of interest.

REFERENCES

- Wild S, Roglic G, Green A, Sicree R, King H. Global prevalence of diabetes: Estimates for the year 2000 and projections for 2030. *Diabetes Care* 2004;27:1047-1053.
- Kempner JH, O'Colmain BJ, Leske MC, Haffner SM, Klein R, Moss SE, et al. The prevalence of diabetic retinopathy among adults in the United States. *Arch Ophthalmol* 2004;122:552-563.
- Roy MS, Klein R, O'Colmain BJ, Klein BE, Moss SE, Kempner JH. The prevalence of diabetic retinopathy among adult type 1 diabetic persons in the United States. *Arch Ophthalmol* 2004;122:546-551.
- Fong DS, Aiello L, Gardner TW, King GL, Blankenship G, Cavallerano JD, et al. Retinopathy in diabetes. *Diabetes Care* 2004;27 Suppl 1:S84-S87.
- Progression of retinopathy with intensive versus conventional treatment in the Diabetes Control and Complications Trial. Diabetes Control and Complications Trial Research Group. *Ophthalmology* 1995;102:647-661.
- Tight blood pressure control and risk of macrovascular and microvascular complications in type 2 diabetes: UKPDS 38. UK Prospective Diabetes Study Group. *BMJ* 1998;317:703-713.
- Early vitrectomy for severe vitreous hemorrhage in diabetic retinopathy. Four-year results of a randomized trial: Diabetic Retinopathy Vitrectomy Study Report 5. *Arch Ophthalmol* 1990;108:958-964.
- Early vitrectomy for severe proliferative diabetic retinopathy in eyes with useful vision. Clinical application of results of a randomized trial – Diabetic Retinopathy Vitrectomy Study Report 4. The Diabetic Retinopathy Vitrectomy Study Research Group. *Ophthalmology* 1988;95:1321-1334.
- Early vitrectomy for severe proliferative diabetic retinopathy in eyes with useful vision. Results of a randomized trial – Diabetic Retinopathy Vitrectomy Study Report 3. The Diabetic Retinopathy Vitrectomy Study Research Group. *Ophthalmology* 1988;95:1307-1320.
- Williams DF, Williams GA, Hartz A, Mieler WF, Abrams GW, Aaberg TM. Results of vitrectomy for diabetic traction retinal detachments using the en bloc excision technique. *Ophthalmology* 1989;96:752-758.
- Miller SA, Butler JB, Myers FL, Bresnick GH. Pars plana vitrectomy. Treatment for tractional macula detachment secondary to proliferative diabetic retinopathy. *Arch Ophthalmol* 1980;98:659-664.
- Aaberg TM. Pars plana vitrectomy for diabetic traction retinal detachment. *Ophthalmology* 1981;88:639-642.
- Ho T, Smiddy WE, Flynn HW Jr. Vitrectomy in the management of diabetic eye disease. *Surv Ophthalmol* 1992;37:190-202.
- Gupta B, Sivaprasad S, Wong R, Laidlaw A, Jackson TL, McHugh D, et al. Visual and anatomical outcomes following vitrectomy for complications of diabetic retinopathy: The DRIVE UK study. *Eye (Lond)* 2012;26:510-516.
- Gupta B, Wong R, Sivaprasad S, Williamson TH. Surgical and visual outcome following 20-gauge vitrectomy in proliferative diabetic retinopathy over a 10-year period, evidence for change in practice. *Eye (Lond)* 2012;26:576-582.
- Sharma S, Hariprasad SM, Mahmoud TH. Surgical management of proliferative diabetic retinopathy. *Ophthalmic Surg Lasers Imaging Retina* 2014;45:188-193.
- Newman DK. Surgical management of the late complications of proliferative diabetic retinopathy. *Eye (Lond)* 2010;24:441-449.
- Charles S, Flinn CE. The natural history of diabetic extramacular traction retinal detachment. *Arch Ophthalmol* 1981;99:66-68.
- Yang CM, Su PY, Yeh PT, Chen MS. Combined rhegmatogenous and traction retinal detachment in proliferative diabetic retinopathy: Clinical manifestations and surgical outcome. *Can J Ophthalmol* 2008;43:192-198.
- Brown JS, Mahmoud TH. Anticoagulation and clinically significant postoperative vitreous hemorrhage in diabetic vitrectomy. *Retina* 2011;31:1983-1987.
- Helbig H, Kellner U, Bornfeld N, Foerster MH. Life expectancy of diabetic patients undergoing vitreous surgery. *Br J Ophthalmol* 1996;80:640-643.
- El Sanhoury A, Elliott D, Mahmoud TH. Systemic Complications in Patients Undergoing Vitrectomy for Proliferative Diabetic Retinopathy. Kresge Eye Institute Annual Meeting; 2009.
- Shah VA, Brown JS, Mahmoud TH. Correlation of outer retinal microstructure and foveal thickness with visual acuity after pars plana vitrectomy for complications of proliferative diabetic retinopathy. *Retina* 2012;32:1775-1780.
- Figueroa MS, Contreras I, Noval S. Anti-angiogenic drugs as an adjunctive therapy in the surgical treatment of diabetic retinopathy. *Curr Diabetes Rev* 2009;5:52-56.
- di Lauro R, De Ruggiero P, di Lauro R, di Lauro MT, Romano MR. Intravitreal bevacizumab for surgical treatment of severe proliferative diabetic retinopathy. *Graefes Arch Clin Exp Ophthalmol* 2010;248:785-791.
- Arevalo JF, Maia M, Flynn HW Jr., Saravia M, Avery RL, Wu L, et al. Tractional retinal detachment following intravitreal bevacizumab (Avastin) in patients with severe proliferative diabetic retinopathy. *Br J Ophthalmol* 2008;92:213-216.
- Nagpal M, Nagpal K, Nagpal PN. A comparative debate on the various anti-vascular endothelial growth factor drugs:

- Pegaptanib sodium (Macugen), ranibizumab (Lucentis) and bevacizumab (Avastin). *Indian J Ophthalmol* 2007;55:437-439.
28. Boyer DS, Yoon YH, Belfort R Jr., Bandello F, Maturi RK, Augustin AJ, et al. Three-year, randomized, sham-controlled trial of dexamethasone intravitreal implant in patients with diabetic macular edema. *Ophthalmology* 2014;121:1904-1914.
 29. Dugel PU, Abulon DJ, Dimalanta R. Comparison of attraction capabilities associated with high-speed, dual-pneumatic vitrectomy probes. *Retina* 2015;35:915-920.
 30. Hahn P, Migacz J, O'Donnell R, Day S, Lee A, Lin P, et al. Preclinical evaluation and intraoperative human retinal imaging with a high-resolution microscope-integrated spectral domain optical coherence tomography device. *Retina* 2013;33:1328-1337.
 31. Dugel PU. Proportional reflux hydrodissection. *Retina* 2012;32:629-630.
 32. Fortun JA, Hubbard GB 3rd. New viscodissection instrument for use with microincisional vitrectomy in the treatment of diabetic tractional retinal detachments. *Arch Ophthalmol* 2011;129:352-355.
 33. Oellers P, Schneider EW, Fekrat S, Mahmoud TH, Mruthyunjaya P, Hahn P. Retained intraocular perfluoro-n-octane after valved cannula pars plana vitrectomy for retinal detachment. *Ophthalmic Surg Lasers Imaging Retina* 2015;46:451-456.
 34. Hahn P, Migacz J, O'Connell R, Maldonado RS, Izatt JA, Toth CA. The use of optical coherence tomography in intraoperative ophthalmic imaging. *Ophthalmic Surg Lasers Imaging* 2011;42 Suppl:S85-S94.
 35. Ehlers JP, Tao YK, Srivastava SK. The value of intraoperative optical coherence tomography imaging in vitreoretinal surgery. *Curr Opin Ophthalmol* 2014;25:221-227.