

Bowel Obstruction in the Postoperative Period of Laparoscopic Inguinal Hernia Repair (TAPP): Review of the Literature

J. Cueto, MD¹, J.A. Vázquez², MD, M.A. Solís², MD, G. Valdéz², MD, S. Valencia², MD, A. Weber, MD

ABSTRACT

A case is presented of a male patient that presented with intestinal obstruction in the early postoperative period of a transabdominal preperitoneal inguinal repair (TAPP) that was diagnosed and repaired successfully using laparoscopy. Whenever a total extraperitoneal procedure (TEP) cannot be performed, the peritoneal closure of the TAPP should be done water-tight using interrupted stitches of absorbable monofilament sutures.

Key Words: Laparoscopy, TAPP hernia repair, Bowel obstruction.

INTRODUCTION

Laparoscopic inguinal hernioplasty is being performed more frequently everywhere, now that several well-designed prospective and randomized studies¹⁻⁵ have shown that it produces results that compare favorably to the open conventional approaches with the added and well-known advantages of this type of mini-invasive surgery. However, like any other surgical procedure, it has complications, some of which appear to be unique to this technical modality like intestinal obstruction related to TAPP. Herein, such a case is reported.

CASE REPORT

A 65-year-old white male was seen in our office with the main complaint of bilateral inguinal hernias diagnosed elsewhere. He had had an appendectomy 15 years before. He recently complained of pain in the right side and was referred to our office by his brother, who had been operated with the same diagnosis using laparoscopy in 1993. The rest of the clinical examination was unremarkable, and a chest film and electrocardiogram and preoperative laboratory workup were within normal limits. Accordingly, on January 22, he was admitted to the Spanish Hospital in México City and, under general endotracheal anesthesia, a 2 cm lower umbilical incision was made. Under direct vision the anterior fascia of the rectus muscle was incised and its fibers retracted. The preperitoneal space was dissected and a balloon trocar was inserted and advanced to the level of the pubis. During the dissection of the preperitoneal space, it was observed that the peritoneum was torn at the site of the previous appendectomy incision, and the procedure was converted to a transperitoneal approach. Two 10 mm trocars were placed in each flank under direct vision and transillumination to avoid injury to the epigastric vessels. The right peritoneal incision was extended and a large indirect hernia with an accompanying direct defect were seen. A lipoma was excised, and the peritoneal sac was dissected free up to the level of the umbilicus. A 15 x 7 cm polypropylene mesh was introduced, unrolled and properly placed and anchored using a 5 mm Tacker (Origin Medical Systems, Inc., Menlo Park, California) in Cooper's ligament, the upper medial corner of the Hesselbach's tri-

Department of Surgery, The American-British Cowdray Hospital, México City, MEXICO

¹Prof. Assist. Adj. Department of Surgery of LSU Medical Center, New Orleans, Louisiana, USA.

²Diplomat in Laparoscopic Surgery.

Address reprint request to: Dr. Jorge Cueto, Bosque de Magnolias No. 87, Bosques de las Lomas, 11700 México, D.F., MEXICO.

angle, and in the lateral upper aspect above the level of the anterior and superior iliac spine. The peritoneal defect was closed with a running suture of 00 PDS (polydioxanone Ethicon, Ltd, U.K.), (**Figure 1**). A similar procedure was carried out in the left side for a smaller indirect hernia. The patient was discharged eight hours later with normal and stable vital signs, tolerating well a liquid diet. He had normal urination and was able to walk with assistance. The next morning he requested pain medication at home and took the analgesic prescribed (Ketorolac P.O. 10 mg), and soon after that he presented nausea and several episodes of forceful vomiting. Three hours later

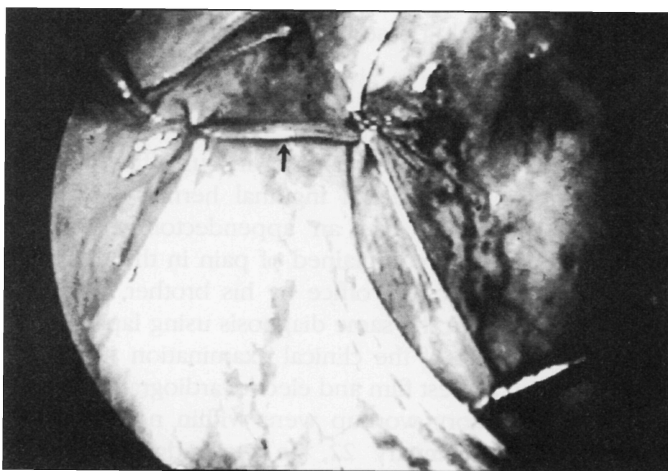


Figure 1. Peritoneal closure that appears to be adequate.

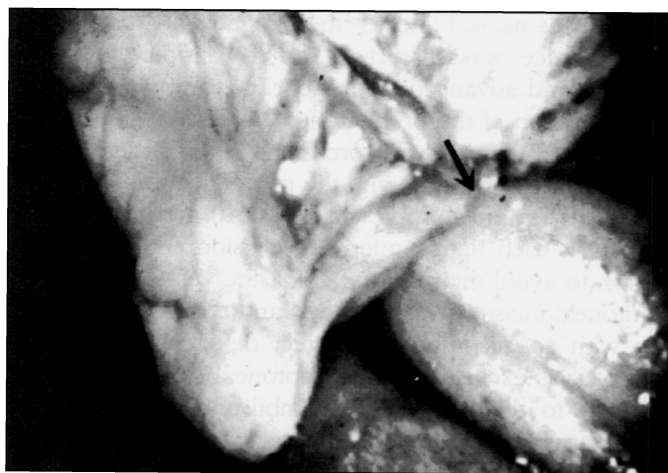


Figure 2. Loop of small bowel herniated through the peritoneal closure defect.

he contacted us because of abdominal pain and bloating. He was seen and examined at the emergency room at which time he was found to have normal vital signs, mild dehydration and abdominal distention with hyperactive bowel sounds without rebound. An upright film of the abdomen revealed air and fluid levels. A complete blood count showed 15,000 white blood cell count (WBC). He was hospitalized, a nasogastric tube was inserted, intravenous fluids and a second generation cephalosporin was given IV. He failed to improve overnight, having a large NG aspirate, and he developed inguino-scrotal swelling for which reason he was taken to the operating room and re-operated using general endotracheal anesthesia. Upon introduction of the 10 mm laparoscope, it was obvious that 30-35 cm of small intestine loops were herniated through a right peritoneal suture defect (**Figure 2**). With the aid of two 10 mm Babcock-type of forceps, all the loops of small bowel were carefully extracted from the defect and none of them showed signs of severe ischemia nor perforation. The preperitoneal defect was irrigated and 10 ml of normal saline containing 1 g of kanamycin were left in. The peritoneal defect was closed using interrupted "figure of X" stitches of polydioxanone until a water-tight closure was achieved (**Figure 3**). The postoperative period was uneventful; he passed flatus in the second postoperative day, tolerated a liquid diet and was discharged on the 3rd postoperative day on oral antibiotics for an additional 10 days. He has remained asymptomatic to this date, having assisted to the office several times and is satisfied with the result of the operation.

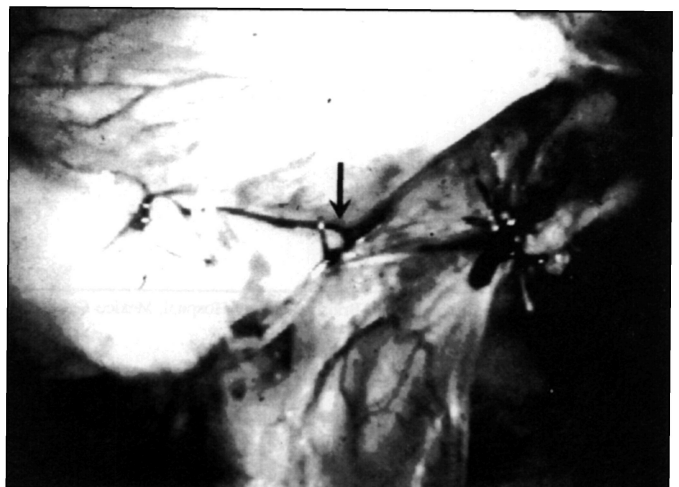


Figure 3. Closure of the defect with interrupted "figure of X" stitches using 00 polydioxanone.

DISCUSSION

Postoperative complications are not exclusive of the laparoscopic approach. At least nine prospective studies¹⁻⁹ have compared the frequency of complications between laparoscopic and open inguinal hernia repair. Overall, the complication index is higher for the open procedures (22% vs 18%), though there is not statistical significance.¹⁰ Mike, et al., in their multicentric prospective and randomized study, also found a higher morbidity for the open techniques (20.3% vs 20.1%) even though in this report the use of extra trocars, rupture of instruments, and conversion from TAPP to TEP techniques were considered complications.¹¹

Fortunately, most of the complications following laparoscopic hernia repair are minor (seromas, hematomas, pneumoscrotum, orchitis, etc.) although there are some serious complications of the operation like nerve entrapment and intestinal obstruction. The latter is rare and may be caused by herniation of an intestinal loop through a port incision (usually bigger than 5 mm) when the wound has not been closed correctly.¹²⁻¹⁴ We found at least 15 cases reported in the literature of intestinal obstruction due to herniation of the intestines or adhesions at the site of peritoneal closure after a transabdominal preperitoneal inguinal repair (TAPP).¹⁵⁻²⁴ In five of these patients reoperation was done laparoscopically, whereas in three it was done by laparotomy and in seven cases the approach was not specified. One patient with a staple peritoneal closure developed an internal herniation, was re-operated by laparoscopy and presented a second intestinal obstruction in the same place that had been closed again with the staples and had to be re-operated for the second time by laparotomy. The peritoneal defect was repaired finally with interrupted stitches.¹⁸

In the case herein reported - the 420th consecutive laparoscopic inguinal repair in our group since 1992 - it is possible to speculate that the vomiting crisis that our patient suffered soon after the analgesic ingestion could have caused a sudden increase of the intra-abdominal pressure leading to herniation of intestinal loops through the peritoneal inguinal closure. In general, the authors agree that staple closure can be defective if a large gap is left between them and that this may lead to the "shower-curtain" effect, which also occurred in this patient who had a running stitch type of closure. Our group previously repaired peritoneal defects with a running-suture or "figure of X" interrupted stitches with 00 PDS (polydiox-

anone) and, as shown in **Figure 1**, the closure seemed to be adequate, initially. After the presentation of this complication, our current opinion is that when TAPP is indicated, a safer closure should be done with interrupted "figure of X" stitches, leaving a space of not more than 0.5 cm between each. The procedure of choice at the present time is to carry out a TEP procedure whenever it is possible, in which this complication is avoided. There are, though, indications for a TAPP procedure with advantages,²⁵ and a reduced number of TEP procedures will be converted. So, it is necessary to keep in mind the possible complications of the former method to prevent them and treat them correctly once they appear.

Finally, we think that the approach of choice in a reoperation of this type of case is laparoscopy because the lysis of adhesions and the internal herniation can be solved readily with this method. If needed, the umbilical trocar incision can be lengthened 3 or 4 cms to assist the procedure in order to exteriorize necrotic intestinal loops to perform the resection/anastomosis procedure and introduce them back into the abdominal cavity.^{26,27} Alternatively, if deemed necessary, a formal laparotomy can be done once the diagnosis has been established.

CONCLUSIONS

Even though laparoscopic inguinal repair has gained popularity due to its results and advantages, it should not be forgotten that, as in any other surgical procedure, complications may appear and some of them can be serious or even lethal. A water-tight peritoneal closure in the TAPP procedure, using interrupted stitches with an adequate closure of the rest of trocar wounds, should reduce the risk of postoperative intestinal obstruction, considerably. We consider laparoscopy the procedure of choice to diagnose and treat this complication.

References:

1. Vogt DM, Curet MJ, Pitcher DE, et al. Preliminary results of a prospective randomized trial of laparoscopic onlay versus conventional inguinal herniorrhaphy. *Am J Surg.* 1995;169:84-90.
2. Lawrence K, McWhinnie D, Goodwin A, et al. Randomised controlled trial of laparoscopic versus open repair of inguinal hernia: early results. *BMJ.* 1995;311:981-985.
3. Stoker DL, Spiegelhalter DJ, Singh R, Wellwood JM. Laparoscopic versus open inguinal hernia repair: randomized prospective trial. *Lancet.* 1994;343:243-245.

4. Payne Jr JL, Grininger LM, Izawa MT, et al. Laparoscopic or open inguinal herniorrhaphy? A randomized prospective trial. *Arch Surg*. 1994;129:973-981.
5. Barkun JS, Wexler MJ, Hinchey EJ, et al. Laparoscopic versus open inguinal herniorrhaphy: preliminary results of a randomized controlled trial. *Surgery*. 1995;18:703-710.
6. Wilson MS, Deans GT, Brough WA. Prospective trial comparing Lichtenstein with laparoscopic tension-free mesh repair of inguinal hernia. *Br J Surg*. 1995;82:274-277.
7. Brooks DC. A prospective comparison of laparoscopic and tension-free open herniorrhaphy. *Arch Surg*. 1994;129:361-366.
8. Cornell RB, Kerlakian GM. Early complications and outcomes of the current technique of transperitoneal laparoscopic herniorrhaphy and a comparison to the traditional open approach. *Am J Surg*. 1994;168:275-279.
9. Millikan KW, Kosik ML, Doolas A. A prospective comparison of transabdominal preperitoneal laparoscopic hernia repair in a university setting. *Surg Laparosc Endosc*. 1994;4:247-253.
10. Memon MA, Rice D, Donohue JH. Laparoscopic herniorrhaphy. *J Am Coll Surg*. 1997;184:325-335.
11. Mike SL, Liem MD, van der Graaf Y, et al. Comparison of conventional anterior surgery and laparoscopic surgery for inguinal-hernia repair. *N Eng J Med*. 1997;336:1541-1547.
12. Wegener ME, Chung D, Crans C, et al. Small bowel obstruction secondary to incarcerated Richter's hernia from laparoscopic hernia repair. *J Laparoendosc Surg*. 1993;3:173-176.
13. Patterson M, Walters D, Browder W. Postoperative bowel obstruction following laparoscopic surgery. *Am Surg*. 1993;59:656-657.
14. Cueto J, Melgoza C, Weber A. A simple and safe technique for closure of trocar wounds using a new instrument. *Surg Laparosc Endosc*. 1996;6(5):392-393.
15. Tetik C, Arregui ME, Dulucq JL, et al. Complications and recurrences associated with laparoscopic repair of groin hernias. A multi-institutional retrospective analysis. *Surg Endosc*. 1994;8:1316-1323.
16. Phillips EH, Arregui M, Carroll BJ, et al. Incidence of complications following laparoscopic hernioplasty. *Surg Endosc*. 1995;9:16-21.
17. Félix EL, Michas CA, González Jr MH. Laparoscopic hernioplasty: why does it work? *Surg Endosc*. 1997;11:36-41.
18. Petersen TI, Qvist N, Wara P. Intestinal obstruction—a procedure-related complication of laparoscopic inguinal repair. *Surg Laparosc Endosc*. 1995;5:214-216.
19. Ohta J, Yamauchi Y, Yoshida Sh, et al. Laparoscopic intervention to relieve small bowel obstruction following laparoscopic herniorrhaphy. *Surg Laparosc Endosc*. 1997;7:464-468.
20. Tsang S, Normand R, Karlin R. Small bowel obstruction: a morbid complication after laparoscopic herniorrhaphy. *Am Surg*. 1994;60:332-334.
21. Corbitt JD Jr. Laparoscopic herniorrhaphy. In Balley RW, Flowers JL, eds. *Complications in Laparoscopic Surgery*. St. Louis: Quality Medical; 1995:185-217.
22. Hendrickse CW, Evans DS. Intestinal obstruction following laparoscopic inguinal repair. *Br J Surg*. 1993;80:1432.
23. Milencoff S, de Gara CJ, Gagic N. Intestinal obstruction following laparoscopic hernia repair [letter]. *Br J Surg*. 1994;81:471-472.
24. Milkins R, Wedgewood K. Intestinal obstruction following laparoscopic inguinal hernia repair [letter]. *Br J Surg*. 1994;81:471.
25. Cueto J, Rodríguez M, Elizalde A, Weber A. Incarcerated obturator hernia successfully treated by laparoscopy. *Surg Laparosc Endosc*. 1998;8(1):71-73.
26. Cueto J, Díaz O, Garteiz D, Rodríguez M, Weber A. The efficacy of laparoscopic surgery in the diagnosis and treatment of peritonitis. *Surg Endosc*. 1997;11(4):366-370.
27. Milsom JW, Garcia RA. Colectomía en enfermedad benigna del colon. *En Cirugía Laparoscópica*. Ed. J. Cueto y A. Weber. Mexico City: McGraw-Hill Internacional; 1997:232-245.