



Review

“Wait and scan” management of patients with vestibular schwannoma and the relevance of non-contrast MRI in the follow-up

Jing Zou ^{a,*}, Timo Hirvonen ^b

^a Department of Otolaryngology-Head and Neck Surgery, Center for Otolaryngology-Head & Neck Surgery of Chinese PLA, Changhai Hospital, Second Military Medical University, Shanghai, China

^b Department of Otorhinolaryngology-Head and Neck Surgery, University of Helsinki and Helsinki University Hospital, Helsinki, Finland

Received 20 June 2017; revised 29 July 2017; accepted 4 August 2017

Abstract

Vestibular schwannoma (VS) is a slow-growing benign neoplasm. There has been an evolution in the management of VS from active treatments (microsurgery and stereotactic radiotherapy) to conservative management (wait and scan). Regular MRI scanning is necessary to monitor tumor progression. Conservative management causes significantly less complications and offers a higher quality of life compared with active treatments. The mean growth rate of VS varies from 0.4 to 2.9 mm/year, and spontaneous shrinkage is observed in 3.8 percent of tumors during observation. If significant growth occurs, active treatment is considered. Significant growth is defined as an increase of at least 3 mm in the largest extrameatal diameter in any plane between the first and last available scans. The vestibulocochlear nerve is surrounded by cerebrospinal fluid, which provides natural contrast for MRI; thus, gadolinium may not be needed to detect VS. Specific sequences have high sensitivity, specificity, and accuracy for detection of progression. Hypointense signal in the ipsilateral inner ear fluid might be a useful sign to distinguish VS from meningioma. In this paper, we summarize the current status of research on conservative management and non-contrast MRI for the detection of VS.

Copyright © 2017, PLA General Hospital Department of Otolaryngology Head and Neck Surgery. Production and hosting by Elsevier (Singapore) Pte Ltd. This is an open access article under the CC BY-NC-ND license (<http://creativecommons.org/licenses/by-nc-nd/4.0/>).

Keywords: Vestibular schwannomas; Treatment; Magnetic resonance imaging; Contrast; Quality of life

Contents

1. Introduction	175
2. The biological behavior of vestibular schwannoma	175
3. The risks and complications of active treatments	176
3.1. Risks and complications of microsurgery	176
3.2. Risks and complications of radiotherapy	176
4. Wait and scan strategy	176
4.1. Advantages of wait and scan procedure	176
4.2. Status in the clinical application of “wait and scan”	177
4.3. Growth rate and transition of the management modality	177
5. Contrast MRI	178
6. Non-contrast MRI	178

* Corresponding author. Department of Otolaryngology-Head and Neck Surgery, Changhai Hospital, Second Military Medical University, Changhai Road #168, 200433 Shanghai, China.

E-mail address: zoujinghb@hotmail.com (J. Zou).

Peer review under responsibility of PLA General Hospital Department of Otolaryngology Head and Neck Surgery.

6.1. Sequences of non-contrast MRI	178
6.1.1. T2-weighted fast spin echo	178
6.1.2. Sampling perfection with application-optimized contrasts by using flip angle evolution	179
6.1.3. 3D constructive interference in the steady state	179
6.1.4. 3D-fast imaging employing steady state acquisition	180
6.1.5. Sequences for distinguishing VS from meningioma	180
6.2. Accuracy and sensitivity of non-contrast MRI	180
6.3. Advantages and clinical relevance of non-contrast MRI in vestibular schwannoma imaging	181
7. Conclusions	181
8. Future perspectives of wait-and-scan management and non-contrast MRI	181
9. Conflict of interest	181
10. Ethical approval	181
Acknowledgments	181
References	182

1. Introduction

Vestibular schwannomas (VSs) are benign neoplasms of the 8th cranial nerve originating from the myelin-forming Schwann cells of either the superior (SVN) or inferior vestibular nerve (IVN), and the latter accounts for more than 90% of cases (Khrais et al., 2008). Patients with VSs commonly complain of asymmetric hearing loss that may be accompanied by tinnitus, dizziness, facial numbness or weakness, or a combination of these. The VS is the most common cerebellopontine angle tumor with a proportion of approximately 80–90% and it accounts for 8–10% of all intracranial neoplasms (Tallan et al., 1993; Valvassori, 1988). The VS has an estimated annual incidence of 1.09 per 100,000 population in USA and 2.55–3.32 per 100,000 population in Netherlands (Kleijwegt et al., 2016; Kshetry et al., 2015). However, this number is significantly higher in Denmark, where the annual incidence has risen from 78 per 100,000 in 1976 to 230 per 100,000 in 2004 likely due to improved detection with magnetic resonance imaging (MRI) (Stangerup and Caye-Thomasen, 2012). In addition, tumor size at diagnosis has decreased significantly over time, probably due to same reason. The current trend in treatment is from traditional microsurgical resection or stereotactic radiotherapy to conservative management (it is also called wait and scan) (Fayad et al., 2014; Jufas et al., 2015; Lee et al., 2014; Patnaik et al., 2015; Rosenberg, 2000; Stangerup and Caye-Thomasen, 2012; Stangerup et al., 2008). For the “wait and scan” strategy, non-contrast MRI has the advantage of avoiding exposure to the contrast agent of gadolinium chelate in either screening or follow-up of VS, but still providing reliable results with constant improvements in technique (Oh et al., 2013; Ozgen et al., 2009; Schulze et al., 2016). This is important for the patients who need serial imaging. This review will present the recent progress in conservative management and non-contrast MRI in the treatment of VS.

2. The biological behavior of vestibular schwannoma

VSs can be either bilateral (neurofibromatosis 2, NF2) or unilateral (sporadic VSs), in which the NF2-associated VSs

tend to be more aggressive than the sporadic VSs (Linthicum and Brackmann, 1980) although the latter one may also sparsely exhibit aggressive behavior (Feghali and Kantrowitz, 1995). Inactivation of the NF2 gene, that leads to a loss of merlin (schwannomin, a putative tumor suppressor) expression, is believed to be paramount to the pathogenesis of both NF2 and sporadic VSs (Zwarthoff, 1996). The involvement of merlin depletion in the schwannoma tumorigenesis induces deregulation of ErbB receptor signaling, promoting a dedifferentiated state, and increasing Schwann cell proliferation (Ahmad et al., 2010). Expressed merlin may also be phosphorylated at the site of S518 by members of the PAK family of kinase and thus failed to enter the nucleus of Schwann cells of VS at S phase that is opposite to the wild type merlin (Lu et al., 2008). The ratio of merlin and S518 phosphorylated merlin may contribute to the biological behavior of VS with respect to the growth rate.

In general, VSs grow very slowly but variably with the average annual tumor growth rate varying from 0.4 to 2.9 mm/y (Yoshimoto, 2005). Even spontaneous shrinkage was observed in 3.8 percent of tumors during the “wait and scan” period (Huang et al., 2013). The variability may be associated with the clinical parameters selected, limited number of patients, different observation periods, location of the tumor, and gene status. Intratumoral hemorrhage, vessel density, the inflammatory reaction, and M2-polarized macrophages associated angiogenesis contribute to volume increase of sporadic vestibular schwannomas (Caye-Thomasen et al., 2005; de Vries et al., 2012; de Vries et al., 2013; Koutsimpelas et al., 2007). The VSs usually cause expansion of the internal auditory meatus within the temporal bone due to the growth. It is generally believed that the size and location of the tumor are the prime determinants of the extent of internal auditory meatus bone remodeling and expansion. Tumors that arise laterally along the course of the vestibular nerve tend to cause more expansion of the internal auditory meatus than those that arise more medially which can grow towards the cerebellopontine angle cistern. Due to this, large VSs may compress the brainstem, and an active intervention is needed.

3. The risks and complications of active treatments

3.1. Risks and complications of microsurgery

In untreated VS patient vertigo is the symptom responsible for the most pronounced negative impact on quality of life (Myrseth et al., 2006). However, vestibular dysfunction persists frequently after VS surgery (Hirvonen et al., 1995). Central compensation occurs in most of the patients, and patients without central compensation suffer more from imbalance (Abboud et al., 2016).

Hearing loss is another important symptom associated with the operation and one of the causes of depression (Blomstedt et al., 1996). Although hearing preservation surgery of VS has become one of the goals during tumor resection, only 40% of the patients in whom the cochlear nerve was left intact, preserved hearing. Moreover, only 9.8% of the patients had pure tone average (PTA) hearing level better than 30 dB in the affected side (Levo et al., 2000b). Sanna modified the American Academy of Otolaryngology-Head and Neck Surgery (AAO-HNS) grading scheme to reflect more accurately what kind of hearing is being preserved, and reported that class A or B was obtained in 6.8% of the middle cranial fossa approach patients and in 16.7% of the retrosigmoid approach patients, while the figures were 32.2% and 31.3%, respectively, when the AAO-HNS system was applied (Sanna et al., 2004). Even contralateral hearing loss and facial paralysis have been associated with excessive loss of cerebrospinal fluid (Lustig et al., 1995; Shuto et al., 2011; Warade et al., 2016). New tinnitus also appeared postoperatively in 39.8% of VS patients (Levo et al., 2000c).

Persistent post-operative headache is an annoying complication of VS surgery especially associated with retrosigmoid approach. The headache was investigated to be linked to neuropathic pain, allegedly caused by trigeminal irritation of the inner ear and the posterior fossa, which has recently been linked to vascular pain (Levo et al., 2000a). Patients with pre-existing headaches who were treated with microsurgery had worse dizziness handicap inventory (DHI) total scores than those managed with observation (wait-and-scan) or gamma knife radiotherapy (Carlson et al., 2014).

Facial paralysis after VS resection remains a concern and can significantly reduce QOL for patients in the postoperative period. Especially the occurrence of delayed facial palsy, which may appear in 29% of patients after VS operations regardless tumor size and surgical approach, is a challenge for both patients and surgeons. At 1 year, 97% of the patients recovered to better than House-Brackmann grade III facial nerve function (Lalwani et al., 1995). Patients with a gross total tumor resection or undergoing a retrosigmoid approach may be at higher risk of developing delayed facial paralysis (Carlstrom et al., 2016). In the case of immediate total paralysis, no patients achieved totally normal facial function (grade I), and only 10% recovered to a grade II (Pardo-Maza et al., 2016).

Cerebrospinal fluid (CSF) leakage is a severe complication associated with VS surgeries which may cause meningitis and

occur in 6.8–17% patients receiving tumor removal (Brennan et al., 2001; Hoffman, 1994; Rodgers and Luxford, 1993). An observation showed that CSF leakage was the cause of admission after discharge in 3.52% (240) of 6820 patients within 30 days, was implicated in nearly half of 490 readmissions (48.98%) (Alattar et al., 2017).

3.2. Risks and complications of radiotherapy

Stereotactic radiotherapy has been considered as a safe method in the treatment of VS. However, hydrocephalus is frequently observed in VS patients after gamma knife radiotherapy regardless the tumor size (Bloch et al., 2003; Gardner et al., 1954; Roche et al., 2008; Rogg et al., 2005; Steenerson and Payne, 1992). Lee et al. fitted an optimal predictive model and found that developing communicating hydrocephalus following stereotactic radiotherapy was most likely if the tumor had a volume $\geq 13.65 \text{ cm}^3$ (Lee et al., 2016). Stereotactic radiotherapy is not suitable for cystic VS and its efficacy is significantly reduced, when the tumor is growing rapidly (Marston et al., 2016). Stereotactic radiotherapy may cause facial palsy and trigeminal neuropathy, which were significantly associated with the history of prior surgical resection, tumor size, and the peripheral tumor dose (Chihara et al., 2007). An international cross-sectional study showed that 19.4% microsurgery-treated patients and 2% stereotactic radiotherapy-treated patients had worsened facial nerve function, whereas none of the conservatively managed patients experienced an objective decline in facial nerve function at the last clinical follow-up (Tveiten et al., 2016). Hearing loss may occur in 18% of VS patients received stereotactic radiotherapy, and 5.8% patients developed trigeminal neuropathy (Hempel et al., 2006).

4. Wait and scan strategy

4.1. Advantages of wait and scan procedure

In 1994, Jørgensen and Pedersen reported the management outcome in 78 patients who had been diagnosed with acoustic neuroma over a period of 13 years. They found that among 59 patients treated with microsurgery (46 patients with trans-labyrinthine, and 13 with suboccipital surgery), 4 died, 30 had problems with eating, drinking and balance, 17 had severe facial palsy, 21 discontinued their work after operation, and 30 had psychological problems. However, 19 patients (20 neuromas) who were kept under observation (wait and scan) had not deteriorated medically or socially (Jørgensen and Pedersen, 1994). Afterwards, Stangerup et al. reported hearing outcomes of 1144 VS patients managed with “wait and scan” during a 33-year period regarding the predictive value of hearing level at diagnosis. They found that in VS patients, good high frequency hearing and good speech discrimination at diagnosis are useful tools in predicting good hearing after observation (Stangerup et al., 2010). In 2015, Jufas et al. reported the quality of life (QOL) among 78 cases who underwent microsurgical excision of VSs compared with 145 cases

managed using “wait and scan”. They found that worse QOL scores for surgically managed versus “wait and scan” managed VS patients are in physical role limitation and social functioning. Handicap due to disequilibrium had the greatest negative impact on QOL (Jufas et al., 2015). Kim et al. also reported QOL in 108 patients with VSs (microsurgery in 47, gamma-knife radiotherapy in 27, and observations in 34), and their QOL did not differ significantly among the three groups with respect to four of the eight domains of the questionnaires (Kim et al., 2015).

Therefore, the “wait and scan” management of VS is a safe method with the least problems and provides a better QOL for the patient than active treatments.

4.2. Status in the clinical application of “wait and scan”

Until now, eight countries including USA, Denmark, Finland, Italy, Australia, Norway, Netherlands, and South Korea have reported conservative management for VS (Table 1). USA (the Florida Ear and Sinus Center) started the “wait-and-scan” management for VS in 1974 (Rosenberg, 2000). Denmark legislated a policy that patients in with a unilateral cerebello-pontine angle tumor resembling a typical VS are required to be referred for a potential primary “wait-and-scan” management at the ENT department in Copenhagen University Hospital, Rigshospitalet/Gentofte (Stangerup and Caye-Thomasen, 2012). Italy reported the results of the second largest sample size (Patnaik et al., 2015). South Korea is the only Asian country that started the conservative management for VS in 2012 (Kim et al., 2015).

In the report from USA, tumors with “wait and scan” management did not grow or regressed in 42%. Surgically treated tumors did not grow or regressed after subtotal resection of acoustic neuroma in 68.5% of patients, and 6.1% required revision surgery due to tumor growth or progressive symptoms (Rosenberg, 2000). Based on the Surveillance, Epidemiology and End Results (SEER) database, patients who received radiation therapy were younger and had larger tumors compared to those electing primary observation. The

microsurgical treatment was more common in younger patients and larger tumor size categories. An equation to predict future management practices created using linear regression predicted that by 2026, half of all cases of VS in USA will be managed initially with observation (Carlson et al., 2015).

In Denmark, 3.8% of 1261 sporadic VS tumors displayed spontaneous shrinkage that started in 3.9 y after diagnosis (Huang et al., 2013). In Finland out of 31 cases with observation, the majority of the patients could live fairly normal lives and required no treatment (Levo et al., 1997).

In Italy that 84 (54.5%) tumors showed no growth, 12 (7.8%) showed slow growth, and 2 (1.3%) tumors showed fast growth during the observation period of 5 years. When the results of “wait and scan” are compared with the literature on radiotherapy, it is possible that a portion of control of tumor by radiotherapy could be attributed to the nature course of VS (Patnaik et al., 2015). In Netherlands, approximately a quarter of the patients had a low risk for growth, which was connected to hearing loss lasting longer than 2 years and an entirely intracanalicular location. The authors suggested that this subgroup of patients does not need regular follow-up with the MRI (Wolbers et al., 2016).

4.3. Growth rate and transition of the management modality

The natural history of VS growth is intangible, in a way that the tumor may grow continuously or only to a certain size, followed by stagnation or even shrinkage. Progressive growth in the cerebellopontine angle would finally lead to compression of the brainstem and/or the cerebellum, occlusion of the fourth ventricle, and subsequently incarceration (Stangerup and Caye-Thomasen, 2012). The VS can be defined as either purely intrameatal or intra-extrameatal, in which tumor extension into the cerebellopontine angle. The size of an intra- and extrameatal tumor is determined by the largest extrameatal diameter, excluding the intrameatal portion (Kanzaki et al., 2003). However, purely extrameatal VSs were very

Table 1
Reports on “wait-and-scan” management for vestibular schwannoma from different countries.

Country	Authors	Start year	Obs period (y)	Cases	NF-2	Reference
USA	Rosenberg	1974	17.2 (Ma)	70	excluded	(Rosenberg, 2000)
	Jethanamest et al.	2002	5.6 (Me)	94	excluded	(Jethanamest et al., 2015)
	Carlson et al.	2004	8	238	unknown	(Carlson et al., 2015)
	Fayad et al.	1988	4.8 (Me), 15.6 (Ma)	114	excluded	(Fayad et al., 2014)
Denmark	Stangerup and Caye-Thomasen	1976	16 (Me)	2500	excluded	(Stangerup and Caye-Thomasen, 2012) ^a
	Huang et al.	1976	9.5 (Me), 27 (Ma)	1261	excluded	(Huang et al., 2013) ^a
Finland	Levo et al.	1981	20	31	included	(Levo et al., 1997)
Italy	Patnaik et al.	1986	3 (Me), 13 (Ma)	576	excluded	(Patnaik et al., 2015)
Australia	Jufas et al.	1994	7.9 (Me), 17.8 (Ma)	145	excluded	(Jufas et al., 2015)
Norway	Breivik et al.	2000	3.6 (Me), 9.6 (Ma)	193	excluded	(Breivik et al., 2012) ^b
	Varughese et al.	2000	5 (Ma)	355	excluded	(Varughese et al., 2012) ^b
Netherlands	Wolbers et al.	2000	6.2 (Me), 14 (Ma)	155	excluded	(Wolbers et al., 2016)
South Korea	Kim et al.	2012	1 (Me & Ma)	34	unknown	(Kim et al., 2015)

Ma: maximum observation period; Me: median time; NF-2: was neurofibromatosis type 2 excluded? Obs: observation.

^a The 2 reports in Denmark were from the same hospital.

^b The 2 reports in Norway were from the same hospital.

rare, although they definitely exist (Jethanamest et al., 2015; Tomogane et al., 2013).

The present judgment for growth of a purely intrameatal tumor was to measure the extrameatal extension. For intra- and extrameatal tumors, an obvious growth was defined as an increase of at least 3 mm in the largest extrameatal diameter, to rule out inter-individual measuring variability and error due to unaligned scanning images. Largest diameter measurement was reported to be adequate when merely evaluating absolute growth (Rosenberg, 2000; Walsh et al., 2000).

Various growth rates were reported by different research groups. In general, VSs grow very slowly but varies in individuals with the annual tumor growth rate varying from 0.4 mm/y to 2.9 mm/y (Yoshimoto, 2005). Even spontaneous shrinkage was observed in 3.8% of tumors, and relative shrinkage was significantly greater for pure intrameatal tumors at diagnosis, compared to intra- and extra-meatal tumors (Huang et al., 2013). Fayad et al. found that 38% of tumors grew with an average of 6.5 mm during the period of 4.8 years at a mean value of 3.1 mm/y (Fayad et al., 2014). Patnaik et al. reported a growth rate of 1.2 ± 2.2 mm/y. The mean growth rate was 1.1 ± 2.2 mm/y in intrameatal tumors and 1.4 ± 2.2 mm/y in extrameatal tumors did not differ significantly. The mean growth rate of cystic tumors was 6.1 ± 3.1 mm/y. The mean growth in patients younger than 40 years was 2.6 ± 3.8 mm, which was faster than that of patients older than 40 years (1.2 ± 2.6 mm).

Varughese et al. compared the growth dynamics of VS patients managed by “wait-and-scan” using a mm/y-based model, a cm^3/y -based model, and a volume doubling time (VDT)-based model. They found that VDT displayed a mean growth rate of 4.4 years (95% CI 3.5–6.0). A cutoff time of 5.2 y provided the best value to distinguish growing from non-growing tumors (Varughese et al., 2012).

How to decide a transition of the management modality from “wait-and-scan”? In general, if significant growth occurs, active treatment is an option. However, some old patients may remain “wait-and-scan” even with obvious growth, and surgery might be performed in patients with stable and small tumors who would insist on primary operation (Stangerup and Caye-Thomasen, 2012).

Active treatment of tumors larger than 15 mm has been suggested, since further growth of the tumor was associated with an increase in operative complications, such as facial paralysis (Tos et al., 1998). Hearing preservation surgery for VS has been intended for more than 40 years (Cohen and Ransohoff, 1984; Wade and House, 1984), and this may influence on treatment decision since preserving hearing is more challenging in surgery of large VS. Sanna et al. reported that hearing preservation in VS is a more difficult proposition than most surgeons appreciate, especially in terms of serviceable hearing (Sanna et al., 2004). Levo et al. has reported that hearing was preserved in 40% of operated patients and, subjectively, the preserved hearing was useful in understanding of speech in 62% of the patients (Levo et al., 2002). These figures may be changing in the future due to increased amount of patients with wait and scan strategy.

It has been published that a VS tumor may grow first and then shrink, and the ‘wait and scan’ strategy might be applied

in VS patients with a largest extrameatal diameter of up to 20 mm (Huang et al., 2013). For example, one of our patients with VS larger than 15 mm had normal facial nerve function and excellent hearing 6 months after tumor removal through retro-sigmoid approach. Perioperative real time auditory brainstem response monitoring demonstrated preserved function after tumor removal (Figs. 1 and 2). This suggests that individual treatment planning is applicable.

5. Contrast MRI

Gadolinium-contrasted MRI has been a standard protocol in diagnosing and following-up VS for decades (Kingsley et al., 1985). Gadolinium-contrast MRI detects VS by demonstrating the uptake of the contrast agent in the tumor through an impaired vasculature barrier resulted from the active angiogenesis of the tumor (Caye-Thomasen et al., 2005; de Vries et al., 2013; Koutsimpelas et al., 2007). However, application of gadolinium-chelate in MRI increases the cost and raises a toxicity issue. The typical toxicity includes cellular impairment by dissociated gadolinium, zinc deficiency, and nephrogenic systemic fibrosis. Replacement of Gd^{3+} within the chelate molecule by body cations leads to free Gd^{3+} release and formation of zinc-chelate that causes zinc deficiency (Idee et al., 2006; Laurent et al., 2001). The released Gd^{3+} may cause nephrogenic systemic fibrosis when the patient has a low renal clearance (Tervahartiala et al., 1991; Thakral et al., 2007; Thomsen, 2004). If patients need multiple scans, the risk of causing nephrogenic systemic fibrosis is higher due to the precipitation with tissue anions in the bone that serves as a site for gadolinium storage (Thakral et al., 2007). This is a critical issue in VS patients with “wait-and-scan” management who needs multiple scans to follow the tumor growth. Therefore, it has been important to develop non-contrast MRI to follow tumor growth in VS patients.

6. Non-contrast MRI

6.1. Sequences of non-contrast MRI

6.1.1. T2-weighted fast spin echo

The 8th cranial nerve is surrounded by cerebrospinal fluid (CSF) which provides a natural contrast for MRI. Therefore, any internal acoustic meatus (IAM) masses will squeeze the adjacent CSF away and produce a hypointense area on T2-weighted MRI. In 1996, Fukui et al. reported the T2-weighted MR characteristics of IAM masses and found that all 50 masses were hypointense relative to CSF on fast spin echo (FSE) images using contrast-enhanced T1-weighted MRI as a reference (Fukui et al., 1996). Five of the 8 small lesions ranged in maximum diameters from 3 to 4 mm were identified with confidence. Even the remaining three smaller (2×2 mm; 3×3 mm; 3×4 mm) lesions displayed hypointense signal when reviewed retrospectively (Fukui et al., 1996). In another observation on 25 patients and 25 control subjects, there was no significant difference between

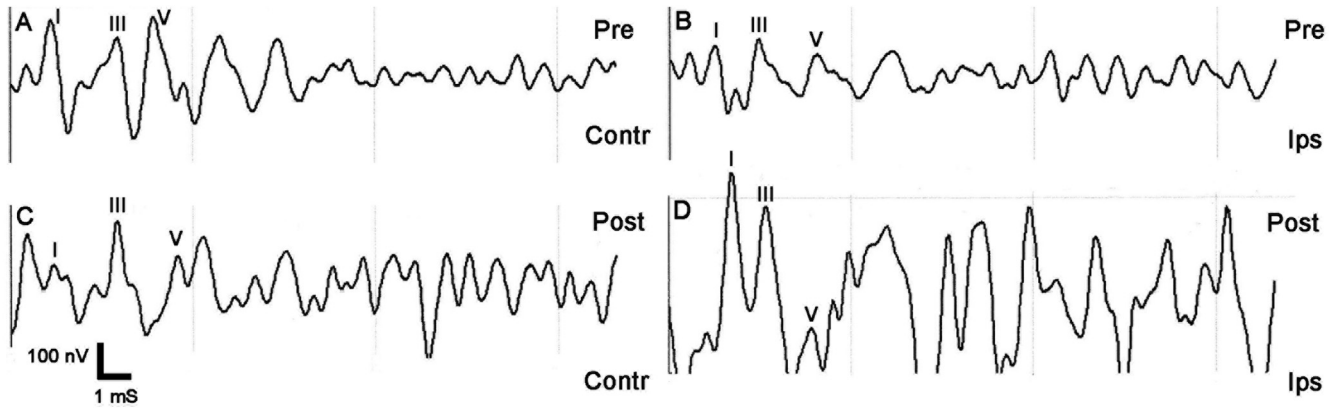


Fig. 1. Real time ABR monitoring of a VS patient (extrameatal diameter of tumor 19 mm) during operation using ISIS IOM system (Inomed, Emmendingen, Germany). A 31 years old man suffered from colitis ulcerosa and was treated with Asacol 800 mg 1 × 2. The patient complained of 2 years hearing loss, tinnitus and imbalance, some vertigo attacks, and MRI revealed abovementioned tumor. Video head impulse test was normal in each horizontal, left anterior-right posterior (LARP) canals or right anterior-left posterior (RALP) canals planes. The ABR on the ipsilateral (Ips) side (B, D) demonstrated even increased amplitude at waveforms I and III immediately after tumor removal comparing to the contralateral (Contr) side (A, C). Post: post-removal; Pre: pre-removal.

non-contrast FSE MRI and contrast-enhanced T1-weighted conventional spin-echo imaging in detection of VSs although 2 lesions measuring <5 mm were missed (Allen et al., 1996).

6.1.2. Sampling perfection with application-optimized contrasts by using flip angle evolution

The sampling perfection with application-optimized contrasts by using flip angle evolution (SPACE) sequence is a proprietary 3D-FSE sequence and is analogous to the VISTA (volume isotropic turbo spin-echo acquisition [Philips Healthcare, Best, the Netherlands]) sequence or Cube sequence (GE Healthcare, Wisconsin, USA) (Mugler, 2014). Recently, Chokshi et al. evaluated cervical spinal MRI anatomy using SPACE sequence, and found that T2-SPACE may

be equivalent or superior to T2-FSE for the evaluation of cervical spine anatomic structures, and T2-SPACE showed a lower degree of CSF pulsation artifact than did the T2-FSE (Chokshi et al., 2017).

6.1.3. 3D constructive interference in the steady state

3D constructive interference in the steady state (CISS) has the advantages of fast acquisition, high spatial resolution, and high contrast-to-noise ratio compared to with 3D T2-weighted MRI (Lane et al., 2004). Casselman et al. reported the first study on imaging the inner ear, cerebellopontine angle, and VSs using CISS sequence as early as 1993 (Casselmann et al., 1993). Using axial CISS and coronal T2-weighted FSE, Abele et al. reported 100% sensitivity, high accuracy and specificity, and excellent inter-observer reliability in detecting small (10 mm or

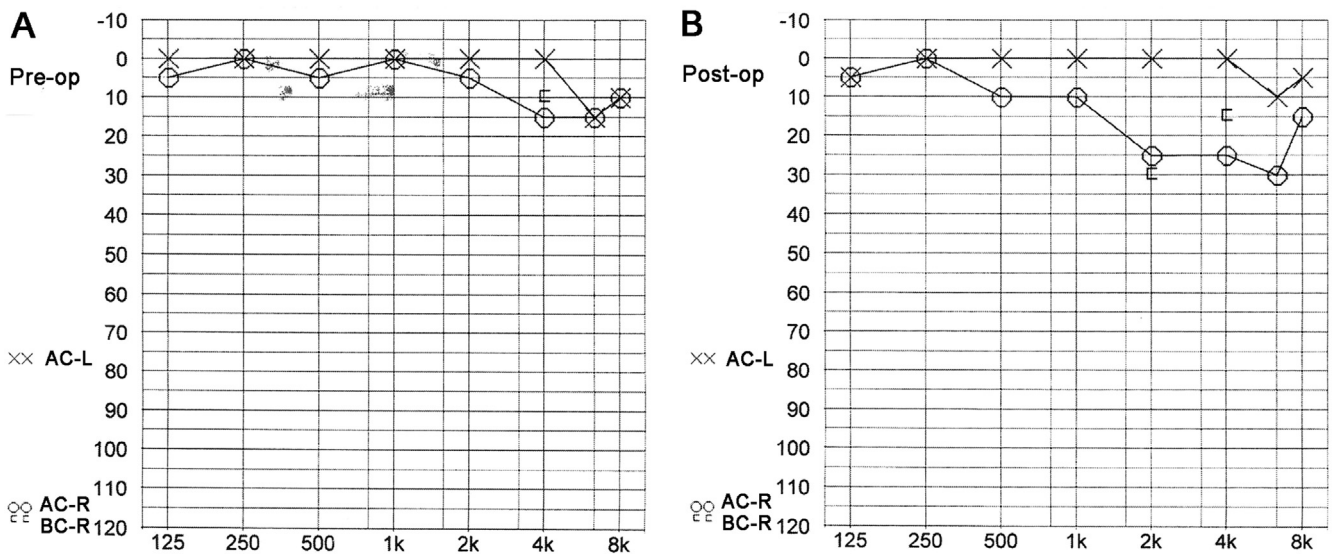


Fig. 2. Audiogram of a VS patient before and 6 months after near total VS resection through a retrosigmoid approach. Before operation (Pre-op), the pure tone audiogram was normal, speech discrimination scores 100%, and speech threshold 0/0 dB (A). Postoperatively (Post-op) there was a mild hearing loss with the PTA of 18 dB, speech discrimination of 100%, and speech threshold of 10 dB (B). AC-L: air conduction of the left ear; AC-R: air conduction of the right ear; BC-R: bone conduction of the right ear.

less) IAM lesions for the purpose of screening VSs (Abele et al., 2014). In the follow-up imaging of VSs, CISS sequence alone showed the sensitivity, specificity, and accuracy for detection of progression to be 100% (Ozgen et al., 2009).

6.1.4. 3D-fast imaging employing steady state acquisition

3D-fast imaging employing steady state acquisition (3D-FIESTA) was recently introduced, and was demonstrated to give significantly higher spatial resolution with outstanding image contrast between the cranial nerves and CSF and has much shorter image acquisition time than conventional MRI scan (Erdogan et al., 2013; Rigby, 2006). Ishikawa et al. reported that 3D-FIESTA was capable of detecting the signal intensity reduction in the inner fluids of patients with VSs in addition to visualize the tumor itself (Ishikawa et al., 2013). The characteristic signal changes in the inner ear fluids were powerful enough to differentiate VSs from meningiomas. They interpret this phenomenon as the result of elevation of protein concentration in the inner perilymph attributed to the blood-inner ear barrier disruption (O'Connor et al., 1981; Silverstein, 1971). From this point of view, 3D-FIESTA sequence seems to be superior to the CISS sequence in depicting the pathological changes associated with VSs. Another possibility is that the authors of using CISS sequence did pay attention to the inner ear signal changes. Actually, there were visible signal intensity decrease in the ipsilateral cochlea and vestibule with lesion on the fundus of IAM, when one carefully checks the CISS images published by the authors (Abele et al., 2014). We have also used 3D-FIESTA in studying the VS (Fig. 3). The inner ear fluids on the ipsilateral side had lower intensities than that on the contralateral side in non-contrast MRI using 3D-FIESTA sequence (Fig. 4).

6.1.5. Sequences for distinguishing VS from meningioma

In addition to VS, meningioma constitutes 10%–15% of cerebellopontine angle (Nakamura et al., 2005). It is important to distinguish VS from meningioma for both “wait-and-scan” management and pre-operative planning due to the different biological behavior and neurologic anatomy. The outcome with

preservation of hearing is significantly better with meningioma than VS (Nakamura et al., 2005). Tumor location is insufficient to distinguish between these two type of tumors because a meningioma may extend to the internal auditory meatus and a VS may appear as pure extrameatal mass (Nakamura et al., 2005; Tomogane et al., 2013). It was reported that approximately 25% of cerebellopontine angle meningiomas were misdiagnosed as VSs (Grey et al., 1996). Microhemorrhage was reportedly a characteristic phenomenon of VS attributed to the expression of thrombomodulin in the endothelial cells, which may play a dominant role in the development of cystic changes in VS (Park et al., 2006; Yamahata et al., 2013). T2*-weighted gradient-echo imaging has been used to detect intratumor microhemorrhage in VS that did not appear in meningioma. It had a sensitivity of 93.8%, specificity and positive predictive value of 100%, and negative predictive value of 83.3%. However, the sample size in that study was rather small (Thamburaj et al., 2008). The principles of echo shifting using a train of observations (PRESTO) MRI was demonstrated to be capable of measuring changes in microscopic magnetic susceptibility effects caused by changes in the amount of paramagnetic deoxyhemoglobin with significantly reduced imaging time (Liu et al., 1993). In addition to all VS, PRESTO MRI revealed spotty signal voids in meningioma suggesting either hemosiderin deposits, or microhemorrhages, or abnormal vessels (Tomogane et al., 2013). Therefore, microhemorrhage is not an absolute specific sign of VS although it appeared more frequently in VS than meningiomas.

6.2. Accuracy and sensitivity of non-contrast MRI

Fortnum et al. reviewed the literature during 1998–2008, and concluded that the specificity of T2WI and T2*WI sequences ranged from 90% to 100% and from 86% to 99% respectively (Fortnum et al., 2009). Afterwards, Abele et al. reported that the accuracy, specificity, and sensitivity for axial CISS alone in detecting VSs were 94%, 92%–96%, and 91%–100% respectively. The data for the coronal T₂WI sequence only were 94%–99%, 96%–100%, and 91%–96%

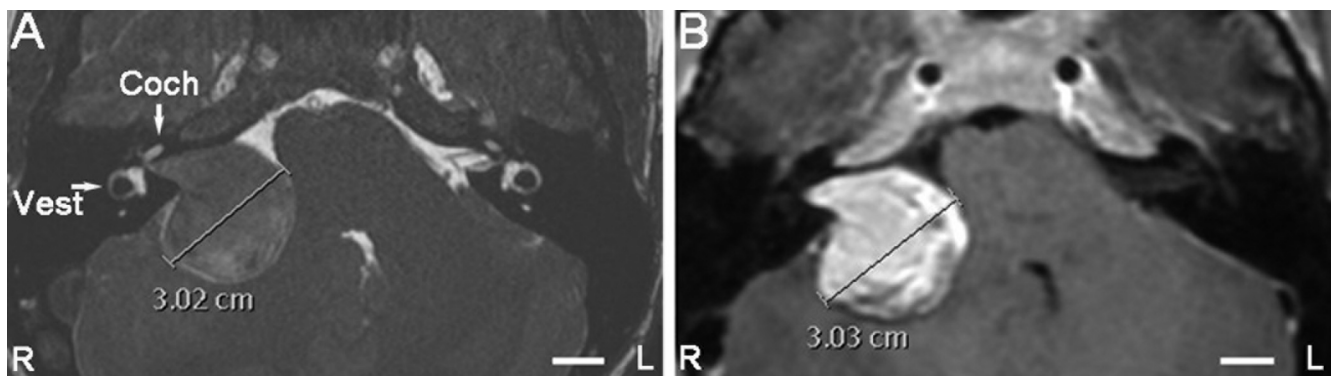


Fig. 3. Comparison of non-contrast and gadolinium-contrasted MRI using a 1.5 T machine at a plane showing the maximum diameter of VS in a patient before operation. Both the inner ear fluids and VS was detected with high resolution in non-contrast MRI using 3D-FIESTA sequence (A). Parameters of 3D-FIESTA sequence are as following: TR 5.776 ms, TE 2.184 ms, flip angle 55°, section thickness 0.5 mm, matrix 512 × 512 × 512. VS but not the inner ear fluids was demonstrated in gadolinium-contrast MRI (B). The non-contrast and gadolinium-contrasted MRI detected the tumor at a similar size. Coch: cochlea; L: left; R: right; Vest: vestibule. Scale bar = 1.0 cm.

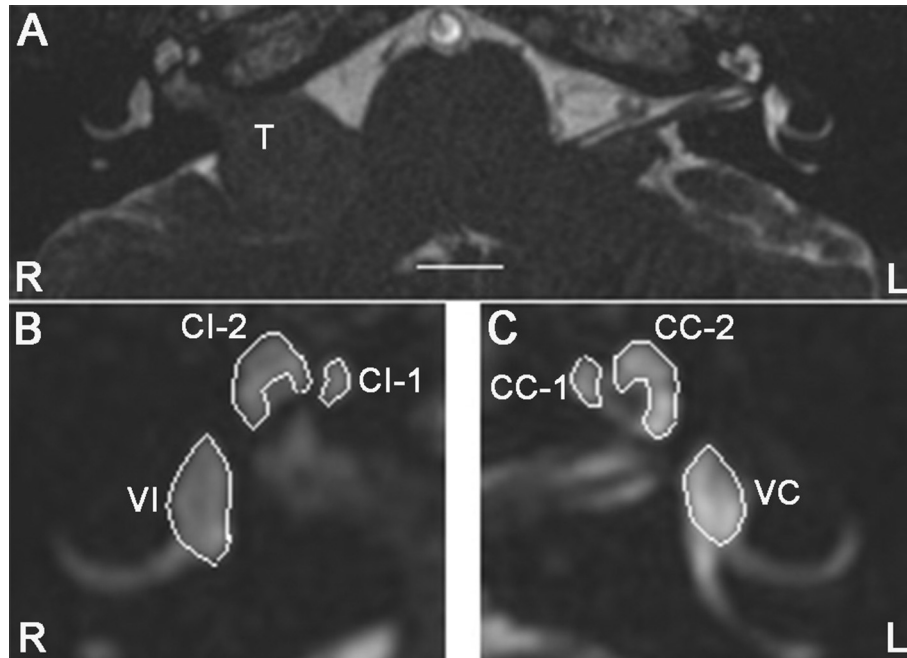


Fig. 4. Comparison of signal intensities in the inner ear fluids between the ipsilateral and contralateral sides in a VS patient before operation. The signal intensities measured in the region of interests using ImageJ 1.50i (NIH, Maryland, USA) were as following: CI-1 = 107; CI-2 = 109; VI = 114; CC-1 = 120; CC-2 = 140; VC = 152. B and C are enlarged windows of the right (R) (B) and left (L) (C) sides of the original image (A). CC-1: cochlear region 1 of the contralateral side; CC-2: cochlear region 2 of the contralateral side; CI-1: cochlear region 1 of the ipsilateral side; CI-2: cochlear region 2 of the ipsilateral side; T: tumor; VC: vestibule of the contralateral side; VI: vestibule of the ipsilateral side. Scale bar = 1.0 cm.

respectively. Using combined axial and coronal sequences, the data were 97%–99%, 96%–98%, and 100% respectively (Abele et al., 2014).

6.3. Advantages and clinical relevance of non-contrast MRI in vestibular schwannoma imaging

Non-contrast MRI of vestibular schwannoma has no risk of causing zinc deficiency, skin ulceration, testicular atrophy, and nephrogenic systemic fibrosis connected to the use of gadolinium-chelate (Ideo et al., 2006; Tervahartiala et al., 1991; Thakral et al., 2007; Thomsen, 2004). In general, non-contrast MRI is faster, cheaper, and safer than the contrast MRI. Attributing to the accuracy, specificity, and sensitivity, non-contrast MRI can replace the contrast MRI in VS imaging.

7. Conclusions

VSs may grow continuously or only to a certain size, followed by stagnation or even shrinkage. In general, the tumors grow slowly and “wait-and-scan” management is suitable for up to 87% of VSs. When the tumor demonstrates a greater than 2 mm linear difference in any plane between the diagnostic MRI scan and the last available scan, the tumor can be considered growing. Taken account the tumor size and other clinical factors the wait-and-scan management can be continued or either microsurgery or stereotactic radiotherapy can be considered. However, stereotactic radiotherapy is unsuitable for cystic VS and the efficacy significantly reduced

when the tumor is growing rapidly. Detailed non-contrast MRI has the potential to replace contrast MRI in diagnosing and following growth of VSs in the future (Abele et al., 2014; Allen et al., 1996; Fortnum et al., 2009; Fukui et al., 1996; Ozgen et al., 2009). Specific sequences of non-contrast MRI may be used to distinguish VSs from meningiomas.

8. Future perspectives of wait-and-scan management and non-contrast MRI

“Wait-and-scan” strategy in VS management should be included in the routine treatment options of VS. A protocol of non-contrast MRI in diagnosing and following VS reduces the risks for complications related to the use of gadolinium.

Conflict of interest

The authors report no conflicts of interest. The authors alone are responsible for the content and writing of the paper.

Ethical approval

According Finnish law, three patients included as examples gave written permission to use their clinical data.

Acknowledgments

This work was supported by the National Natural Science Foundation of China (81170914/H1304).

References

- Abboud, T., Regelsberger, J., Matschke, J., Jowett, N., Westphal, M., Dalchow, C., 2016. Long-term vestibulocochlear functional outcome following retro-sigmoid approach to resection of vestibular schwannoma. *Eur. Arch. Otorhinolaryngol.* 273, 719–725.
- Abele, T.A., Besachio, D.A., Quigley, E.P., Gurgel, R.K., Shelton, C., Harnsberger, H.R., Wiggins 3rd, R.H., 2014. Diagnostic accuracy of screening MR imaging using unenhanced axial CISS and coronal T2WI for detection of small internal auditory canal lesions. *AJNR Am. J. Neuroradiol.* 35, 2366–2370.
- Ahmad, Z., Brown, C.M., Patel, A.K., Ryan, A.F., Ongkeko, R., Doherty, J.K., 2010. Merlin knockdown in human schwann cells: clues to vestibular schwannoma tumorigenesis. *Otol. Neurotol.* 31, 460–466.
- Alattar, A.A., Hirshman, B.R., McCutcheon, B.A., Chen, C.C., Alexander, T., Harris, J., Carter, B.S., 2017. Risk factors for readmission with cerebrospinal fluid leakage within 30 d of vestibular schwannoma surgery. *Neurosurgery*. <http://dx.doi.org/10.1093/neuros/nyx197> [Epub ahead of print].
- Allen, R.W., Harnsberger, H.R., Shelton, C., King, B., Bell, D.A., Miller, R., Parkin, J.L., Apfelbaum, R.I., Parker, D., 1996. Low-cost high-resolution fast spin-echo MR of acoustic schwannoma: an alternative to enhanced conventional spin-echo MR? *AJNR Am. J. Neuroradiol.* 17, 1205–1210.
- Bloch, J., Vernet, O., Aube, M., Villemure, J.G., 2003. Non-obstructive hydrocephalus associated with intracranial schwannomas: hyperproteinorrhachia as an etiopathological factor? *Acta Neurochir. (Wien)* 145, 73–78.
- Blomstedt, G.C., Katila, H., Henriksson, M., Ekholm, A., Jaaskelainen, J.E., Pyykko, I., 1996. Depression after surgery for acoustic neuroma. *J. Neurol. Neurosurg. Psychiatry* 61, 403–406.
- Breivik, C.N., Varughese, J.K., Wentzel-Larsen, T., Vassbotn, F., Lund-Johansen, M., 2012. Conservative management of vestibular schwannoma—a prospective cohort study: treatment, symptoms, and quality of life. *Neurosurgery* 70 (5), 1072–1080 discussion 80.
- Brennan, J.W., Rowed, D.W., Nedzelski, J.M., Chen, J.M., 2001. Cerebrospinal fluid leak after acoustic neuroma surgery: influence of tumor size and surgical approach on incidence and response to treatment. *J. Neurosurg.* 94, 217–223.
- Carlson, M.L., Habermann, E.B., Wagie, A.E., Driscoll, C.L., Van Gompel, J.J., Jacob, J.T., Link, M.J., 2015. The changing landscape of vestibular schwannoma management in the United States — a shift toward conservatism. *Otolaryngol. Head Neck Surg.* 153, 440–446.
- Carlson, M.L., Tveiten, O.V., Driscoll, C.L., Neff, B.A., Shepard, N.T., Eggers, S.D., Staab, J.P., Tombers, N.M., Goplen, F.K., Lund-Johansen, M., Link, M.J., 2014. Long-term dizziness handicap in patients with vestibular schwannoma: a multicenter cross-sectional study. *Otolaryngol. Head Neck Surg.* 151, 1028–1037.
- Carlstrom, L.P., Copeland 3rd, W.R., Neff, B.A., Castner, M.L., Driscoll, C.L., Link, M.J., 2016. Incidence and risk factors of delayed facial palsy after vestibular schwannoma resection. *Neurosurgery* 78, 251–255.
- Casselmann, J.W., Kuhweide, R., Deimling, M., Ampe, W., Dehaene, I., Meeus, L., 1993. Constructive interference in steady state-3DFT MR imaging of the inner ear and cerebellopontine angle. *AJNR Am. J. Neuroradiol.* 14, 47–57.
- Caye-Thomasen, P., Werther, K., Nalla, A., Bog-Hansen, T.C., Nielsen, H.J., Stangerup, S.E., Thomsen, J., 2005. VEGF and VEGF receptor-1 concentration in vestibular schwannoma homogenates correlates to tumor growth rate. *Otol. Neurotol.* 26, 98–101.
- Chihara, Y., Ito, K., Sugawara, K., Shin, M., 2007. Neurological complications after acoustic neurinoma radiosurgery: revised risk factors based on long-term follow-up. *Acta Otolaryngol. Suppl.* 65–70.
- Chokshi, F.H., Sadigh, G., Carpenter, W., Allen, J.W., 2017 Apr. Diagnostic quality of 3D T2-SPACE compared with T2-FSE in the evaluation of cervical spine MRI anatomy. *AJNR Am. J. Neuroradiol.* 38 (4), 846–850.
- Cohen, N.L., Ransohoff, J., 1984. Hearing preservation—posterior fossa approach. *Otolaryngol. Head Neck Surg.* 92, 176–183.
- de Vries, M., Hogendoorn, P.C., Briaire-de Bruyn, I., Malessy, M.J., van der Mey, A.G., 2012. Intratumoral hemorrhage, vessel density, and the inflammatory reaction contribute to volume increase of sporadic vestibular schwannomas. *Virchows Arch.* 460, 629–636.
- de Vries, M., Briaire-de Bruyn, I., Malessy, M.J., de Bruine, S.F., van der Mey, A.G., Hogendoorn, P.C., 2013. Tumor-associated macrophages are related to volumetric growth of vestibular schwannomas. *Otol. Neurotol.* 34, 347–352.
- Erdogan, N., Altay, C., Akay, E., Karakas, L., Uluc, E., Mete, B., Oygen, A., Oyar, O., Gelal, F., Songu, M., Katilmis, H., Calli, C., 2013. MRI assessment of internal acoustic canal variations using 3D-FIESTA sequences. *Eur. Arch. Otorhinolaryngol.* 270, 469–475.
- Fayad, J.N., Semaan, M.T., Lin, J., Berliner, K.I., Brackmann, D.E., 2014. Conservative management of vestibular schwannoma: expectations based on the length of the observation period. *Otol. Neurotol.* 35, 1258–1265.
- Feghali, J.G., Kantrowitz, A.B., 1995. Atypical invasion of the temporal bone in vestibular schwannoma. *Skull Base Surg.* 5, 33–36.
- Fortnum, H., O'Neill, C., Taylor, R., Lenthall, R., Nikolopoulos, T., Lightfoot, G., O'Donoghue, G., Mason, S., Baguley, D., Jones, H., Mulvaney, C., 2009. The role of magnetic resonance imaging in the identification of suspected acoustic neuroma: a systematic review of clinical and cost effectiveness and natural history. *Health Technol. Assess.* 13 iii-iv, ix-xi, 1–154.
- Fukui, M.B., Weissman, J.L., Curtin, H.D., Kanal, E., 1996. T2-weighted MR characteristics of internal auditory canal masses. *AJNR Am. J. Neuroradiol.* 17, 1211–1218.
- Gardner, W.J., Spittler, D.K., Whitten, C., 1954. Increased intracranial pressure caused by increased protein content in the cerebrospinal fluid; an explanation of papilledema in certain cases of small intracranial and intraspinal tumors, and in the Guillain-Barre syndrome. *N. Engl. J. Med.* 250, 932–936.
- Grey, P.L., Moffat, D.A., Hardy, D.G., 1996. Surgical results in unusual cerebellopontine angle tumours. *Clin. Otolaryngol. Allied Sci.* 21, 237–243.
- Hempel, J.M., Hempel, E., Wowra, B., Schichor, C., Muacevic, A., Riederer, A., 2006. Functional outcome after gamma knife treatment in vestibular schwannoma. *Eur. Arch. Otorhinolaryngol.* 263, 714–718.
- Hirvonen, T., Pyykko, I., Juhola, M., Aalto, H., 1995. High frequency deficit of the vestibular system after acoustic neurinoma surgery. *Acta Otolaryngol. Suppl.* 520 (Pt 1), 16–18.
- Hoffman, R.A., 1994. Cerebrospinal fluid leak following acoustic neuroma removal. *Laryngoscope* 104, 40–58.
- Huang, X., Caye-Thomasen, P., Stangerup, S.E., 2013. Spontaneous tumour shrinkage in 1261 observed patients with sporadic vestibular schwannoma. *J. Laryngol. Otol.* 127, 739–743.
- Idee, J.M., Port, M., Raynal, I., Schaefer, M., Le Greneur, S., Corot, C., 2006. Clinical and biological consequences of transmetallation induced by contrast agents for magnetic resonance imaging: a review. *Fundam. Clin. Pharmacol.* 20, 563–576.
- Ishikawa, K., Haneda, J., Okamoto, K., 2013. Decreased vestibular signal intensity on 3D-FIESTA in vestibular schwannomas differentiating from meningiomas. *Neuroradiology* 55, 261–270.
- Jethanamest, D., Rivera, A.M., Ji, H., Chokkalingam, V., Telischi, F.F., Angeli, S.I., 2015. Conservative management of vestibular schwannoma: predictors of growth and hearing. *Laryngoscope* 125, 2163–2168.
- Jorgensen, B.G., Pedersen, C.B., 1994. Acoustic neuroma. Follow-up of 78 patients. *Clin. Otolaryngol. Allied Sci.* 19, 478–484.
- Jufas, N., Flanagan, S., Biggs, N., Chang, P., Fagan, P., 2015. Quality of life in vestibular schwannoma patients managed by surgical or conservative approaches. *Otol. Neurotol.* 36, 1245–1254.
- Kanzaki, J., Tos, M., Sanna, M., Moffat, D.A., Monsell, E.M., Berliner, K.I., 2003. New and modified reporting systems from the consensus meeting on systems for reporting results in vestibular schwannoma. *Otol. Neurotol.* 24, 642–648 (discussion 648–649).
- Khras, T., Romano, G., Sanna, M., 2008. Nerve origin of vestibular schwannoma: a prospective study. *J. Laryngol. Otol.* 122, 128–131.
- Kim, H.J., Jin Roh, K., Oh, H.S., Chang, W.S., Moon, I.S., 2015. Quality of life in patients with vestibular schwannomas according to management strategy. *Otol. Neurotol.* 36, 1725–1729.

- Kingsley, D.P., Brooks, G.B., Leung, A.W., Johnson, M.A., 1985. Acoustic neuromas: evaluation by magnetic resonance imaging. *AJNR Am. J. Neuroradiol.* 6, 1–5.
- Kleijwegt, M., Ho, V., Visser, O., Godefroy, W., van der Mey, A., 2016. Real incidence of vestibular schwannoma? Estimations from a national registry. *Otol. Neurotol.* 37, 1411–1417.
- Koutsimpelas, D., Stripf, T., Heinrich, U.R., Mann, W.J., Brieger, J., 2007. Expression of vascular endothelial growth factor and basic fibroblast growth factor in sporadic vestibular schwannomas correlates to growth characteristics. *Otol. Neurotol.* 28, 1094–1099.
- Kshetry, V.R., Hsieh, J.K., Ostrom, Q.T., Kruchko, C., Barnholtz-Sloan, J.S., 2015. Incidence of vestibular schwannomas in the United States. *J. Neurooncol.* 124, 223–228.
- Lalwani, A.K., Butt, F.Y., Jackler, R.K., Pitts, L.H., Yingling, C.D., 1995. Delayed onset facial nerve dysfunction following acoustic neuroma surgery. *Am. J. Otol.* 16, 758–764.
- Lane, J.L., Ward, H., Witte, R.J., Bernstein, M.A., Driscoll, C.L., 2004. 3-T imaging of the cochlear nerve and labyrinth in cochlear-implant candidates: 3D fast recovery fast spin-echo versus 3D constructive interference in the steady state techniques. *AJNR Am. J. Neuroradiol.* 25, 618–622.
- Laurent, S., Elst, L.V., Copoix, F., Muller, R.N., 2001. Stability of MRI paramagnetic contrast media: a proton relaxometric protocol for transmetallation assessment. *Investig. Radiol.* 36, 115–122.
- Lee, J.D., Park, M.K., Kim, J.S., Cho, Y.S., 2014. The factors associated with tumor stability observed with conservative management of intracanalicular vestibular schwannoma. *Otol. Neurotol.* 35, 918–921.
- Lee, S., Seo, S.W., Hwang, J., Seol, H.J., Nam, D.H., Lee, J.I., Kong, D.S., 2016. Analysis of risk factors to predict communicating hydrocephalus following gamma knife radiosurgery for intracranial schwannoma. *Cancer Med.* 5, 3615–3621.
- Levo, H., Pyykko, I., Blomstedt, G., 1997. Non-surgical treatment of vestibular schwannoma patients. *Acta Otolaryngol. Suppl.* 529, 56–58.
- Levo, H., Blomstedt, G., Pyykko, I., 2000a. Vestibular schwannoma surgery and headache. *Acta Otolaryngol. Suppl.* 543, 23–25.
- Levo, H., Blomstedt, G., Pyykko, I., 2000b. Is hearing preservation worthwhile in vestibular schwannoma surgery? *Acta Otolaryngol. Suppl.* 543, 26–27.
- Levo, H., Pyykko, I., Blomstedt, G., 2000c. Postoperative headache after surgery for vestibular schwannoma. *Ann. Otol. Rhinol. Laryngol.* 109, 853–858.
- Levo, H., Blomstedt, G., Pyykko, I., 2002. Is hearing preservation useful in vestibular schwannoma surgery? *Ann. Otol. Rhinol. Laryngol.* 111, 392–396.
- Linthicum Jr., F.H., Brackmann, D.E., 1980. Bilateral acoustic tumors. A diagnostic and surgical challenge. *Arch. Otolaryngol.* 106, 729–733.
- Liu, G., Sobering, G., Duyn, J., Moonen, C.T., 1993. A functional MRI technique combining principles of echo-shifting with a train of observations (PRESTO). *Magn. Reson. Med.* 30, 764–768.
- Lu, J., Zou, J., Wu, H., Cai, L., 2008. Compensative shuttling of merlin to phosphorylation on serine 518 in vestibular schwannoma. *Laryngoscope* 118, 169–174.
- Lustig, L.R., Jackler, R.K., Chen, D.A., 1995. Contralateral hearing loss after neurotologic surgery. *Otolaryngol. Head Neck Surg.* 113, 276–282.
- Marston, A.P., Jacob, J.T., Carlson, M.L., Pollock, B.E., Driscoll, C.L., Link, M.J., 2016. Pretreatment growth rate as a predictor of tumor control following Gamma Knife radiosurgery for sporadic vestibular schwannoma. *J. Neurosurg.* 1–8.
- Mugler 3rd, J.P., 2014. Optimized three-dimensional fast-spin-echo MRI. *J. Magn. Reson. Imaging* 39, 745–767.
- Myrseth, E., Moller, P., Wentzel-Larsen, T., Goplen, F., Lund-Johansen, M., 2006. Untreated vestibular schwannomas: vertigo is a powerful predictor for health-related quality of life. *Neurosurgery* 59, 67–76 (discussion 67–76).
- Nakamura, M., Roser, F., Dormiani, M., Matthies, C., Vorkapic, P., Samii, M., 2005. Facial and cochlear nerve function after surgery of cerebellopontine angle meningiomas. *Neurosurgery* 57, 77–90 (discussion 77–90).
- O'Connor, A.F., France, M.W., Morrison, A.W., 1981. Perilymph total protein levels associated with cerebellopontine angle lesions. *Am. J. Otol.* 2, 193–195.
- Oh, J.H., Chung, J.H., Min, H.J., Cho, S.H., Park, C.W., Lee, S.H., 2013. Clinical application of 3D-FIESTA image in patients with unilateral inner ear symptom. *Korean J. Audiol.* 17, 111–117.
- Ozgen, B., Oguz, B., Dolgun, A., 2009. Diagnostic accuracy of the constructive interference in steady state sequence alone for follow-up imaging of vestibular schwannomas. *AJNR Am. J. Neuroradiol.* 30, 985–991.
- Pardo-Maza, A., Lassaletta, L., Gonzalez-Otero, T., Roda, J.M., Moraleda, S., Arbizu, A., Gavilan, J., 2016. Evolution of patients with immediate complete facial paralysis secondary to acoustic neuroma surgery. *Ann. Otol. Rhinol. Laryngol.* 125, 495–500.
- Park, C.K., Kim, D.C., Park, S.H., Kim, J.E., Paek, S.H., Kim, D.G., Jung, H.W., 2006. Microhemorrhage, a possible mechanism for cyst formation in vestibular schwannomas. *J. Neurosurg.* 105, 576–580.
- Patnaik, U., Prasad, S.C., Tutar, H., Giannuzzi, A.L., Russo, A., Sanna, M., 2015. The long-term outcomes of wait-and-scan and the role of radiotherapy in the management of vestibular schwannomas. *Otol. Neurotol.* 36, 638–646.
- Rigby, P., 2006. Comparison of FIESTA and gadolinium-enhanced T1-weighted sequences in magnetic resonance of acoustic schwannoma. *Radiographer* 53, 11–21.
- Roche, P.H., Khalil, M., Soumare, O., Regis, J., 2008. Hydrocephalus and vestibular schwannomas: considerations about the impact of gamma knife radiosurgery. *Prog. Neurol. Surg.* 21, 200–206.
- Rodgers, G.K., Luxford, W.M., 1993. Factors affecting the development of cerebrospinal fluid leak and meningitis after translabyrinthine acoustic tumor surgery. *Laryngoscope* 103, 959–962.
- Rogg, J.M., Ahn, S.H., Tung, G.A., Reinert, S.E., Noren, G., 2005. Prevalence of hydrocephalus in 157 patients with vestibular schwannoma. *Neuroradiology* 47, 344–351.
- Rosenberg, S.I., 2000. Natural history of acoustic neuromas. *Laryngoscope* 110, 497–508.
- Sanna, M., Khrais, T., Russo, A., Piccirillo, E., Augurio, A., 2004. Hearing preservation surgery in vestibular schwannoma: the hidden truth. *Ann. Otol. Rhinol. Laryngol.* 113, 156–163.
- Schulze, M., Reimann, K., Seeger, A., Klose, U., Ernemann, U., Hauser, T.K., 2017 Mar. Improvement in imaging common temporal bone pathologies at 3 T MRI: small structures benefit from a small field of view. *Clin. Radiol.* 72 (3), 267.e1–267.e12. <http://dx.doi.org/10.1016/j.crad.2016.11.019>.
- Shuto, T., Matsunaga, S., Suenaga, J., 2011. Contralateral hearing disturbance following posterior fossa surgery. *Neurol. Med. Chir. (Tokyo)* 51, 434–437.
- Silverstein, H., 1971. Inner ear fluid proteins in acoustic neuroma, Meniere's disease and otosclerosis. *Ann. Otol. Rhinol. Laryngol.* 80, 27–35.
- Stangerup, S.E., Caye-Thomasen, P., 2012. Epidemiology and natural history of vestibular schwannomas. *Otolaryngol. Clin. North Am.* 45, 257–268 vii.
- Stangerup, S.E., Caye-Thomasen, P., Tos, M., Thomsen, J., 2008. Change in hearing during 'wait and scan' management of patients with vestibular schwannoma. *J. Laryngol. Otol.* 122, 673–681.
- Stangerup, S.E., Tos, M., Thomsen, J., Caye-Thomasen, P., 2010. Hearing outcomes of vestibular schwannoma patients managed with 'wait and scan': predictive value of hearing level at diagnosis. *J. Laryngol. Otol.* 124, 490–494.
- Steenerson, R.L., Payne, N., 1992. Hydrocephalus in the patient with acoustic neuroma. *Otolaryngol. Head Neck Surg.* 107, 35–39.
- Tallan, E.M., Harner, S.G., Beatty, C.W., Scheithauer, B.W., Parisi, J.E., 1993. Does the distribution of Schwann cells correlate with the observed occurrence of acoustic neuromas? *Am. J. Otol.* 14, 131–134.
- Tervahartiala, P., Kivisaari, L., Kivisaari, R., Virtanen, I., Standertskjold-Nordenstam, C.G., 1991. Contrast media-induced renal tubular vacuolization. A light and electron microscopic study on rat kidneys. *Investig. Radiol.* 26, 882–887.
- Thakral, C., Alhariri, J., Abraham, J.L., 2007. Long-term retention of gadolinium in tissues from nephrogenic systemic fibrosis patient after multiple gadolinium-enhanced MRI scans: case report and implications. *Contrast Media Mol. Imaging* 2, 199–205.
- Thamburaj, K., Radhakrishnan, V.V., Thomas, B., Nair, S., Menon, G., 2008. Intratumoral microhemorrhages on T2*-weighted gradient-echo imaging helps differentiate vestibular schwannoma from meningioma. *AJNR Am. J. Neuroradiol.* 29, 552–557.
- Thomsen, H.S., 2004. Gadolinium-based contrast media may be nephrotoxic even at approved doses. *Eur. Radiol.* 14, 1654–1656.

- Tomogane, Y., Mori, K., Izumoto, S., Kaba, K., Ishikura, R., Ando, K., Wakata, Y., Fujita, S., Shirakawa, M., Arita, N., 2013. Usefulness of PRESTO magnetic resonance imaging for the differentiation of schwannoma and meningioma in the cerebellopontine angle. *Neurol. Med. Chir. (Tokyo)* 53, 482–489.
- Tos, M., Charabi, S., Thomsen, J., 1998. Clinical experience with vestibular schwannomas: epidemiology, symptomatology, diagnosis, and surgical results. *Eur. Arch. Otorhinolaryngol.* 255, 1–6.
- Tveiten, O.V., Carlson, M.L., Goplen, F., Myrseth, E., Driscoll, C.L., Mahesparan, R., Link, M.J., Lund-Johansen, M., 2016. Patient- versus physician-reported facial disability in vestibular schwannoma: an international cross-sectional study. *J. Neurosurg.* 1–10.
- Valvassori, G.E., 1988. Cerebellopontine angle tumors. *Otolaryngol. Clin. North Am.* 21, 337–348.
- Varughese, J.K., Breivik, C.N., Wentzel-Larsen, T., Lund-Johansen, M., 2012. Growth of untreated vestibular schwannoma: a prospective study. *J. Neurosurg.* 116, 706–712.
- Wade, P.J., House, W., 1984. Hearing preservation in patients with acoustic neuromas via the middle fossa approach. *Otolaryngol. Head Neck Surg.* 92, 184–193.
- Walsh, R.M., Bath, A.P., Bance, M.L., Keller, A., Rutka, J.A., 2000. Comparison of two radiologic methods for measuring the size and growth rate of extracanalicular vestibular schwannomas. *Am. J. Otol.* 21, 716–721.
- Warade, A., Chawla, P., Warade, A., Desai, K., 2016. Contralateral hearing loss and facial palsy in an operated case of vestibular schwannoma—case report. *Int. J. Surg. Case Rep.* 29, 47–50.
- Wolbers, J.G., Dallenga, A.H., van Linge, A., Te West, M., Kummer, E.E., Mendez Romero, A., Pauw, B.K., Wieringa, M.H., 2016. Identifying at diagnosis the vestibular schwannomas at low risk of growth in a long-term retrospective cohort. *Clin. Otolaryngol.* 41, 788–792.
- Yamahata, H., Yunoue, S., Tokimura, H., Hanaya, R., Hirano, H., Tokudome, M., Karki, P., Yonezawa, H., Sugata, S., Kawahara, K., Maruyama, I., Arita, K., 2013. Immunohistochemical expression of thrombomodulin in vestibular schwannoma. *Brain Tumor Pathol.* 30, 28–33.
- Yoshimoto, Y., 2005. Systematic review of the natural history of vestibular schwannoma. *J. Neurosurg.* 103, 59–63.
- Zwarthoff, E.C., 1996. Neurofibromatosis and associated tumour suppressor genes. *Pathol. Res. Pract.* 192, 647–657.