

Research

Open Access

## Treatment of dyslipidemia with lovastatin and ezetimibe in an adolescent with cholesterol ester storage disease

Venu T Tadiboyina<sup>1,2</sup>, Dora M Liu<sup>1</sup>, Brooke A Miskie<sup>2</sup>, Jian Wang<sup>2</sup> and Robert A Hegele\*<sup>1,2</sup>

Address: <sup>1</sup>Department of Medicine, Schulich School of Medicine and Dentistry, University of Western Ontario, London, ON, N6A 5C1, Canada and <sup>2</sup>Vascular Biology Group and Blackburn Cardiovascular Genetics, Laboratory, Robarts Research Institute, London, ON, N6A 5K8, Canada

Email: Venu T Tadiboyina - vtadoboy@uwo.ca; Dora M Liu - doralu@hotmail.com; Brooke A Miskie - bmiskie@robarts.ca; Jian Wang - jwang@robarts.ca; Robert A Hegele\* - hegele@robarts.ca

\* Corresponding author

Published: 28 October 2005

Received: 08 October 2005

*Lipids in Health and Disease* 2005, 4:26 doi:10.1186/1476-511X-4-26

Accepted: 28 October 2005

This article is available from: <http://www.lipidworld.com/content/4/1/26>

© 2005 Tadiboyina et al; licensee BioMed Central Ltd.

This is an Open Access article distributed under the terms of the Creative Commons Attribution License (<http://creativecommons.org/licenses/by/2.0>), which permits unrestricted use, distribution, and reproduction in any medium, provided the original work is properly cited.

### Abstract

**Background:** Cholesterol ester storage disease (CESD) is an autosomal recessive illness that results from mutations in the *LIPA* gene encoding lysosomal acid lipase. CESD patients present in childhood with hepatomegaly and dyslipidemia characterized by elevated total and low-density lipoprotein cholesterol (LDL-C), with elevated triglycerides and depressed high-density lipoprotein cholesterol (HDL-C). Usual treatment includes a low fat diet and a statin drug.

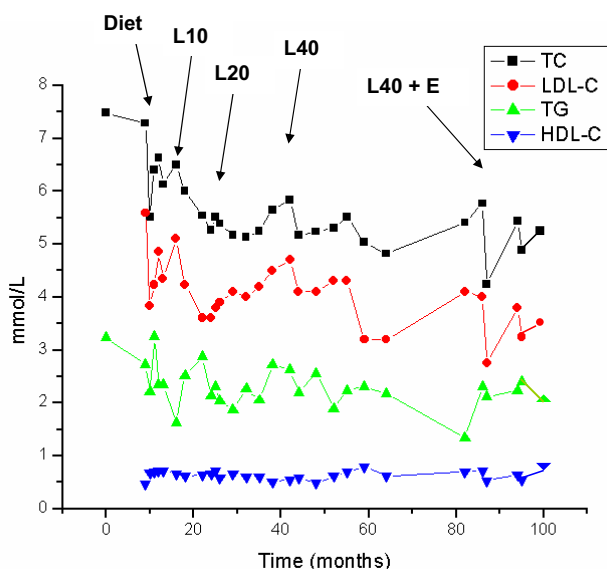
**Results:** In an 18-year old with CESD, we documented compound heterozygosity for two *LIPA* mutations: a novel frameshift nonsense mutation and a deletion of exon 8. The patient had been treated with escalating doses of lovastatin for ~80 months, with ~15% decline in mean LDL-C. The addition of ezetimibe 10 mg to lovastatin 40 mg resulted in an additional ~16% decline in mean LDL-C.

**Conclusion:** These preliminary anecdotal findings in a CESD patient with novel *LIPA* mutations support the longer term safety of statins in an adolescent patient and provide new data about the potential efficacy and tolerability of ezetimibe in this patient group.

### Background

Cholesteryl ester storage disease (CESD; MIM 278000) is an autosomal recessive disorder caused by a deficiency of lysosomal acid lipase (LAL; acid cholesteryl hydrolase; EC 3.1.1.13). LAL is responsible for the intralysosomal hydrolysis of cholesteryl esters (CE) and triglycerides (TG) [1]. Patients with CESD present in childhood with hepatomegaly, hypercholesterolemia and hypertriglyceridemia; most are diagnosed by age 20 [1]. Reduced LAL activity is detectable in peripheral blood leukocytes, cultured skin fibroblasts and liver homogenates [1]. More

recently mutational screening of the human LAL gene (*LIPA*) [2-4] has been used for diagnosis. Wolman disease (WD; MIM 278000) also results from mutations in *LIPA*. WD is characterized by early death (usually before age 6 months) and widespread intracellular storage of both CE and TG, mainly in liver, adrenal glands and intestine [1]. *In vitro* catalytic activity was decreased ~200-fold in WD fibroblasts, but only ~50-fold in CESD fibroblasts [5], showing correlation with the differences in phenotypic severity [6,7].



**Figure 1**  
**Plasma lipoprotein responses to treatment.** The graph shows plasma lipoproteins measured serially in the proband over ~96 months. Abbreviations: TC, total cholesterol; LDL-C, low-density lipoprotein cholesterol; TG, triglycerides; HDL-C, high-density lipoprotein cholesterol; Diet, fat restricted to 30% of total calories, L10, L20 and L40 for lovastatin 10, 20 and 40 mg daily, respectively; E, ezetimibe 10 mg daily.

Defective LAL activity results in decreased free intracellular cholesterol [6,7]. Because intracellular free cholesterol normally inhibits 3-hydroxy-3-methylglutaryl-CoA (HMG-CoA) reductase, cholesterol biosynthesis is increased in CESD patients. Thus, pharmacological inhibition of HMG-CoA reductase with statins would seem to be a reasonable approach to restrain the increased cholesterol biosynthesis in CESD. While the plasma lipoprotein response to statins among CESD patients has been variable [8-14], these drugs are considered to be the anti-dyslipidemia agents of choice in CESD.

Ezetimibe is a novel type of lipid-lowering medication that prevents the absorption of cholesterol and plant sterols at the small intestinal brush border by interfering with the activity of the *NPC1L1* receptor [15-18]. Ezetimibe has been used in adult hypercholesterolemic patients either as monotherapy [19] or in combination with statins [20-25]. The rates of myopathy and serum transaminase elevations in ezetimibe-treated patients appeared to be comparable to those in placebo-treated patients [19-25]. We now present our experience with the combination of lovastatin and ezetimibe treatment in an 18 year old male with CESD.

## Results

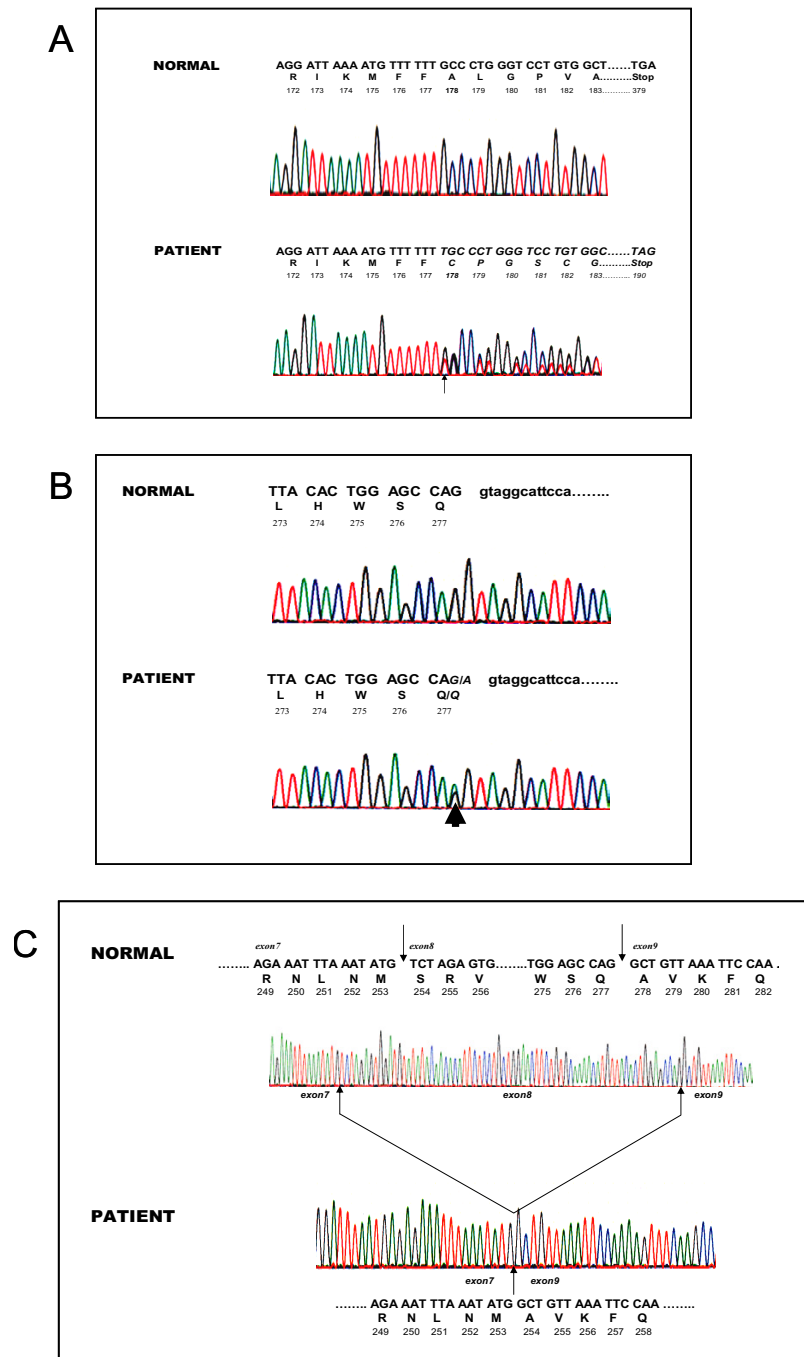
### Patient history

A three-year old boy presented to his paediatrician for assessment of a pruritic abdominal rash. His birth and infancy had been unremarkable, with normal growth and development. There was no consanguinity; both parents and two older sisters were all healthy. At age 3, hepatosplenomegaly was noted on abdominal examination and was confirmed by ultrasound. No diagnosis was made and he was monitored periodically. At age 8, he was admitted to the hospital with gastroenteritis. Light microscopy of a liver biopsy showed increased intracytoplasmic glycogen and small lipid droplets in hepatocytes. Electron microscopy showed membrane-bound lipid droplets with small electron dense granules. A working diagnosis of glycogen storage disease type III (DeBrancher disease) was made, but skin fibroblast Debrancher activity was normal.

At age 10, hepatomegaly persisted and a second liver biopsy was taken. Light microscopy showed altered lobular architecture of the hepatic parenchyma with distended hepatocytes containing cytoplasmic granules and vacuoles with mild periportal fibrosis. Fibroblast acid lipase activity was found to be 7% of normal, confirming the diagnosis of CESD. Plasma concentrations of total cholesterol (TC), triglycerides (TG), low-density lipoprotein cholesterol (LDL-C) were each above the 95<sup>th</sup> percentile for age and sex at 7.49, 3.23 and 5.59 mmol/L, respectively, while plasma high-density lipoprotein cholesterol (HDL-C) was below the 5<sup>th</sup> percentile at 0.46 mmol/L; he had combined hyperlipidemia (hypercholesterolemia, hypertriglyceridemia, hypoalphalipoproteinemia and hyperbetalipoproteinemia). After 12 months, a low fat diet was started (Figure 1).

After 6 months of diet alone, lovastatin 10 mg daily was added. Because of rising plasma concentrations of TC and LDL-C, the dose of lovastatin was increased to 20 mg after ~22 months and increased again to 40 mg after a further ~8 months. Ezetimibe 10 mg per day was added after a further ~40 months and the combination of lovastatin 40 mg and ezetimibe 10 mg daily has continued for 12 months. Serum asparagine transaminase (AST) and creatine kinase (CK) were measured concurrently with the lipoproteins.

The proband's lipoprotein profile since age 10 is summarized in Figure 1. Mean  $\pm$  standard deviation (SD) lipoprotein concentrations on each phase of treatment were determined from a minimum of three values. From baseline concentrations, the diet was associated with a 5.3% decrease in TC ( $6.67 \pm 0.79$  to  $6.32 \pm 0.26$  mmol/L), a 27.3% decrease in TG ( $2.75 \pm 0.48$  to  $1.99 \pm 0.50$  mmol/L), a 2.2% increase in LDL-C ( $4.63 \pm 0.77$  to  $4.73 \pm 0.53$  mmol/L), a 7.8% increase in HDL-C ( $0.64 \pm 0.12$  to  $0.69$



**Figure 2**  
**Nucleotide sequence analysis of *LIPA*.** The nucleotide sequences, codon numbers, single letter amino acid codes for the deduced protein sequence are shown in each panel. Panel A shows normal *LIPA* genomic sequence above and the sequence from the proband's genomic DNA below. The inserted nucleotide is indicated by the arrow and the shifted reading frame is suggested by the presence of two peaks at each position following the insertion. Panel B shows normal *LIPA* genomic sequence above and the sequence from the proband's genomic DNA below, with abnormal sequence italicized. The single base nonsense mutation is indicated by the arrow. Panel C shows normal *LIPA* cDNA sequence from a single copy cloned source derived from a normal individual, spanning part of exon 7, all of exon 8 and then part of exon 9. The lower part of the panel shows the cDNA sequence for one of the proband's alleles, in which exon 8 has been deleted in frame. This confirms that the mutation at the intron-exon boundary of exon 8 affected RNA splicing.

$\pm 0.04$  mmol/L), and a decrease in TC:HDL-C ratio of 11.5% ( $10.4 \pm 0.3$  to  $9.2 \pm 0.5$ ). When pooled data over  $\sim 70$  months from all 19 determinations on lovastatin were compared with diet alone, statin treatment was associated with a further 13.5% decrease in TC (to  $5.47 \pm 0.42$  mmol/L), a 12.6% increase in TG (to  $2.24 \pm 0.36$  mmol/L), a 15.9% decrease in LDL-C (to  $3.98 \pm 0.41$  mmol/L), an 8.7% decrease in HDL-C (to  $0.63 \pm 0.08$  mmol/L), and a 5.5% decrease in TC:HDL-C ratio (to  $8.7 \pm 0.2$ ). Finally, when pooled data over 12 months from all four determinations on ezetimibe plus lovastatin were compared with lovastatin monotherapy, the drug combination was associated with a further 9.4% decrease in TC (to  $4.96 \pm 0.60$  mmol/L), a 3.1% decrease in TG (to  $2.17 \pm 0.20$  mmol/L), an 15.8% decrease in LDL-C (to  $3.35 \pm 0.46$  mmol/L), no change in HDL-C ( $0.63 \pm 0.08$  mmol/L), and a 9.1% decrease in TC:HDL-C ratio (to  $7.9 \pm 0.3$ ). Unpaired t-tests showed that the TC and LDL-C concentrations were significantly different for the period with lovastatin monotherapy compared to the period with combination therapy ( $P < 0.05$ ). Also, there were no deviations of plasma CK and AST above the upper limit of normal for any treatment period. Finally, liver and spleen size evaluated clinically were reduced compared to baseline over the treatment period with statin and then later statin plus ezetimibe; specifically, while the liver edge was palpable 5 cm below the right costal margin before drug treatment it was not palpable at the most recent clinical assessment.

#### Molecular genetic studies

Genomic DNA sequencing of the LIPA gene revealed that the proband had two mutations (Figure 2). The first was a T insertion in exon 6 at codon 178 that shifted the reading frame (Figure 2A) and caused a premature termination at codon 190 (FS A178-X190). The second was G>A change at the last nucleotide of exon 8 (Q277), which resulted in a silent mutation at the amino acid level (Figure 2B). The patient was heterozygous for both mutations. In order to determine the chromosomal phase of the two LIPA mutations, sequencing of exon 6 and exon 8 from the proband's mother's genomic DNA revealed that she was a simple heterozygote for the frameshift mutation, confirming that the two mutations in the proband were on different chromosomes. Reverse transcriptase PCR amplification of LIPA from the proband, followed by sequence analysis of the partial cDNA spanning exon 5 through exon 10 revealed an abnormal sequence in which the entire exon 8 had been deleted (Figure 2C).

#### Discussion

The untreated lipoprotein profile of our CESD patient revealed not only a combined hypercholesterolemia and hypertriglyceridemia, but also a severe hypoalphalipoproteinemia, indicating that mutations in *LIPA* are a rare genetic cause of complex dyslipidemia. Of course, this is

in the context of numerous systemic abnormalities, specifically hepatomegaly. We also showed improvement of the plasma lipoprotein profile with low fat diet, with further improvement with statin monotherapy and even further improvement with the addition of ezetimibe in combination with the statin.

Lovastatin has been shown to be safe and effective in treating hypercholesterolemia over the long term in adults [26,27]. The  $\sim 80$  month treatment period for our proband was among the longest time spans for any of our young patients with respect to duration of statin therapy. Over this period, the patient's hepatomegaly improved clinically and the AST and CK have remained stable. The addition of ezetimibe was associated with further improvement of plasma lipoproteins, and was also well tolerated in combination with statin treatment.

Statins have previously been successfully used in adolescents with CESD with some variability in reported efficacy [8-14]. This may be explained by genetic heterogeneity in response to lovastatin or by underlying differences in the factors responsible for the hyperlipidemia [3]. Statins block the conversion of 3-hydroxymethylglutaryl-coenzyme A (HMGCoA) to mevalonate, a rate limiting step in cholesterol biosynthesis. This results in an increase in the number and activity of LDL receptors on the hepatocyte membrane, and the rate of LDL catabolism increases. In patients with CESD, the increased activity of the LDL receptors theoretically could lead to increased accumulation of cholesteryl esters in the liver [4]. However, Ginsberg *et al.* [2] showed no change in hepatic cholesteryl ester accumulation after 8 months of lovastatin 40 mg daily in a 9 year old girl with CESD. Furthermore, our patient had reduced hepatomegaly clinically, suggesting that cholesteryl ester accumulation in the liver was unlikely.

Our findings also suggest that ezetimibe may be a useful treatment in patients with CESD. Ezetimibe interferes with the normal function of the *NPC1L1* gene product, which regulates sterol absorption in the small intestine [15-17]. This is thought to result in depletion of hepatic cholesterol and upregulation of hepatic LDL receptors. The mean plasma LDL-C reduction seen with ezetimibe is  $\sim 20\%$ , and this has been remarkably consistent across patient subgroups defined by age, gender, ethnic background and concomitant use of other lipid regulating agents, such as statin drugs [20-25]. Inter-individual genetic variation may also play a role in the response to ezetimibe; for instance, a subset of individuals with a particular *NPC1L1* haplotype appears to have a larger plasma LDL-C response [28]. Combination therapy for hypercholesterolemia may allow more patients to achieve target plasma TC and LDL-C goals. We observed that coadmin-

**Table 1: Primers used to amplify coding regions of LIPA**

Exon	Primer sequences
1	Forward: 5' AGC GCT AAA CAG CTT GCT AG Reverse: 5' CTT GCT GAA GGC ACC AGC
2	Forward: 5' GGC TGG AGT CAT TTG TTT CA Reverse: 5' AGA ATC ACT TGA GCC CCT GA
3	Forward: 5' GCC TGG AGA ACA TAG TTT ATC TGC Reverse: 5' TTA GAT GAC TCT TGT CCT TAC TTC
4	Forward: 5' ATG TGA GTA CAT CAC TAT GTC Reverse: 5' CTC ATA CAA CTT CAG AGT TAC
5	Forward: 5' TTC CCA GCT GTG TTT AGT TTG TG Reverse: 5' GAC TAA ATG TTA CCA ACA TTC C
6	Forward: 5' GTG TTA GGG CAC ACG GAA GT Reverse: 5' GTG TGC AGG AAA CGA CAG G
7	Forward: 5' GCA TCC TGA TTT GAT GTC CA Reverse: 5' CAT AAG AAG GTG ACC ACA GTC AG
8	Forward: 5' TGG CTC TAG TTT TTA GTG CTT TGA Reverse: 5' GGA CTC TGG GGA AGA AAA CC
9	Forward: 5' TTC TGT GTC AGG TGG TAG CTG Reverse: 5' TGG ACT GAT GGA AAA CAA ACA
10	Forward: 5' CTC CAC AGC TAG TGG CGA TT Reverse: 5' CAC ACA ATT CTT TGG GCC TAT

istration of ezetimibe with lovastatin resulted in reduction in plasma LDL-C concentration of 16% compared to lovastatin alone. Ezetimibe appeared to be well tolerated by our patient and there were no reported adverse effects. Ezetimibe added to lovastatin did not result in an increase in muscle enzymes. In fact, serum CK (mean  $\pm$  SD) actually decreased from  $185 \pm 156$  with statin monotherapy to  $120 \pm 68$  during combination treatment with the statin and ezetimibe. AST levels never exceeded the upper limit of normal at any time. The complementary mechanism of action of ezetimibe and statins may offer a new treatment alternative for dyslipidemia management in CESD patients.

## Methods

### Genomic DNA analysis

Genomic DNA was isolated from whole blood obtained from patients (Puregene, GentraSystem, Minneapolis, MN). The entire coding region and intron-exon boundaries of LAL gene were amplified using custom primer pairs shown in table 1. PCR amplifications were carried out in a 50  $\mu$ l mixture containing 32 pmole of each primer, 0.2 mM of each dATP, dCTP, dGTP and dTTP, 1.5 mM MgCl<sub>2</sub>, 50 mM KCl, 20 mM Tris-HCl (pH 8.4), 2.5 units of Taq

platinum DNA polymerase (Invitrogen, Mississauga, ON). 30 cycles were performed consisting of denaturation at 94 °C, annealing at 56 °C and extension at 72 °C for 30 s each, followed by extension for 10 min at 72 °C. PCR products were purified from agarose (QIAQuick Gel Extraction Kit, Qiagen, Mississauga, ON). Direct DNA sequence results were analyzed with an ABI automated sequencer 3730 and were read with ABI Sequence Navigator software (both from PE Biosystems, Mississauga, ON).

### Reverse transcriptase polymerase chain reaction and cDNA sequence analysis

Total RNA was isolated from the proband using PAXgene Blood RNA Tube and Blood RNA Kit (Qiagen, Mississauga, ON). 2.5 ml blood was used for RNA isolation according to manufacturer's instruction. 100 ng of total RNA was used for first strand cDNA synthesis (SuperScript First Strand Synthesis System, Invitrogen, Mississauga, ON). 2  $\mu$ l of first strand reaction was used for amplify partial cDNA sequence of the LIPA gene spanning exon 5 to 10 with primer pair 5' AAT ATG ACC TAC CAG CTT CCA, 3' GTA AGC AAA CAC ATT TTC ACA. PCR products were gel purified, sequenced and read as described above.

### Authors' contributions

VT: data analysis, manuscript preparation and approval

DML: data analysis, manuscript preparation, manuscript approval

BAM: data collection, patient interaction, manuscript approval

JW: sequencing, data analysis, editing, manuscript approval

RAH: experimental design, manuscript preparation and approval

### Acknowledgements

Supported by the Jacob J. Wolfe Distinguished Medical Research Chair, the Edith Schulich Vinet Canada Research Chair (Tier I) in Human Genetics, a Career Investigator award from the Heart and Stroke Foundation of Ontario, and operating grants from the Canadian Institutes for Health Research, the Heart and Stroke Foundation of Ontario, the Ontario Research and Development Challenge Fund (Project #0507) and by Genome Canada. The first author was supported by a grant from the Summer Research Training Program (S RTP) from the Schulich School of Medicine and Dentistry, University of Western Ontario.

### References

- Schmitz G, Assmann G: Acid lipase deficiency. In *The Metabolic Basis of Inherited Disease* Edited by: Scriver CR, Sly WS, Valle D. New York: McGraw Hill; 1989:1623-1644.
- Anderson RA, Sando GN: **Cloning and expression of cDNA encoding human lysosomal acid lipase/cholesteryl ester hydrolase: similarities to gastric and lingual lipases.** *J Biol Chem* 1991, **266**:22479-22484.

3. Koch G, Lalley PA, McAvoy M, Shows TB: **Assignment of LIPA, associated with human acid lipase deficiency, to human chromosome 10 and comparative assignment to mouse chromosome 19.** *Somatic Cell Genet* 1981, **7**:345-358.
4. Anderson RA, Rao N, Byrum RS, Rothschild CB, Bowden DW, Hayworth R, Pettenati M: **In situ localization of the genetic locus encoding the lysosomal acid lipase/cholesteryl esterase (LIPA) deficient in Wolman disease to chromosome 10q23.2-q23.3.** *Genomics* 1993, **15**:245-247.
5. Burton BK, Reed SP: **Acid lipase cross-reacting material in Wolman disease and cholesterol ester storage disease.** *Am J Hum Genet* 1981, **33**:203-208.
6. Aslanidis C, Ries S, Fehring P, Buchler C, Klima H, Schmitz G: **Genetic and biochemical evidence that CESD and Wolman disease are distinguished by residual lysosomal acid lipase activity.** *Genomics* 1996, **33**:85-93.
7. Ries S, Aslanidis C, Fehring P, Carel JC, Gendrel D, Schmitz G: **A new mutation in the gene for lysosomal acid lipase leads to Wolman disease in an African kindred.** *J Lipid Res* 1996, **37**:1761-1765.
8. Ginsberg HN, Le NA, Short MP, Ramakrishnan R, Desnick RJ: **Suppression of apolipoprotein B production during treatment of cholesteryl ester storage disease with lovastatin: implications for regulation of apolipoprotein B synthesis.** *J Clin Invest* 1987, **80**:1692-1697.
9. Tarantino MD, McNamara DJ, Granstrom P, Ellefson RD, Unger EC, Udall JN Jr: **Lovastatin therapy for cholesterol ester storage disease in two sisters.** *J Pediatr* 1991, **118**:131-135.
10. Glueck CJ, Lichtenstein P, Tracy T, Speirs J: **Safety and efficacy of treatment of pediatric cholesteryl ester storage disease with lovastatin.** *Pediatr Res* 1992, **32**:559-565.
11. Levy R, Ostlund RE Jr, Schonfeld G, Wong P, Semenkovich CF: **Cholesteryl ester storage disease: complex molecular effects of chronic lovastatin therapy.** *J Lipid Res* 1992, **33**:1005-1015.
12. Leone L, Ippoliti PF, Antonicelli R: **Use of simvastatin plus cholestyramine in the treatment of lysosomal acid lipase deficiency.** *J Pediatr* 1991, **119**:1008-1009.
13. Rassoul F, Richter V, Lohse P, Naumann A, Purschwitz K, Keller E: **Long-term administration of the HMG-CoA reductase inhibitor lovastatin in two patients with cholesteryl ester storage disease.** *Int J Clin Pharmacol Ther* 2001, **39**:199-204.
14. Di Bisceglie AM, Ishak KG, Rabin L, Hoeg JM: **Cholesteryl ester storage disease: hepatopathology and effects of therapy with lovastatin.** *Hepatology* 1990, **11**:764-772.
15. Altmann SW, Davis HR Jr, Zhu LJ, Yao X, Hoos LM, Tetzloff G, Iyer SP, Maguire M, Golovko A, Zeng M, et al.: **Niemann-Pick C1 Like I protein is critical for intestinal cholesterol absorption.** *Science* 2004, **303**:1201-1204.
16. Smart EJ, De Rose RA, Farber SA: **Annexin 2-caveolin I complex is a target of ezetimibe and regulates intestinal cholesterol transport.** *Proc Natl Acad Sci USA* 2004, **101**:3450-3455.
17. Garcia-Calvo M, Lisnock J, Bull HG, Hawes BE, Burnett DA, Braun MP, Crona JH, Davis HR Jr, Dean DC, Detmers PA, Graziano MP, Hughes M, Macintyre DE, Ogawa A, O'Neill KA, Iyer SP, Shevell DE, Smith MM, Tang YS, Makarewicz AM, Ujjainwalla F, Altmann SW, Chapman KT, Thornberry NA: **The target of ezetimibe is Niemann-Pick C1-Like I (NPC1L1).** *Proc Natl Acad Sci USA* 2005, **102**:8132-8137.
18. Kosoglou T, Statkevich P, Johnson-Levonas AO, Paolini JF, Bergman AJ, Alton KB: **Ezetimibe: a review of its metabolism, pharmacokinetics and drug interactions.** *Clin Pharmacokinet* 2005, **44**:467-494.
19. Knopp RHGH, Truitt T, Lipka LJ, LeBeaut AP, Suresh R, Veltri EP: **Ezetimibe reduces low-density lipoprotein cholesterol: results of a phase III, randomized, double blind, placebo-controlled trial.** *Atherosclerosis* 2001, **2**:38.
20. Davidson MH, McGarry T, Bettis R, Melani L, Lipka LJ, LeBeaut AP, Suresh R, Sun S, Veltri EP: **Ezetimibe coadministered with simvastatin in patients with primary hypercholesterolemia.** *J Am Coll Cardiol* 2002, **40**:2125-2134.
21. Ballantyne CM, Houry J, Notarbartolo A, Melani L, Lipka LJ, Suresh R, Sun S, LeBeaut AP, Sager PT, Veltri EP: **Effect of ezetimibe coadministered with atorvastatin in 628 patients with primary hypercholesterolemia: a prospective, randomized, double-blind trial.** *Circulation* 2003, **107**:2409-2415.
22. Kerzner B, Corbelli J, Sharp S, Lipka LJ, Melani L, LeBeaut A, Suresh R, Mukhopadhyay P, Veltri EP: **Efficacy and safety of ezetimibe coadministered with lovastatin in primary hypercholesterolemia.** *Am J Cardiol* 2003, **91**:418-424.
23. Dujovne CA, Ettinger MP, McNeer JF, Lipka LJ, LeBeaut AP, Suresh R, Yang B, Veltri EP: **Efficacy and safety of a potent new selective cholesterol absorption inhibitor, ezetimibe, in patients with primary hypercholesterolemia.** *Am J Cardiol* 2002, **90**:1092-1097.
24. Knopp RH, Gitter H, Truitt T, Bays H, Manion CV, Lipka LJ, LeBeaut AP, Suresh R, Yang B, Veltri EP: **Effects of ezetimibe, a new cholesterol absorption inhibitor, on plasma lipids in patients with primary hypercholesterolemia.** *Eur Heart J* 2003, **24**:729-741.
25. Melani L, Mills R, Hassman D, Lipetz R, Lipka L, LeBeaut A, Suresh R, Mukhopadhyay P, Veltri E: **Efficacy and safety of ezetimibe coadministered with pravastatin in patients with primary hypercholesterolemia: a prospective, randomized, double-blind trial.** *Eur Heart J* 2003, **24**:717-728.
26. Bradford RH, Shear CL, Chremos AN, Franklin FA, Nash DT, Hurley DP, Dujovne CA, Pool JL, Schnaper H, Hesney M: **Expanded clinical evaluation of lovastatin (EXCEL) study results: III. Efficacy in modifying lipoproteins and implications for managing patients with moderate hypercholesterolemia.** *Am J Med* 1991, **91**:18S-24S.
27. Mantell G: **Lipid lowering drugs in atherosclerosis: the HMG-CoA reductase inhibitors.** *Clin Exp Hypertens* 1989, **11**:927-941.
28. Hegele RA, Guy J, Ban MR, Wang J: **NPC1L1 haplotype is associated with inter-individual variation in plasma low-density lipoprotein response to ezetimibe.** *Lipids Health Dis* 2005, **4**:16.

Publish with **BioMed Central** and every scientist can read your work free of charge

"BioMed Central will be the most significant development for disseminating the results of biomedical research in our lifetime."

Sir Paul Nurse, Cancer Research UK

Your research papers will be:

- available free of charge to the entire biomedical community
- peer reviewed and published immediately upon acceptance
- cited in PubMed and archived on PubMed Central
- yours — you keep the copyright

Submit your manuscript here:  
[http://www.biomedcentral.com/info/publishing\\_adv.asp](http://www.biomedcentral.com/info/publishing_adv.asp)

