

Case report: Percutaneous treatment of multiple honeycomb-like liver hydatid cysts (type III CE2, according to WHO classification)

Mario Corona, Alessandro Cannavale, Antonio Bruni, Emanuele Boatta, Massimiliano Allegritti, Pierleone Lucatelli, Fabrizio Fanelli, Armando Pucci, Carolina Paciotti¹, Filippo Maria Salvatori

Department of Radiology, Vascular and Interventional Radiology Unit, "Sapienza" University of Rome, ¹Department of Surgical Sciences, "Sapienza" University of Rome, Rome, Italy

Correspondence: Dr. Alessandro Cannavale, Department of Radiological Sciences, University of Rome "Sapienza," 324 Viale Regina Elena, 00161 Rome, Italy. E-mail: rossi883@hotmail.com

Abstract

Percutaneous treatment has been developing as a reliable and effective alternative to surgery in the treatment of liver hydatid cysts. However, percutaneous treatment is strongly recommended only for some types of hydatid cysts (types I and II). We report a patient with type III (CE2, according to the WHO classification) multiple liver hydatid cysts treated with the PAIR (puncture–aspiration–injection–reaspiration) technique. The patient developed a secondary biliary fistula, which ultimately healed.

Key words: Computed tomography; hydatid liver disease; interventional treatment

Introduction

Liver cystic echinococcosis (CE) is considered a relatively benign disease. However, some complications can lead to morbidity and occasional mortality, for example, anaphylaxis after a cyst's rupture into the peritoneum or into the biliary system. Moreover, infection of the cyst can facilitate the development of liver abscesses and cause mass effect on bile ducts and vessels, leading to cholestasis, portal hypertension, and the Budd–Chiari syndrome.^[1,2] In view of the risk of severe complications, treatment is mandatory for all symptomatic cysts and is recommended in active cysts.^[1–3]

Treatment of hydatid cyst of the liver can vary from surgical intervention (with a conventional or laparoscopic approach)

to percutaneous drainage to medical therapy. Although surgery is still considered the gold standard treatment, it is characterized by high rates of morbidity and mortality, long hospital stay and high cost.

In the last two decades, the technique of USG-percutaneous drainage and injection of different scolicidal agents has given excellent results in terms of disappearance of the cyst, with only minor side effects and a low mortality rate. Different techniques have been described, such as the PAIR technique (puncture–aspiration–injection–reaspiration), double puncture-aspiration-injection (D-PAI) technique, and other modified catheterization techniques.

At present, percutaneous intervention is generally indicated for type I (pure fluid collection), type II (fluid collection with a split wall), and some type III lesions (fluid collection with multiseptated cysts with daughter cysts).^[2–7] We report a patient with type III (CE2, according to the WHO classification) multiple liver hydatid cysts whom we treated with the PAIR technique.

Case Report

A 60-year-old man presented to our emergency department

Access this article online

Quick Response Code:



Website:
www.ijri.org

DOI:
10.4103/0971-3026.95399

with a history of pain and a heavy sensation in the right flank for the last month. He had no history of trauma but he had postischemic heart failure and diabetes. Blood tests showed abnormal liver function (serum albumin = 2.5 g/dl, aspartate transaminase (AST) = 100 UI/l, alanine transaminase (ALT) = 90 UI/l, total bilirubin = 1.7 mg/dl, and gamma glutamyl transpeptidase (GGT) = 70 IU/l). At USG examination of the abdomen, multiple well-rounded hepatic hypoechoic areas with some septae inside were found; the picture was suggestive of hydatid cyst formations. CT scan confirmed the presence of multiple hydatid multivesiculated (honeycomb-like) cysts (type CE2), almost totally replacing the right liver parenchyma [Figure 1]. Preoperative liver volume assessment using a dedicated volume software package (Volume, Syngo Workstation, Siemens, Erlangen, Germany) showed a remnant liver volume (RLV) of 34%. Considering the clinical condition of the patient and the extensive disease with reduced liver function we felt that the surgical risk was unacceptably high and decided to perform percutaneous treatment.

Albendazole (ABZ) was administered 4 hours before the procedure for prophylaxis. Under aseptic conditions and local anesthesia, a coaxial system composed of a 20-cm-long fine needle with an outer 10 Fr sheath was inserted into the cystic cavity via the transhepatic route under USG guidance. Due to the large dimensions of the cyst (maximum diameter of 12 cm), under fluoroscopic guidance, a 10 Fr pigtail drainage catheter (Flexima® multipurpose, Boston Scientific, Natick, MA, USA) was positioned within the cyst at the level of the VIII liver segment [Figure 2]. The volume of the whole cyst was about 900 ml and we aspirated 70% of the cyst's fluid content. Cavitography in multiple projections was performed in order to exclude biliary fistula. Under monitoring of vital parameters and sedation we injected 10 ml of 95% sterile ethanol into the cyst, which was left *in situ* (usually inject an amount of ethanol corresponding to 10% of the cyst residual volume, however, in case the residual volume is more than 100 ml, we inject a maximum of 10 ml to avoid excessive cyst filling and to reduce the risk of extravasation). After 15 minutes, reaspiration of the fluid within the cyst was performed. The aspirated material was sent for microscopic analysis.

Four treatments with alcohol were performed at intervals of about 7 days. After 1 month, CT scan showed healing of the cyst within the VIII–VII liver segments. However, other communicating hydatid cysts remained within the IV, V, and VI liver segments and these were also treated with the same technique, using two basket-type catheters (OptiMed, Ettlingen, Germany). After drainage catheter placement, cavitography in multiple projections revealed communication with the bile ducts [Figure 3] and therefore alcohol was not injected but the catheters were left in place in order to resolve the biliary fistula and collections. During the next fluoroscopic follow-up, only saline was injected to keep the catheters patent.

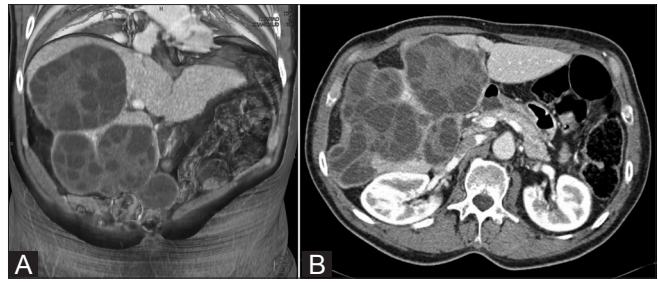


Figure 1 (A,B): Preprocedure volume rendered CT scan reconstructions show multiple multivesiculated, honeycomb-like, hydatid cysts (type CE2) at the level of the VIII–VII and IV liver segments (A) and within the V–VI liver segments (B)

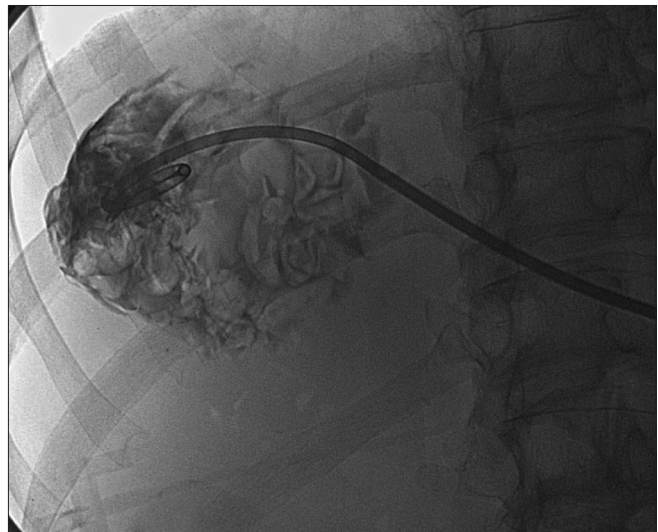


Figure 2: Under fluoroscopic guidance, a 10 Fr pigtail drainage catheter (Flexima® multipurpose, Boston Scientific, Natick, MA, USA) was placed within the cyst in the VIII liver segment. After contrast injection, no communication with the bile ducts is detected

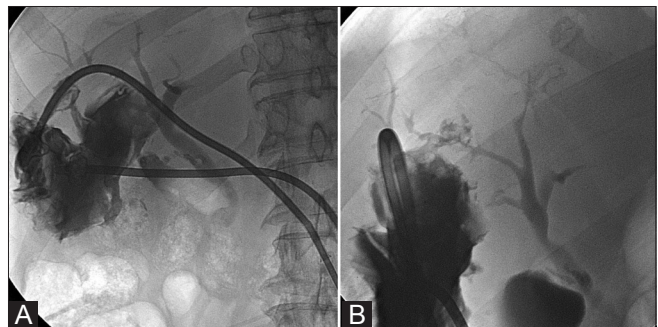


Figure 3 (A,B): After placement of the two basket-type catheters (OptiMed, Ettlingen, Germany) within the cysts of the IV, V, and VI liver segments, anteroposterior (A) and lateral views (B) after contrast injection show communication of the cysts with the right biliary ducts, with visualization of the common bile duct

After 3 months, the biliary communication resolved, with healing of the cysts; both the drainage catheters were subsequently removed [Figure 4A]. A CT scan confirmed the satisfactory final result [Figure 4B]. USG examination done 18 months later showed no recurrence of the liver hydatidosis [Figure 5].

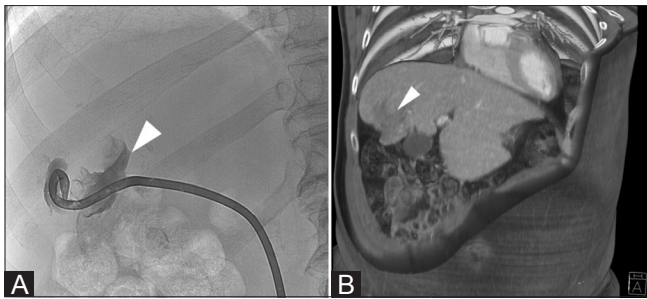


Figure 4 (A,B): After 6 months, fluoroscopy after iodinated contrast injection shows complete healing of the cysts and no communication with the biliary tree (A). Volume-rendered CT scan image (B) confirms the satisfactory result with a small residual collection within the right liver (arrow)

Discussion

Percutaneous treatment of abdominal CE was introduced in the mid-1980s. Initially received with skepticism by some, it developed into an attractive alternative to surgery and medical therapy. With this treatment modality the aim is to destroy the germinal layer with scolicidal agents or to evacuate the entire endocyst.

Current guidelines give the indications for percutaneous treatment of hydatid liver disease. According to these guidelines, the best results with PAIR + BMZ are achieved in >5 cm CE1 and CE3a cysts, and in these cases this treatment modality may be considered the first-line treatment [Table 1]. However, PAIR is contraindicated for CE2, CE3b, CE4, and CE5 cysts, as well as for lung cysts.^[1-3,5,6] Some authors have reported high rates of repeated failures of PAIR in multivesiculated cysts (CE2 and CE3b). These findings have prompted most clinicians to use PAIR exclusively for unilocular cysts with or without detached endocysts.

Although the relatively low rate of success of PAIR in type III cysts is well known, some authors, using different techniques and prolonged catheterization, have reported high success rates in terms of volume loss.^[7,8] In their series, Kabaalioglu *et al.*, reported successful outcomes in 39% of all type III cysts treated with PAIR.^[7] However, they considered type III cysts according to the traditional Gharbi classification, not discerning between CE2 (honeycomb-like) and CE3b (with daughter cysts in solid matrix) cysts.

In our patient it was reasonable to choose the PAIR technique instead of surgical intervention due to the high risk of liver failure after surgery in this patient; the surgical risk was considered to be high because the preoperative liver function was abnormal, RLV was only 34%, and the patient was an elderly man with other comorbidities. Other studies have suggested that these are risk factors for postresectional liver failure. In particular, it has been reported that an RLV of at least 40% is needed in patients with restricted liver function to avoid postresectional liver

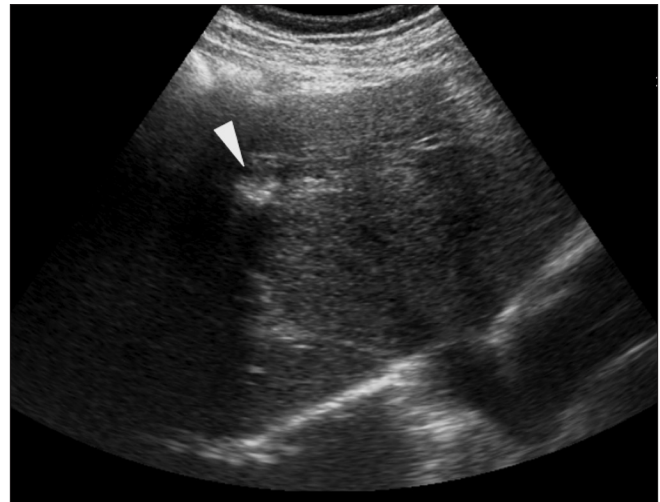


Figure 5: Follow-up abdominal USG shows calcification within the VI-VII liver segment (arrowhead), without any evidence of a hydatid cyst

Table 1: Comparative description of the WHO-IWGE and Gharbi ultrasound classifications of echinococcal cysts

WHO-IWGE 2001	Gharbi 1981	Description	Stage
CE1	Type I	Unilocular anechoic cystic lesion with double line sign	Active
CE2	Type III	Multiseptated, "rosette-like" "honeycomb" cyst	Active
CE3 A	Type II	Cyst with detached membranes (water-lily-sign)	Transitional
CE3 B	Type III	Cyst with daughter cysts in solid matrix	Transitional
CE4	Type IV	Cyst with heterogenous hypoechoic/hyperechoic contents. No daughter cysts	Inactive
CE5	Type V	Solid cyst with calcified wall	Inactive

failure.^[9] Considering that the hydatid cysts in our patient were multivesiculated but without a solid matrix inside and quite large, we decided to perform the PAIR technique, using prolonged catheterization to allow further alcohol injections. We ultimately obtained an excellent result, 13 months after the first procedure.

We suggest that hydatid multivesiculated cysts (WHO type CE2) are easier to treat with the percutaneous procedure than cysts with daughter cysts in a solid matrix (WHO type CE3b). In fact, any solid matrix present within the cysts may hinder percutaneous drainage by clogging the catheters, leading to a high rate of complications and recurrence.^[8]

Cystobiliary communication, which occurs as a result of cyst rupture into the biliary tree, is the most common complication of liver hydatid disease, with an incidence of 10%-37% for occult rupture and 3%-17% for frank rupture.^[10] Secondary biliary fistula after percutaneous treatment occurs in 1.7%-6.2% of cases.^[11] The rate of radiologically apparent biliary fistula was higher (ranging

from 15.6% to 41.6%) in studies where the cyst contents were evacuated. To rule out biliary fistula, a cavigraphy in multiple projections is highly recommended before alcohol injection into the hydatid cavity.

The major complication of alcohol injection into a biliary fistula can be a devastating secondary sclerosing cholangitis.^[12,13] In the PAIR technique, this is explained by the fact that no negative pressure is applied and the solid components are left in the collapsed cavity, decreasing the fistula rate.

As in our case, in most patients with cystobiliary fistula, following percutaneous treatment the catheter can be kept in the cavity until daily drainage ceases.^[12-16] In our case, a communication with the bile ducts appeared after a delay of 2 months, and at that time the lesions were certainly inactive. This late development of a biliary fistula was probably due to the prolonged catheterization.

To conclude, the PAIR technique with prolonged catheterization and multiple alcohol injections was demonstrated to be effective in a multivesiculated cyst without solid matrix (WHO type CE2 cysts) in a patient not considered suitable for surgery.

References

1. Giorgio A, de Stefano G, Esposito V, Liorre G, Di Sarno A, Giorgio V, *et al.* Long-term results of percutaneous treatment of hydatid liver cysts: A single center 17 years experience. *Infection* 2008;36:256-61.
2. Czermak BV, Akhan O, Hiemetzberger R, Zelger B, Vogel W, Jaschke W, *et al.* Echinococcosis of the liver. *Abdom Imaging* 2008;33:133-43.
3. Sayek I, Onat D. Diagnosis and treatment of uncomplicated hydatid cyst of the liver. *World J Surg* 2001;25:21-7.
4. Dziri C, Haouet K, Fingerhut A. Treatment of hydatid cyst of the liver: Where is the evidence? *World J Surg* 2004;28:731-6.
5. Yagci G, Ustunsoz B, Kaymakcioglu N, Bozlar U, Gorgulu S, Simsek A, *et al.* Results of surgical, laparoscopic, and percutaneous treatment for hydatid disease of the liver: 10 years experience with 355 patients. *World J Surg* 2005;29:1670-9.
6. Gharbi HA, Hassine W, Brauner MW, Dupuch K. Ultrasound examination of the hydatid liver. *Radiology* 1981;139:459-63.
7. Brunetti E, Kern P, Vuitton DA. Writing Panel for the WHO-IWGE. Expert consensus for the diagnosis and treatment of cystic and alveolar echinococcosis in humans. *Acta Trop* 2010;114:1-16.
8. Junghanss T, da Silva AM, Horton J, Chiodini PL, Brunetti E. Clinical management of cystic echinococcosis: State of the art, problems, and perspectives. *Am J Trop Med Hyg* 2008;79:301-11.
9. Van den Broek MA, Olde Damink SW, Dejong CH, Lang H, Malagó M, Jalan R, *et al.* Liver failure after partial hepatic resection: Definition, pathophysiology, risk factors and treatment. *Liver Int* 2008;28:767-80.
10. Kabaalioglu A, Ceken K, Alimoglu E, Apaydin A. Percutaneous imaging-guided treatment of hydatid liver cysts: Do long-term results make it a first choice? *Eur J Radiol* 2006;59:65-73.
11. Bosanac ZB, Lisanin L. Percutaneous drainage of hydatid cyst in the liver as a primary treatment: Review of 52 consecutive cases with long-term follow-up. *Clin Radiol* 2000;55:839-48.
12. Rozanes I, Güven K, Acunaş B, Emre A. Cystic echinococcal liver disease: New insights into an old disease and an algorithm for therapy planning. *Cardiovasc Intervent Radiol* 2007;30:1112-6.
13. Manouras A, Genetzakis M, Antonakis PT, Lagoudianakis E, Pattas M, Papadima A, *et al.* Endoscopic management of a relapsing hepatic hydatid cyst with intrabiliary rupture: A case report and review of the literature. *Can J Gastroenterol* 2007;21:249-53.
14. Men S, Hekimoglu B, Yucesoy C, Arda IS, Baran I. Percutaneous treatment of hepatic hydatid cysts: An alternative to surgery. *AJR Am J Roentgenol* 1999;172:83-9.
15. Canyigit M, Gumus M, Cay N, Erol B, Karaoglanoglu M, Akhan O. Refractory cystobiliary fistula secondary to percutaneous treatment of hydatid cyst: Treatment with n-butyl 2-cyanoacrylate embolization. *Cardiovasc Intervent Radiol* 2011;34 Suppl 2:S266-70.
16. Akhan O, Ozmen MN. Percutaneous treatment of liver hydatid cysts. *Eur J Radiol* 1999;32:76-85.

Cite this article as: Corona M, Cannavale A, Bruni A, Boatta E, Allegritti M, Lucatelli P, *et al.* Case report: Percutaneous treatment of multiple honeycomb-like liver hydatid cysts (type III CE2, according to WHO classification). *Indian J Radiol Imaging* 2012;22:23-6.

Source of Support: Nil, **Conflict of Interest:** None declared.