

# Handling Cervical Myomas

Pravin Patel, Manish Banker, Sujal Munshi,  
Aditi Bhalla

Pulse Women's Hospital, Ahmedabad, India

## ABSTRACT

Compared to myomas that occur in the uterine corpus, cervical myomas are closer to other organs such as the bladder, ureter, and rectum, and the approach needs to be modified, as the organs that have to be considered differ depending on the location of the myoma. Surgical difficulties associated with these cases are, poor access to the operative field, difficulty in suturing the repairs, increased blood loss, and distortion of the anatomy of the vital neighboring structures in the pelvic cavity.

**Key words:** Cervical fibroid, laproscopic myomectomy, vasopressin

Uterine myoma is a common gynecological disorder occurring in 20 – 50% of women, of late reproductive age. A majority of myomas are associated with uterine corpus. Cervical myomas (CM) account for less than 5% of uterine myomas.

Laparoscopic Myomectomy and Hysterectomy have been advocated over traditional laparotomy for various benefits in case of uterine leiomyoma.<sup>[1]</sup> With the advances in laparoscopic techniques, almost all uterine myomas in the uterine corpus can be treated using laparoscopic myomectomy. However, the treatment of cervical myoma by laparoscopic operation remains crucial. It is essential to establish techniques for safety in operative laparoscopy, for different types of cervical myomas.<sup>[2]</sup> Compared to myomas that occur in the uterine corpus, cervical myomas are closer to other organs such as the bladder, ureter, and rectum, and the approach needs to be modified, as the organs that have to be considered differ depending on the location of the myoma. Surgical difficulties associated with these cases are, poor access to the operative field, difficulty in suturing the repairs, increased blood loss, and distortion of the anatomy of the vital neighboring structures in the pelvic cavity.<sup>[3]</sup>

Cervical myomas are divided into two types according to the location, comprising of the intracervical and

extracervical types. Surgical steps differ according to the type and location, either anterior or posterior.

## OPERATIVE STEPS FOR LAPAROSCOPIC MYOMECTIONY IN CERVICAL MYOMA

A uterine manipulator is normally inserted through the cervix into the uterus before surgery, which sometimes is not possible in patients with a myoma bulging out of the external os of the uterus into the vagina.<sup>[4]</sup>

The standard surgical steps of operative laparoscopy are followed. Pneumoperitoneum can be obtained by the closed method. The primary 10 mm trocar may be inserted at a point 2-3 cm above the umbilicus or in the palmer's area in such cases. We prefer three 5 mm trocars (one midline and two lateral) in the lower abdominal region.

A step worth considering in huge cervical myomas is bilateral uterine artery ligation before Myomectomy or Hysterectomy. The Uterine can be approached by opening the broad ligament at round ligament and identification and ligation at its origin from the internal iliac artery through retrograde umbilical ligament tracking.

### Address for correspondence:

Dr. Pravin Patel,  
Pulse Women's Hospital, Ahmedabad, India.  
E-mail: mivfg@yahoo.com

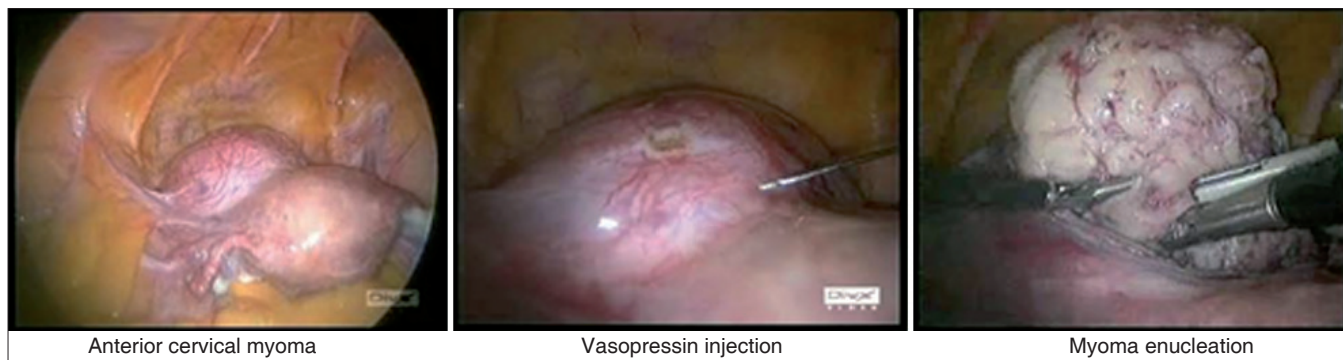### Access this article online

#### Quick Response Code:



Website:  
[www.gynecendoscopy.org](http://www.gynecendoscopy.org)

DOI:  
10.4103/0974-1216.85277



**Figure 1:** Posterior myomas we prefer a midline vertical incision to avoid injuring the vessels and to stay at a safe distance from the ureters

An average of 20 U/mL diluted in 200 mL of saline can be laparoscopically injected into the myoma in the presence of a posterior uterine wall myoma and in the layer between the myoma and the serosa, in an attempt to reduce operative blood loss.

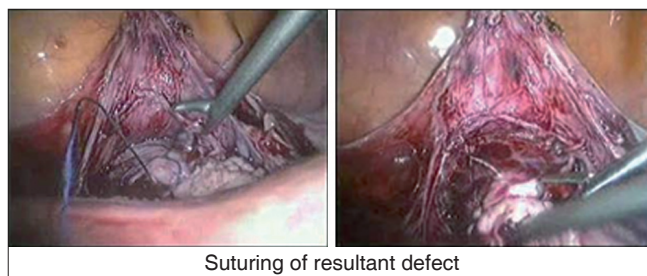
The course of the ureter is confirmed with special attention given to the sacral uterine ligament attachments, to determine the displacement in the relative position of the uterine arteries or ureter. At times when the myoma is large and boundaries difficult to confirm, the broad ligament is opened with an anterior approach to delineate the myoma.

In case of an anterior wall type, a transverse incision is made in the uterovesical pouch and peritoneum, to perform a blunt dissection of the bladder. When performing traction and enucleation with a laparoscopic myomectomy screw, the base of the wound is held with a bipolar grasping forceps and simultaneous complete homeostasis is achieved along with dissection to avoid post enucleation difficulties due to retracted capillaries.

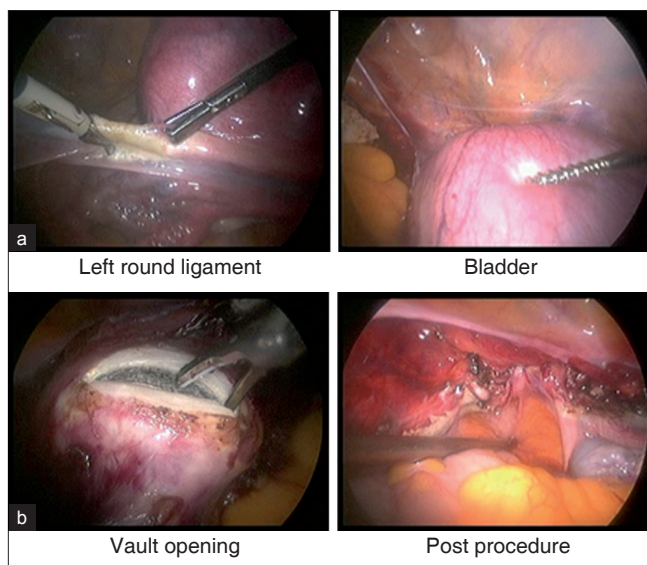
In case of posterior myomas we prefer a midline vertical incision to avoid injuring the vessels and to stay at a safe distance from the ureters [Figure 1].

After the Cervical Myoma is completely enucleated, morcellation is performed. If complete enucleation is difficult with large myomas and there is limited pelvic space for traction, the myoma is sometimes morcellated when it is still attached to the uterus. The approach should be varied according to the size and location of the myoma.

The most difficult part of cervical myomectomy is suturing the base of the wound following enucleation. Complete dissection of the surrounding organs such as the bladder and ureter, near the base of the wound, is difficult. Bleeding makes it difficult to maintain the visual field, thereby



**Figure 2:** Suturing of resultant defect



**Figure 3:** (a) Uterus with cervical myoma, (b) Bladder dissection

increasing the possibility of damage during suturing. A bottom-up procedure makes it possible to perform suturing safely by providing a complete visual field [Figure 2].

The resultant defect is sutured at intervals of about 1 cm with 1/0 or 2/0 absorbable suture material. For the second layer, continuous sutures of the muscle layer can be made

with 1/0 sutures for the first layer of cervical mucosa. It is recommended to close the peritoneum also with sutures, to restore the anatomy.

### OPERATIVE STEPS TO BE CONSIDERED FOR LAPAROSCOPIC HYSTERECTOMY IN CERVICAL MYOMA

An additional difficulty may be the introduction of conventional manipulators during total Laparoscopic Hysterectomy, where a myoma screw with additional port may be utilized, to manipulate the uterus.

A reasonable option is to perform myomectomy and correct the distortion of the anatomy before proceeding to the hysterectomy, in selected cases.

When performing hysterectomy with myoma *in situ*, approach the broad ligament on the side with less distortion first and try to tackle the uterus simultaneously on that side. After release of the uterosacrals on the less affected side, normally, reasonable mobility of the uterus is gained so as to be at a safe distance from the vital pelvic organs on the contralateral side (where myoma is projecting) when performing the dissection and coagulation.<sup>[5]</sup>

Prior identification of the ureters with either retroperitoneal dissection or pre-procedure cystoscopic ureteric stenting may be of help in selected cases of very large cervical myomas with lateral projection. In cases of anterior myomas, prior bladder dissection helps in reaching the uterines. Thus, after considering the location of the myoma, cervical myomectomy or hysterectomy can be performed

safely by developing a uniform strategy that uses a fixed operative procedure, if sufficient attention is paid to the following points [Figure 3a and b]:

- Reducing the size of the myoma with preoperative GnRH
- Determining the positional relationship between the myoma and the surrounding organs
- Optional blocking of the uterine artery blood flow temporarily
- Suppressing bleeding during myomectomy with the use of vasopressin
- Minimizing the risk of damaging the surrounding organs by properly positioning the incision in the myometrium
- Suturing the bottom of the wound after grasping with the forceps, to avoid making a dead space
- Prior myomectomy before attempting definitive steps for hysterectomy

### REFERENCES

1. Matsuoka S, Kikuchi I, Kitade M, Kumakiri J, Kuroda K, Tokita S, et al. Strategy for laparoscopic cervical myomectomy. J Minim Invasive Gynecol 2010;17:301-5.
2. Chang WC, Chen SY, Huang SC, Chang DY, Chou LY, Sheu BC. Strategy of cervical myomectomy under laparoscopy. Fertil Steril 2010;94:2710-5.
3. Matsuoka. Strategy of Cervical Myoma under Laparoscopy. J Minim Invasive Gynecol 2009.
4. Sinha R, Hegde A, Warty N, Mahajan C. Laparoscopic myomectomy: Enucleation of the myoma by morcellation while it is attached to the uterus. J Minim Invasive Gynecol 2005;12:284-9.
5. Shi. Clinical Analysis of Laparoscopic Myomectomy for Patients with Cervical Myoma R. J Minim Invasive Gynecol 2010.

**How to cite this article:** Patel P, Banker M, Munshi S, Bhalla A. Handling cervical myomas. J Gynec Endosc Surg 2011;2:30-2.

**Source of Support:** Nil. **Conflict of Interest:** None declared.

### Staying in touch with the journal

#### 1) Table of Contents (TOC) email alert

Receive an email alert containing the TOC when a new complete issue of the journal is made available online. To register for TOC alerts go to [www.gynecendoscopy.org/signup.asp](http://www.gynecendoscopy.org/signup.asp).

#### 2) RSS feeds

Really Simple Syndication (RSS) helps you to get alerts on new publication right on your desktop without going to the journal's website. You need a software (e.g. RSSReader, Feed Demon, FeedReader, My Yahoo!, NewsGator and NewzCrawler) to get advantage of this tool. RSS feeds can also be read through FireFox or Microsoft Outlook 2007. Once any of these small (and mostly free) software is installed, add [www.gynecendoscopy.org/rssfeed.asp](http://www.gynecendoscopy.org/rssfeed.asp) as one of the feeds.