

# Salivary gland tumors: A 15-year experience of a university hospital in Turkey

 Erdem Mengi,<sup>1</sup>  Cuneyt Orhan Kara,<sup>1</sup>  Funda Tumkaya,<sup>1</sup>  Fazil Necdet Ardic,<sup>1</sup>  Bulent Topuz,<sup>1</sup>  
 Ferda Bir<sup>2</sup>

<sup>1</sup>Department of Otorhinolaryngology, Head and Neck Surgery, Pamukkale University Faculty of Medicine, Denizli, Turkey

<sup>2</sup>Department of Pathology, Pamukkale University Faculty of Medicine, Denizli, Turkey

## ABSTRACT

**OBJECTIVE:** To determine the demographic characteristics of benign and malignant salivary gland tumors in our department in the last 15 years.

**METHODS:** In this study, the files of the patients who underwent salivary gland surgery between 2004 and 2019 in our department were analyzed retrospectively. A total of 366 patients whose diagnoses of salivary gland tumor histopathologically confirmed were included in this study. The demographic data of the patients and tumor localizations were recorded, and their relationships with histopathological results were examined.

**RESULTS:** Of the 366 tumors, 292 (80%) of them was originated from the parotid gland, 52 (14%) from the submandibular gland, and 22 (6%) from the minor salivary gland. The male: female ratio was found as 1.2:1, and the mean age of the patients was 50.37 years. A total of 259 (70.8%) tumors were benign, and 107 (29.2%) were malignant. The most frequent benign tumor was pleomorphic adenoma, with 121 cases (46.7%). While pleomorphic adenomas constituted the majority of the benign tumors of the submandibular gland and minor salivary glands, Warthin tumor was detected more than pleomorphic adenoma in the parotid gland. The most common malignant tumor was mucoepidermoid carcinoma, with 26 cases (24.3%).

**CONCLUSION:** The distribution of the salivary gland tumors detected in our department was found to be substantially similar to other worldwide series. Unlike the literature, we concluded that salivary gland tumors were seen slightly more in males, minor salivary gland tumors were relatively rare and Warthin tumors were more frequently detected in our region.

*Keywords:* Histology; minor salivary gland; parotid; salivary gland tumor; submandibular.

**Cite this article as:** Mengi E, Kara CO, Tumkaya F, Ardic FN, Topuz B, Bir F. Salivary gland tumors: A 15-year experience of a university hospital in Turkey. *North Clin Istanbul* 2020;7(4):366–371.

The salivary glands consist of three major glands as parotid, submandibular and sublingual glands and hundreds of minor glands, which are diffusely located in the beginning part of the respiratory system. Tumors of the salivary glands are rarely encountered. However, they appear with different histopathological characters. Different biological behaviors can be observed even in neoplasms defined by the same name. In the latest classifica-

tion made by the World Health Organization (WHO) in 2017, salivary gland tumors were classified into more than 30 benign and malignant histologic subtypes [1]. This wide histopathological spectrum and significant differences in prognosis between them distinguish salivary gland tumors from other organ neoplasms.

Salivary gland tumors account for approximately 3-4% of all head and neck tumors [2]. Their inci-

*Received:* November 09, 2019 *Accepted:* February 06, 2020 *Online:* June 15, 2020

**Correspondence:** Erdem MENGI, MD. Pamukkale Üniversitesi Tıp Fakültesi, Kulak Burun Bogaz ve Bas Boyun Cerrahisi Anabilim Dalı, Camlaraltı Mahallesi Kalp Merkezi, 20070 Denizli, Turkey.

Tel: +90 258 296 60 00 e-mail: emengi@hotmail.com

© Copyright 2020 by Istanbul Provincial Directorate of Health - Available online at [www.northclinist.com](http://www.northclinist.com)



dence has been reported as 1.1–1.3/100.000 annually in the United States [3]. Incidence rates have similarly been reported as 1.31/100.000 in Europe and as 1.04/100.000 in Japan [4]. These tumors increase, especially after the age of 50, and their incidence increases to above 7/100.000 at the age of 70 [3]. They can be seen in both sexes. Approximately 80% of the tumors are in benign character, and the majority of them are seen in the parotid gland [5]. Although, in many studies, the most commonly seen benign and malignant tumors are reported as pleomorphic adenoma and mucoepidermoid carcinoma, respectively, different tumor types and different rates may be observed in different geographic areas and ethnic groups.

The present study aims to determine the demographic characteristics of salivary gland tumors in our region by analyzing the histopathological results of patients who had undergone salivary gland surgery in our department in the last 15 years and to compare these results with the literature.

## MATERIALS AND METHODS

In this study, the files of 462 patients who underwent salivary gland surgery between 2004 and 2019 in the ENT department of Pamukkale University Hospital were analyzed retrospectively. Of these cases, 96 patients who were operated for non-tumor reasons were excluded from this study. This study included 366 patients whose diagnoses of salivary gland tumors were histopathologically confirmed. The demographic data of the patients and tumor localizations were recorded, and their relationships with histopathological results were examined. The data of this study were evaluated according to 2017 WHO histological classification criteria for salivary gland tumors [1]. Approval was received from the Ethics Committee of Pamukkale University (60116787-020/30512).

### Statistical Analysis

The data were analyzed using SPSS version 24.0 software (IBM Corporation, Armonk, NY). Continuous variables were expressed as mean±standard deviation and range, and categorical variables were expressed as count and percentage. The independent-samples *t*-test was used for comparison between two groups. The Chi-square test was used for categorical groups' comparisons. The statistical significance level was set at  $p < 0.05$  in all statistical analyses.

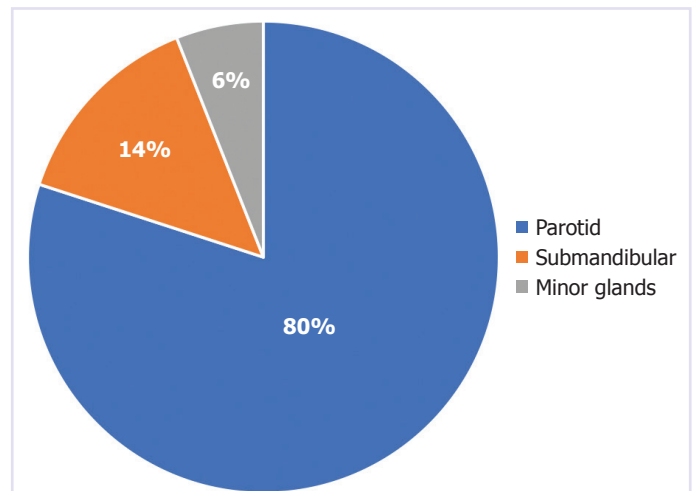


FIGURE 1. The site of origin of the salivary gland tumors.

## RESULTS

### Patient Population

Of the 366 patients included in this study, 202 were male (55.2%), and 164 were female (44.8%) and their mean age was  $50.37 \pm 17.67$  (min.–max.: 8–95) years. The male: female ratio was found as 1.2:1 in our study.

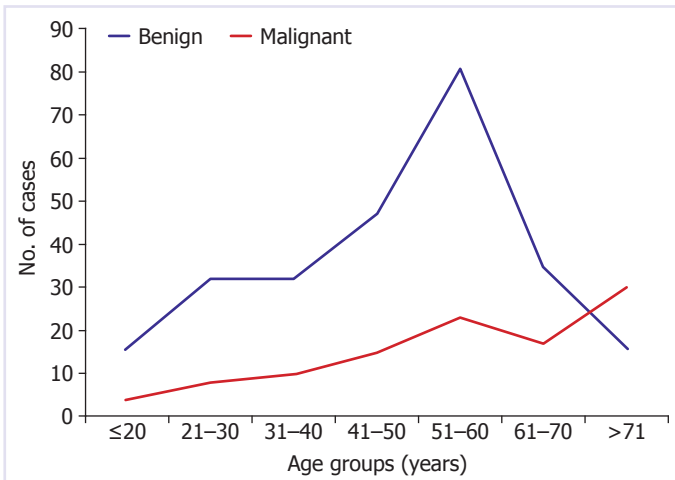
### Tumor Localization

Of the 366 tumors, 292 (79.8%) were originated from the parotid gland, 52 (14.2%) from the submandibular gland, and 22 (6%) from the minor salivary gland (Fig. 1). No tumor originated from the sublingual gland was detected. Of the 22 minor salivary gland tumors, 17 occurred in the palate, 2 in the paranasal sinuses, 1 in the lip, 1 in the buccal mucosa and 1 in the nasopharynx.

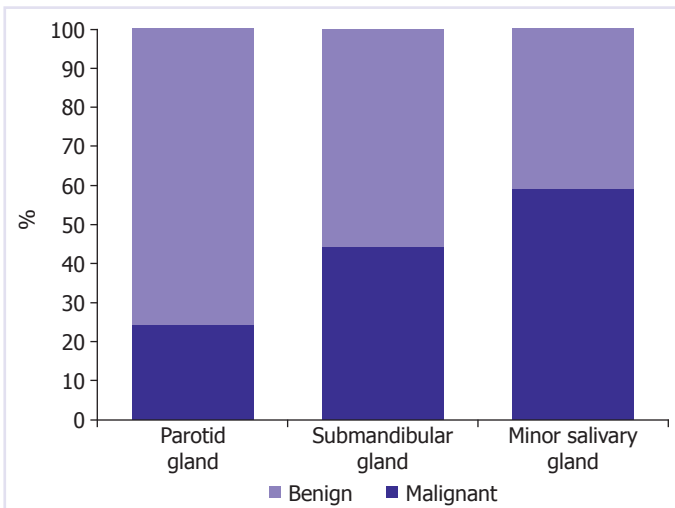
### Types of the Tumors

Of the 366 tumors, 259 (70.8%) were in benign character, and 107 (29.2%) were in malignant character. Benign tumors were most frequently detected in patients between the ages of 50–60 (mean:  $47.46 \pm 16.05$ ), while malignant tumors were most frequently detected in patients older than 70 years (mean:  $57.43 \pm 19.47$ ) (Fig. 2). The mean age for malignant tumors was significantly higher than benign tumors ( $p = 0.0001$ ). The male: female ratio was found as 1.3:1 in benign tumors, and 1.06:1 in malignant tumors.

When salivary gland tumors were evaluated according to their localizations, malignancy rates for parotid, submandibular and minor salivary gland tumors were



**FIGURE 2.** Distribution of the salivary gland tumors according to age group.



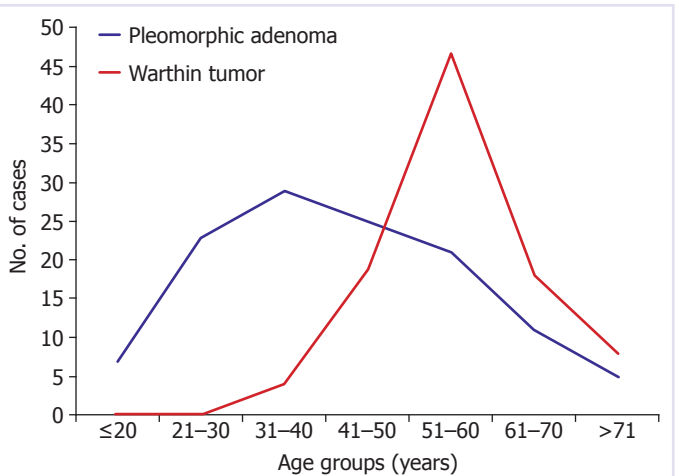
**FIGURE 3.** Malignancy rates for salivary gland tumors according to the site of origin.

found as 24.3%, 44.2%, and 59.1%, respectively (Fig. 3). The rate of benign tumor in the parotid gland was found to be statistically significant, whereas the rate of malignant tumor in the minor salivary gland was statistically higher ( $p=0.0001$ ).

The histopathological distribution of benign salivary gland tumors, according to localization, is shown in Table 1. The most frequently detected benign tumor in our cases was observed to be pleomorphic adenoma (46.7%). It was followed by Warthin tumor (37.1%), cystadenoma (3.4%) and oncocytoma (3.1%), respectively. The most common benign mesenchymal tumor in our study was hemangioma (2.7%). While pleomorphic adenomas constitute the majority of the benign

**TABLE 1.** The histopathological distribution of the benign salivary gland tumors according to the lesion site

Histologic type	Parotid (%)	Submandibular (%)	Minor glands (%)	Total glands (%)
<b>Epithelial tumors</b>				
Pleomorphic adenoma	41.2	72.4	100	46.7
Warthin tumor	43.5	–	–	37.1
Cystadenoma	3.6	3.5	–	3.4
Oncocytoma	3.2	3.5	–	3.1
Myoepithelioma	2.7	3.5	–	2.7
Lymphadenoma	0.4	3.5	–	0.8
Basal cell adenoma	0.4	–	–	0.4
<b>Mesenchymal tumors</b>				
Hemangioma	2.3	6.9	–	2.7
Lipoma	2.3	3.5	–	2.3
Lymphangioma	0.4	3.5	–	0.8



**FIGURE 4.** Distribution of pleomorphic adenomas and Warthin tumors according to age group. While pleomorphic adenoma has a much wider range of age, Warthin tumor is seen to peak between the ages of 51 and 60.

tumors of the submandibular gland and minor salivary glands, it was observed that Warthin tumor was detected more than pleomorphic adenoma in the parotid gland. Besides, all Warthin tumors were originated from the parotid gland. The distribution of pleomorphic adenomas and Warthin tumors, according to the age group, is shown in Figure 4. Pleomorphic adenoma was most frequently detected in the 4<sup>th</sup> decade (mean:

**TABLE 2.** The histopathological distribution of the malignant salivary gland tumors according to lesion site

Histologic type	Parotid (%)	Submandibular (%)	Minor glands (%)	Total (%)
<b>Epithelial tumors</b>				
Mucoepidermoid carcinoma	19.7	30.4	38.5	24.3
Acinic cell carcinoma	14.1	–	–	9.3
Adenoid cystic carcinoma	4.2	–	46.1	8.4
Squamous cell carcinoma	8.4	4.3	–	6.6
Adenocarcinoma. NOS	7.1	4.3	–	5.6
Myoepithelial carcinoma	2.8	–	–	1.9
Salivary duct carcinoma	1.4	4.3	–	1.9
Polymorphous adenocarcinoma	–	4.3	7.7	1.9
Epithelial-myoepithelial carcinoma	–	4.3	7.7	1.9
Basal cell adenocarcinoma	1.4	–	–	0.9
Small cell neuroendocrine carcinoma	1.4	–	–	0.9
Carcinoma ex pleomorphic adenoma	–	4.3	–	0.9
Metastasis	26.8	39.1	–	26.2
<b>Mesenchymal tumors</b>				
Lymphoma	12.7	4.3	–	9.3

NOS: Not otherwise specified.

42.53±15.41), while Warthin tumor was most frequently detected in the 6<sup>th</sup> decade (mean: 56.49±9.15). Pleomorphic adenoma was significantly more frequent in women (62%), whereas Warthin tumor was significantly more frequent in men (89%,  $p=0.0001$ ). For all the benign tumors, the mean follow-up duration was 5.11±3.95 years and no recurrence was seen in our study group.

The distribution of malignant salivary gland tumors, according to localization, is shown in Table 2. The most common malignant epithelial tumor was mucoepidermoid carcinoma, with 26 cases (24.3%). It was followed by acinic cell carcinoma (9.3%) and adenoid cystic carcinoma (8.4%), respectively. Mucoepidermoid carcinoma was most frequently detected in the parotid and submandibular glands, while adenoid cystic carcinoma was most frequently detected in the minor salivary glands. In addition, 67% of adenoid cystic carcinomas were originated from the minor salivary glands. All of the malignant tumors of the mesenchymal origin were lymphoma and accounted for 9.3% of all malignant tumors. For all the malignant tumors, the mean duration of the follow up was 5.7±3.93 years. Two malignant tumor patients (1 squamous cell carcinoma of the parotid gland, and 1 adenoid cystic carcinoma of the nasophar-

ynx) had unresectable tumors, so no curative surgery was planned for them. Of the 69 primary malignant epithelial tumors, recurrence was detected in 17 patients (24.6%) and distant organ metastasis was detected in three patients (4.3%). Of the 17 local recurrences, five were squamous cell carcinoma, four were adenocarcinoma, three were mucoepidermoid carcinoma, two were adenoid cystic carcinoma, one was salivary duct carcinoma, one was epithelial-myoepithelial carcinoma and one was small cell neuroendocrine carcinoma. All the distant organ metastasis was adenoid cystic carcinomas. During the follow-up period, the mortality occurred 11 of the 17 local recurrence patients and one of the three distant organ metastasis patients. The follow-up of other patients is continuing.

In our study, metastatic tumors of the salivary glands were detected in 28 cases (Table 3). 68% of the metastatic tumors were in the parotid gland and 32% were in the submandibular gland. No metastatic tumor of the minor salivary glands was detected. It was found that the tumors which most frequently metastasize to the parotid gland were squamous cell carcinomas of the skin (79%) and the tumors which most frequently metastasize to the submandibular gland were squamous cell carcinomas of the lip (67%).



**TABLE 3.** Metastatic tumors of the salivary glands

	n
Metastatic tumors of the parotid gland	
Squamous cell carcinomas of the skin	15
Malignant melanoma	2
Invasive ductal carcinoma of the breast	1
Thyroid papillary carcinoma	1
Metastatic tumors of the submandibular gland	
Squamous cell carcinomas of the lip	6
Squamous cell carcinomas of the oral cavity	1
Nasopharyngeal carcinoma	1
Small cell neuroendocrine carcinoma of the lung	1

## DISCUSSION

Salivary gland tumors, whether benign or malignant, show very different histopathological characteristics. Therefore, the accurate classification of these tumors according to their biological characteristics and histology is very important for the proper treatment plan. The classification of salivary gland tumors proposed by the World Health Organization and revised in 2017 is widely used all over the world. This study was also planned according to these classification criteria.

Salivary gland tumors can be seen in both sexes. In our study, the male: female ratio was found as 1.3:1 for benign tumors, 1.06:1 for malignant tumors. According to these results, it can be said that these tumors are more commonly seen in men. Although some studies have reported salivary gland tumors more often affected male [5–7], some studies have reported female predominance [8–11]. The high prevalence of Warthin tumors in our study population and the presence of significant male dominance in these tumors stand out as the most important factor determining the male: female ratio in our study.

Salivary gland tumors are rarely seen in children, and their incidence increases especially after the age of 40 years. In previous studies, benign tumors were reported to be most commonly seen in the 4<sup>th</sup> and 5<sup>th</sup> decades and malignant tumors in the 7<sup>th</sup> decades [8, 11, 12]. In our study, the mean age of all patients was 50 years and the median age was 52 years. Furthermore, the mean age in malignant tumors was found to be significantly higher compared to benign tumors.

The majority of salivary gland tumors are located in the parotid gland. Submandibular gland and minor salivary gland tumors are seen at similar rates. In large series of studies on this subject, their incidence has been reported as between 61%–83% for parotid gland tumors, 10%–17% for submandibular gland tumors, and 3%–26% for minor salivary gland tumors [5–15]. Sublingual gland tumors account for less than 1% of all tumors. In our study, salivary gland tumors were most frequently detected in the parotid gland (80%), followed by the submandibular gland (14%) and minor salivary glands (6%). It is noteworthy that minor salivary gland tumors were relatively rare in our region. In addition, the absence of the tumors located in the sublingual gland supports the conclusion that tumors in this localization are very rarely seen.

In general, the majority of salivary gland tumors are in benign character. However, malignancy rates vary according to the localization of tumors. In previous studies carried out on this subject, the rates of all salivary gland tumors' being benign were reported to be between 60% and 80% [5–7]. In our study, 71% of the salivary gland tumors were observed to be in benign character, similar to the literature. When the tumors were evaluated according to their localizations, only 24% of the parotid tumors were malignant, while this rate increased to 44% in the submandibular gland and 59% in the minor salivary glands. Our results support the conclusion that an inverse relationship exists between the incidence of salivary gland tumors by site and the percentage of malignancy.

In our study, the most frequently detected benign salivary gland tumor was observed as pleomorphic adenoma. The second most frequently detected benign tumor was Warthin tumor. Pleomorphic adenoma accounted for 47% of benign tumors, while Warthin tumor accounted for 37% of them. In previous studies, pleomorphic adenoma has been reported to be the most common benign tumor in all salivary glands [5–17]. However, in our study, Warthin tumor was detected in the parotid gland more than pleomorphic adenoma, unlike the literature. In addition, among all salivary gland tumors, Warthin tumor rate was reported as between 6% and 21% in large series of studies conducted in different regions of the world [5–16], while it was found as 26.2% in our study. In the light of this information, it can be said that Warthin tumor is more frequently seen in our region compared to many parts of the world.

Many studies have found the most common primary malignancy in the salivary glands to be mucoepidermoid

carcinoma [6, 7, 9, 11–14, 16]. However, there are also studies reporting that adenoid cystic carcinoma is seen more frequently [5, 8, 10, 15, 18]. In our cases, mucoepidermoid carcinoma was found as the most common tumor. Adenoid cystic carcinoma ranks third after acinic cell carcinoma. Adenoid cystic carcinomas are known to be the most frequently seen tumor of the minor salivary glands. In our study, we think that the low rate of minor salivary gland tumors is effective in the low rate of adenoid cystic carcinomas.

## Conclusion

In conclusion, the distribution of the salivary gland tumors detected in our department in the last 15 years was found to be substantially similar to other worldwide series. Unlike the literature, in our study, we concluded that salivary gland tumors were seen slightly more in males, minor salivary gland tumors were relatively rare, and Warthin tumors were more frequently detected in our region.

**Ethics Committee Approval:** The Pamukkale University Clinical Research Ethics Committee granted approval for this study (date: 27.05.2014, number: 60116787-020/30512).

**Conflict of Interest:** No conflict of interest was declared by the authors.

**Financial Disclosure:** The authors declared that this study has received no financial support.

**Authorship Contributions:** Concept – EM, COK, FT, FNA, BT, FB; Design – EM, COK, FT, FNA, BT, FB; Supervision – EM, COK, FT, FNA, BT, FB; Fundings – EM, FB; Materials – EM, COK, FB; Data collection and/or processing – EM, COK; Analysis and/or interpretation – EM, COK, FNA, FB; Literature review – EM, COK, FB; Writing – EM, COK, FT, FNA, BT, FB; Critical review – EM, COK, FT, FNA, BT, FB.

## REFERENCES

1. Tumours of salivary glands In: El-Naggar AK, Chan JKC, Grandis JR, Takata T, Slootweg PJ, editors. WHO classification of head and neck tumours, 4<sup>th</sup> ed. Lyon: International Agency for Research on Cancer; 2017. p. 159–202.
2. Saade ER, Bell DM, Hanna EY. Benign neoplasms of the Salivary Glands. In: Flint PW, Haughey BH, Lund VL, Niparko JK, Robbins KT, Thomas JG, editors. Cummings Otolaryngology Head and Neck Surgery. 6<sup>th</sup> ed. Philadelphia: Elsevier Saunders Inc; 2015. p. 1238–57.
3. Lin HH, Limesand KH, Ann DK. Current State of Knowledge on Salivary Gland Cancers. *Crit Rev Oncol* 2018;23:139–51.
4. Tamaki T, Dong Y, Ohno Y, Sobue T, Nishimoto H, Shibata A. The burden of rare cancer in Japan: application of the RARECARE definition. *Cancer Epidemiol* 2014;38:490–5.
5. Sentani K, Ogawa I, Ozasa K, Sadakane A, Utada M, Tsuya T, et al. Characteristics of 5015 Salivary Gland Neoplasms Registered in the Hiroshima Tumor Tissue Registry over a Period of 39 Years. *J Clin Med* 2019;8:566.
6. Amin NS, Shah SA, Prajapati SG, Goswami HM. Histomorphological spectrum of salivary gland tumors in a tertiary care hospital—A retrospective study. *Int J Med Sci Public Health* 2017;6:299–302.
7. Li LJ, Li Y, Wen YM, Liu H, Zhao HW. Clinical analysis of salivary gland tumor cases in West China in past 50 years. *Oral Oncol* 2008;44:187–92.
8. de Oliveira FA, Duarte EC, Taveira CT, Máximo AA, de Aquino EC, Alencar Rde C, Vencio EF. Salivary gland tumor: a review of 599 cases in a Brazilian population. *Head Neck Pathol* 2009;3:271–5.
9. Etit D, Ekinci N, Tan A, Altinel D, Dag F. An analysis of salivary gland neoplasms: a 12-year, single-institution experience in Turkey. *Ear Nose Throat J* 2012;91:125–9.
10. Satko I, Stanko P, Longauerová I. Salivary gland tumours treated in the stomatological clinics in Bratislava. *J Craniomaxillofac Surg* 2000;28:56–61.
11. Ito FA, Ito K, Vargas PA, de Almeida OP, Lopes MA. Salivary gland tumors in a Brazilian population: a retrospective study of 496 cases. *Int J Oral Maxillofac Surg* 2005;34:533–6.
12. Williams NP, Boyd DL, Choy L, Hanchard B. Salivary gland lesions: a Jamaican perspective. *West Indian Med J* 2001;50:62–5.
13. Spiro RH. Salivary neoplasms: overview of a 35-year experience with 2,807 patients. *Head Neck Surg* 1986;8:177–84.
14. Edizer DT, Server EA, Yiğit Ö, Yıldız M. Role of Fine-Needle Aspiration Biopsy in the Management of Salivary Gland Masses. *Türk Arch Otorhinolaryngol* 2016;54:105–11.
15. Lima SS, Soares AF, de Amorim RF, Freitas Rde A. Epidemiologic profile of salivary gland neoplasms: analysis of 245 cases. [Article in Portuguese]. *Braz J Otorhinolaryngol* 2005;71:335–40.
16. Çukurova İ, Özkul D, Demirhan E, Mengi E, Yalçın Y, Tan A. Salivary Gland Masses: Analysis of 155 Cases. *Tepecik Eğitim Hast Derg* 2008;18:30–5.
17. Altın F, Alimoğlu Y, Barcan Y. Evaluation of the patients with parotis mass in the last 7 years: retrospective analysis of 211 patients. *KBB-Forum* 2019;18:1–5.
18. Yağız C, Ada M, Yener M, Oğuz F. Malignant Tumors of the Salivary Glands. *Türk Arch Otorhinolaryngol* 2002;40:265–8.