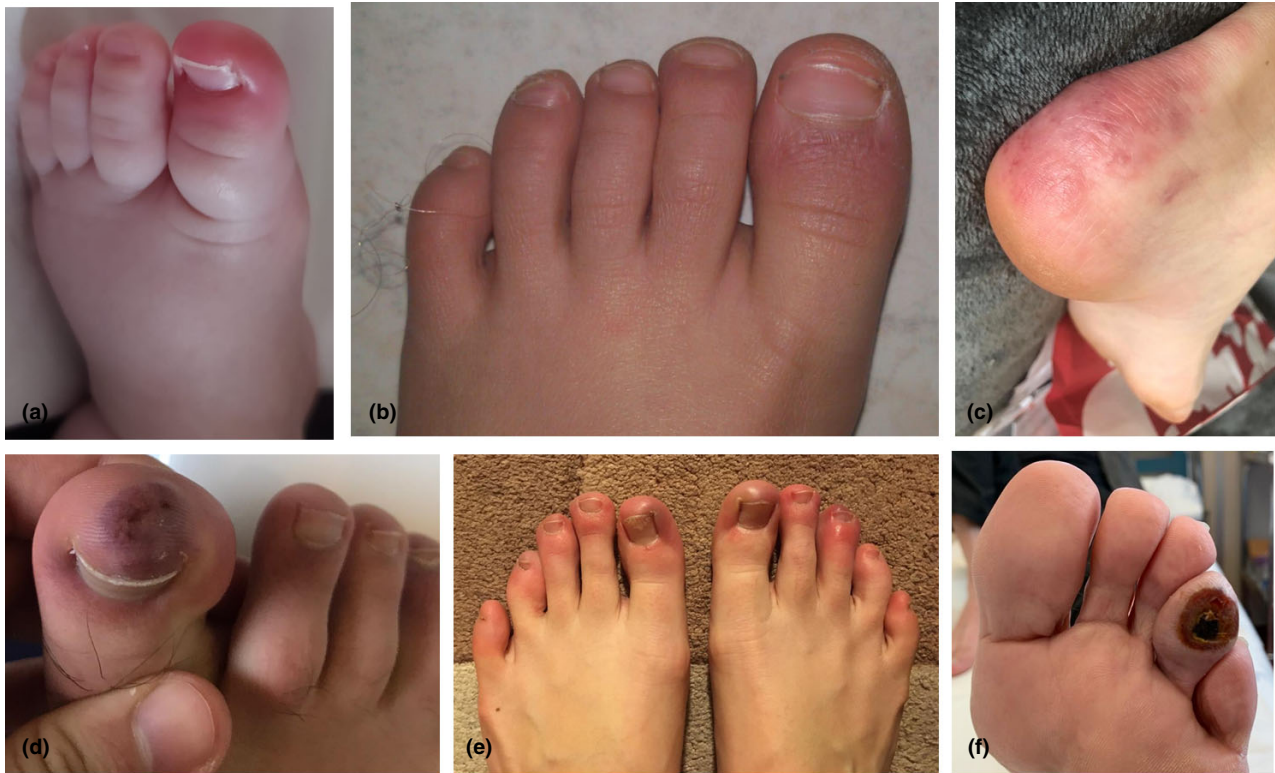



**Figure 2** (a) Swelling with erythema and oedema of the left big toe of a 4-year-old infant, apparently not painful, whose mother had been feverish for 20 days. (b) This is the left foot of a 9-year-old girl, daughter of the patient mentioned in Fig. 1, who had developed these erythematous-violaceous lesions on the toes bilaterally, a few days before the onset of the father's manifestations. (c) A 11-year-old boy who developed erythematous-purpuric infiltrate plaques to the heels about 10 days after the onset of fever in the mother, poorly responsive to the application of local steroid. (d) Infiltrated and painful erythematous-violaceous plaque, appeared at the apex of the right big toe of a 25-year-old boy, asymptomatic. (e) Chilblain-like lesions bilaterally affecting the toes of a 28-year-old girl, asymptomatic. (f) Ulcerative, violaceous lesion, complication of a previous bullous lesion, on the plantar surface of the fourth toe of the left foot of a 60-year-old man, smoker, who came to our attention already at the end of February, free of systemic symptoms.

## References

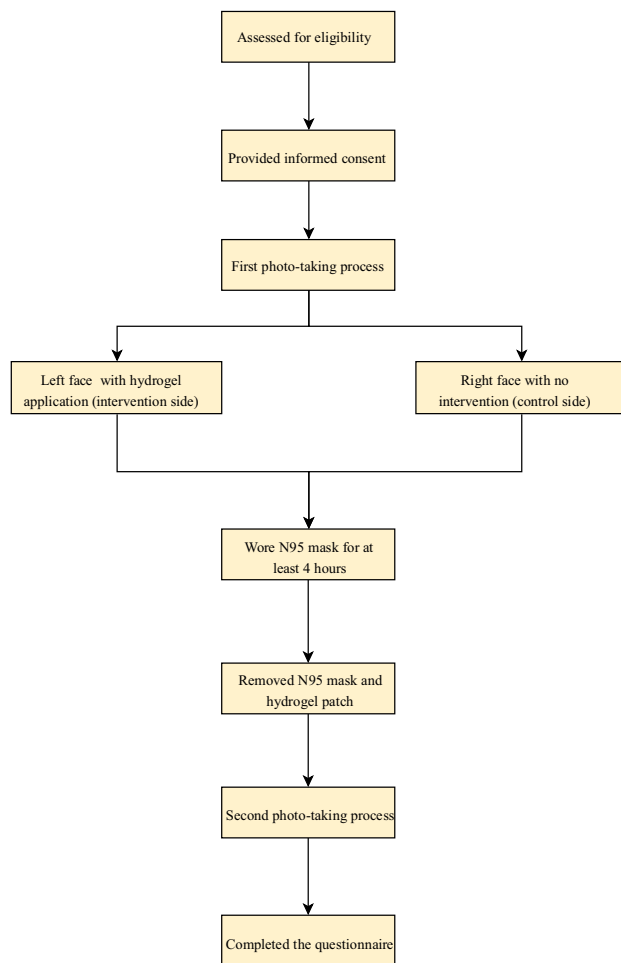
- 1 Estébanez A, Pérez-Santiago L, Silva E, Guillen-Climent S, García-Vázquez A, Ramón MDJ. Cutaneous manifestations in COVID-19: a new contribution. *Eur Acad Dermatol Venereol* 2020. <https://doi.org/10.1111/jdv.16474>. [Epub ahead of print].
- 2 Takci Z, Vahaboglu G, Eksioğlu H. Epidemiological patterns of perniosis, and its association with systemic disorder. *Clin Exp Dermatol* 2012; **37**: 844.
- 3 Cappel JA, Wetter DA. Clinical characteristics, etiologic associations, laboratory findings, treatment, and proposal of diagnostic criteria of pernio (chilblains) in a series of 104 patients at Mayo Clinic, 2000 to 2011. *Mayo Clin Proc* 2014; **89**: 207–215.
- 4 Wigley FM, Flavahan NA. Raynaud's phenomenon. *Rheum Dis Clin North Am* 1996; **22**: 765–781.
- 5 Cribier B, Djeridi N, Peltre B, Grosshans E. A histologic and immunohistochemical study of chilblains. *J Am Acad Dermatol* 2001; **45**: 924–929.

DOI: 10.1111/jdv.16636

## Efficacy of hydrogel patches in preventing facial skin damage caused by mask compression in fighting against coronavirus disease 2019: a short-term, self-controlled study

### Editor

During the recent ongoing coronavirus disease-2019 (COVID-19) outbreak, healthcare workers around the world are fighting at the front lines of this epidemic, as well as the dermatologists.<sup>1</sup> Our previous research<sup>2</sup> revealed that long-term wearing of N95 masks could lead to various facial skin lesions, which might



**Figure 1** Study flowchart.

affect their routine work and mental health.<sup>3,4</sup> More importantly, severe skin lesions (e.g. ulcers) might put them in danger of being infected. Generally, hydrogels have been used to treat patients with pressure ulcers.<sup>5</sup> Therefore, by analogy, we intended to conduct a short-term, self-controlled study to assess whether hydrogel patch application could also relieve the skin damage of healthcare workers caused by long period of mask-wearing.

This study was approved by the Medical Ethics Committee of Huazhong University of Science and Technology (No. [2020] (0063)), and the written informed consent was obtained. In this study, frontline healthcare workers (no gender preference) aged 20–55 were recruited (Fig. 1) after excluding those who already had facial skin damage, hypersensitive and pregnant people. Each participant needed to wear an N95 mask to work for at least 4 h with hydrogel patch applied on the left face and no intervention on the right face. Pre- and post-intervention facial photographs were taken, and a questionnaire concerning their

subjective feelings and skin damages of two sides was filled out. Their perception of different adverse skin reactions was recorded on a numeric scale from 0 to 5 in the questionnaire, with 5 indicating the most severe. Statistical analysis was performed by SPSS using paired sample *t*-test ( $P < 0.05$ ).

Nineteen participants enrolled in and completed the study. The adverse skin reactions and mean scores were illustrated in Fig. 2. In general, the mean total score of each participant's skin reactions was  $13.32 \pm 2.06$  (control side), much higher ( $P < 0.001$ ) than  $3.47 \pm 1.39$  (intervention side), indicating that the hydrogel patch could reduce the emergence or severity of skin damage overall. The skin damage that scored highest caused by mask compression was indentation, with the mean score of  $2.47 \pm 0.32$  (control side) and  $1.05 \pm 0.29$  (intervention side), respectively. Moreover, there were marked reductions in indentation ( $1.74$ ; 95% CI,  $0.86$ – $2.61$ ;  $P = .001$ ), redness ( $1.63$ ; 95% CI,  $0.81$ – $2.45$ ;  $P = 0.001$ ) and pain ( $1.47$ ; 95% CI,  $0.86$ – $2.08$ ;  $P < 0.001$ ) on the hydrogel side, as measured by the mean difference (Fig. 2). Regarding pimples, ulcers and erosions and blisters, there were no significant differences ( $P > 0.05$ ) with or without hydrogel application.

Water, sodium polyacrylate, cellulose gum and sodium hyaluronate are the main components in the hydrogel, acting as a soft-tissue cushion against mask compression for preventing indentation and relieving pain.<sup>6</sup> Moreover, the glycerin and several plant extracts in the hydrogel could keep the skin moisturized, calm and protect the skin barrier,<sup>7</sup> triggering the reduction of redness. In addition, it should be noted that after wearing the N95 mask, it is necessary to visually observe whether the edge of the mask fits tightly or to check for leaks through exhalation so as to ensure the seal of the N95 mask.

Although our results revealed the significant roles of hydrogel patches in preventing facial skin damage, there are several major limitations, especially the small sample size and relatively short period of intervention. A long-term controlled trial with more participants is warranted to verify our findings.

### Acknowledgements

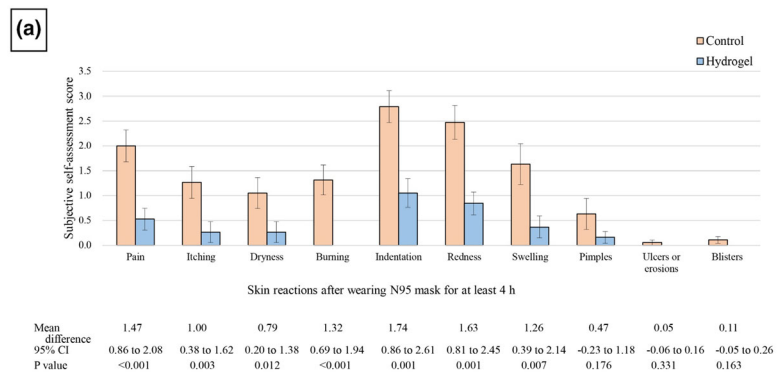
The authors thank all the healthcare workers participated in this study for their support. Meanwhile, we would like to show our own gratitude and great respect to the medical staff who are fighting against COVID-19 at the front lines. The patients in this manuscript have given written informed consent to publication of their case details.

### Conflict of Interest

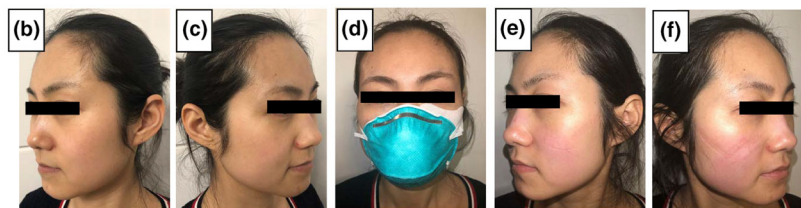
None.

### Funding Information

This work was supported by HUST COVID-19 Rapid Response Call Program (2020kfyXGYJ056) and Hubei Provincial Emergency Science and Technology Program for COVID-19 (2020FCA037).



**Figure 2** Mean score plotted with regard to different skin reactions (a) and representative photographs: the left (b) and right (c) sides of the face before the intervention; wearing N95 mask with hydrogel patch applied on the left face (d); the hydrogel side (e) showing less adverse skin reactions in contrast with the control side (f) subsequent to at least 4 h N95 mask compression.



L. Dong,<sup>1,2,†</sup> L. Yang,<sup>1,3,†</sup> Y. Li,<sup>1,2</sup> J. Yang,<sup>1,2</sup> X. An,<sup>1,2</sup> L. Yang,<sup>1,2</sup> N. Zhou,<sup>1,2</sup> Y. Zhang,<sup>1,2</sup> H. Du,<sup>1,2</sup> J. Lan,<sup>1,2</sup> Z. Song,<sup>1,4</sup> X. Miao,<sup>5</sup> J. Zhu,<sup>6</sup> J. Tao<sup>1,2,\*</sup>

<sup>1</sup>Department of Dermatology, Union Hospital, Tongji Medical College, Huazhong University of Science and Technology (HUST), Wuhan, China, <sup>2</sup>Hubei Engineering Research Center for Skin Repair and Theranostics, Wuhan, China, <sup>3</sup>School of Medicine, Hunan Normal University, Changsha, China, <sup>4</sup>The Second Clinical Medical College, Chongqing Medical University, Chongqing, China, <sup>5</sup>Department of Epidemiology and Biostatistics, School of Public Health, Tongji Medical College, HUST, Wuhan, China, <sup>6</sup>School of Chemistry and Chemical Engineering, HUST, Wuhan, China

\*Correspondence: J. Tao. E-mail: tjhappy@126.com

<sup>†</sup>These authors contributed equally to this work.

## References

- Zheng Y, Lai W. Dermatology staff participate in fight against Covid-19 in China. *J Eur Acad Dermatol Venereol* 2020; **34**: e210–e211.
- Lan J, Song Z, Miao X *et al*. Skin damage among health care workers managing coronavirus disease-2019. *J Am Acad Dermatol* 2020; **82**: 1215–1216.
- Schuster B, Ziefreund S, Albrecht H *et al*. Happiness in dermatology: a holistic evaluation of the mental burden of skin diseases. *J Eur Acad Dermatol Venereol* 2020. <https://doi.org/10.1111/jdv.16146>. [Epub ahead of print].
- Dalgard F, Svensson A, Sundby J, Dalgard OS. Self-reported skin morbidity and mental health. A population survey among adults in a Norwegian city. *Br J Dermatol* 2005; **153**: 145–149.
- Dumville JC, Stubbs N, Keogh SJ, Walker RM, Liu Z. Hydrogel dressings for treating pressure ulcers. *Cochrane Database Syst Rev* 2015; CD011226.
- Kaya AZ, Turani N, Akyuz M. The effectiveness of a hydrogel dressing compared with standard management of pressure ulcers. *J Wound Care* 2005; **14**: 42–44.

- Milani M, Sparavigna A. The 24-hour skin hydration and barrier function effects of a hyaluronic 1%, glycerin 5%, and Centella asiatica stem cells extract moisturizing fluid: an intra-subject, randomized, assessor-blinded study. *Clin Cosmet Investig Dermatol* 2017; **10**: 311–315.

DOI: 10.1111/jdv.16638

## Acral purpuric lesions (erythema multiforme type) associated with thrombotic vasculopathy in a child during the COVID-19 pandemic

Editor

Since the beginning of the COVID-19 pandemic, different types of cutaneous manifestations have been reported. In Spain, there were reports in the first weeks of April 2020 of an increase in purpuric acral lesions similar to perniosis on the hands and especially the feet of children and young adults. These patients do not normally present with clinical manifestations linked to COVID-19, and their PCR and serological tests are usually negative for specific IgM and IgG.<sup>1,2</sup>

These acral lesions manifest in two clinical forms and can present in an isolated or concomitant manner. The first type of