



## Case report

## Diffuse alveolar hemorrhage caused by exposure to organic dust



Yuzo Suzuki <sup>a, b, \*</sup>, Shiro Imokawa <sup>b</sup>, Fumiya Nihashi <sup>b</sup>, Tomohiro Uto <sup>b</sup>, Jun Sato <sup>b</sup>, Takafumi Suda <sup>a</sup>

<sup>a</sup> Second Division, Department of Internal Medicine, Hamamatsu University School of Medicine, Hamamatsu, Japan

<sup>b</sup> Respiratory Medicine, Iwata City Hospital, Iwata, Japan

## A B S T R A C T

## Keywords:

Diffuse alveolar hemorrhage  
Organic dust exposure

Diffuse alveolar hemorrhage, a life-threatening disease, can complicate various conditions. We herein describe, for the first time, a patient with diffuse alveolar hemorrhage caused by exposure to organic dust. A 49-year-old woman who worked as a cantaloupe farmer in a greenhouse was referred to our hospital for sudden onset of dyspnea 3 h after exposure to organic dust. A chest X-ray and computed tomography scan performed on admission showed diffuse ground-glass opacities in both lung fields. Suspecting hypersensitivity pneumonitis, fiberoptic bronchoscopy was performed. Mucopurulent sputum was present in the trachea and both bronchi, and bronchoalveolar lavage revealed a progressively bloody return, typical of diffuse alveolar hemorrhage. Based on the history and bronchoscopy findings, she was diagnosed with diffuse alveolar hemorrhage following exposure to organic dust and was treated with antibiotics and corticosteroids. Diffuse alveolar hemorrhage should be considered in the differential diagnosis of diffuse ground-glass opacities observed on radiographs in farmers following exposure to organic dust.

© 2015 The Authors. Published by Elsevier Ltd. This is an open access article under the CC BY-NC-ND license (<http://creativecommons.org/licenses/by-nc-nd/4.0/>).

## Introduction

Diffuse alveolar hemorrhage (DAH), a life-threatening disease, represents a syndrome associated with various conditions such as vasculitis, connective tissue diseases, infectious diseases causing acute respiratory distress syndrome and certain drugs [1]. Exposure to organic dust causes a variety of occupational pulmonary diseases in farmers such as hypersensitivity pneumonitis (HP), inhalation fever, organic dust toxicity syndrome (ODTS), and chronic bronchitis, and may have an acute onset after exposure to organic dust [2–4]. We describe the first case of a patient with diffuse alveolar hemorrhage (DAH) caused by exposure to organic dust.

## Case report

A 49-year-old woman working as a cantaloupe farmer in a greenhouse was referred to our hospital for sudden onset of

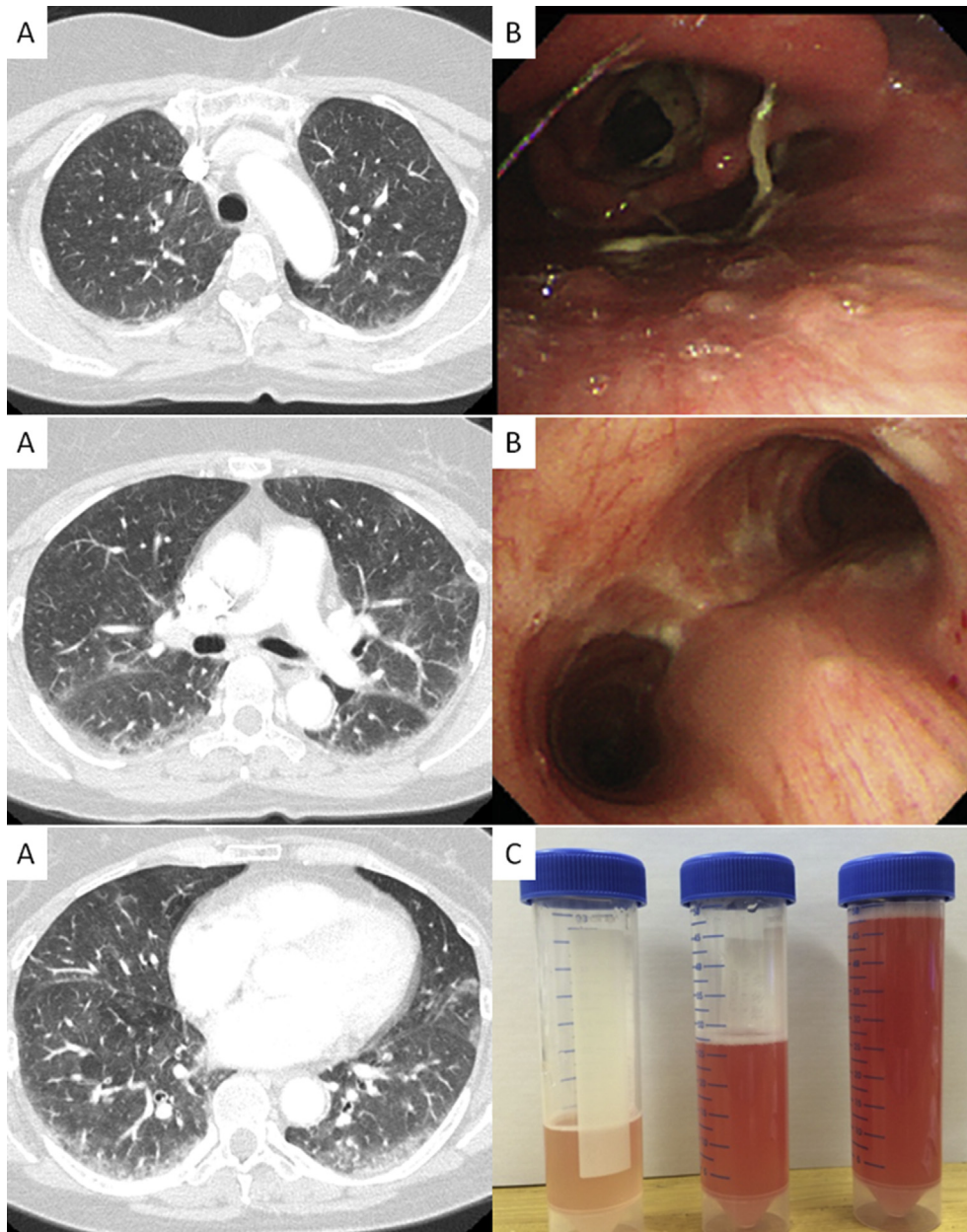
dyspnea, chills, and a non-productive cough. Three hours before admittance to our hospital, she had been packing soil mixed with leaf mold and compost into fertilizer bags for 4 h in a barn without using specific protection against organic dust inhalation. She had covered her mouth with a white towel, which turned black where her mouth had pressed against it. At the time of admission, she had tachycardia and a fever of 38.6 °C. Physical examination revealed moderate crackles on both sides of the lower lung fields and weak respiratory sounds. Laboratory studies disclosed the following values: PaO<sub>2</sub> 55.0 Torr; PaCO<sub>2</sub> 28.4 Torr (measured while the patient was breathing at room air); WBC count, 9100/mm<sup>3</sup> (90.4% neutrophils, 9.1% lymphocytes); Hb 14.0 g/dL; Plt 25.2 × 10<sup>4</sup>/mm<sup>3</sup>; and C-reactive protein (CRP) 0.18 mg/dL. The levels of prothrombin time (PT), activated partial thromboplastin time (APTT), and fibrinogen, KL-6, and SP-D were within normal range. Urine pneumococcal and *Legionella* antigen tests and the rapid influenza test were negative. Serological analyses showed no evidence of atypical pneumonia infection based on measuring *Mycoplasma pneumoniae*, *Chlamydia pneumoniae* and *Chlamydia psittaci* antibodies both in acute and convalescent phase samples.

A chest X-ray and computed tomography (CT) scan on admission showed diffuse ground-glass opacities in both lung fields (Fig. 1A). Suspecting hypersensitivity pneumonitis (HP), fiberoptic bronchoscopy was performed on the next day without the

Abbreviations: DAH, diffuse alveolar hemorrhage; HP, hypersensitivity pneumonitis; ODTS, organic dust toxicity syndrome; BAL, bronchoalveolar lavage.

\* Corresponding author. 1-20-1 Handayama Higashi-ku, Hamamatsu, Shizuoka 431-3129, Japan. Tel.: +81 53 435 2263; fax: +81 53 435 2354.

E-mail address: [yuzosuzu@hama-med.ac.jp](mailto:yuzosuzu@hama-med.ac.jp) (Y. Suzuki).



**Fig. 1.** The chest CT showed diffuse ground-glass opacities in both lung field (A). Bronchoscopic finding showed productive yellow sputum from trachea and bronchi (B). Bronchoalveolar lavage (BAL) revealed a progressively more bloody return, typical of diffuse alveolar hemorrhage (C).

administration of antibiotics. Surprisingly, fiberoptic bronchoscopy showed productive yellow sputum in the trachea and both bronchi (Fig. 1B) that was thought to be consistent with bacterial infection. Whilst bronchoalveolar lavage (BAL) revealed a progressively more bloody return with 86% neutrophils and 9.7% lymphocytes, typical of DAH (Fig. 1C). Microbiological analyses of samples collected for culture during bronchoscopy revealed non-specific pathogens; there were no fungal, or mycobacterial isolates. The rapid influenza diagnostic test was negative. She was treated with intravenously administration of antibiotics and methylprednisolone 1 g for three consecutive days, followed by oral administration of prednisolone for one month. These treatments dramatically improved the patient's symptoms and ground-glass opacities on CT. An exhaustive search showed no evidence of underlying conditions such as systemic vasculitis, connective tissue disease, drugs including anticoagulant drugs, or any specific pathogens causing DAH such as

influenza A, dengue, leptospirosis, malaria, and *Streptococcus aureus* [5].

### Discussion

To the best of our knowledge, this is the first report of DAH associated with exposure to organic dust. Exposure to organic dust is fairly common among farmers and causes occupational pulmonary diseases. A careful occupational exposure history is a key for diagnosing these diseases. This patient's history indicated extensive inhalation exposure to organic dust. The manifestations of respiratory symptoms in ODTS are similar to those in HP, but there are several differences. In ODTS, thoracic radiographs are often normal, the oxygen saturation level is within the normal range, and respiratory failure is very rare [3,4]. Meanwhile diffuse ground-glass opacities in both lung fields are a common radiographic finding

and hypoxia is frequently observed in HP patients [2]. In addition, an elevated lymphocyte ratio in BAL samples is found in HP. In the present case, a strong association between organic dust exposure and the occurrence of symptoms was found. However, the clinical manifestations, radiographic and BAL findings of DAH (with elevated neutrophils) are different than those associated with HP or ODTS.

DAH is a clinical syndrome that often causes respiratory failure and is known to be complicated by various conditions including bacterial, viral, and fungal infections [1,5]. Microbiological and serological analyses did not reveal any specific pathogens. A massive inhalation of organic dust is considered potentially to include infectious agents and endotoxins, which leads to a severe inflammatory reaction in the airways resulting in DAH.

In summary, this is the first case of exposure to organic dust causing DAH and mimicking HP and ODTS. DAH should be considered in the differential diagnosis of diffuse ground-glass opacities occurring in farmers following exposure to organic dust.

#### Author contributions

YS: Conception and design, and Manuscript writing, Final approve of manuscript; FN,TU, and JS: Data collection; IS and TS: Conception and design, Administrative support, Final approve of manuscript.

#### Role of funding source

The funders had no role in study design, data collection and analysis, decision to publish, or preparation of the manuscript.

#### Consent

Written informed consent was obtained from the patient for publication of this case report and any accompanying images. A copy of the written consent is available for review by the Editor of this journal.

#### References

- [1] Lara AR, Schwarz MI. Diffuse alveolar hemorrhage. *Chest* 2010;137:1164–71.
- [2] Selman M, Pardo A, King Jr TE. Hypersensitivity pneumonitis: insights in diagnosis and pathobiology. *Am J Respir Crit Care Med* 2012;186:314–24.
- [3] Seifert SA, Von Essen S, Jacobitz K, Crouch R, Lintner CP. Organic dust toxic syndrome: a review. *J Toxicol Clin Toxicol* 2003;41:185–93.
- [4] von Essen S, Anderson CI, Smith LM. Organic dust toxic syndrome: a noninfectious febrile illness after exposure to the hog barn environment. *J Swine Health Prod* 2005;13:273–6.
- [5] von Ranke FM, Zanetti G, Hochegger B, Marchiori E. Infectious diseases causing diffuse alveolar hemorrhage in immunocompetent patients: a state-of-the-art review. *Lung* 2013;191:9–18.