

CASE REPORT

Essential thrombocythemia with (type2) calreticulin presented as stuttering priapism case report and review of literature

Elrazi Awadelkarim Ali¹  | Abdulqadir Jeprel Nashwan²  | Mohamed A Yassin³ 

¹Internal Medicine Department, Hamad Medical Corporation, Doha, Qatar

²Nursing Department, Hamad Medical Corporation, Doha, Qatar

³Hematology and Oncology Department, Hamad Medical Corporation, Doha, Qatar

Correspondence

Elrazi Ali, Department: Internal Medicine, Hamad Medical Corporation, Al-Rayyan road, PO Box 3050, 00000 Doha, Qatar.
Email: razinho5@gmail.com

Abstract

Priapism is a rare presentation and complication of ET that might be underreported. In ET, priapism can present as an ischemic or stuttering type. These patients are more likely to be anemic and have a high platelet count.

KEYWORDS

calreticulin, erectile dysfunction, essential thrombocythemia, male fertility, myeloproliferative neoplasms, priapism

1 | BACKGROUND

Essential thrombocythemia is a myeloproliferative neoplasm (MPN), characterized by clonal proliferation of myeloid cell line with a significant increase in platelet count. Diagnosis is made by meeting the 2016 WHO criteria with four major or three major and one minor criterion after excluding secondary causes of thrombocytosis. It usually an asymptomatic disease or presents with hemorrhagic or thrombotic complications. Priapism is a prolonged penile erection not related to sexual stimulation. The longer the duration of priapism, the higher the risk for penile fibrosis and erectile dysfunction, which have a devastating outcome on male fertility. Priapism is seen more commonly in hematological conditions, that is, sickle cell anemia. In myeloproliferative neoplasms, it is relatively more common with chronic myeloid leukemia and is rarely reported with essential thrombocythemia, polycythemia Vera, or primary myelofibrosis. We are reporting a case of a 51-year-old man with persistent thrombocytosis diagnosed as essential thrombocythemia with *CALR* (Type 2). The patient developed priapism with the onset of rising

in platelets count. This is the first report in the literature of *CALR* type 2 essential thrombocythemia presenting with priapism. The case sheds light on rare or underreported complication and reviewing our current knowledge concerning such rare complication.

Priapism is a persistent erection of the penis that is not associated with sexual stimulation or desire lasting more than 4 hours.¹ Priapism can be classified as ischemic, nonischemic, or stuttering. Stuttering priapism is defined; recurrent priapism lasting less than 4 hours.² Commonly, no cause is identified; secondary causes include medications, especially intracorporal injections or medical conditions such as hematological diseases, particularly sickle cell disease. But it is uncommon to be seen with essential thrombocythemia (ET). It adversely affects the quality of life, sexual function (SF), and physical wellness of the affected patients,³ besides the risk of penile fibrosis and permanent erectile dysfunction.^{2,4} The underlying pathophysiology is not clearly understood; several mechanisms have been postulated. This includes disturbed nitrous oxide (NO), phosphodiesterase enzyme activity, and disturbed autoregulation of the penile circulation.^{1,5} There are few reported cases of priapism as the presenting feature of ET.

This is an open access article under the terms of the Creative Commons Attribution License, which permits use, distribution and reproduction in any medium, provided the original work is properly cited.

© 2020 The Authors. *Clinical Case Reports* published by John Wiley & Sons Ltd.

2 | CASE REPORT

A 51-year-old gentleman with a past medical history of sleeve gastrectomy in 2014 and gastric bypass 2016 for morbid obesity, married with no children and referred from a primary healthcare center for evaluation of high platelets, discovered incidentally during a medical checkup. During that time, he reported recurrent painful erections two to three times per month, lasting 15–60 minutes. No history of trauma or medication use. He has no headache, dizziness, tinnitus, chest pain, or bleeding from any site. No family history of hematological or connective tissue diseases. He had previous normal platelet count with range of $(200\text{--}260 \times 10^3/\mu\text{L})$ until age of 50 years, then found to have platelet count $1189 \times 10^3/\mu\text{L}$ ($150\text{--}400 \times 10^3/\mu\text{L}$) (Figure 1), had hemoglobin level of 11.2 gm/dL (13–17 gm/dL) WBC $8.7 \times 10^3/\mu$ ($4\text{--}10 \times 10^3/\mu$), iron level 7.00 $\mu\text{mol/L}$ (11.6–31.30 $\mu\text{mol/L}$) Fe saturation 11% (15%–45%), transferrin 2.60 gm/L (2–3.6 gm/L), and ferritin 3.8 mcg/L (24–336 mcg/L). Anemia was corrected with iron replacement therapy and repeated follow-up ferritin improved to 529.0 $\mu\text{g/L}$. ANA and ANCA were negative. Further workup showed BCR/ABL1 t(9;22)(q34;q11.2) negative. Molecular study for JAK2 mutation was negative but positive for Type 2 calreticulin mutation. Bone marrow biopsy findings are consistent with a myeloproliferative neoplasm (consistent with ET).

The peripheral blood smear showed increased numbers of platelets with some large and few giant forms. Chromosomal analysis revealed normal Karyotype: 46,XY. US Abdomen showed normal liver and spleen, no ascites, and no organomegaly. After the diagnosis of ET, the patient was counseled regarding the recurrence of priapism. He was started on aspirin 75 mg daily and is following with urology for priapism. He did not require any urological intervention for priapism.

3 | DISCUSSION

This patient platelet count was normal up to the time of presentation with priapism, as shown in (Figure 1). His only previous conditions were infertility and sleeve gastrectomy. The majority of patients with essential thrombocythemia are asymptomatic, discovered accidentally by chance during routine blood work or investigation for another reason.⁶ Others present with vasomotor symptoms, thrombotic, or hemorrhagic complications.⁷ Priapism is a rare medical condition incidence in the United States is 0.73 per 100 000 men per year.⁸ It is rare for ET to present as priapism. Our literature search revealed 11 reported cases with ET who developed or presented with priapism.

The most common type of priapism is ischemic (low flow), while nonischemic is much rare and related to trauma.⁹ Stuttering priapism results and can lead to ischemic priapism, and they share similar causes.⁹ It thought that the initial insult results in defective penile circulation due to loss of phosphodiesterase type 5 (PDE5) regulatory function which in turn result in altered NO and cyclic guanosine monophosphate signaling mechanisms.^{10,11} The major hematological cause for ischemic priapism is sickle cell anemia. In ET, the mechanism is probably related to high platelet count and platelets sludging in the corpora cavernosa, similar to RBC sludging in sickle cell disease and WBC sludging in leukemia.¹² Subsequent stasis and disturbed NO and cyclic guanosine monophosphate signaling. This might be precipitated by increased viscosity due to dehydration or release of free hemoglobin¹³ secondary to hemolysis similar to sickle cell anemia, as many patients had low hemoglobin levels, as seen in (Table 1). The table shows that most of hemoglobin levels are in the low to lower normal limits, but no patient had high hemoglobin levels, opposite to what can be expected that

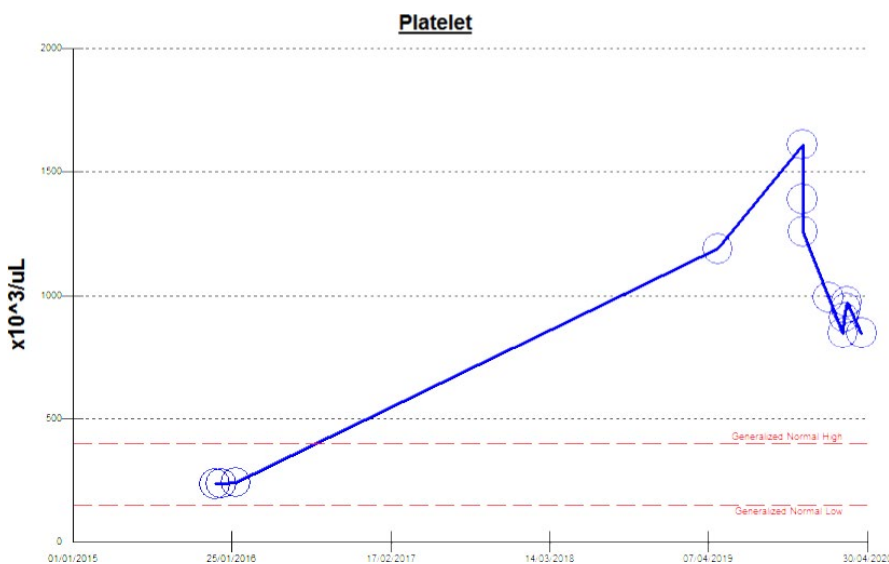


FIGURE 1 Shows previously normal platelet count until the time of presentation on April 30, 2019

polycythemia might increase the viscosity of the blood and enhance thrombosis. This is supported by observing patients with other myeloproliferative neoplasms who developed priapism. In one study 430 patients with chronic myeloid leukemia, those who developed priapism at diagnosis (8 patients) had lower hemoglobin levels compared to chronic myeloid leukemia patients who did not develop priapism.¹⁴ In the same study, the mean hemoglobin level in patients with priapism was 8.4 ± 2.3 g/dL, compared to a hemoglobin level of 10.8 ± 2.5 g/dL in chronic myeloid leukemia patient's control who did not develop priapism. The age and platelet count did not have a significant effect on priapism in these patients with chronic myeloid leukemia. To the best of our knowledge, there are no reports of cases of adults with polycythemia Vera who developed priapism, which might indicate that anemia has a sort of synergistic effect with leukocytosis in the pathogenesis of priapism in CML patients. And it might affect the type of priapism as most CML type is ischemic. But it is difficult to generalize this observation to ET. The effect of hemoglobin level on essential thrombocythemia with priapism is not clear, and it is not clear if the hemoglobin level itself is related to the type of priapism due to incomplete information. However, anemia can enhance thrombosis and the risk of thromboembolism.¹⁵ This effect is not related to reactive thrombocytosis and might be linked to an increase in plasminogen inhibitors or the levels of clotting factors.^{16,17} In the table, the WBC count is variable but at a high level for most patients. From (Table 1), it is noted that some patients presented after years from the onset of priapism. This may indicate the complaint of priapism is underreported, especially for patients with stuttering priapism who develop erection for a shorter duration of time and subsides spontaneously as with our case. While patients with painful ischemic priapism have prolonged, painful erection usually seeks medical attention from the first time. This can be the reason that chronic myeloid leukemia reports of priapism are relatively more common 1.7% compared to ET¹⁸ because CML type is predominantly ischemic. At the same time, ET can be ischemic or stuttering.

Penile tissue composes of two spongy erectile tissue called corpora cavernosa and another spongy tissue in the ventral side of the penis called the corpus spongiosum. Priapism usually involves the cavernosal tissue; less commonly, it can affect the spongiosum and glans penis.^{19,20} After 4-6 hours of erection, tissue damage can be detected at a microscopic level.²¹ And with more prolonged erection, there is a high risk of permanent damage and fibrosis. If it persists more than 24 hours, the risk of permanent erectile dysfunction is more than 90%²² and a drastic effect on male fertility.

Most of these cases are reported a long time ago, and few are reported after the 2008 WHO criteria for ET, which explains why no genetic studies were done for the cases before 2008. Two cases were *Jak2* +, and our case is the first case with *CALR* type 2 ET to present with priapism. Usually, the platelet count is higher with *CALR* mutation than *Jak2* mutation²³ but with fewer thrombotic or hemorrhagic complications than *Jak2*. Due to the limited numbers of reported cases, it is not clear if the priapism is related to *Jak 2* mutation over *CALR* mutation. As *Jak2* mutation is more common, it is expected to be seen more with *Jak2* than *CALR* mutation. Other ET patients who developed priapism also had high platelet count (830-4100) (Table 1). Some patients had splenomegaly. Splenomegaly is seen in up to 51% of ET patients by using ultrasonography.²⁴ In table, 6/11 had splenomegaly or splenectomy. This ratio is close to ET patients without priapism. The effect of age is ill-defined, as it was reported in children²⁵ as well in a patient aged 71 years²⁶; it seems that age plays a minor role, if any. Additionally, priapism pathophysiology is not clear, and ET presented with different types of priapism stuttering and ischemic,^{26,27} which makes the underlying mechanism of such priapism more debatable.

Generally, stuttering priapism management depends on the situation at presentation. If the patient is in acute priapic even, priapism will be managed as Ischemic priapism.⁹ If the patient is not in a priapic state, then the aim is to prevent the recurrence of the condition.²⁸ Management starts with patient counseling regarding early measures to control priapism-like physical activity, urination, ejaculation, fluid intake, and cold baths.²⁹ Various medications had shown benefits. Intracavernosal injection of α -agonists like phenylephrine or oral-like pseudoephedrine is used to contract the smooth muscles allowing detumescence.³⁰ Other modalities include the use of hormonal therapy to suppress testosterone-like goserelin acetate, leuprolide, and ketoconazole. Additional effective medications include phosphodiesterase 5 inhibitors, gabapentin,³¹ and terbinafine.³⁰

4 | CONCLUSION

Priapism is a rare presentation and complication of ET. It can present as ischemic or stuttering types. Stuttering priapism might be underreported which explains the fewer reports in ET compared to CML because in CML priapism is mostly low flow type. The main risk factors are not well-understood due to the old and few reported cases. Splenomegaly, age, and type of mutation appear to have little impact. However, the distinctive feature is the high platelet count with or without

TABLE 1 List of published cases of priapism (listed chronologically)

Published case reports	Age (Y)	Time from onset of priapism to presentation and diagnosis	Type of priapism	PLT $\times 10^9/L$	WBC $\times 10^9/L$	Hb g/dL
Patient 1 ³²	60	5 mo	N/A	1500-3900	12	4.7
Patient 2 ³²	66	N/A	N/A	700-4100	2.9-41	6
Patient 3 ³³	25	36 h	N/A	3000	14	N/A
Patient 4 ¹²	34	Short-term onset	N/A	1245	15.4	13.2
Patient 5 ³⁴	45	N/A	N/A	1200-1600	N/A	N/A
Patient 6 ³⁵	7	N/A	N/A	4370	19	12
Patient 7-8 ²⁵	Mean age 12	N/A	N/A	2300-2900	23.4-30.6	N/A
Patient 9 ²⁷	21	2 y	Stuttering	830	17	12.2
Patient 10 ²⁶	71	3 d	Ischemic	945	N/A	N/A
Patient 11 ³⁶	31	24 h	Stuttering	1424	18.3	13
Our patient 12	51	1 y	Stuttering	1189	8.7	11.2

Note: The table shows the reported cases of ET arranged by chronological order. Before 2008, there was no genetic testing for diagnosis of ET (2008 WHO criteria). Abbreviation: N/A, No data available.

anemia but no polycythemia. Early diagnosis and rapid management of such cases could lead to favorable prognosis and better outcome preserving the erectile ability of corpora cavernosa.

ACKNOWLEDGMENTS

I wish to show my gratitude to the Internal medicine residency program, to Dr Dabia Hamad Almohanadi, and I would like to thank the patient for allowing us to share his case. Open Access funding provided by the Qatar National Library.

CONFLICT OF INTEREST

None declared.

AUTHOR CONTRIBUTIONS

EAA: concept, writing, editing and approval of final manuscript. MAY: concept, writing, editing and approval of final manuscript. AJN: writing, editing, and approval of final manuscript.

CONSENT

The consent for publication was obtained.

DATA AVAILABILITY STATEMENT

All data generated during this published case report are not publicly available. However, it is available up on request from the corresponding author with permission.

ORCID

Elrazi Awadelkarim Ali  <https://orcid.org/0000-0002-8967-433X>

Abdulqadir Jeprel Nashwan  <https://orcid.org/0000-0003-4845-4119>

Mohamed A Yassin  <https://orcid.org/0000-0002-1144-8076>

Mohamed A Yassin  <https://orcid.org/0000-0002-1144-8076>

Mohamed A Yassin  <https://orcid.org/0000-0002-1144-8076>

Mohamed A Yassin  <https://orcid.org/0000-0002-1144-8076>

REFERENCES

1. Champion HC, Bivalacqua TJ, Takimoto E, Kass DA, Burnett AL. Phosphodiesterase-5A dysregulation in penile erectile tissue is a mechanism of priapism. *Proc Natl Acad Sci USA*. 2005;102(5):1661-1666.
2. Broderick GA, Kadioglu A, Bivalacqua TJ, Ghanem H, Nehra A, Priapism SR. Pathogenesis, epidemiology, and management. *J Sex Med*. 2010;7:476-500.
3. Burnett AL, Anele UA, Derogatis LR. Priapism impact profile questionnaire: development and initial validation. *Urology*. 2015;85(6):1376-1381.

Type of mutation	Intervention/medication	Year of publication	Splenomegaly below costal margin (cm)	Criteria for diagnosis
N/A	N/A	1960	Hepatosplenomegaly	Bone marrow examination
N/A	N/A	1960	N/A	N/A
N/A	Plateletpheresis, aspiration winter procedure then plateletpheresis,/ busulfan	1979	Splenectomy due to splenic vein thrombosis 1976, was on anticoagulation until 1977	N/A
N/A	Blood clot was evacuated from the corpora cavernosa	1981	Splenectomy for ITP	N/A
N/A	Bilateral cavern-ostomy	1990	5 cm	N/A
N/A	Busulfan	1997	2 cm	N/A
N/A	Aspirin/dipyridamole	2000	N/A	The Polycythemia Vera Study Group criteria
Jak2	Repeated aspiration and instillation with phenylephrine/aspirin 75 mg hydroxyurea	2017	Mild splenomegaly on ultrasound	The revised WHO criteria for PSV, ET, PMF: an alternative proposal. Blood 2008
Jack2	Aspiration of corpus cavernosum and injection of phenylephrine/hydroxyurea	2019	N/A	2016 WHO criteria
Jack2	Aspiration of corpus cavernosum and injection of phenylephrine/ hydroxyurea acetyl salicylic acid	2020	No splenomegaly	2016 WHO criteria
CALR type 2	Aspirin	2020	No splenomegaly	2016 WHO criteria

- Burnett AL, Priapism BTJ. Current Principles and Practice. *Urol Clin North Am.* 2007;34:631-642.
- Burnett AL. Nitric oxide in the penis - Science and therapeutic implications from erectile dysfunction to priapism. *J Sex Med.* 2006;3(4):578-582.
- Wolanskyj AP, Lasho TL, Schwager SM, et al. JAK2V617F mutation in essential thrombocythaemia: clinical associations and long-term prognostic relevance. *Br J Haematol.* 2005;131(2):208-213.
- Yassin MA, Taher A, Mathews V, et al. MERGE: a multinational, multicenter observational registry for myeloproliferative neoplasms in Asia, including Middle East, Turkey, and Algeria. *Cancer Med.* 2020;9:4512-4526.
- Roghamann F, Becker A, Sammon JD, et al. Incidence of priapism in emergency departments in the United States. *J Urol.* 2013;190(4):1275-1280.
- Montague DK, Jarow J, Broderick GA, et al. American urological association guideline on the management of priapism. *J Urol.* 2003;170(4 I):1318-1324.
- Bivalacqua TJ, Priapism BAL. New concepts in the pathophysiology and new treatment strategies. *Curr Urol Rep.* 2006;7:497-502.
- Burnett AL, Bivalacqua TJ, Champion HC, Musicki B. Long-term oral phosphodiesterase 5 inhibitor therapy alleviates recurrent priapism. *Urology.* 2006;67(5):1043-1048.
- Welford C, Spies SM, Green D. Priapism in primary thrombocytopenia. *Arch Intern Med.* 1981;141(6):807-808.
- Nolan VG, Wyszynski DF, Farrer LA, Steinberg MH. Hemolysis-associated priapism in sickle cell disease. *Blood.* 2005;106(9):3264-3267.
- Savage DG, Szydlo RM, Goldman JM. Clinical features at diagnosis in 430 patients with chronic myeloid leukaemia seen at a referral centre over a 16-year period. *Br J Haematol [Internet].* 1997;96(1):111-116.
- Hung SH, Lin HC, Chung SD. Association between venous thromboembolism and iron-deficiency anemia: a population-based study. *Blood Coagul Fibrinolysis.* 2015;26(4):368-372.
- Turpini R, Stefanini M. The nature and mechanism of the hemostatic breakdown in the course of experimental hemorrhagic shock. *J Clin Invest.* 1959;38(1 Part 1):53-65.
- Çalışkan Ü, Öner AF, Kabakuş N, Koç H. Diminished platelet aggregation in patients with iron deficiency anemia. *Clin Appl Thromb.* 1999;5(3):161-163.
- Jandial A, Mishra K, Sandal R, et al. CML patients presenting with priapism: Is there any disparity in outcome? *J Clin Oncol.* 2019;37(15_suppl):e18545.
- Sharpsteen JR, Powars D, Johnson C, Rogers ZR, Williams WD, Posch RJ. Multisystem damage associated with tricorporal priapism in sickle cell disease. *Am J Med.* 1993;94(3):289-295.
- Lewis JH, Javidan J, Keoleian CM, Shetty SD. Management of partial segmental priapism. *Urology.* 2001;57(1):169.
- Pryor J, Akkus E, Alter G, et al. Priapism. *J Sex Med.* 2004;1(1):116-120.

22. Pryor JP, Hehir M. The management of priapism. *Br J Urol*. 1982;54(6):751-754.
23. Verger E, Cassinat B, Chauveau A, et al. Clinical and molecular response to interferon- α therapy in essential thrombocythemia patients with CALR mutations. *Blood*. 2015;126(24):2585-2591.
24. Picardi M, Martinelli V, Ciancia R, et al. Measurement of spleen volume by ultrasound scanning in patients with thrombocytosis: a prospective study. *Blood*. 2002;99(11):4228-4230.
25. Kudo K, Horibe K, Iwase K, Kondo M, Kojima S. Clinical features of essential thrombocythemia in three children. *Rinsho Ketsueki [Internet]*. 2000;41(11):1164-1170.
26. Matsumoto Y, Amano T, Shimojima Y, Imao T, Kato H. Ischemic priapism associated with essential thrombocythemia: A case report. *Acta Urol Jpn*. 2019;65(7):315-317.
27. Goel S, Sokhal AK, Singh BP, Aggarwal A. Priapism due to essential thrombocythaemia: a rare causation. *BMJ Case Reports*. 2017;bcr-2017. <http://dx.doi.org/10.1136/bcr-2017-221116>.
28. Kousournas G, Muneer A, Ralph D, Zacharakis E. Contemporary best practice in the evaluation and management of stuttering priapism [Internet]. *Ther Adv Urol*. 2017;9:227-238.
29. Maples BL, Hagemann TM. Treatment of priapism in pediatric patients with sickle cell disease [Internet]. *Am J Health System Pharm*. 2004;61:355-363.
30. Lowe FC, Jarow JP. Placebo-controlled study of oral terbutaline and pseudoephedrine in management of prostaglandin E1-induced prolonged erections. *Urology*. 1993;42(1):51-53.
31. Perimenis P, Athanasopoulos A, Papanthanasopoulos P, Barbalias G. Gabapentin in the management of the recurrent, refractory, idiopathic priapism. *Int J Impot Res [Internet]*. 2004;16(1):84-85.
32. Ozer FL, Truax WE, Miesch DC, Levin WG. Primary hemorrhagic thrombocythemia. *Am J Med*. 1960;28(5):807-823.
33. Leifer W, Leifer G. Priapism caused by primary thrombocythemia. *J Urol [Internet]*. 1979;121(2):254-255.
34. Durosini MA, Badejo OA, Ayoade BA, Odelana CO. Essential thrombocythaemia associated with priapism: a case report. *East Afr Med J [Internet]*. 1990;67(8):594-595.
35. Michiels JJ, Van Genderen PJJ. Essential thrombocythemia in childhood. *Semin Thromb Hemost*. 1997;23(Issue 3):295-301.
36. Verma SP, Kumar N, Jain M, Tripathi AK. Essential thrombocythemia presenting with recurrent priapism: a case report and review of literature. *Am J Case Rep [Internet]*. 2020;21:e924455.

How to cite this article: Ali EA, Nashwan AJ, Yassin MA. Essential thrombocythemia with (type2) calreticulin presented as stuttering priapism case report and review of literature. *Clin Case Rep*. 2021;9:399–404. <https://doi.org/10.1002/ccr3.3541>