

Successful treatment of plasma cell vulvitis: A case series



Courtney Ann Prestwood, BS,^a Robin Granberry, BA,^a Audrey Rutherford, MD,^b and
Melissa M. Mauskar, MD^{b,c}
Dallas, Texas

Key words: estradiol cream; hydrocortisone suppositories; plasma cell vulvitis; skin; topical estrogen; topical hydrocortisone; vaginal drug absorption; vulva; vulvar dermatosis.

INTRODUCTION

Plasma cell vulvitis (PCV) is a rare, idiopathic inflammatory dermatosis of the vulva and rarely the oral mucosa and glans penis. PCV most commonly occurs in the fifth to eighth decades of life.^{1,2} Clinically, it presents as chronic red-brown or orange well-demarcated macules or patches that are 1-3 cm in diameter accompanied by erosions and cayenne pepper-colored spots.^{1,2} PCV ranges from being asymptomatic to presenting with burning pain, dyspareunia, and pruritus.²

While the etiology of PCV remains unclear, there are several potential causes, including hormonal, viral, irritant, and potentially autoimmune factors.^{1,2} Histologically, the infiltrate of PCV is composed primarily of polyclonal plasma cells, but lozenge- or diamond-shaped keratinocytes, erythrocyte extravasation, and hemosiderin deposition may also be observed. The plasma cell infiltrate observed on tissue biopsy is sufficient for a diagnosis of PCV, when plasma cells compose $\geq 50\%$ of the sample.²

There is no gold standard of treatment for PCV, and this condition is often refractory to treatment. Current treatment options include strong topical corticosteroids, topical calcineurin inhibitors, topical immunomodulators, surgical excision, liquid nitrogen cryotherapy, carbon dioxide laser ablation, and the synthetic retinoid etretinate.¹⁻³ However, these treatments do not provide a consistently effective treatment response across patient trials.

Abbreviation used:

PCV: plasma cell vulvitis

This cases series highlights 3 patients with successful treatment of PCV with 100 mg of hydrocortisone suppositories alternating with 1 g estradiol 0.01% vaginal cream every night for 4-8 weeks.

CASE SERIES

Case 1

A 57-year-old woman presented with complaints of constant pain, inflammation, irritation, and pruritus of her vulva and vagina accompanied by redness, dyspareunia, and dysuria for the past 3 years. She had previously tried clobetasol cream and estrogen topical cream without success. On physical examination, she presented with orange-brown lesions of her left labia minora, introitus, and periurethra. Histologically, tissue from the left vaginal introitus showed a slightly irregular epidermis, with change centered around the dermoepidermal surface with vacuolar changes of basal cells, band-like infiltration of leukocytes in the papillary dermis, and dyskeratosis. The inflammatory infiltrate contained numerous plasma cells, consistent with PCV.

The patient began a regimen of betamethasone dipropionate 0.05% topical ointment on her vulva once daily and then transitioned to a regimen of

From the University of Texas Southwestern Medical Center^a; Department of Dermatology^b and the Department of Obstetrics and Gynecology^c, University of Texas Southwestern Medical Center.

Authors Prestwood and Granberry contributed equally to this article.

Funding sources: None.

IRB approval status: Not applicable.

Correspondence to: Melissa M. Mauskar, MD, UT Southwestern Medical Center Dermatology, 5353 Harry Hines Blvd, Dallas, TX 75390. E-mail: melissa.mauskar@utsouthwestern.edu.

JAAD Case Reports 2022;19:37-40.
2352-5126

© 2021 by the American Academy of Dermatology, Inc. Published by Elsevier, Inc. This is an open access article under the CC BY-NC-ND license (<http://creativecommons.org/licenses/by-nc-nd/4.0/>).

<https://doi.org/10.1016/j.jidcr.2021.10.023>

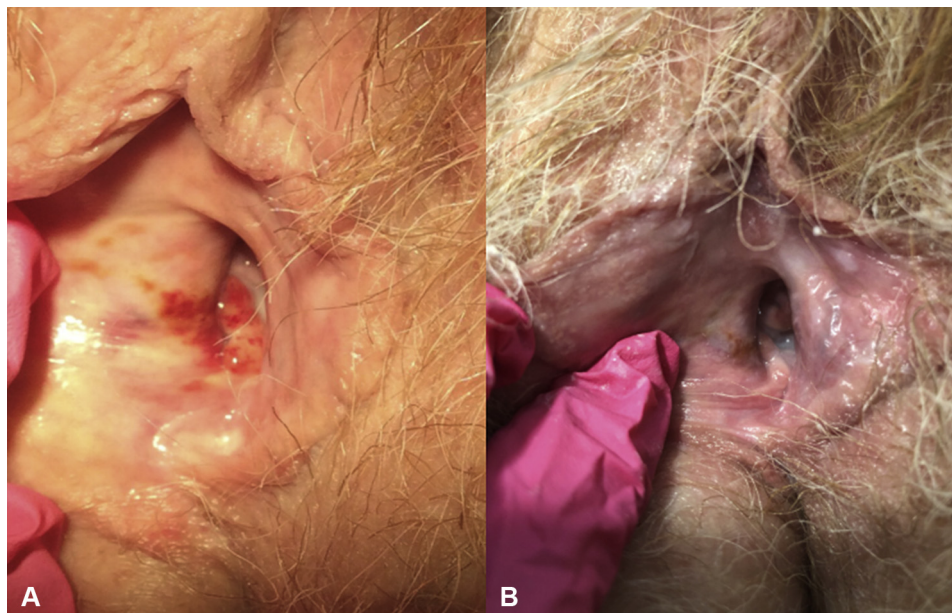


Fig 1. Plasma cell vulvitis. Case 2. **A**, A 59-year-old woman with confluent, painful, red-orange, glistening papules coalescing into plaques on the right introitus. **B**, After 10 weeks of treatment with 1 g topical estradiol 0.01% vaginal cream 3 times a week, alternating with hydrocortisone 100 mg suppository with resolution of symptoms and lesions.

alternating days of estradiol 10 mcg vaginal tablets and hydrocortisone 100 mg suppositories. These treatments resulted in partial symptomatic and clinical improvement. The patient then began 1 g estradiol 0.01% vaginal cream and 100 mg hydrocortisone suppositories on alternating days, and she experienced complete symptomatic and clinical improvement in 3 weeks. She continues to have symptomatic and clinical relief after 5 months of treatment with no erosions on exam.

Case 2

A 59-year-old woman presented for long-standing vulvar burning pain, dysuria, and dyspareunia. She previously tried to manage her symptoms with oral estrogen, low- and high-dose topical steroids, and other bland emollients with only slight relief. On physical examination, she presented with scattered orange-red erosions with a size of 1-4 mm on her introitus (Fig 1, A) and a periurethral lesion. A biopsy of her left introitus and left labia majus showed a dense lichenoid inflammatory infiltrate composed of plasma cells, eosinophils, and lymphocytes, suggesting a diagnosis of PCV.

Initially, treatments of betamethasone dipropionate 0.05% topical ointment twice a day, intralesional triamcinolone 10 mg/cc injections, 1 g topical estradiol 0.01% vaginal cream, and doxycycline 100 mg twice a day were all attempted with some symptomatic but no significant clinical improvements. Then,

she initiated 100 mg of hydrocortisone suppositories 3 times a week in addition to 1 g topical estradiol 0.01% vaginal cream twice a week. Ten weeks later, she reported complete symptomatic relief, and her physical exam showed marked improvement with faint light brown patches on her introitus (Fig 1, B) and a light brown periurethral lesion.

At that time, she began to taper her treatment, first by changing to hydrocortisone 100 mg suppositories twice weekly and estrogen cream 3 times weekly, then decreasing after 1 month to hydrocortisone 100 mg suppositories once weekly and estrogen 3 times weekly. As her condition continued to improve, with no symptoms and only a slight, 1-mm, brown urethral lesion on physical examination 7 months following the initiation of hydrocortisone and estrogen, she continued to taper by removing the use of hydrocortisone and prescribing only topical estrogen 3 times weekly.

Case 3

A 47-year-old woman presenting with a past medical history of lichen sclerosus and generalized morphea began experiencing vulvar pruritus and irritation with increased urinary frequency and urgency. She also reported a vaginal, painful, pulsating, and rough lesion. She used over-the-counter bland emollients and clobetasol twice weekly to manage her lichen sclerosus. On physical examination, she presented with a red-brown, tender patch

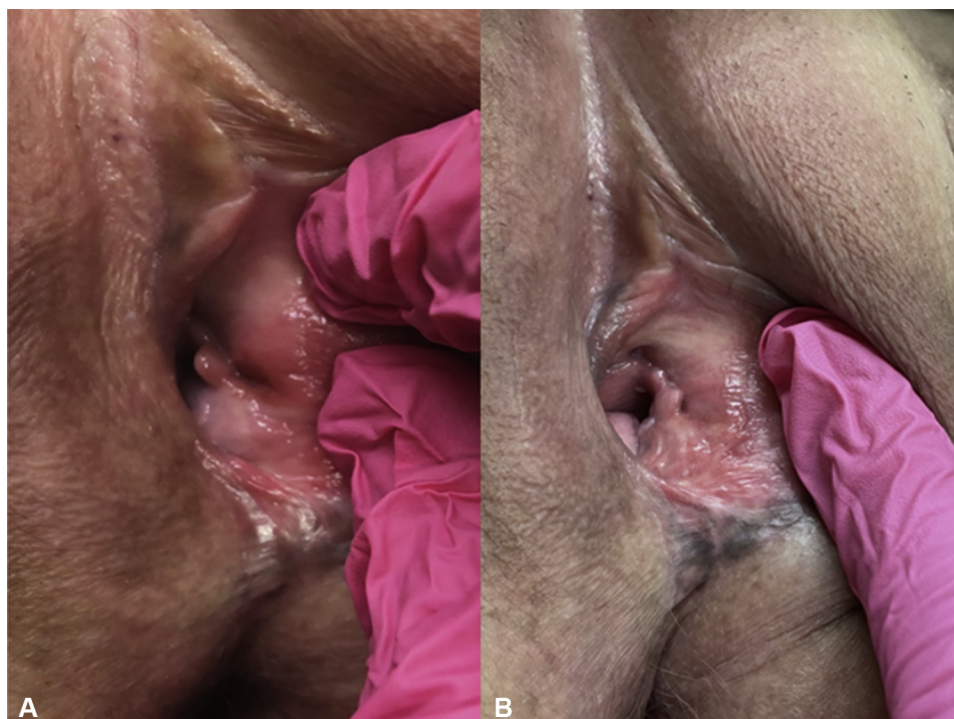

Fig 2. Plasma cell vulvitis. Case 3. **A**, A 47-year-old woman presented with increased erythema and rawness, with a red-brown, glistening, atrophic erosion on her left introitus. **B**, After 6 weeks of treatment with 1 g topical estradiol 0.01% vaginal cream 3 times a week, alternating with hydrocortisone 100 mg suppository with complete resolution.

on the left vestibule, agglutination of the labia minora, and a narrow introitus (Fig 2, A). PCV was initially suspected; however, the patient had a previous biopsy of the oral mucosa showing oral pemphigus, and she was given a diagnosis of pemphigus vulgaris of the vaginal mucosa. She began using clobetasol 0.05% topical gel to her vulva twice daily.

The patient returned to clinic 3 years later with worsening of the red isolated lesion on her left vaginal wall and increased erythema and bleeding. A biopsy of her left introitus was obtained. The biopsy showed dense infiltrates of lymphocytes and plasma cells and polytypia of plasma cells on *in situ* hybridization studies for κ and λ light chains. The biopsy results confirmed PCV as the diagnosis. The patient was treated with hydrocortisone 100 mg suppositories alternating with estradiol 10 mcg vaginal tablets every other day for 4 weeks. Four weeks later, she reported no improvement. Her treatment was modified to 1 g estradiol 0.01% vaginal cream 3 times a week alternating with hydrocortisone 100 mg suppositories. Six weeks after beginning the estradiol cream, she presented with resolution of the red erosive lesion (Fig 2, B). She began to taper her treatment, switching to 1 g topical estradiol 0.01%

vaginal cream and hydrocortisone 100 mg suppositories twice a week for 1 month, then reducing the hydrocortisone 100 mg suppositories to once weekly. This patient continues to have resolution of her symptoms and no PCV lesions on exam.

DISCUSSION

Here we describe 3 patients with plasma cell vulvitis who had a significant clinical response with treatment of hydrocortisone 100 mg suppositories nightly alternating with 1 g estradiol 0.01% vaginal cream for 4-8 weeks. There is currently no standard of care treatment for PCV. Limited information is available regarding duration of therapy, treatment time to resolution, and treatment efficacy.² Our treatment regimen was well-tolerated and provided both clinical and symptomatic relief. Local estrogen therapy with estradiol vaginal tablets has a low safety risk profile, and studies have not shown increased risk of breast cancer, endometrial cancer, or cardiovascular events.^{4,5} Estradiol 0.01% vaginal cream is also well-tolerated; however, more systemic absorption occurs with the cream compared to low-dose vaginal tablets. If patients are undergoing treatment for breast cancer or have a history of breast cancer,

dermatologists should discuss this treatment with their patient's oncologist.

One barrier to treating PCV is our poor understanding of vaginal drug absorption, which depends on membrane penetration and the solubility of the drug in the vaginal lumen. Vaginal drug absorption is affected by epithelium thickness, viscosity of vaginal mucus, and the volume and pH of vaginal fluid, which differs in each patient. Vaginal fluid contains a large amount of water, so any drug intended for vaginal delivery requires a certain degree of solubility in water. Also, low-molecular weight lipophilic drugs such as progesterone and estrone are more likely to be vaginally absorbed than large-molecular weight lipophilic or hydrophilic drugs, such as testosterone and hydrocortisone.⁶ Our preparation of hydrocortisone 100 mg in suppository form increases the amount of time the drug is in contact with the vaginal epithelium. This can help improve the poor absorbance of hydrocortisone.

All patients experienced a delay to diagnosis mirroring previous findings of a five-year average delay of diagnosis.⁷ Prior to beginning this combination therapy, all patients were prescribed 4 or more treatment regimens with varying degrees of results. The continuation of symptoms with multiple treatments led to patient frustration and feelings of hopelessness with their disease. Hydrocortisone 100 mg suppositories alternating with 1 g estradiol

0.01% vaginal cream provided significant clinical and symptomatic relief for patients suffering from this rare condition.

Conflicts of interest

None disclosed.

REFERENCES

1. Bharatia PR, Pradhan AM, Zavar VP. Plasma cell vulvitis. *Indian J Sex Transm Dis AIDS*. 2015;36(2):185-187. <https://doi.org/10.4103/0253-7184.167172>
2. Sattler S, Elsensohn AN, Mauskar MM, Kraus CN. Plasma cell vulvitis: a systematic review. *Int J Womens Dermatol*. 2021. <https://doi.org/10.1016/j.ijwd.2021.04.005>
3. Robinson JB, Im DD, Simmons-O'Brien E, Rosenshein NB. Etretinate: Therapy for plasma cell vulvitis. *Obstet Gynecol*. 1998;92(4 Pt 2):706. [https://doi.org/10.1016/S0029-7844\(98\)00238-5](https://doi.org/10.1016/S0029-7844(98)00238-5)
4. Crandall CJ, Hovey KM, Andrews CA, et al. Breast cancer, endometrial cancer, and cardiovascular events in participants who used vaginal estrogen in the Women's Health Initiative Observational Study. *Menopause*. 2018;25(1):11-20. <https://doi.org/10.1097/GME.0000000000000956>
5. Escobar C, Rosenblum N. Vaginal estrogen - What a urologist should know. *Urology*. 2021;151:37-43. <https://doi.org/10.1016/j.urology.2020.05.034>
6. Hussain A, Ahsan F. The vagina as a route for systemic drug delivery. *J Control Release*. 2005;103(2):301-313. <https://doi.org/10.1016/j.jconrel.2004.11.034>
7. Virgili A, Borghi A, Minghetti S, Corazza M. Comparative study on topical immunomodulatory and anti-inflammatory treatments for plasma cell vulvitis: long-term efficacy and safety. *J Eur Acad Dermatol Venereol*. 2015;29(3):507-514. <https://doi.org/10.1111/jdv.12604>