

Review Article

Current clinical applications of cardiovascular magnetic resonance imaging

L Scholtz, A Sarkin, Z Lockhat

Abstract

Cardiovascular magnetic resonance (CMR) imaging is unsurpassed in the evaluation of myocardial anatomy, function and mass. Myocardial perfusion pre- and post-stress, as well as late enhancement is increasingly used in the work-up for ischaemic heart disease, especially in establishing the presence of myocardial viability. Late enhancement patterns can contribute substantially to the diagnosis of myocarditis and various cardiomyopathies as well as infiltrative diseases and tumours. With their high incidence of cardiovascular disease, patients on the African continent could potentially benefit enormously from the proper utilisation of this exciting, continually evolving and versatile technique, via thorough didactic and clinical training as well as interdisciplinary co-operation.

Keywords: cardiovascular, cardiomyopathy, imaging, Africa, non-invasive

Submitted 9/10/13, accepted 25/4/14

Cardiovasc J Afr 2014; 25: 185–190

www.cvja.co.za

DOI: 10.5830/CVJA-2014-021

Owing to initial obstacles, mainly related to cardiac motion and ECG triggering, cardiovascular magnetic resonance (CMR) established itself within the cardiac imaging armamentarium long after its first diagnostic application in other disciplines. Faster and more effective sequences were subsequently developed to 'freeze' heart motion. Vector ECG and other solutions have also minimised the initial problems during ECG triggering that were due to the magneto-hydrodynamic effect of pulsatile blood in the aorta.

The quality of CMR imaging has consequently improved dramatically since the first MR images of the human heart were described more than 20 years ago, and it is still advancing apace. CMR now represents one of the most versatile, non-invasive imaging modalities available, offering high spatial resolution and image contrast along with tissue characterisation and haemodynamic assessment, without applying ionising radiation, and with complete multiplanar coverage of the heart.

Good communication between the referring physician and the CMR specialist is paramount to streamline the type and order of sequences required for each particular scenario. Although new sequences are constantly being developed, the basic principles of CMR remain unaltered, as follows.

Basic principles of CMR

Scout imaging

Each examination starts with a series of scout views performed on each patient to establish the short- and long-axis views of the heart. These act as localisers in planning the rest of the study. The pulse sequences used for scouting are based on steady-state free-precession (SSFP). Typically, 27 scout images are acquired to define the thoracic contents, including nine parallel images in each of the axial, coronal and sagittal planes.

Anatomical and morphological imaging

To assess anatomy and morphology, static images are required. Black-blood imaging is usually preferred because it allows clear distinguishing of the inner portion of the vessel or myocardium from blood. Half-Fourier single-shot fast-spin echo (HASTE) is a special variant of the fast-spin echo sequences, and ideal for delineation of anatomy. Anatomical and morphological information is particularly important in the diagnosis of congenital abnormalities and cardiac tumours.

Functional imaging

Dynamic ciné CMR white blood imaging is used for global and regional left ventricular (LV) and right ventricular (RV) wall motion assessment as well as ventricular volume, ejection fraction and mass measurements. It is now widely regarded as the gold standard.¹ The SSFP sequence is fast and ideal for white blood ciné imaging owing to its high signal-to-noise ratio and excellent ability to visualise the endocardial border. Functional analysis is especially important in the work-up of ischaemic heart disease as well as the non-ischaemic cardiomyopathies.

Department of Radiology, Steve Biko Hospital, Pretoria, South Africa

Leonie Scholtz, MB ChB, MMed (Rad) (Diag), (Pret), leonie@scholtzrad.co.za

Z Lockhat, FFRAD (D) (SA)

Department of Cardiology, Steve Biko Hospital, Pretoria, South Africa

Andrew Sarkin, MB BCH, FCP (Wits)

Myocardial perfusion imaging

During perfusion scanning, a movie of the wash-in of gadolinium-based contrast through the myocardium is obtained (so called 'first-pass perfusion'). The gradient echo (GRE) pulse sequence is most commonly used nowadays to visualise perfusion of the myocardium at rest or during adenosine stress testing. Perfusion defects appear as dark regions surrounded by bright contrast-enhanced, normally perfused myocardium. CMR perfusion is playing an increasingly important diagnostic role in ischaemic heart disease.

Oedema imaging

Myocardial oedema is associated with prolonged magnetic resonance relaxation time on T2-weighted pulse sequences. Static dark blood images of the myocardium can be obtained, confirming the presence or absence of oedema, which manifests as bright areas among the normal darker myocardium.

Late gadolinium enhancement (LGE) CMR imaging

LGE images are acquired with an inversion recovery-prepared GRE or SSFP imaging pulse sequences, with images acquired 10–15 minutes following gadolinium (Gd) chelate contrast administration. Gd circulates in the extracellular space and is excluded by intact myocardial cell membranes. They accumulate in areas of abnormal myocardium, resulting in T1 shortening manifesting as higher signal intensity on T1-weighted images. Gd migrates through damaged myocytic membranes into the cells (for example, in the case of myocardial infarction) or accumulates in the enlarged interstitial space (in the case of scar tissue).

The goal of LGE imaging is to create images with high contrast between the hyper-enhanced, damaged, fibrotic or non-viable tissue and the normal myocardium. LGE patterns play an important role in viability assessment during acute or chronic myocardial infarction as well as in the setting of non-ischaemic cardiomyopathies and cardiac tumours.

Flow/velocity imaging

Velocity-encoded (VENC) CMR imaging of blood flow is usually performed to measure velocity in the arteries, veins and across valves or shunts. With VENC CMR, a cine series of greyscale images reflecting flow during the cardiac cycle is acquired. The grey level is proportional to the velocity of blood into or out of the measured plane. VENC CMR allows quantification of valvular stenosis or regurgitation and is used in the assessment of valvular pathology.

Role of CMR in cardiovascular pathology

CMR plays an increasingly important role in cardiovascular pathology, as follows.

Ischaemic heart disease

Myocardial infarction and T2-weighted imaging

In the event of an acute myocardial infarct, myocardial oedema can be seen on T2 sequences as early as 30 minutes after the onset of ischaemia.² T2-weighted CMR imaging can help to

differentiate between acute and chronic myocardial infarction.³ CMR is consequently also useful in patients with acute chest pain of unclear aetiology with suspected acute coronary syndrome (Fig. 1).^{4,5} More importantly, high signal intensity on T2-weighted CMR, in the absence of LGE in the same area, reflects reversible ischaemic injury.²

There is excellent correlation between the area at risk (AAR) measured by T2-weighted imaging and the angiographic APPROACH score, which is an anatomically and prognostically validated measure of the extent of myocardial jeopardy.^{6,7}

LGE imaging

LGE plays an important diagnostic and prognostic role in patients with ischaemic heart disease.⁸⁻¹⁰ In patients with chronic myocardial infarction scheduled for implantable cardioverter-defibrillator (ICD) implantation, transmural involvement as defined by LGE CMR identifies a subgroup with increased risk for life-threatening arrhythmias and cardiac death.¹¹

According to a recent study by Desjardins *et al.*,¹² ventricular tachycardia (VT) circuits are mainly located in the centre of the LGE CMR-defined infarcts. Total infarct size can be ascertained by LGE CMR and is a strong predictor of future events in patients with coronary artery disease.¹³

The absence of contrast enhancement during the first two minutes after contrast injection in the centre of an area of infarction that may persist on the LGE images points to microvascular obstruction, which is associated with a worse prognosis and outcome.¹⁴⁻¹⁶

Stress perfusion imaging

Adenosine perfusion CMR has a high diagnostic accuracy in detecting coronary artery stenosis in patients with suspected coronary artery disease (CAD).^{17,18} A combined perfusion and infarction CMR examination with a visual interpretation algorithm can accurately diagnose CAD in the clinical setting.¹⁹ In a recent large, multicentre, multivendor study, the sensitivity of perfusion CMR in detecting CAD was superior to single-photon emission computed tomography (SPECT), while its specificity was inferior to SPECT.²⁰

Adenosine perfusion CMR provides excellent risk stratification and intermediate-term prognostic value in patients

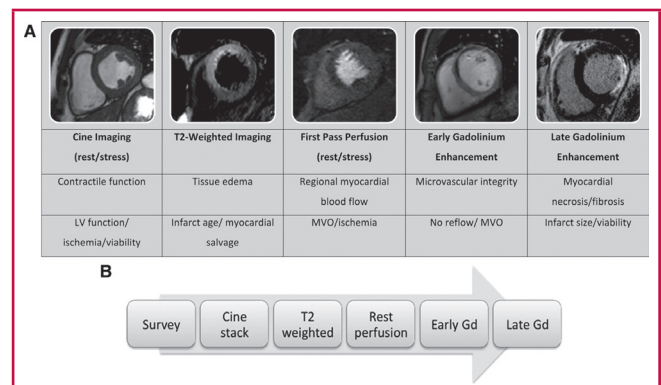


Fig. 1. CMR methods for the assessment of ACS. Short-axis views of different patients illustrate the different imaging techniques used (rows 1 and 2), their morphological correlates (row 3), and main clinical application (row 4).

with stable CAD.²¹ The presence of a reversible perfusion deficit is associated with a tripled risk for death or non-fatal myocardial infarction.²² The presence of abnormal CMR characteristics, including a reversible perfusion deficit, is a strong predictor of myocardial events during follow up.²³

Viability assessment

Several different methods of assessing myocardial viability are available in the diagnostic armamentarium. Viability tests have become a crucial tool in evaluating whether patients with congestive cardiac failure related to CAD might benefit from revascularisation therapy.²⁴⁻²⁶

Allman *et al.*²⁷ demonstrated a strong association between viable myocardium on non-invasive testing and increased survival after revascularisation, with a reduction in annual mortality of 79.6% compared with medical therapy. Three CMR methods exist for the evaluation of viability:

- resting LV wall end-diastolic wall thickness (> 5 mm regarded as viable)²⁸
- low-dose dobutamine (LDD) stress assessment of contractile reserve²⁹
- LGE of non-viable scar tissue.³⁰

According to a recent meta-analysis, LGE CMR provides the highest sensitivity and negative predictive value among the three methods. LDD CMR, however, has the highest specificity and PPV.³¹ If LGE CMR is compared with PET-FDG, rest-distribution thallium-201 SPECT and technetium-99m sestamibi-SPECT, and dobutamine stress echocardiography, it also performs better for predicting functional improvement after revascularisation of hibernating myocardium. LGE CMR also has a higher sensitivity, NPV and PPV than the other available techniques.^{25,32}

Cardiovascular MRI provides a unique tool to assess multiple interrelated clinical markers of viability in a single test.²⁹ The comprehensive assessment of ventricular mass, volume, function and perfusion as well as the ability to establish the presence and extent of non-viable tissue and AAR during a single CMR scan is unparalleled in the diagnostic work-flow of ischaemic heart disease.

Cardiomyopathies

CMR is fast becoming an invaluable tool in the assessment of cardiomyopathies. Regional and global myocardial function can be assessed, and its unique capability to visualise the apex and lateral wall supersedes all other imaging modalities. It is also unique in being able to perform tissue characterisation and to suppress fat, which, combined with LGE, assists in differentiating between various forms of cardiomyopathy (Fig. 2).

Hypertrophic cardiomyopathy (HCM) is the leading cause of sudden death in young people. The majority of HCM patients with sudden cardiac death have few or no clinical symptoms.³³ CMR is a powerful tool in the diagnosis and risk stratification of HCM; it is widely accepted as the gold standard for assessment of myocardial function as well as left ventricular mass, which has been shown to be a sensitive predictor of adverse outcomes in HCM.³⁴

According to a recent meta-analysis, the presence of LGE can predict a higher risk for sudden cardiac death (SCD) and heart failure in patients with HCM, thereby identifying patients who would benefit from ICD placement.³⁵ The presence of

oedema on T2-weighted CMR has also been observed in patients with HCM.³⁶ The presence of LGE has been shown to be a marker for adverse outcomes in several other non-ischaemic cardiomyopathies.^{37,38} LGE CMR can help to differentiate between ischaemic and non-ischaemic dilative cardiomyopathy.³⁹ According to the revised Task Force criteria for arrhythmogenic right ventricular dysplasia published in *Circulation* in 2010, MRI findings now fall under the major and minor criteria.⁴⁰

Albeit non-specific, CMR findings in ARVD include fatty infiltration of the RV wall, dilatation of the RV, regional or global RV dyskinesia and patchy areas of LGE in the RV wall mainly. CMR shows a characteristic pattern of global sub-endocardial late enhancement as well as abnormal myocardial and blood-pool kinetics in patients with cardiac amyloidosis.⁴¹ CMR is a useful diagnostic tool in cardiac involvement owing to sarcoidosis, which is responsible for the majority of deaths resulting from sarcoidosis.^{42,43}

Myocarditis

Endomyocardial biopsy (EMB) is considered to be the gold standard for the diagnosis of myocarditis. Recently, CMR has emerged as a promising non-invasive alternative. Three CMR techniques are applied in myocarditis:

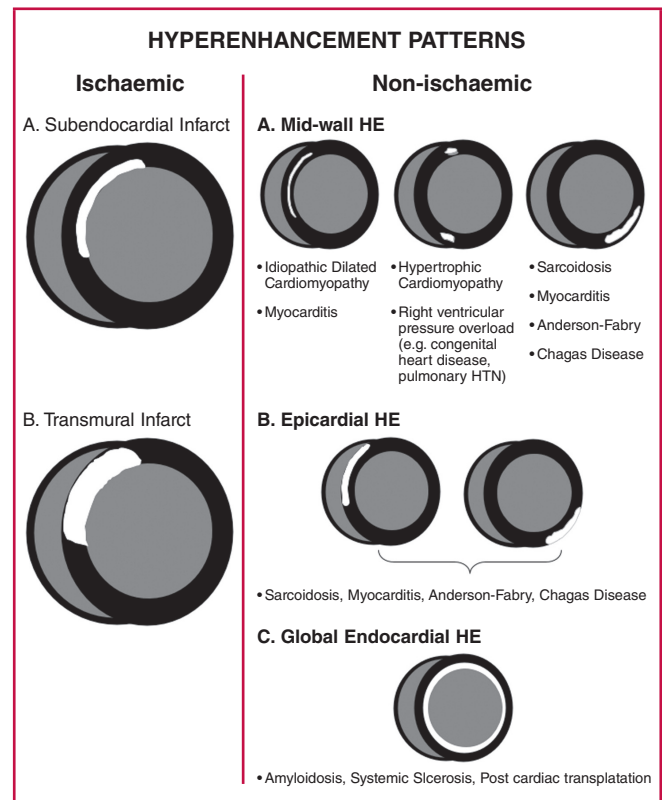


Fig. 2. Hyper-enhancement patterns that one may encounter in clinical practice. If hyper-enhancement is present, the endocardium should be involved in patients with ischaemic disease. Isolated mid-wall or epicardial hyper-enhancement strongly suggests a 'non-ischaemic' aetiology. (Reprinted with permission from Shah *et al. Clinical Magnetic Resonance Imaging*, 3rd edn. New York: Elsevier Press; 2005.)

- LGE sequences for detection of myocardial necrosis/fibrosis
- T2-weighted images for assessment of myocardial oedema⁴⁴
- T1-weighted sequences before and after contrast injection for the detection of myocardial hyperaemia.

The Lake Louise criteria for CMR diagnosis of myocarditis state that CMR findings are consistent with myocarditis if two out of three of the above criteria are found to be positive.⁴⁵ Although the CMR findings in myocarditis are not specific, they can act as a useful tool for the assessment of myocardial inflammation in patients with suspected acute myocarditis.⁴⁶

Pericardial disease

CMR is emerging as a most useful tool in the assessment of the pericardium. CMR, owing to its excellent resolution, can comprehensively assess pericardial anatomy. Through evaluation of regional myocardial deformation, ventricular interaction and venous return, CMR can also assess the physiological consequences of pericardial constriction. Owing to its combined anatomical and functional capabilities, CMR is a unique tool that enables one to distinguish between restrictive cardiomyopathy and constrictive pericarditis.

Congenital heart disease

Echocardiography is the primary diagnostic tool for the assessment of congenital heart disease but CMR can provide valuable information to confirm uncertain diagnoses. The large field of view allows assessment of the anatomical relationships between cardiac and vascular structures.

Valvular heart disease

Although echocardiography remains the initial tool for assessing cardiac valves, CMR can provide similar information in patients with sub-optimal or unsatisfactory echocardiographic examination.⁴⁷ Valve anatomy and motion as well as the presence of vegetations, thrombi or tumours can be visualised. Velocity measurements can be performed and pressure gradients calculated accurately with good reproducibility. The concomitant excellent determination of ventricular function and volume makes CMR a good alternative when echocardiography is sub-optimal.

Cardiac masses

The goal of CMR for assessing cardiac and paracardiac masses includes confirming or excluding a mass suspected by X-ray or echocardiography, assessing its location, mobility and relationship to surrounding tissues, and imaging the degree of vascularity; and distinguishing solid lesions from fluid and determining tissue characteristics as well as the specific nature of a mass. Owing to its excellent resolution, tissue characterisation and multiplanar approach, the extent of intra- or pericardial mass lesions can be clearly visualised. The additional administration of gadolinium contrast agents can assess vascularity and help to differentiate tumour from thrombus.

Coronary artery imaging with CMR

There has been continuous improvement in image quality

and examination time in coronary artery imaging with CMR. Hamden *et al.*⁴⁸ recently compared 3.0-T MRI with 64-slice CT angiography of the coronary arteries and concluded that, although both modalities could similarly identify significant coronary stenosis in patients with suspected or known CAD, CT angiography showed a favourable trend towards higher diagnostic performance. CMR is a most useful alternative modality to CT for the detection of anomalous coronary vessels, especially when ionised contrast administration is contra-indicated.⁴⁹

The future

Imaging speed is likely to continue to increase and larger and larger imaging volumes will become accessible at any given spatial and temporal resolution. The ability to accurately assess total scar burden via T1 mapping could provide a more objective method of non-invasively quantifying diffuse myocardial fibrosis, as recent studies have validated this method in various myocardial diseases.^{50,51}

Quantitative analysis of perfusion studies will become easier and more applicable in the clinical setting. Myocardial tagging, enabling the CMR specialist to quantify diastolic wall motion will probably move from the research environment into clinical practice. Although coronary artery imaging via CMR is still in its infancy, the imaging of carotid plaque composition looks promising, especially in evaluating the response to lipid-lowering drugs.⁵² Plaque characterisation with 3.0-T MRCA will probably play an important role in the diagnosis and risk stratification of CAD in the future.

Conclusion

CMR is a unique, versatile, rapidly evolving, non-invasive diagnostic tool offering complete coverage of the heart, and is independent of chest wall anatomy. Owing to its excellent resolution, interstudy reproducibility, user independence and absence of radiation exposure, it is bound to play an increasingly important role in cardiac imaging.

CMR is regarded as the gold standard for evaluating ventricular function, because of its reproducibility and validated assessment of ventricular size, function and mass of both the left and right ventricles. CMR plays an increasingly important role in the work-up of ischaemic heart disease as well as the non-ischaemic cardiomyopathies. Owing to the versatility and multitude of possible sequences, it is necessary to assemble lists of sequences into protocols that are specifically tailored to diagnostic questions or scenarios, in order to decrease scan time, and streamline and simplify the technique.

References

1. Pennell DJ, Sechtem UP, Higgins CB, *et al.* Clinical indications for cardiovascular magnetic resonance (CMR): Consensus Panel report. *Eur Heart J* 2004; **25**: 1940–1965.
2. Abdel-Aty H, Cocker M, Meek C, Tyberg JV, Friedrich MG. Edema as a very early marker for acute myocardial ischemia: a cardiovascular magnetic resonance study. *J Am Coll Cardiol* 2009; **53**:1194–1201.
3. Abdel-Aty H, Zagrosek A, Schulz-Menger J, *et al.* Delayed enhancement and T2-weighted cardiovascular magnetic resonance imaging differentiate acute from chronic myocardial infarction. *Circulation* 2004;

- 109: 2411–2416.
4. Cury RC, Shash K, Nagurney JT, *et al.* Cardiac magnetic resonance with T2-weighted imaging improves detection of patients with acute coronary syndrome in the emergency department. *Circulation* 2008; **118**: 837–844.
 5. Lockie T, Nagel E, Redwood S, Plein S. Use of cardiovascular magnetic resonance in acute coronary syndromes. *Circulation* 2009; **119**: 1671–1681.
 6. Fuernau G, Eitel I, Franke V, *et al.* Myocardium at risk in ST-segment elevation myocardial infarction. *J Am Coll Cardiol Img* 2011; **4**: 967–976.
 7. Graham MM, Faris PD, Ghali WA, *et al.* for the APPROACH investigators. Validation of three myocardial jeopardy scores in a population-based cardiac catheterization cohort. *Am Heart J* 2001; **142**: 254–261.
 8. Ishida M, Kato S, Sakuma H. Cardiac MRI in ischemic heart disease. *Circ J* 2009; **73**: 1577–1588.
 9. Kwon DH, Halley CM, Carrigan TP, *et al.* Extent of left ventricular scar predicts outcomes in ischemic cardiomyopathy patients with significantly reduced systolic function: a delayed hyperenhancement cardiac magnetic resonance study. *J Am Coll Cardiol Img* 2009; **2**: 34–44.
 10. Cheong BY, Muthupillai R, Wilson JM, *et al.* Prognostic significance of delayed-enhancement magnetic resonance imaging: survival of 857 patients with and without left ventricular dysfunction. *Circulation* 2009; **120**: 2069–2076.
 11. Boyé P, Abdel-Aty H, Zacharzowsky U, *et al.* Prediction of life-threatening arrhythmic events in patients with chronic myocardial infarction by contrast-enhanced CMR. *J Am Coll Cardiol Img* 2011; **4**: 871–879.
 12. Desjardins B, Crawford T, Good E, *et al.* Infarct architecture and characteristics on delayed enhanced magnetic resonance imaging and electro-anatomic mapping in patients with post-infarction ventricular arrhythmia. *Heart Rhythm* 2009; **6**: 644–651.
 13. Kelle S, Roes SD, Klein C, *et al.* Prognostic value of myocardial infarct size and contractile reserve using magnetic resonance imaging. *J Am Coll Cardiol* 2009; **54**: 1770–1777.
 14. Beek AM, Kühl HP, Bondarenko O, *et al.* Delayed contrast-enhanced magnetic resonance imaging for the prediction of regional functional improvement after acute myocardial infarction. *J Am Coll Cardiol* 2003; **42**: 895–901.
 15. Rezkalla SH, Kloner RA. No-reflow phenomenon. *Circulation* 2002; **105**: 656–662.
 16. Friedrich MG. Tissue characterization of acute myocardial infarction and myocarditis by cardiac magnetic resonance. *J Am Coll Cardiol Img* 2008; **1**: 652–662.
 17. Bernhardt P, Levenson B, Albrecht A, Engels T, Strohm O. Detection of cardiac small vessel disease by adenosine-stress magnetic resonance. *Int J Cardiol* 2007; **121**: 261–266.
 18. Nandalur KR, Dwamena BA, Choudhri AF, Nandalur MR, Carlos RC. Diagnostic performance of stress cardiac magnetic resonance imaging in the detection of coronary artery disease. *J Am Coll Cardiol* 2007; **50**: 1343–1353.
 19. Klem I, Heitner JF, Shah DJ, *et al.* Improved detection of coronary artery disease by stress perfusion cardiovascular magnetic resonance with the use of delayed enhancement infarction imaging. *J Am Coll Cardiol* 2006; **47**(8): 1630–1638.
 20. Schwitter J, Wacker CM, Wilke N, *et al.* MR-IMPACT II: Magnetic resonance imaging for myocardial perfusion assessment in coronary artery disease trial: perfusion-cardiac magnetic resonance vs. single-photon emission computed tomography for the detection of coronary artery disease: a comparative multicenter, multivendor trial. *Eur Heart J* 2013; **34**(10): 775–781.
 21. Buckert D, Dewes P, Walcher T, Rottbauer W, Bernhardt P. Intermediate-term prognostic value of reversible perfusion deficit diagnosis by adenosine CMR. *J Am Coll Cardiol Img* 2013; **6**: 56–63.
 22. Steel K, Broderick R, Gandla V, *et al.* Complementary prognostic values of stress myocardial perfusion and late gadolinium enhancement imaging in suspected coronary artery disease. *Circulation* 2009; **120**: 1390–1400.
 23. Bingham SE, Hachamovitch R. Incremental prognostic significance of combined cardiac magnetic resonance imaging, adenosine stress perfusion, delayed enhancement, and left ventricular function over pre-imaging information for the prediction of adverse events. *Circulation* 2011; **123**: 1509–1518.
 24. Chareonthaitawee P, Gersh BJ, Araoz PA, Gibbons RJ. Revascularization in severe left ventricular dysfunction: the role of viability testing. *J Am Coll Cardiol* 2005; **46**: 567–574.
 25. Schinkel AF, Bax JJ, Poldermans D, Elhendy A, Ferrari R, Rahimtoola SH. Hibernating myocardium: diagnosis and patient outcomes. *Curr Probl Cardiol* 2007; **32**: 375–410.
 26. Camici PG, Prasad SK, Rimoldi OE. Stunning, hibernation and assessment of myocardial viability. *Circulation* 2008; **117**: 103–114.
 27. Allman KC, Shaw LJ, Hachamovitch R, Udelson JE. Myocardial viability testing and impact of revascularization on prognosis in patients with coronary artery disease and left ventricular dysfunction: a meta-analysis. *J Am Coll Cardiol* 2002; **39**: 1151–1158.
 28. Klein C, Nekolla SG, Bengel FM, *et al.* Assessment of myocardial viability with contrast-enhanced magnetic resonance imaging: comparison with positron emission tomography. *Circulation* 2002; **105**: 162–167.
 29. Shan K, Constantine G, Sivananthan M, Flamm SD. Role of cardiac magnetic resonance imaging in the assessment of myocardial viability. *Circulation* 2004; **109**: 1328–1334.
 30. Mahrholdt H, Wagner A, Judd RM, Sechtem U, Kim RJ. Delayed enhancement cardiovascular magnetic resonance assessment of non-ischaemic cardiomyopathies. *Eur Heart J* 2005; **26**: 1461–1474.
 31. Romero J, Xue X, Gonzalez W, Garcia MJ. CMR imaging assessing viability in patients with chronic ventricular dysfunction due to coronary artery disease. *J Am Coll Cardiol Img* 2012; **5**: 494–508.
 32. Bax JJ, Poldermans D, Elhendy A, Boersma E, Rahimtoola SH. Sensitivity, specificity, and predictive accuracies of various noninvasive techniques for detecting hibernating myocardium. *Curr Probl Cardiol* 2001; **26**: 147–186.
 33. Maron BJ. Hypertrophic cardiomyopathy: a systemic review. *J Am Med Assoc* 2002; **287**: 1308–1320.
 34. Olivetto I, Maron MS, Autore C, *et al.* Assessment and significance of left ventricular mass by cardiovascular magnetic resonance in hypertrophic cardiomyopathy. *J Am Coll Cardiol* 2008; **52**: 559–566.
 35. Green JJ, Berger JS, Kramer CM, Salerno M. Prognostic value of late gadolinium enhancement in clinical outcomes for hypertrophic cardiomyopathy. *J Am Coll Cardiol* 2012; **5**: 370–377.
 36. Abdel-Aty H, Cocker M, Strohm O, Filipchuk N, Friedrich MG. Abnormalities in T2-weighted cardiovascular magnetic resonance images of hypertrophic cardiomyopathy: regional distribution and relation to late gadolinium enhancement and severity of hypertrophy. *J Magn Reson Img* 2008; **28**: 242–245.
 37. Assomull RG, Prasad SK, Lyne J, *et al.* Cardiovascular magnetic resonance, fibrosis and prognosis in dilated cardiomyopathy. *J Am Coll Cardiol* 2006; **48**: 1977–1985.
 38. Wu KC, Weiss RG, Thiemann DR, *et al.* Late gadolinium enhancement by cardiovascular magnetic resonance heralds an adverse prognosis in nonischemic cardiomyopathy. *J Am Coll Cardiol* 2008; **51**: 2414–2421.
 39. McCrohon JA, Moon JC, Prasad SK, *et al.* Differentiation of heart failure related to dilated cardiomyopathy and coronary artery disease using

- gadolinium-enhanced cardiovascular magnetic resonance. *Circulation* 2003; **108**: 54–59.
40. Marcus FI, McKenna WJ, Sherrill D, *et al.* Diagnosis of arrhythmogenic right ventricular cardiomyopathy/dysplasia: proposed modification of the Task Force criteria. *Circulation* 2010; **121**: 1533–1541.
 41. Maceira AM, Prasad SK, Hawkins PN, Roughton M, Pennell DJ. Cardiovascular magnetic resonance in cardiac amyloidosis. *Circulation* 2005; **111**: 186–193.
 42. Smedema JP, Snoep G, van Kroonenburgh MP, *et al.* Evaluation of the accuracy of gadolinium-enhanced cardiovascular magnetic resonance in the diagnosis of cardiac sarcoidosis. *J Am Coll Cardiol* 2005; **45**: 1683–1690.
 43. Patel MR, Cawley PJ, Heitner JF, *et al.* Detection of myocardial damage in patients with sarcoidosis. *Circulation* 2009; **120**: 1969–1977.
 44. Abdel-Aty H, Boyé P, Zagrosek A, *et al.* Diagnostic performance of cardiovascular magnetic resonance in patients with suspected acute myocarditis: comparison of different approaches. *J Am Coll Cardiol* 2005; **45**: 1815–1822.
 45. Friedrich MG, Sechtem U, Schulz-Menger J, *et al.* Cardiovascular magnetic resonance in myocarditis A JACC White Paper. *J Am Coll Cardiol* 2009; **53**: 1475–1487.
 46. Lurz P, Eitel I, Adam J, *et al.* Diagnostic performance of CMR imaging compared with EMB in patients with suspected myocarditis. *J Am Coll Cardiol Img* 2012; **5**: 513–524.
 47. Cawley PJ, Maki JH, Otto CM. Cardiovascular magnetic resonance imaging for valvular heart disease. *Circulation* 2009; **119**: 468–478.
 48. Hamdan A, Asbach P, Wellnhofer E, *et al.* A prospective study for comparison of MR and CT imaging for detection of coronary artery stenosis. *J Am Coll Cardiol Img* 2011; **4**(1): 50–61.
 49. Dirksen MS, Bax JJ, Blom NA, *et al.* Malignant right coronary artery anomaly detected by magnetic resonance coronary angiography. *Circulation* 2002; **106**: 1881–1882.
 50. Iles L, Pfluger H, Phrommintikul A, *et al.* Evaluation of diffuse myocardial fibrosis in heart failure with cardiac magnetic resonance contrast enhanced T1 mapping. *J Am Coll Cardiol* 2008; **52**: 1574–1580.
 51. Flett AS, Hayward MP, Ashworth MT, *et al.* Equilibrium contrast cardiovascular magnetic resonance for the measurement of diffuse myocardial fibrosis: preliminary validation in humans. *Circulation* 2010; **122**: 138–144.
 52. Zhao XQ, Dong L, Hatsukami T, *et al.* MR imaging of carotid plaque composition during lipid-lowering therapy. *J Am Coll Cardiol Img* 2011; **4**: 977–986.



THE AFRICAN ASSOCIATION OF THORACIC & CARDIOVASCULAR SURGEONS

PRESENTS ITS

2nd ANNUAL SCIENTIFIC CONFERENCE



THEME

CHALLENGES OF CARDIOVASCULAR AND THORACIC CARE IN AFRICA

**Vascular Surgery Workshop By
Vascular Society of Southern Africa (VASSA)**

Date 12th & 13st Sept, 2014

Venue Centro de Conferencia de Belas, Luanda

Time 8:00am-6:00pm

www.aactcv-angola.com