




Contents lists available at ScienceDirect

International Journal of Surgery Case Reports

journal homepage: www.casereports.com

Intestinal obstruction caused by the strangulation of a Treves' field pouch hernia from a Meckel's diverticulum – A case report

Jin Whan, Ching Ming Kwok*

Department of Surgery, Cheng Hsin General Hospital, Taipei, Taiwan

ARTICLE INFO

Article history:

Received 26 October 2020
 Received in revised form 4 November 2020
 Accepted 4 November 2020
 Available online 7 November 2020

Keywords:

Treves' field pouch hernia
 Mesenteric pouch hernia
 Meckel's diverticulum
 Intestinal obstruction
 Case report

ABSTRACT

INTRODUCTION: The etiology for intestinal obstruction is often difficult to determine especially in a young patient with a virgin abdomen. Differential diagnosis may include congenital abnormalities such as a more common Meckel's diverticulum but also a rarer mesenteric type internal hernia. Although the definite diagnosis is not as important in an acute setting and diagnosis is often made postoperatively, the preoperative differential diagnosis including the two should be considered for successful management. **PRESENTATION OF CASE:** We report a case of a 16-year-old young female who has a history of abdominal complaints but treated successfully conservatively. She eventually presented to us with suspicion of intestinal obstruction and image study confirmed an internal hernia. Operative findings showed a Meckel's diverticulum with tip adherent leading to the strangulation of a Treves' field pouch hernia. The encapsulated small bowel resulted in an intestinal obstruction of the terminal ileum.

DISCUSSION: Meckel's diverticulum is a common congenital abnormality but often asymptomatic. Treves' field of the mesentery is also a congenital abnormality but a much rarer finding often only impressed if herniation of the bowel is involved. However, both can lead to an abdominal emergency.

CONCLUSION: Intestinal obstruction is often an emergent situation and prompt surgery is usually required. The exact etiology may not be obvious preoperatively especially in a young patient with a virgin abdomen, but differential diagnosis like Meckel's diverticulum and Treves' field hernia should be important for successful management.

© 2020 Published by Elsevier Ltd on behalf of IJS Publishing Group Ltd. This is an open access article under the CC BY-NC-ND license (<http://creativecommons.org/licenses/by-nc-nd/4.0/>).

1. Introduction

Intestinal obstruction is often a surgical emergency and requires prompt reaction for successful management due to its high morbidity and mortality of possible necrosis to the bowel. Preoperative diagnosis is often clinically challenging especially in young patients with a virgin abdomen. Congenital abnormalities are a differential diagnosis but due to the rare incidence may often be confusing for surgeons not familiar with the abnormality. We describe a case of a young patient without any surgical history presenting with intestinal obstruction. Preoperative image suggests internal herniation and operative findings showed a Meckel's diverticulum with tip adherent leading to the strangulation of a Treves' field pouch hernia. The encapsulated small bowel resulted in an intestinal obstruction of the terminal ileum. Both Meckel's diverticulum and Treves' field are rare congenital abnormalities, but both can lead to a surgical emergency. Review of the literature for the two congenital abnormalities is done.

* Corresponding author at: Department of Surgery, Cheng Hsin General Hospital, No. 45, Cheng-Hsin Street, 112, Taipei, Taiwan.

E-mail addresses: whanejin@hotmail.com (J. Whan), peterkcm@ms2.hinet.net (C.M. Kwok).

<https://doi.org/10.1016/j.ijscr.2020.11.019>

2210-2612/© 2020 Published by Elsevier Ltd on behalf of IJS Publishing Group Ltd. This is an open access article under the CC BY-NC-ND license (<http://creativecommons.org/licenses/by-nc-nd/4.0/>).

2. Case report

A 16-year-old female was presented to our pediatric out-patient department due to abdominal fullness and distension for hours with mild periumbilical pain. She was just discharged from our hospital two days prior due to the same symptoms. At then, she was discharged under stable conditions after treated conservatively with non-per oral and intravenous fluids with the impression of acute enterogastritis. Tracing back her medical history, she had been admitted a few times to our hospital since childhood with similar symptoms and all treated successfully conservatively. She has no chronic illness nor history of abdominal surgery.

This time, two days after her last discharge, the similar symptoms occurred. There were no clinical signs of acute abdomen and vital signs were stable. Laboratory data showed leukocytosis with white blood count 16,300/uL, neutrophil 80%, and C-reactive protein 2.18 mg/dL. Standing abdominal plain film showed dilated loops of the small bowel centrally located over the mid abdomen. Abdominal sonography was arranged for further investigation and a segment of encapsulated small bowel at right lower quadrant was seen (*Image 1*). Abdominal CT confirmed an internal hernia with transition zone at right lower abdomen (*Image 2*). A presumptive diagnosis of internal hernia was made based on the radiological findings and a decision was taken to proceed to the operation room.

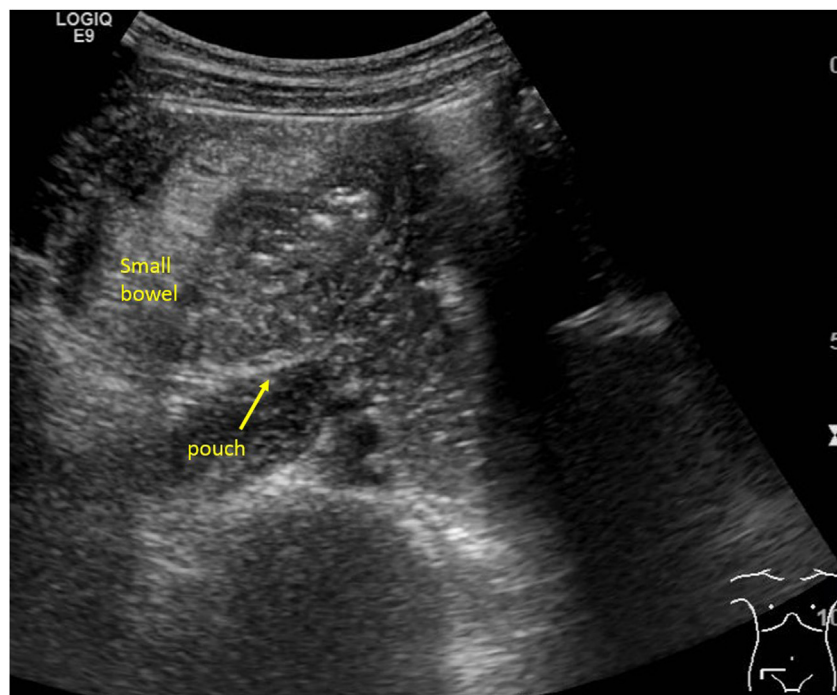


Image 1. Abdominal sonography.

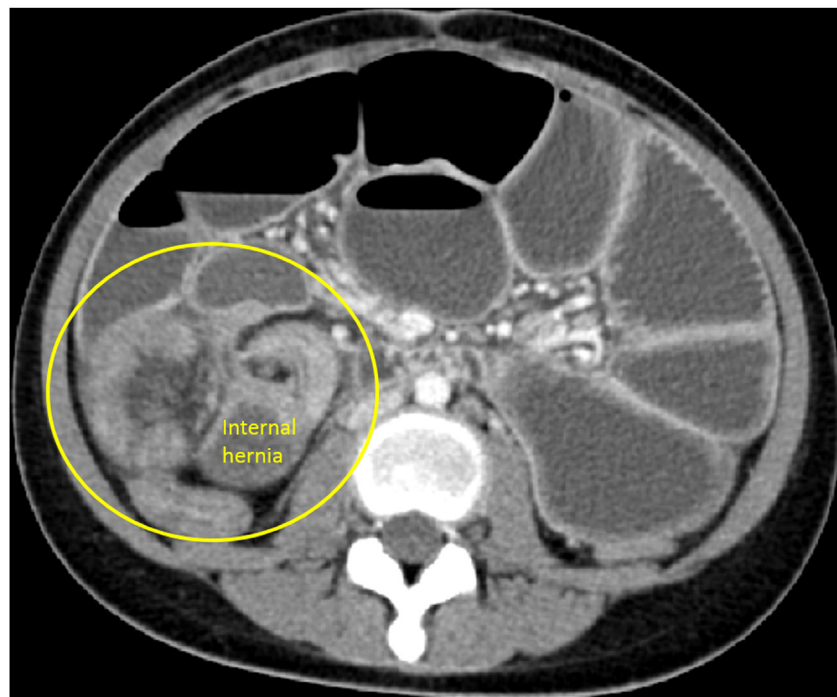


Image 2. Abdominal CT.

Emergent exploratory laparotomy was arranged. Operative findings included a 20 cm segment of distal ileum herniated and entrapped into the Treves' field pouch, and an adjacent 6 cm long Meckel's diverticulum with a fibrotic tip adherent around the opening of the pouch leading to complete intestinal obstruction ([Image 3](#)). Resection of the encapsulated bowel and Meckel's diverticulum was performed with end-to-end anastomosis. Post operation was smooth and oral diet was resumed gradually. Patient was discharged under stable conditions and out-patient department follow up showed good restoration of bowel functions. Pathology

confirmed a Meckel's diverticulum and an avascular area of the mesentery – the Treves' field pouch.

3. Discussion

3.1. Meckel's diverticulum

Meckel's diverticulum is a congenital malformation of the digestive tract and is named after Johann Friedrich Meckel who first

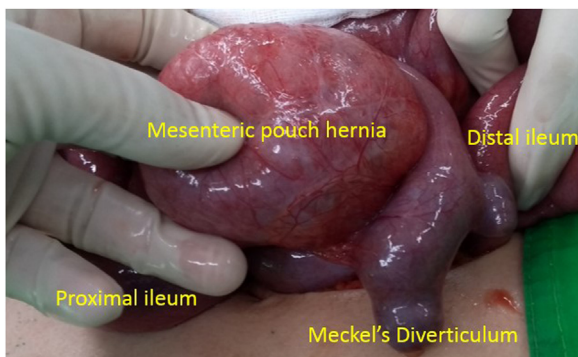


Image 3. Operative findings: a Treves' field pouch hernia with strangulation from a Meckel's diverticulum.

established its embryologic origin in 1809 [1]. It is a true diverticulum and is one of the most common digestive tract congenital abnormalities that occurs in about 2% of the population. In most cases, Meckel's diverticulum remains asymptomatic but 4% of patients can develop complications such as diverticulitis, gastrointestinal bleeding, perforation, or intestinal obstruction [2]. Zhang et al. suggested several reasons for the development of complications such as intestinal obstruction. One possibility is that repeated inflammation can lead to the formation of adhesion bands which can cause adhesive obstruction [2]. Symptomatic or complicated Meckel's diverticulum may therefore require surgical intervention as it is often the treatment of choice. However, preoperative diagnosis of Meckel's diverticulum is usually difficult due to the lack of specific symptoms and overlapping impressions with other acute abdominal emergencies. Image studies are usually used for investigation but sensitivity suggesting Meckel's diverticulum is generally low. Definite diagnosis is often made during surgery.

3.2. Treves' field pouch hernia

Mesenteric hernias are a rare type of internal hernias and can be divided into transmesenteric or pouch type. Transmesenteric types are hernias that pass through a mesenteric opening defect while pouch types are hernias that are entrapped in a pouch formed from the mesentery. Transmesenteric hernias are far more frequent while mesenteric pouch hernias are predominantly found in children [3]. In mesenteric pouch type hernias, the pouch is often found in the Treves' field. The Treves' field is a congenital abnormality at the mesentery close to the ileocecal region. In 1885, Treves first described this area of defect bounded by the ileocolic branch of the superior mesenteric artery and its anastomosis with the last ileal artery (Image 4). This area is remarkable because it is thin and contained no fat, blood vessels, or lymph nodes [4]. Martin et al. noted that one popular theory for the cause "relates to prenatal intestinal ischemia and subsequent thinning of the mesenteric. Other possible causes include intraperitoneal inflammation, trauma, partial development regression, and fenestration of the mesentery by the colon during the embryologic displacement into the umbilical cord" [5]. Some articles have also mentioned the occasional association with malrotation of the bowel with the development of Treves' field [6].

Treves' field permits entrapment of the bowel and patients with Treves' field pouch hernias can therefore develop symptoms of an intestinal obstruction. However, there are no specific symptoms for Treves' field pouch hernias. Vaos and Skondras mentioned that patients with Treves' field pouch hernias can have a "history of chronic, intermittent episodes of vague abdominal discomfort or cramps which subside spontaneously without previous abdominal surgery, trauma, infections. However, colicky and intense abdomi-

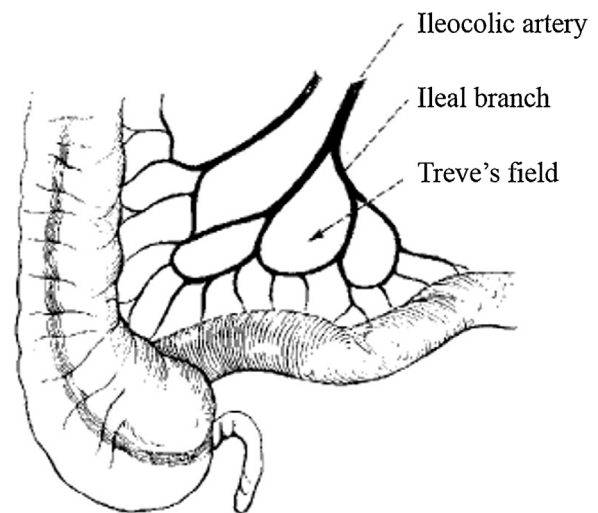


Image 4. Treves' field.

nal pain and persisted vomiting are usual initial symptoms of bowel obstruction when strangulation occurs" [6]. Despite the progress in technology, differential diagnosis from images can be confusing especially for those not familiar with this congenital abnormality. Because of the increased risk for bowel strangulation and the considerable associated morbidity and mortality, patients with suspected Treves' field pouch hernia can lead to a surgical emergency. Like Meckel's diverticulum, definite diagnosis is also often made upon surgery.

3.3. Our case

In our presented case, the patient had a few medical histories of abdominal discomforts during her childhood but treated successfully conservatively. The sudden relapse of her abdominal distension since her last admission two days prior suggested further investigation and abdominal sonography showed an encapsulated section of the bowel. Further imaging study from abdominal CT confirmed an internal herniation and emergent surgical intervention was carried out. Operative findings were intriguing and showed an intestinal obstruction caused by the strangulation of a Treves' field pouch hernia from a Meckel's diverticulum.

Both Meckel's diverticulum and Treves' field hernia are congenital abnormalities and each with a low incidence rate. Our case shows a rare finding resulting from these two congenital abnormalities leading to intestinal obstruction. Both Meckel's diverticulum and Treves' field pouch hernia remains a diagnostic challenge since they are both often clinically silent. They both have unspecific symptoms and image studies are sometimes only impressed as intestinal obstruction. The exact etiology is often made only upon surgery. For our case, we believe that the repeated abdominal discomforts from her childhood suggested congenital abnormality of her digestive tract. The tip adherent causing the strangulation of the Treves' field pouch hernia from the Meckel's diverticulum suggested an inflammatory history. The entrapped small bowel had intermittently herniated into the pouch followed by spontaneous reduction. The final episode was caused by the incarceration of the bowel leading to intestinal obstruction.

Internal hernias arising from Meckel's diverticulum are a rare form of complication and only a handful of case reports have been published [7]. Despite the low incidence and although the definite diagnosis is not as crucial in an acute abdominal setting, it is well worthy to be aware of these congenital abnormalities for optimal management. Our case was fortunate to capture the image of the

encapsulated bowel segment from abdominal sonography which is suggestive of a Treves' field pouch hernia. Abdominal CT findings of an internal hernia prompted us for emergent surgical intervention. It is important to note that image study still provides critical diagnostic information and rare congenital abnormalities should be considered for the differential diagnosis.

4. Conclusion

The etiology for intestinal obstruction remains a challenging task especially in a young patient with a virgin abdomen. Congenital abnormalities are a differential diagnosis but can remain difficult without the proper knowledge especially when clinical symptoms are nonspecific and image findings are confusing. Although exact etiology may be not as crucial in an acute abdomen setting, image studies can best impress a congenital abnormality and surgeons should be aware of the possible differential diagnosis such as Treves' field pouch hernias.

This work has been reported in line with the SCARE 2018 criteria [8].

Declaration of Competing Interest

The authors report no declarations of interest.

Funding

None.

Ethical approval

Consent has been obtained from the patient and family.

Consent

Written informed consent was obtained from the patient for publication of this case report and accompanying images. A copy of the written consent is available for review by the Editor-in-Chief of this journal on request.

Author's contribution

Jin Whan took care of the research, designing, and writing of the article.

Ching Ming Kwok was the leading surgeon of the case and has also contributed immensely in the research as well as in scripting the content.

Registration of research studies

N/A.

Guarantor

Jin Whan and Ching Ming Kwok have full responsibility for the work.

Provenance and peer review

Not commissioned, externally peer-reviewed.

References

- [1] Robbert-Jan Lindeman, Kjetil Søreide, The many faces of Meckel's diverticulum: update on management in incidental and symptomatic patients, *Curr. Gastroenterol. Rep.* 22 (2020) 3.
- [2] Yang Zhang, Yuchen Guo, Yuanlin Sun, Yuechao Xu, An internal hernia caused by Meckel's diverticulum: a case report, *BMC Gastroenterol.* 20 (2020) 69.
- [3] Nana Nakazawa, Tadaharu Okazaki, et al., Treves' field pouch hernia: our experience and literature review, *Pediatr. Surg. Int.* 25 (2009) 1013–1016.
- [4] William P. Harbin, Joel Andres, Samuel H. Kim, Spencer Borden IV, Internal hernia into Treves' field pouch – case report and review of the literature, *Radiology* 130 (January) (1979) 71–72.
- [5] Lucie C. Martin, Elmar M. Merkle, William M. Thompson, Review of internal hernias: radiographic and clinical findings, *AJR* 186 (2006) 703–717.
- [6] G. Vaos, C. Skondras, Treves' field congenital hernias in children: an unsuspected rare cause of acute small bowel obstruction, *Pediatr. Surg. Int.* 23 (2007) 337–342.
- [7] Xiau Wei Tay, Niruben Rajasagaram, Rare case of internal hernia sac with Meckel's diverticulum, *ANZ J. Surg.* 90 (April (4)) (2020) E69–E70.
- [8] R.A. Agha, M.R. Borrelli, R. Farwana, K. Koshy, A. Fowler, D.P. Orgill, For the SCARE Group, The SCARE 2018 statement: updating consensus Surgical Case RReport (SCARE) guidelines, *Int. J. Surg.* 60 (2018) 132–136.

Open Access

This article is published Open Access at [sciencedirect.com](https://www.sciencedirect.com). It is distributed under the [IJSCR Supplemental terms and conditions](#), which permits unrestricted non commercial use, distribution, and reproduction in any medium, provided the original authors and source are credited.