

Bipolar Fresh Osteochondral Allograft Transplantation and Joint Reconstruction for Patellar and Trochlear Cartilage Defects



Omid Jalali, B.S., Zachary Vredenburgh, M.D., John Prodromo, M.D., Neilen Benvegna, M.D., and George Frederick “Rick” Hatch III, M.D.

Abstract: Patellar instability is a debilitating condition, and trauma due to the dislocations may severely damage the articular cartilage of the patellofemoral joint. The lack of healing capacity of cartilage makes treatment of such lesions challenging. In young patients, preservation of native bone and cartilage is a priority, and therefore arthroplasty procedures should be avoided even in relatively larger lesions. Fresh osteochondral allografting has been described for these difficult and complex cases, with recent studies showing promising results. In this surgical technique, we describe the use of bipolar osteochondral allografts of the patella and trochlea and patellofemoral joint reconstruction for large bipolar full-thickness cartilage defects due to recurrent dislocation events.

Patellar instability is a debilitating condition. Approximately 36% of those who sustain an instability event will go on to have a recurrence of their instability,¹ and this number is greater in individuals with skeletal immaturity.² Trauma due to the dislocations often leads to symptomatic articular cartilage injuries and eventual patellofemoral osteoarthritis. Weber et al.³ recommended an algorithmic approach to treatment of this pathology, with consideration given to an individual patient’s injuries, limb alignment, osseous structure of the patella and trochlea, and integrity of static and dynamic soft-tissue constraints. Surgical treatment is recommended for patients with recurrent dislocation events to alleviate symptoms and prevent progression of the disease.

In particular, the limited healing capacity of cartilage makes the treatment of articular cartilage lesions

challenging.⁴ In young patients, preservation of native bone and cartilage is a priority, and therefore arthroplasty procedures should be avoided even in relatively larger lesions. Fresh osteochondral allografting often is used in these cases, with recent studies showing promising results.⁵ In this surgical technique, we describe the use of bipolar osteochondral allografts (OCAs) of the patella and trochlea and patellofemoral joint reconstruction (tibial tubercle osteotomy, medial patellofemoral ligament reconstruction, and lateral lengthening) for the treatment of large bipolar articular cartilage defects of the patellofemoral joint secondary to 16 years of recurrent lateral dislocations.

Preoperative Assessment

The patient was a 24-year-old female patient with a 16-year history of bilateral patellar instability. She presented for a chronically dislocated patella of her right knee. She had no history of previous right knee surgery. On presentation in the clinic, her patellofemoral joint was grossly dislocated, with the patella articulating on the lateral aspect of her lateral femoral condyle. Preoperative imaging studies demonstrated profound patellofemoral dysplasia of the right knee with a Dejour type D trochlea. Computed tomography scan demonstrated a tibial tubercle–trochlear groove (TT-TG) distance of 30 mm. Diagnostic arthroscopy was performed as a separate procedure for direct assessment of cartilage status before a definitive stabilization procedure. This demonstrated a complete loss of cartilage

From the Epstein Center Sports Medicine, Department of Orthopaedic Surgery, University of Southern California, Los Angeles, California, U.S.A.

The authors report the following potential conflict of interest or source of funding: G.F.H. reports personal fees from Arthrex, outside the submitted work. Full ICMJE author disclosure forms are available for this article online, as supplementary material.

Received May 27, 2019; accepted August 12, 2019.

Address correspondence to Omid Jalali, 765 Kendall Dr., Laguna Beach, CA 92651. E-mail: ojalali@usc.edu

© 2019 Published by Elsevier on behalf of the Arthroscopy Association of North America. This is an open access article under the CC BY-NC-ND license (<http://creativecommons.org/licenses/by-nc-nd/4.0/>).

2212-6287/19692

<https://doi.org/10.1016/j.eats.2019.08.003>

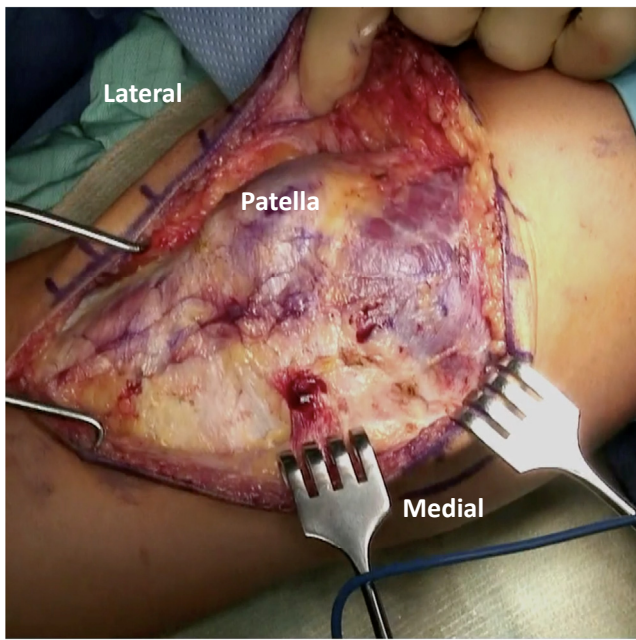


Fig 1. Intraoperative photograph of a right knee with a midline skin incision and development of full-thickness skin flaps bilaterally. Retractors are being used to visualize the patella and extensor mechanism.

with exposed and eroded subchondral bone involving greater than 3/4 of the undersurface of the patella, and significant-full thickness articular cartilage loss and subchondral erosion of the trochlea. The arthroscopy also confirmed her trochlear groove demonstrated severe dysplasia, Dejour type D with a cliff laterally, and a hypoplastic medial femoral condyle medially with diffuse cartilage loss.

Patient Positioning and Examination Under Anesthesia

The patient undergoes induction of general anesthesia with administration of intravenous antibiotics, is placed supine on the operating table, and has a well-padded tourniquet applied high on the thigh of the operative extremity. An examination with the patient under anesthesia is performed to document patellar mobility, both medially and laterally. The lower extremity is prepped and draped in the usual sterile fashion. A sterile bump is placed under the knee to maintain 20 to 30° of flexion.

Surgical Technique

Exposure and Arthrotomy

The leg is exsanguinated and tourniquet inflated. A midline skin incision is made from about 5 cm proximal to the superior pole of the patella extending down about 6 cm distal to the tibial tubercle (Fig 1). Full-thickness skin and subcutaneous flaps are developed to expose the patella and extensor

mechanism (Video 1). Hemostasis is obtained with electrocautery.

Next, a lateral parapatellar arthrotomy is performed along the lateral aspect of the patella, for later lateral lengthening upon closure. The incision is first made through layer 1 and then continues posteriorly approximately 15 to 20 mm between layers 1 and 2 (Fig 2). This proceeds distally to the prepatellar recess and will be left open until the end of the case.

Fulkerson Osteotomy, Part 1

The patellar tendon is retracted anteriorly and the pretibial recess is demarcated on either side to visualize the insertion of the patellar tendon on the tibial tubercle using a Kelly clamp. The periosteum is then elevated on each side of the tibial tubercle using electrocautery and a blunt elevator to retract the musculature of the anterior compartment laterally, exposing the proximal lateral tibia. Using the T3 AMZ System (Arthrex, Naples, FL; Fig 3A, A 45° cut osteotomy is performed using an oscillating saw, tapered distally (Fig 3B). The osteotomy is completed with an osteotome proximally within the pretibial recess (Fig 3C). The pedicle is reflected superiorly to expose the joint space with the fat pad carefully released and protected. The osteotomy will be secured later.

Trochlear OCA Transplantation

With the tibial tubercle osteotomy reflected superiorly, attention is focused on exposing the trochlea in preparation for OCA transplantation. The suprapatellar fat pad and condylar soft-tissue attachments are

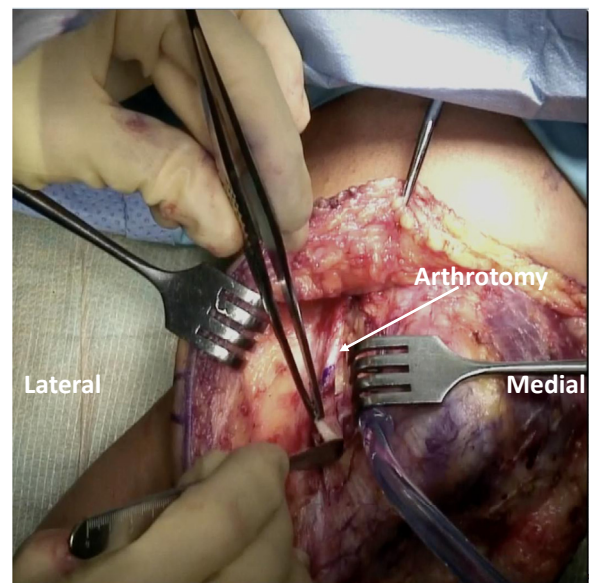


Fig 2. Intraoperative photograph of a right knee with a lateral parapatellar arthrotomy being performed to enter the knee joint. An incision is being made at the superolateral aspect of the patella and is continued distally to the pretibial recess.

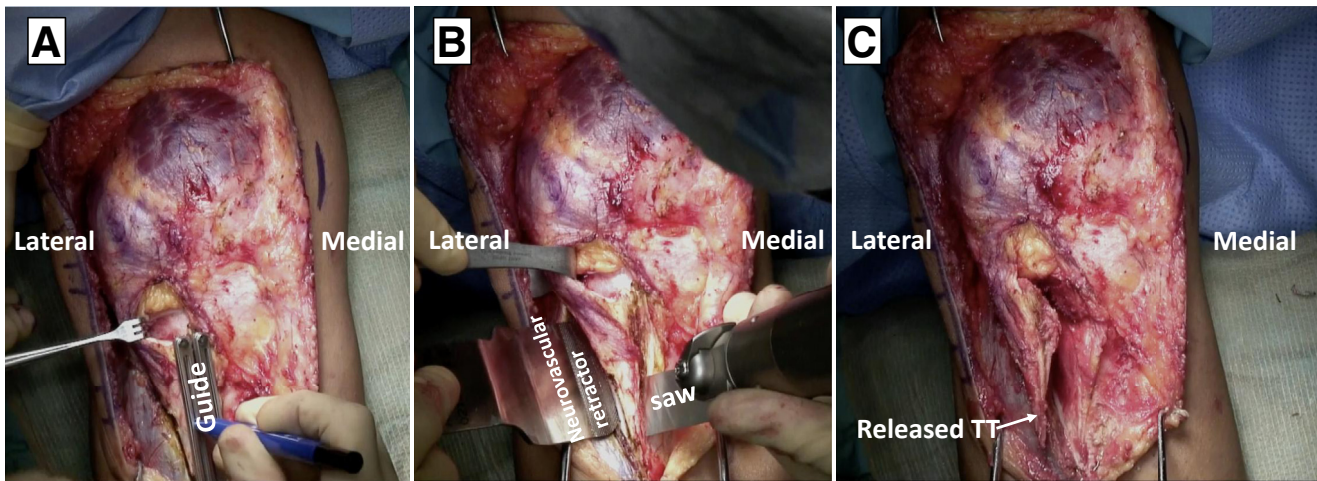


Fig 3. Intraoperative photographs of a right knee undergoing tibial tubercle osteotomy. An Arthrex AMZ Guide System (A) is being used to determine the medial and lateral sites for release of the tibial tubercle, followed by a 45° cut osteotomy being performed with an oscillating saw, tapered distally (B). The osteotomy is completed with an osteotome within the pretibial recess and should result in complete release of the tibial tubercle (C). (TT, tibial tubercle.)

reflected proximally to fully expose the proximal trochlea and condyles (Fig 4A). The trochlea is classified based on the Dejour classification. A type D trochlea and evidence of post-traumatic osteoarthritis were identified in this case (Fig 4B).

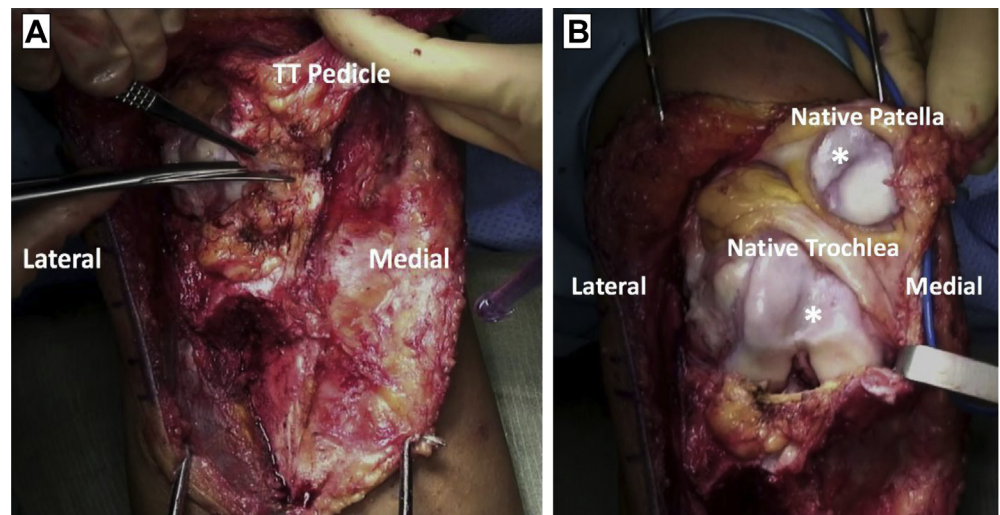
The defect is demarcated with a surgical pen (Fig 5A), identifying the proximal aspect by placing the femur parallel to the floor and table. The distal aspect is identified just proximal to the intercondylar notch of the distal femur. With an oscillating saw, a free-hand oblique cut is made on the native trochlea coming out just proximal to the trochlear groove (Fig 5B). A second, vertical cut is made from lateral to medial, cutting off just the anterior aspect of the distal end of the femur and trochlea. Multiple fluoroscopic views may be

needed to ensure the distal femur is not notched and the medial or lateral femoral condyles are not violated. Upon completion of the osteotomy, the wafer is removed in one solid piece (Fig 5C).

A fresh, OCA from the trochlear groove is then placed on the recipient trochlear surface and matched using oscillating saws and bone cutters (Fig 6, A and B). A 10-L pulsatile lavage is used to remove marrow elements.

The allograft is then secured with 4 K-wires: 2 lateral and 2 medial (Fig 7A). Direct visualization and fluoroscopic views are used to confirm normal-appearing contour of the trochlea and that there is no notching into the distal aspect of the femur. Then, 3.5-mm headless screws are placed on the lateral aspect of the trochlear groove on the non-articular surface (Fig 7B).

Fig 4. Intraoperative photographs of a right knee undergoing preparation for bipolar osteochondral allografting of the patellofemoral joint. With the tibial tubercle reflected superiorly, excision of the suprapatellar fat pad and soft tissue attachments is being performed (A) to reveal the native trochlear and patellar articular surfaces (B). *Arthritic lesions. (TT, tibial tubercle.)



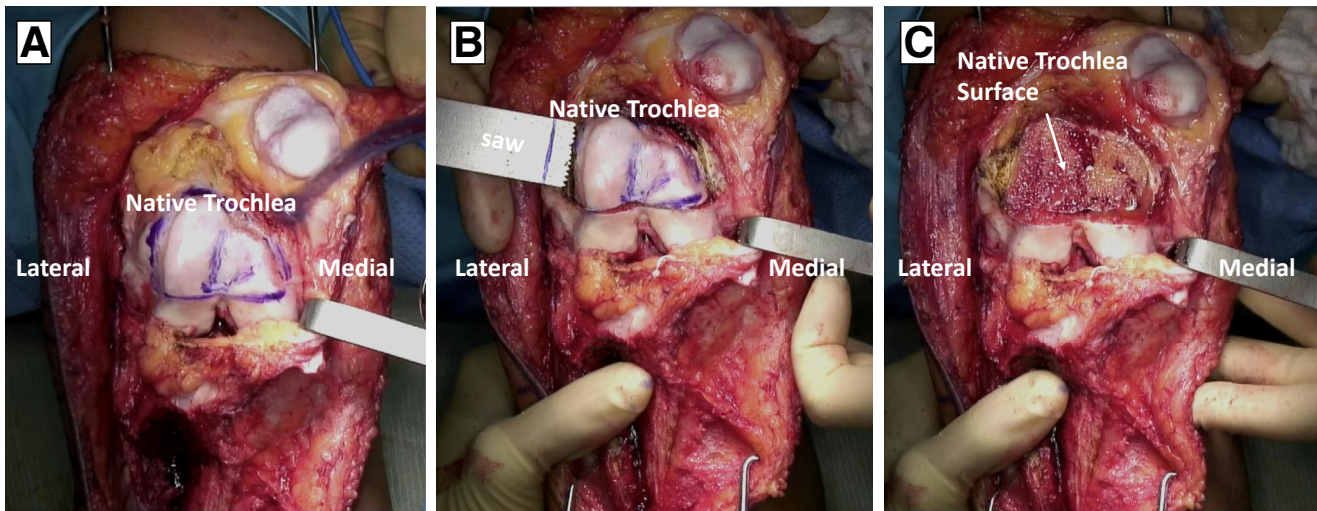


Fig 5. Intraoperative photographs of a right knee undergoing removal of the native trochlear surface. Surgical pen markings are used to delineate boundaries of the arthritic and dysplastic native trochlea in preparation for removal and osteochondral allograft transplantation (A). Using these lines as a guide, an oscillating saw is being used to remove the native trochlea in one solid piece (B), with reaming performed to the depth at which bleeding healthy subchondral bone is encountered (C).

Proper screw heights are confirmed with direct measurement and intraoperative lateral C-arm fluoroscopy. All screws are inserted below the articular surface.

Patellar OCA Transplantation

With the trochlear graft in place, attention can be turned to the patellar allografting. Using the Zimmer Arthroplasty System (Zimmer Biomet, Warsaw, Poland), the native and donor patella are sized using holders and a clamp (Fig 8).

The native patella is then cut (Fig 9A), ensuring there is at least 13 mm of native patella left in thickness and

a flat surface to fix the donor patella to (Fig 9B). The thickness of the residual patella is measured and subtracted from the precut thickness of the patella. The donor patella is then clamped and cut so that the composite patella will end up being within 1 mm of the original thickness of the native patella.

The allograft is placed in a basin and irrigated with 10 L of pulsatile lavage to remove marrow elements, matched to the native patella site, held in place with K-wires (2 medial, 2 lateral, 1 superior, 1 inferior) (Fig 10, A and B), and definitively fixed with 3.5-mm headless compression screws (Fig 10C), inserted from the

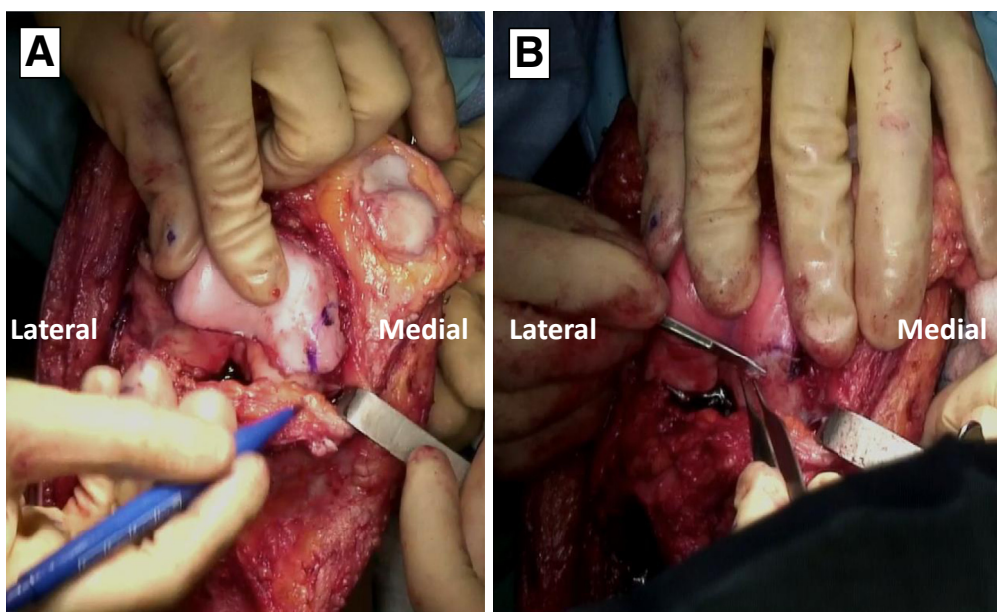


Fig 6. Intraoperative photograph of a right knee undergoing sizing of a trochlear osteochondral allograft. A surgical pen being used to mark areas of incongruence between the trochlear osteochondral graft and the appropriate donor trochlear shape and size (A). Using these markings, bone cutters are being used to make fine adjustments to ensure the graft re-approximates an appropriate trochlea given the individual patients anatomic considerations.

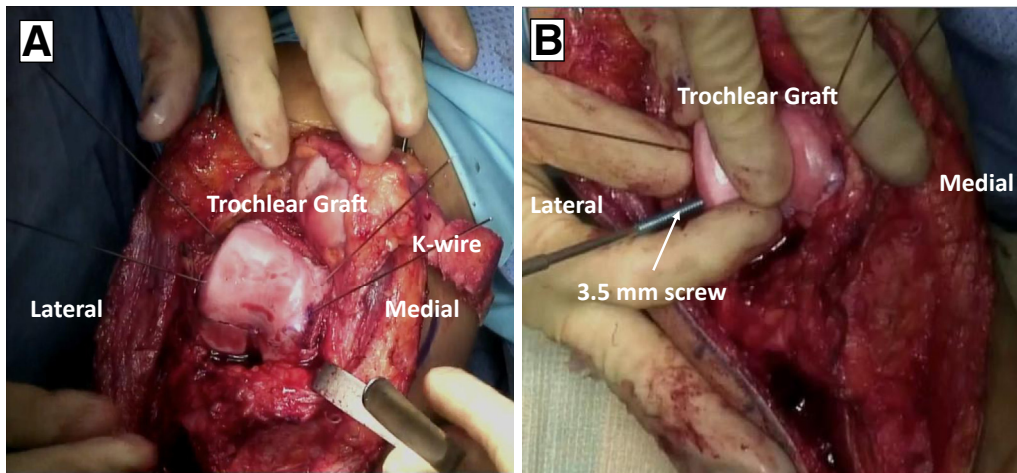


Fig 7. Intraoperative photographs of a right knee undergoing fixation of a trochlear osteochondral allograft. The trochlear allograft is secured to the donor site with 4 K-wires (A), and 3.5-mm headless screws are being placed over the K-wires (B), lateral to the trochlear groove on the nonarticular surface.

articular surface to maximize fixation in the allograft fragment.

Direct visualization and palpation confirm that the screws are sunk below the articular surface. Both allografts should now be fixed in place (Fig 11).

Before returning to the tibial tubercle, dissection should be carried down with a 15 blade to identify the equator of the medial aspect of the patella. Layer 2, containing the medial patellofemoral ligament (MPFL), should be identified and tagged with 0 Vicryl suture for later identification. An elevator is used to subperiosteally dissect on the medial aspect of the patella up to the proximal aspect of it. Two anchors (3.0 Bio-Composite SutureTak; Arthrex) are placed at the insertion of the MPFL on the patella.

Revisiting the Fulkerson Osteotomy, Part 2

Attention is now turned to securing the tibial tubercle osteotomy transfer. The quantity of medialization or distomedialization is determined based on preoperative computed tomography scan measurements. In this patient, preoperative TT-TG was 30 mm, so the tubercle was medialized 15 mm to achieve a normal TT-TG distance of 15 mm. If there is preoperative patella baja or alta, the Caton–Deschamps ratio is used to determine whether concomitant distalization is required at this time.⁶ The osteotomy is held tentatively in place with 2 K-wires and proper location of the tubercle is confirmed with anteroposterior and lateral fluoroscopy.

The tibial tubercle is then fixed with a combination of 2 large frag (4.5 mm) screws drilled in a lag fashion and 2 headless cannulated (3.0 mm) screws where the K-wires were placed (Fig 12). Anteroposterior and lateral fluoroscopy confirm appropriate screw placement and length.

MPFL Reconstruction

The origin of the MPFL is identified radiographically by previous landmarks described by Schöttle et al.⁷ A small incision between the medial epicondyle and the adductor tubercle is performed to directly confirm proper placement. The saddle region of the native medial patellofemoral ligament is identified between these 2 landmarks. A guide pin for an anchor (4.75-mm SwiveLock Anchor; Arthrex) is then inserted here.

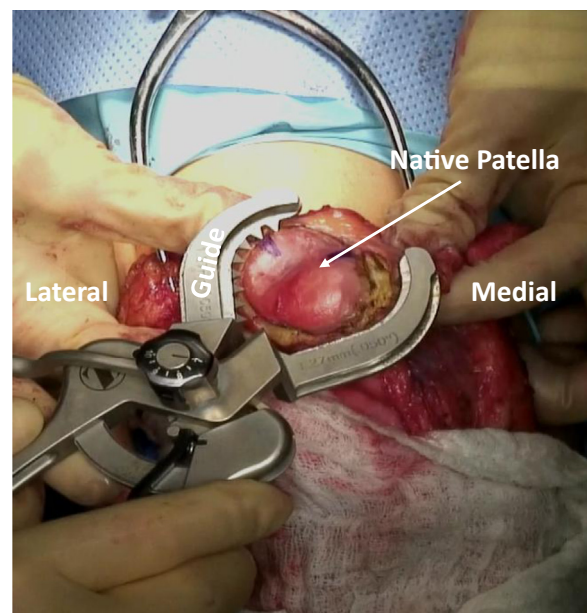


Fig 8. Intraoperative photograph of a right knee with the Zimmer Arthroplasty System being used to measure the size of the arthritic native patella in preparation for excision and placement of an osteochondral allograft.

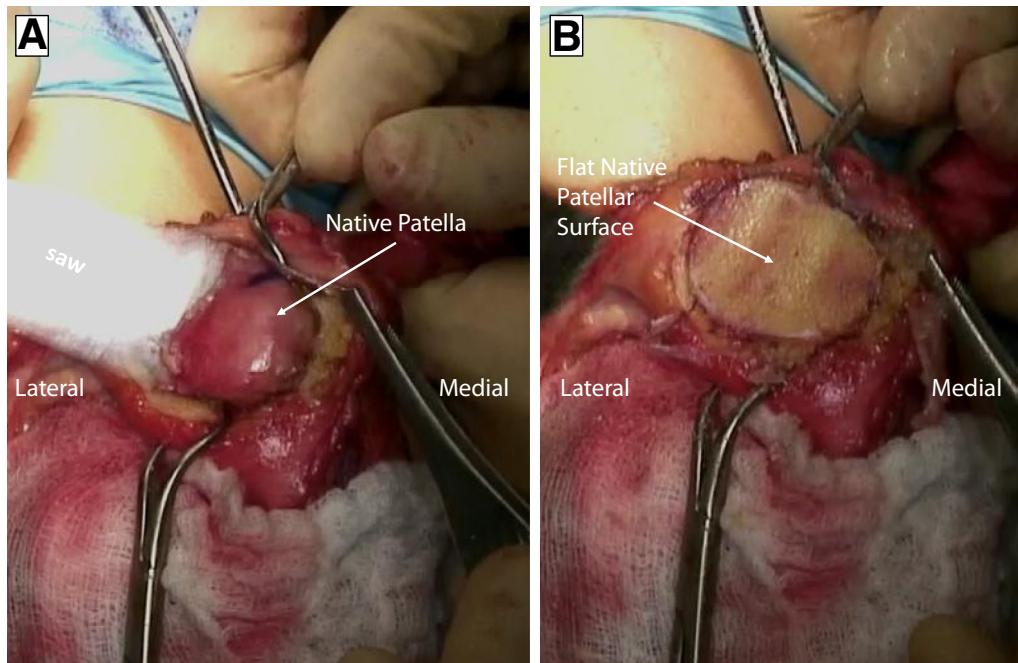


Fig 9. Intraoperative photograph of a right knee undergoing removal of an arthritic native patellar surface in preparation for osteochondral allograft transplantation. An oscillating saw is being used to remove the native patella from lateral to medial (A), with reaming performed to ensure a flat surface at the level of healthy, bleeding subchondral bone and a minimum of 13 mms of native patellar thickness (B).

Sutures are placed around this pin and held at the site of the SutureTak anchors on the medial aspect of the patella (Fig 13).

The knee is cycled through range of motion, with care taken to ensure that there is no evidence of graft tension with flexion. The semitendinosus allograft is then whip stitched in the middle of the tendon using #2 FiberWire (Arthrex). These sutures are used to secure the SwiveLock anchor at the site of the pin using

standard technique. The plane between layers 2 and 3 that was previously identified adjacent to the medial patella is developed and a hemostat is used to grab the 2 free ends of the semitendinosus graft and bring them up to the medial aspect of the patella, between layers 2 and 3, being careful not to twist the 2 ends (Fig 14).

What remains of the tissues of the medial retinaculum and medial patellofemoral ligament are then imbricated onto the graft using 0 Vicryl (Fig 15). More imbricating

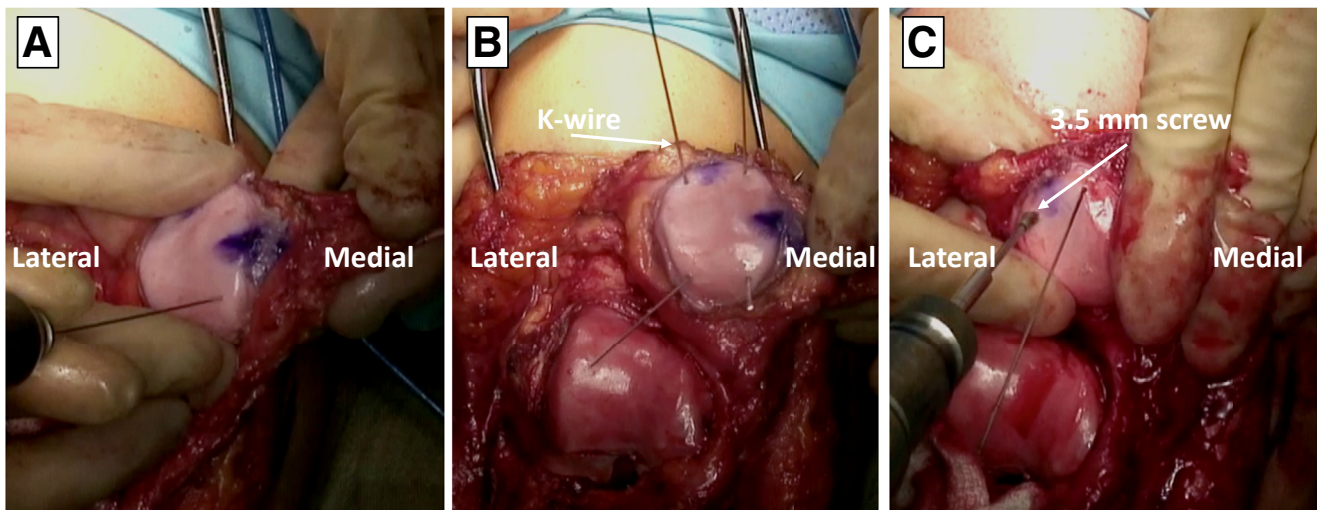


Fig 10. Intraoperative photograph of a right knee undergoing fixation of a patellar osteochondral allograft. K-wires are being placed at the periphery of a patellar osteochondral allograft (A), with 2 lateral and 2 medial K-wires used for temporary fixation (B). For definitive fixation, headless screws are being placed using the K-wires as a guide for placement (C).

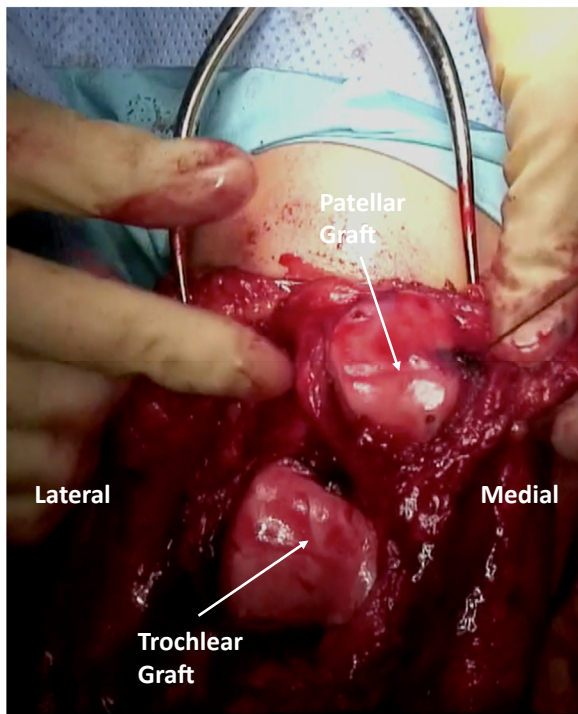


Fig 11. Intraoperative photograph of a right knee with bipolar osteochondral allografts appropriately sized and definitively fixed at the patellofemoral joint.

stitches of the graft to the tissues from the native medial patellar and femoral ligament are performed and also reinforced to the vastus medialis.

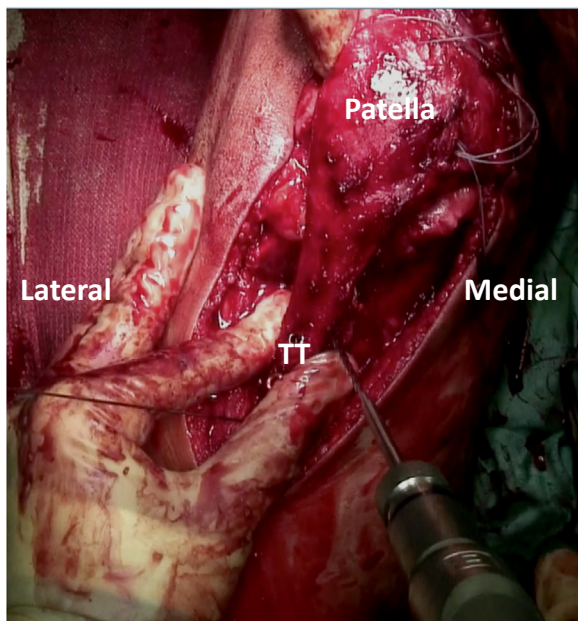


Fig 12. Intraoperative photograph of a right knee undergoing fixation of a tibial tubercle osteotomy with large frag screws being drilled in a lag fashion. (TT, tibial tubercle.)

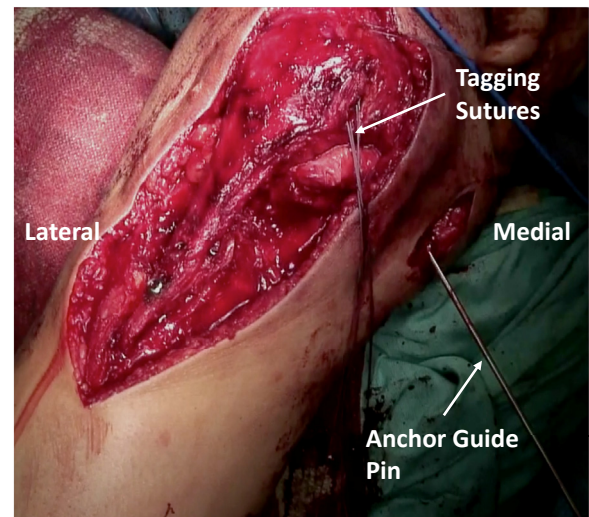


Fig 13. Intraoperative photograph of a right knee undergoing MPFL reconstruction with a semitendinosus allograft. An anchor guide pin is being used to mark the origin of the MPFL on the femur and tagging sutures used to mark the location of its insertion on the patella. (MPFL, medial patellofemoral ligament.)

Lateral Lengthening and Closure

With reconstruction complete, tracking of the patella within the trochlear groove is assessed. If any tendency toward lateral subluxation remains, we recommend a lateral lengthening of 15 to 20 mm. Layer 1 on the lateral side of the arthrotomy defect is sutured to layers 2 and 3 on the medial side. Typically, the lateral lengthening is closed with the knee held in approximately 70° of flexion. The most distal aspect of the defect (infrapatellar portion) should not be closed to avoid infrapatellar scarring and patella baja (Table 1).

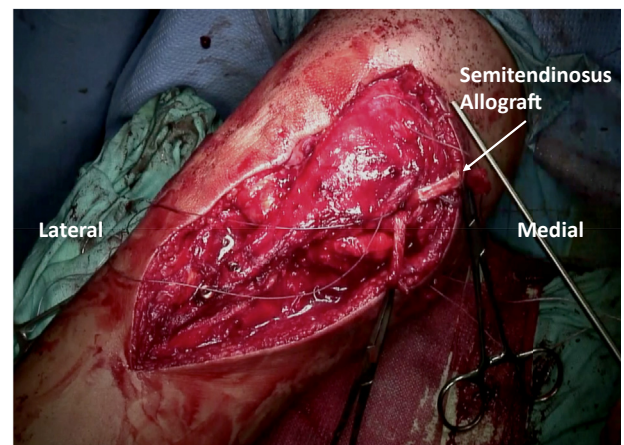


Fig 14. Intraoperative photograph of a right knee undergoing MPFL reconstruction with hemostats being used to grab the free ends of a semitendinosus allograft that has been fixed with suture tack anchors to reconstruct the native MPFL. (MPFL, medial patellofemoral ligament.)

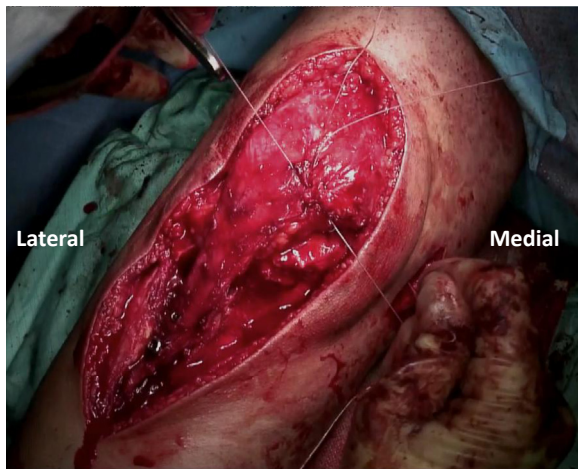


Fig 15. Intraoperative photograph of a right knee undergoing medial patellofemoral ligament reconstruction. Imbricating sutures are being used to imbricate the graft to the tissues of the medial retinaculum and remnants of the native medial patellofemoral ligament.

Copious irrigation with sterile saline and 0.25% Betadine is then performed and the surgical site is closed in standard fashion with 0 Vicryl loosely in the

anterior compartment, 0 Vicryl in deep subcutaneous tissues, 2-0 subcutaneous Vicryl, and a running 3-0 Monocryl.

Postoperative Rehabilitation

The patient can be weight bearing as tolerated, with her knee locked in extension in a hinged knee brace while using crutches for the first 6 weeks postoperatively. Active knee extension is avoided for 6 weeks to allow for osteotomy healing. Quadriceps sets and straight leg raises will be encouraged with the knee brace in place. If chronic quadriceps contracture is present, we recommend only allowing 0 to 70° of active and passive flexion for the first 2 weeks postoperatively and then mobilization with the goal of obtaining greater than 90° of flexion by postoperative weeks 3 to 4. The patient should achieve over 120° of flexion by week 6.

Discussion

A technique for bipolar osteochondral allografting of the patella and trochlea with Fulkerson osteotomy, MPFL reconstruction, and lateral lengthening for bipolar osteochondral defects and chronic patellar

Table 1. Pearls and Pitfalls

Pearls	Pitfalls
Use a systematic, repeatable approach in evaluating limb alignment, osseous structure of the patella and trochlea, and the integrity of soft-tissue constraints for choice of joint reconstructive techniques.	Do not violate the tibial plateau when performing the tibial tubercle osteotomy. Angle your cut appropriately and use a neurovascular protector to protect the exit site.
Obtain a CT scan preoperatively to evaluate trochlear dysplasia and TT-TG distance.	If using cannulated screws for graft fixation, they should be at least 3.5 mm. The 2.5-mm cannulated screw driver has the potential to break because of the torque/bite in good young bone.
Obtain long leg films to evaluate limb alignment (i.e. Q-angle).	Avoid closing inferior to the patella, as this may result in infrapatellar scarring and subsequent patella baja.
Perform a diagnostic arthroscopy as a separate procedure and on a separate day. This will help determine the cartilage procedure needed, allow adequate time to obtain the proper graft materials, and determine the extent of lateral and or medial instability.	Avoid prolonged postoperative immobilization to prevent knee joint stiffness postoperatively.
Leave the Fulkerson osteotomy unfixed until completion of the patellar and trochlear grafting, and return to fixation once grafts are sized appropriately and fixed in place.	
Fix the patellar allograft with screws going from the articular surface into the native patella. This will allow for the strongest fixation in the allograft piece.	
Insert patellar anchors for the MPFL reconstruction before fixing the Fulkerson osteotomy. This reduces tension on fixation and makes it easier to visualize anchor sites and drill.	
Check the isometry of the MFPL graft using a suture around a pin in Schöttle's point.	
Evaluate tracking of the patella in the trochlear groove at the end of the case to assess MPFL allograft tension and help determine lateral closure technique (lengthening vs release). We recommend a lateral lengthening of 15-20 mm if any tendency for lateral subluxation is noted.	

CT, computed tomography; MPFL, medial patellofemoral ligament; TT-TG, tibial tubercle–trochlear groove.

instability in a young, active patient has been described in this surgical technique. If not adequately treated, cartilage lesions of the patellofemoral joint frequently progress to advanced osteoarthritis, relegating patients to arthroplasty procedures. To prevent this, OCA transplantation has been recommended in young patients for chondral defects throughout the knee.⁵ The only technique that treats cartilage defects with anatomically matched hyaline cartilage, OCA transplantation has the advantage of no donor-site morbidity, a minor immunologic response, and improved chondrocyte viability when compared with frozen allografts.⁸ Limitations of OCA include decreased success when performed as bipolar allografts (similar to other cartilage transplantation procedures) and evidence of increased antibody responses in relation to graft size, although such antibody responses have not been shown to decrease graft survival.⁸

Although OCAs have a long clinical history and have shown greater than 75% clinical success rates for treatment of knee defects,⁹⁻¹² bipolar OCAs have reported poorer results. In contrast to this, Torga Spak and Teitg¹³ demonstrated good results with bipolar allografts in a young cohort of 14 patellofemoral OCAs for patellofemoral arthritis. Twelve of the allografts examined in this study were bipolar OCAs, and 10 of the 14 implants studied lasted greater than 10 years. In a recent 10 year-follow up, Meric et al.⁵ demonstrated 64.1% survivorship of 48 bipolar OCAs at 5 years and 39% at 10 years. Thirty-four of their OCA procedures involved the tibiofemoral joint and 14 involved the patellofemoral joint. Although survivorship was low, all patients whose implants were in situ at their final follow-up demonstrated significantly improved pain and function compared with their preoperative status. Specifically, this subset of patients experienced a mean International Knee Documentation Committee pain score improvement from 7.5 to 4.7, and a mean International Knee Documentation Committee function score from 3.4 to 7.0.⁵

Critically evaluating the etiology of patellofemoral instability is imperative to the success of these grafts. Chronic instability and bony malalignment in particular must be corrected for biologic resurfacing of the patellofemoral joint to succeed. If joint kinematics and excess load from bony malalignment are not identified and corrected, the allograft will follow the same deterioration as the original articular cartilage.¹³

Further outcomes studies examining bipolar OCAs for patellofemoral chondral and osteochondral lesions are needed. In particular, an increased understanding of risk factors for implant failure in bipolar OCAs would be

of great benefit due to the demonstrated improved subjective and objective outcomes seen in patients whose implants do not fail. We recommend our described transplant technique using bipolar OCAs in conjunction with correction of known risk factors for patellofemoral instability in young, active patients to improve function, prevent the development of diffuse patellofemoral arthritis, and delay arthroplasty procedures.

References

1. Christensen TC, Sanders TL, Pareek A, Mohan R, Dahm DL, Krych AJ. Risk factors and time to recurrent ipsilateral and contralateral patellar dislocations. *Am J Sports Med* 2017;45:2105-2110.
2. Sanders TL, Pareek A, Hewett TE, Stuart MJ, Dahm DL, Krych AJ. High rate of recurrent patellar dislocation in skeletally immature patients: A long-term population-based study. *Knee Surg Sports Traumatol Arthrosc* 2018;26:1037-1043.
3. Weber AE, Nathani A, Dines JS, et al. An algorithmic approach to the management of recurrent lateral patellar dislocation. *J Bone Joint Surg Am* 2016;98:417-427.
4. Mankin HJ. The response of articular cartilage to mechanical injury. *J Bone Joint Surg Am* 1982;64:460-466.
5. Meric G, Gracitelli GC, Görtz S, De Young AJ, Bugbee WD. Fresh osteochondral allograft transplantation for bipolar reciprocal osteochondral lesions of the knee. *Am J Sports Med* 2015;43:709-714.
6. Caton J, Deschamps G, Chambat P, Lerat JL, Dejour H. Patella infera. Apropos of 128 cases. *Rev Chir Orthop Reparatrice Appar Mot* 1982;68:317-325 [in French].
7. Schöttle PB, Schmeling A, Rosenstiel N, Weiler A. Radiographic landmarks for femoral tunnel placement in medial patellofemoral ligament reconstruction. *Am J Sports Med* 2007;35:801-804.
8. Hunt HE, Sadr K, Deyoung AJ, Gortz S, Bugbee WD. The role of immunologic response in fresh osteochondral allografting of the knee. *Am J Sports Med* 2014;42:886-891.
9. Aubin PP, Cheah HK, Davis AM, Gross AE. Long-term followup of fresh femoral osteochondral allografts for posttraumatic knee defects. *Clin Orthop Relat Res* 2001;3318-3327.
10. Bugbee W, Cavallo M, Giannini S. Osteochondral allograft transplantation in the knee. *J Knee Surg* 2012;25:109-116.
11. Cameron JI, Pulido PA, McCauley JC, Bugbee WD. Osteochondral allograft transplantation of the femoral trochlea. *Am J Sports Med* 2016;44:633-638.
12. Lattermann C, Kremser V, Altintas B. Use of fresh osteochondral allografts in the patellofemoral joint. *J Knee Surg* 2018;31:227-230.
13. Torga Spak R, Teitge RA. Fresh osteochondral allografts for patellofemoral arthritis: Long-term followup. *Clin Orthop Relat Res* 2006;444:193-200.