

Delayed Paraplegia in an Adult Patient With Spinal Cord Injury without Radiographic Abnormality of Dorsal Spine: A Lesson Learned

Abstract

Noncompressive myelopathy of lower dorsal spine secondary to trauma is a rare event. We report a case of delayed paraplegia in a patient with a history of road traffic accident. The X-ray of dorsolumbar spine did not show any abnormality. Magnetic resonance imaging of dorsolumbar spine was performed which showed the presence of central T2-weighted hyperintensities from D10–D11 to D12–L1 level. No associated bony injury was documented, and the integrity of the spinal canal was maintained. The patient was managed conservatively with bed rest, and steroids were given. However, the patient did not show any signs of improvement after 1 month of follow-up.

Keywords: Delayed paraplegia, dorsal spine injury, magnetic resonance imaging, noncompressive myelopathy, spinal cord injury without radiographic abnormality

**Amitesh Dubey,
Sachin Tomar,
Ashok Gupta,
Dinesh Khandelwal**

Department of Neurosurgery,
SMS Medical College, Jaipur,
Rajasthan, India

Introduction

Posttraumatic paraplegia occurs commonly due to compression of spinal cord associated with vertebral fracture and ligamentous injury.^[1] However, Pang and Wilberger in 1982 were the first to describe spinal cord injury without radiographic abnormality (SCIWORA).^[2] It is a type of spinal cord injury without any evidence of vertebral fracture or bony misalignment as evidenced by plain radiographs or computed tomography (CT). With the advent of magnetic resonance imaging (MRI), there has been a surge in the detection of the ligamentous injuries, cord edema, and contusions in the cases which were previously categorized as SCIWORA. SCIWORA is common in the pediatric population, and its reported incidence in the literature ranges from 4% to 66%.^[3-5] Very few cases of SCIWORA have been reported in the adult population and majority of these cases document abnormalities in cervical spine.^[6] Involvement of dorsal spinal cord is extremely rare, and only six case reports were found in the literature.^[7-10]

We report a case of a 30-year-old male patient with a history of road traffic accident who presented with delayed onset paraplegia with noncompressive injury

to the dorsal spinal cord (as ruled out by imaging).

Case Report

A 30-year-old patient was referred to the emergency department after a recent road traffic accident. The history was suggestive of sudden flexion followed by extension of spine. At the time of admission, the body temperature was 98.1 F, pulse 72 beats/min, respiratory rate was regular, 16 breaths/min, and blood pressure was 124/80 mmHg. Mental status, speech, cerebellar, and cranial nerve examinations were normal. Respiratory, cardiovascular, and abdominal examinations were normal. Motor strength as per medical research council (MRC) was grade 5/5 in all four limbs. The back showed no spinal deformity, and the skin was intact. Plain CT scan of the brain showed evidence of pneumocephalus with small air pockets present at bilateral frontoparietal regions. Patient was being managed conservatively.

On the 2nd day, patient complained of backache and gradually developed flaccid paraplegia. His motor power was 0/5 in bilateral lower limbs, below L2 level and had a sensory loss to all modalities below D12 level. Tone in bilateral lower limbs was decreased. Knee and ankle jerks were absent. Plantar reflex was mute bilaterally. His bladder and bowel reflexes were also involved.

This is an open access journal, and articles are distributed under the terms of the Creative Commons Attribution-NonCommercial-ShareAlike 4.0 License, which allows others to remix, tweak, and build upon the work non-commercially, as long as appropriate credit is given and the new creations are licensed under the identical terms.

For reprints contact: reprints@medknow.com

How to cite this article: Dubey A, Tomar S, Gupta A, Khandelwal D. Delayed paraplegia in an adult patient with spinal cord injury without radiographic abnormality of dorsal spine: A lesson learned. Asian J Neurosurg 2018;13:867-9.

Address for correspondence:

Dr. Amitesh Dubey,
Department of Neurosurgery,
SMS Medical College, Tonk
Road, Jaipur, Rajasthan, India.
E-mail: amiteshdubey1@gmail.
com

Access this article online

Website: www.asianjns.org

DOI: 10.4103/1793-5482.238013

Quick Response Code:



Dorsal and lumbosacral spine radiographs (anteroposterior, lateral) revealed normal curvature, normal height, and alignment of vertebral bodies, well-preserved disk spaces, and normal pedicles and posterior elements. MRI of dorsolumbar spine [Figure 1] revealed evidence of elongated central T2 hyperintensities extending from lower end plate level of D9 to mid D11 vertebral plane. Another similar T2 hyperintense focus was seen from D12 to L1 level. No bony, ligamentous, or soft tissue injury was appreciated.

Patient was managed conservatively with bed rest, and steroid therapy was initiated. Passive exercises were initiated by the physiotherapists. After 10 days, the patient did not show any improvement in motor power and sensations, and he was discharged from the hospital with an advice of regular follow-up. After 1 month of follow-up, the patient did not show any improvement in the neurological status. Repeat MRI [Figure 2a] was performed which showed the presence of central T2 hyperintensities from D9 to L1 level. Diffusion-weighted imaging [Figure 2b] showed restricted diffusion at these levels.

Discussion

Pang and Pollack have classified SCIWORA into four groups on the basis of age.^[11] The adult group (16–45 years old) under which the patient in this case falls, is known to have a low incidence rate of SCIWORA while it is commonly seen in the pediatric population. The higher incidence of SCIWORA in children has been attributed to the inherent soft tissue elasticity of spine in children.^[12] There is a decrease in elasticity of the spine as the child grows leading to higher incidence of bony fractures in adults. Another hypothesis states that SCIWORA is caused by the differential stretch of the spinal cord and the spine. Besides these, there are vascular and concussive hypotheses, but they lack accurate evidence.^[12] While most of the SCIWORA cases are accounted for by cervical

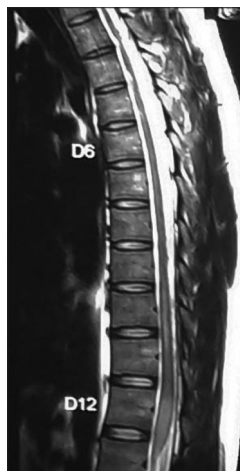

Figure 1: Magnetic resonance imaging of dorsal spine showing central T2 hyperintensities of the cord

cord injuries, the cases by thoracic cord injuries are rare. The rarity of SCIWORA in thoracic spine may be due to the splinting effect of the rib cage, which prevents translation of the vertebral column and subsequent spinal cord injury.^[13] However, longitudinal distraction due to hyperextension can lead to thoracic cord injury.

Medullary edema after spinal cord injury is generally known to be seen between 24 and 72 h after the injury. Regarding the timing of the onset of neurological symptoms, however, Hamilton and Myles *et al.* have stated that the symptoms could occur 4 days after the injury.^[14] While the mechanism of occurrence of medullary edema has not been accurately revealed, three hypotheses have been suggested. The first hypothesis states worsening and progression of the symptoms because of the continuous spinal movement without initial fixation after the occurrence of instability. The second hypothesis deemed it possible when the original cause of the injury is the type that gradually progresses and destroys the nerve tissue such as in ischemia. The third states it as the gradual progression of edema or hemorrhage.^[11]

In our case, the patient fell asleep while sitting in the front seat of a four-wheeler when it suddenly collided with a stationary truck. It may have caused sudden flexion followed by extension of the spine which caused gradual onset spinal cord injury. In our case, the cause of spinal injury appears to be due to vascular compromise as there was no improvement in the neurological status of the patient after 1 month follow-up and MRI revealed restricted diffusion of the involved segment of the spinal cord. Previously reported cases in the literature of the thoracic SCIWORA were managed conservatively. Some of the authors had included steroids as part of their treatment plan along with bed rest.^[1,9,10] The use of steroids is not supported by substantial evidence in these cases. Incomplete spinal cord syndromes had shown better results in terms of neurological improvement than complete injuries which were seen in our case.^[15] The appropriate management in the adult SCIWORA cases is still debatable and not well established and must be tailored according to the cause of injury.

Conclusion

SCIWORA of adult thoracic spine causing delayed paraplegia is a rare entity. As seen in this case, clinicians

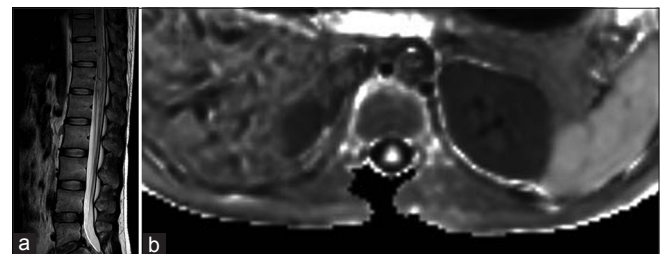


Figure 2: (a) Magnetic resonance imaging of dorsal spine after 1 month follow-up showing central T2 hyperintensities of the cord. (b) Diffusion-weighted imaging of the spine showing restricted diffusion

should recognize the possibility of SCIWORA caused by trauma, seen at thoracic level and deterioration after a minor trauma. Therefore, precautions must be taken for appropriate acute phase management. Further studies on the appropriate management and prediction of prognostic factors of delayed onset paraplegia due to SCIWORA are necessary.

Financial support and sponsorship

Nil.

Conflicts of interest

There are no conflicts of interest.

References

1. Park MC, Bok SK, Lee SJ, Ahn DH, Lee YJ. Delayed onset of thoracic SCIWORA in adults. *Ann Rehabil Med* 2012;36:871-5.
2. Pang D, Wilberger JE Jr. Spinal cord injury without radiographic abnormalities in children. *J Neurosurg* 1982;57:114-29.
3. Choi JU, Hoffman HJ, Hendrick EB, Humphreys RP, Keith WS. Traumatic infarction of the spinal cord in children. *J Neurosurg* 1986;65:608-10.
4. Hill SA, Miller CA, Kosnik EJ, Hunt WE. Pediatric neck injuries. A clinical study. *J Neurosurg* 1984;60:700-6.
5. Ruge JR, Sinson GP, McLone DG, Cerullo LJ. Pediatric spinal injury: The very young. *J Neurosurg* 1988;68:25-30.
6. Tewari MK, Gifti DS, Singh P, Khosla VK, Mathuriya SN, Gupta SK, *et al.* Diagnosis and prognostication of adult spinal cord injury without radiographic abnormality using magnetic resonance imaging: Analysis of 40 patients. *Surg Neurol* 2005;63:204-9.
7. Samsani SR, Calthorpe D, Geutjens G. Thoracic spinal cord injury without radiographic abnormality in a skeletally mature patient: A case report. *Spine (Phila Pa 1976)* 2003;28:E78-80.
8. Koizumi M, Ueda Y, Iida J, Matsuyama E, Yoshikawa T, Takakura Y, *et al.* Upper thoracic spinal cord injury without vertebral bony lesion: A report of two cases. *Spine (Phila Pa 1976)* 2002;27:E467-70.
9. Van Buul G, Oner FC. Thoracic spinal cord injury without radiographic abnormality in an adult patient. *Spine J* 2009;9:e5-8.
10. Khatri K, Farooque K, Gupta A, Sharma V. Spinal cord injury without radiological abnormality in adult thoracic spinal trauma. *Arch Trauma Res* 2014;3:e19036.
11. Pang D, Pollack IF. Spinal cord injury without radiographic abnormality in children – The SCIWORA syndrome. *J Trauma* 1989;29:654-64.
12. Burke DC. Traumatic spinal paralysis in children. *Paraplegia* 1974;11:268-76.
13. Winn HR. *Youmans Neurological Surgery*. 5th ed. Philadelphia: Saunders; 2004. p. 3518-26.
14. Hamilton MG, Myles ST. Pediatric spinal injury: Review of 174 hospital admissions. *J Neurosurg* 1992;77:700-4.
15. Grabb PA, Pang D. Magnetic resonance imaging in the evaluation of spinal cord injury without radiographic abnormality in children. *Neurosurgery* 1994;35:406-14.