



Since January 2020 Elsevier has created a COVID-19 resource centre with free information in English and Mandarin on the novel coronavirus COVID-19. The COVID-19 resource centre is hosted on Elsevier Connect, the company's public news and information website.

Elsevier hereby grants permission to make all its COVID-19-related research that is available on the COVID-19 resource centre - including this research content - immediately available in PubMed Central and other publicly funded repositories, such as the WHO COVID database with rights for unrestricted research re-use and analyses in any form or by any means with acknowledgement of the original source. These permissions are granted for free by Elsevier for as long as the COVID-19 resource centre remains active.



ELSEVIER



## Correspondence and Communications

## Bespoke regional blocks for axillary sentinel node biopsy



Dear Sir,

Sentinel Lymph Node Biopsy (SLNB) for melanoma is a well-established highly accurate prognostic investigation which has been at the forefront of melanoma staging for the past 15 years [1]. SLNB is usually performed under General Anaesthetic (GA). However, in the context of COVID-19, there is an associated risk of increased morbidity and mortality with GA [2] and the literature suggests regional or local alternatives should be favoured as they avoid intubation related seeding of pathogens to the lower respiratory tract, and are associated with decreased thromboembolic complications and decreased surgical stress response [3,4]. During the first peak of the pandemic we halted our sentinel node service as per BAPRAS guidance and either carried out treatment margin excisions or 1 cm excisions pending delayed SLNB as appropriate. Once the hospital COVID-19 pressure settled, we sought a regional anaesthetic option for our sentinel node service to obviate potential risks of GAs. For lower limb melanomas this was achieved through spinal anaesthesia, however options for the axilla were limited. Ultimately, we wanted to provide the same high level of melanoma care for all patients. We challenged our anaesthetic colleagues for a bespoke solution in the form of a regional axillary block for melanomas of the upper limb or ipsilateral upper torso with a single draining lymph node basin in the axilla.

The axilla is often described as a difficult zone to block. The apex of the axilla is innervated by the intercosto-brachial nerve, a cutaneous branch of the second intercostal nerve (T2). The pectoralis major and minor muscles are innervated by the medial (C8-T1) and lateral pectoral nerves (C5-C7). Serratus anterior is supplied by the long thoracic nerve (C5-C7). Latissimus dorsi is supplied by the thoracodorsal nerve (C6-C8). These nerves can be blocked through a combination of interfascial blocks with ultrasound guidance (PEC I between the pectoralis major and minor muscles, PEC II between pectoralis minor and serratus anterior and the deep serratus block between serratus anterior and the ribs / intercostal muscles). The addition of a brachial plexus block allows anaesthesia for the treatment margin excision of the melanoma scar on the upper limb and also anaesthetises the associated myotomes.

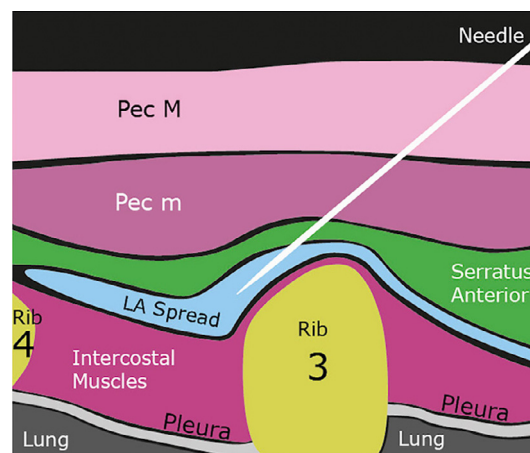


Figure 1 Diagram of the deep serratus plane block.

Following approval from the Joint Study Review Committee on behalf of the Research and Ethics Department we consented and operated on 10 consecutive patients collecting PROMs using the validated Quality of Recovery (QoR15)[5] questionnaire pre and post operatively. All patients were operated on as day case following two weeks isolation and a negative COVID-19 test. The regional anaesthesia for the axillary blocks was given with ultrasound guidance. Figure 1 which shows a deep serratus block. Patients were offered and received intravenous sedation if required. SLNB was carried out in a standard manner with either lymphoscintigraphy the afternoon before surgery or the morning of surgery.

10 patients were treated over a two-week time period (four male/six females). Mean age was 52 years (27-71). Mean Breslow thickness was 2.8 mm (0.8 - 7). All patients were discharged the same day. The average time spent in hospital following surgery was 2.2 h (1-4.5 h range). When compared to an average four hours spent in hospital following a GA, this time was significantly shorter ( $p = 0.0008$ ). 90% of patients were discharged in under four hours. There were no complications. The procedure was well tolerated. However, variable anatomy needs to be taken into consideration as some patients required additional LA or sedation. No patient required conversion to a GA. Histological analysis found one patient to have a positive sentinel node.

Analysis of the PROMs demonstrated high levels of patient satisfaction as evidenced by a lack of statistical difference between pre and post-operative scores ( $p = 0.0118$ ), (see Table 1). Additional qualitative analysis revealed 80% of patients were happy to have a regional block, 70% stated

**Table 1** shows a comparison between pre-operative and post-operative scores using the QoR15.

Question	Pre-operative	Post-operative	Change in score	P Value
1. Able to breathe easily	9.8 +/- 0.6	9.8 +/- 0.6	0	1
2. Been able to enjoy food	9.4 +/- 1.3	8.4 +/- 2.8	1	0.236708
3. Feeling rested	8.9 +/- 1.4	7.4 +/- 2.8	1.1	0.119665
4. Have had a good sleep	8.1 +/- 2.2	7.6 +/- 3	0.5	0.647364
5. Able to look after personal toilet and hygiene unaided	9.8 +/- 0.6	8.9 +/- 1.8	0.9	0.081126
6. Able to communicate with family or friends	10 +/- 0	9.8 +/- 0.6	0.2	0.343436
7. Getting support from hospital doctors and nurses	10 +/- 0	9.6 +/- 0.9	0.4	0.222868
8. Able to return to work or usual home activities	9.7 +/- 0.6	7.4 +/- 2.1	2.5	0.007804
9. Feeling comfortable and in control	9.9 +/- 0.3	7.1 +/- 1.8	2.8	0.001081
10. Having a feeling of general well-being	9.3 +/- 1.3	7.9 +/- 1.9	1.4	0.082993
11. Moderate pain	10 +/- 0	6.3 +/- 2.8	3.7	0.003245
12. Severe pain	10 +/- 0	7.4 +/- 3	2.6	0.029011
13. Nausea or vomiting	10 +/- 0	7.5 +/- 3.9	2.5	0.083468
14. Feeling worried or anxious	8.3 +/- 1.8	8 +/- 2.6	0.3	0.788556
15. Feeling sad or depressed	9.3 +/- 1.4	9 +/- 1.8	0.3	0.520307

they would recommend the procedure to a friend or family member and 90% were happy to attend hospital during the COVID-19 pandemic.

Following this pilot study, we have carried out an additional 30 axillary SLNB under bespoke regional block. We have demonstrated this is a safe, well tolerated procedure that allows the surgeon to remove a lymph node anywhere in the axilla including level III. Anecdotally there is an increased risk of bleeding due to the vasodilatory effects of the regional anaesthesia and the loss of a hypotensive general anaesthesia, however, with judicious haemostasis there have been no post-operative haematomas.

This technique of bespoke axillary block is safe and effective. It negates the current risks associated with performing GAs during the COVID-19 pandemic and facilitates more rapid turnover and discharge from hospital. There was a learning curve associated with the efficiency and accuracy of performing blocks which like many regional techniques is also variable between patients. We wanted to ensure surgical outcomes were not compromised by performing axillary SLNB under regional block and we are confident the regional block allows excision of all hot lymph nodes as identified by the lymphoscintigraphy.

## Funding

None.

## Conflicts of Interest

None declared.

## Ethical approval

Approval was granted by the Joint Study Review Committee on behalf of the Research and Ethics Department, Morriston Hospital, Morriston.

## Acknowledgements

We thank Rhys Whelan, Morriston Hospital Library for conducting the literature review and Steve Atherton, Morriston Hospital for his expertise and help with the figures.

## References

1. Peach H, Board R, Cook M, et al. Current role of sentinel lymph node biopsy in the management of cutaneous melanoma: a UK consensus statement. *J. Plast. Reconstr. Aesthet. Surg.* 2020;73(1):36-42.
2. Bhangu A, et al. COVIDSurg Collaborative. Mortality and pulmonary complications in patients undergoing surgery with peri-operative SARS-CoV-2 infection: an international cohort study. *The Lancet* 2020:1-12 pg.
3. Macfarlane A, Harrop-Griffiths W, Pawa A. Regional anaesthesia and COVID-19: first choice at last? *Br. J. Anaesth.* 2020;125:243-7.
4. Hou Y, Okuda K, Edwards C, et al. SARS-CoV-2 reverse genetics reveals a variable infection gradient in the respiratory tract. *Cell* 2020;182(46e14):429.
5. Kleif J, Waagr J, Christensen K, Gögenur I. Systematic review of the QoR-15 score, a patient-reported outcome measure measuring quality of recovery after surgery and anaesthesia. *Br. J. Anaesth.* 2018;120(1):28-36.

R Clancy, S Hemington-Gorse, S Pope-Jones  
The Welsh Centre for Burns and Plastic Surgery, Morriston Hospital, Swansea SA6 6LN, United Kingdom

A Jayakumar, C Beynon, C Egeler  
Anaesthetics Department, Morriston Hospital, Swansea SA6 6LN, United Kingdom

J Cubitt  
The Welsh Centre for Burns and Plastic Surgery, Morriston Hospital, Swansea SA6 6LN, United Kingdom  
E-mail address: [rachelclancy@hotmail.com](mailto:rachelclancy@hotmail.com) (R. Clancy)

© 2021 Published by Elsevier Ltd on behalf of British Association of Plastic, Reconstructive and Aesthetic Surgeons.

<https://doi.org/10.1016/j.bjps.2021.05.007>

## Brachial plexus block versus wide-awake local anaesthesia for open reduction internal fixation surgery in distal radius fracture: A preliminary retrospective report



Dear Sir,

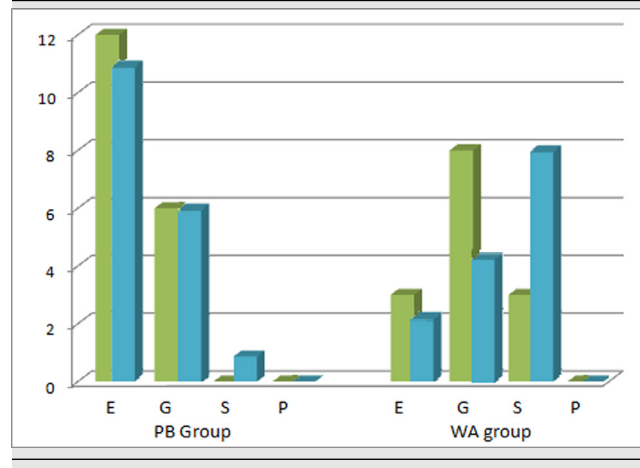
### Introduction

Volar plating is the gold standard for open reduction internal fixation (ORIF) of distal radius fractures leading to good stability and allowing early mobilization of the wrist.<sup>1</sup> Standard anaesthesia techniques have been described for ORIF of the wrist, and these include axillary regional block, forearm block and intravenous regional anaesthesia.<sup>2</sup> These techniques require different approaches to the patient, either concerning tourniquet use and sedation during surgery. More recently, the WALANT technique (Wide-Awake Local Anaesthesia No Tourniquet) in which local anaesthesia without tourniquet and sedation is used, has been increasingly used by hand surgeons.<sup>3</sup> In this retrospective case series, we compared the perioperative features and patient reported pain in subjects that undergone ORIF for distal radius fractures, with axillary block or WALANT.

### Materials and methods

We retrospectively reviewed medical records of all patients that underwent ORIF for distal radius fractures at our institution between March 2019 and November 2019. This procedure was performed with brachial plexus block until July 2019, while, from August 2019 we also introduced the wide-awake local anaesthesia (WALANT). Perioperative data were collected from medical records and included: type and time of anaesthesia, surgical time and tourniquet time; 10 cm Visual Analogue Scale (VAS)<sup>4</sup> for pain before and during surgery, at the end of the surgical procedure and discharge (12 to 14 h after surgery); postoperative (until discharge) use of NSAIDs; surgeon opinion on operability; patient opinion on the overall perioperative comfort. The surgeon's and patient's opinions were rated on a 4-point scale, including 'poor', 'sufficient', 'good', and 'excellent' grades. Data were collected and analysed by a researcher blinded to patients status and surgical procedures. Given the non-normal

**Table 1** Before surgery, the mean VAS was  $3.4 \pm 1.4$  in PB group vs.  $6.9 \pm 1.2$  in WA group ( $p = 0.000006$ ); intraoperatively, at the time of fracture reduction, mean VAS was  $0.7 \pm 0.7$  in PB group vs.  $5.3 \pm 1.5$  in WA group ( $p = 0.000001$ ); at the end of surgery mean VAS was  $0.2 \pm 0.4$  in PB group, while averaged  $4.4 \pm 1$  in WA group ( $p = 0.000001$ ). At discharge, the morning after surgery, average VAS was  $3.4 \pm 0.8$  in PB group vs.  $7.2 \pm 0.7$  in WA group ( $p = 0.000001$ ).

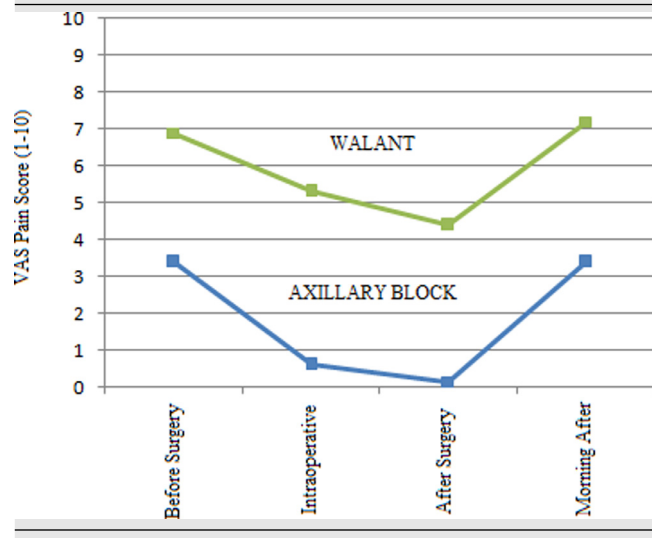


distribution of the data series, checked through visual methods, we considered non-parametric tests for data comparison. Comparative analysis at each time-point and for comparison of pre-operative with postoperative data was carried out using the Wilcoxon Sum rank test. A significance two-tail threshold was set with  $p = 0.05$ . A post-hoc calculation of the effect size showed a Cohen's  $d = 3.54$ , with  $\beta = 1$ .

### Results

We collected data of 32 patients that underwent ORIF for distal radius fractures, from March 2019 to November 2019; of these, 14 with wide-awake anaesthesia (WA group) and 18 with brachial plexus block (PB group). Average age was  $42 \pm 14$  years; 26 were male and 6 were female. No difference occurred between the groups concerning operating time, with mean times of  $27.3 \pm 4$  for PB and  $29.9 \pm 3.2$  for WA ( $p = 0.098596$ ). Mean time of tourniquet application in PB group was  $22.8 \pm 3.8$  min, while no tourniquet application was required in WA group. Pain averages were significantly higher in WA group at all time-points (Table 1). Overnight pain was controlled with NSAIDs. Four patients in the PB group required diclofenac 100 mg, for 2 of them 1 tablet was sufficient, while one required 2 tablets and one required Ketorolac 30 mg injection. In the WA group, pain was controlled for all patients with one Ketorolac 30 mg injection. However, sedation during surgery was required only by 3 patients in the PB group, because of tourniquet discomfort and none in the WA group. Overall satisfaction of the patients and surgeons was significantly higher in PB group (Table 2).

**Table 2** In green the surgeon rate, in blue patient rate. Surgeon opinion concerning operability was “Excellent” in 12 patients in PB group and 3 in WA group; “Good” in 6 patient in PB group and 6 in WA group; “Sufficient” in 5 patients of the WA group. Overall satisfaction of the patients was rated as ‘Excellent’ in 11 patients of PB group and 2 in WA group, ‘Good’ in 6 patients in the PB group and 4 in the WA group, ‘Sufficient’ in 1 patient in the PB group and 8 in the WA group .



## Discussion

The use of WALANT allows the surgery to be performed in an outpatient setting, with short observation period before discharge and with a significant reduction of overall procedure time and costs. Furthermore, the absence of an inflated tourniquet allows better control of bleeding, through direct visualization of vascular structures and prompt address of the bleeding with the electrocautery. However, this approach needs an appropriate postoperative pain management strategy, including strong NSAIDs as Ketorolac. In our study, patients in the WA group presented higher VAS average at all time points. It is interesting to notice, that also before surgery, those patients reported a significantly higher mean VAS, and this may influence the overall pain perception. This baseline difference constitutes a significant bias in evaluating pain and comparison between groups. It has been reported indeed that intense preoperative pain can be considered a negative predictive factor, influencing pain after major surgery.<sup>5</sup> Some limitations affect the results of this study. The different operator in administering anaesthesia and the absence of ultrasound guidance, did not allow standardization of the procedure. Furthermore, no data were available concerning the time from anaesthesia to surgery, which is detrimental for a complete time-effectiveness analysis.

## Conclusion

Our study represents the first study comparing local with plexus anaesthesia for ORIF treatment of distal radius fractures, with standardized and validated patient reporting outcome measures. In a setting of patient care, where

patient comfort is of paramount importance, the use of WALANT should be carefully evaluated and discussed with the patient prior the surgical intervention since a higher perception of pain during and after the procedure can be experienced by the patient.

## Funding

This research received no specific grant from any funding agency in the public, commercial, or not-for-profit sectors.

## Declaration of Competing Interest

The Authors declare that there is no conflict of interest.

## Ethical approval

Written informed consent for patient information and images was provided by a legally authorized representative. All the procedures performed in this study were in accordance with the 1964 Helsinki declaration and its later amendments or comparable ethical standards.

## References

- Arora R, Gabl M, Erhart S, Schmidle G, Dallapozza C, Lutz M. Aspects of current management of distal radius fractures in the elderly individuals. *Geriatr Orthop Surg Rehabil* 2011;2(5-6):187-94.
- Soberon JR, Crookshank JW, Nossaman BD, Elliott CE, Sisco-Wise LE, Duncan SF. Distal peripheral nerve blocks in the forearm as an alternative to proximal brachial plexus blockade in patients undergoing hand surgery: a prospective and randomized pilot study. *J Hand Surg Am* 2016;41(10):969-77.
- Ahmad AA, Yi LM, Ahmad AR. Plating of distal radius fracture using the wide-awake anesthesia technique. *J Hand Surg Am* 2018;43(11):1045 e1 -1045 e5.
- Guastafierro A, Avvedimento S, Pieretti G, et al. Steri-Strips™ vs. intracuticular skin suture in endoscopic release of carpal tunnel: a retrospective study and review of the literature. *Eur J Plast Surg* 2020;43(4):415-20.
- Hernández C, Díaz-Heredia J, Berraquero ML, Crespo P, Loza E, Ruiz Ibán MA. Pre-operative predictive factors of post-operative pain in patients with hip or knee arthroplasty: a systematic review. *Reumatol Clin (Engl Ed)* 2015;11(6):361-80.

Guglielmo Torre  
 Division of Plastic Surgery, Ospedale  
 Accreditato Villa dei Fiori, Acerra, Naples, Italy  
 Department of Orthopaedic and Trauma Surgery, Campus  
 Bio-Medico University of Rome, Italy

Stefano Avvedimento  
 Division of Plastic Surgery, Ospedale  
 Accreditato Villa dei Fiori, Acerra, Naples, Italy

Antonio Guastafierro, Mario Faenza, Gorizio Pieretti  
 Multidisciplinary Department of Medical-Surgical and  
 Dental Specialties, Plastic Surgery Unit, University of  
 Study degli Studi della Campania “Luigi Vanvitelli”, Viale  
 dei Pini, 6 Volla (NA), 80140 Naples, Italy

Roberto Cuomo  
Unit of Plastic Surgery, University of Siena, Italy

Sara Izzo  
Multidisciplinary Department of Medical-Surgical and  
Dental Specialties, Plastic Surgery Unit, University of  
Study degli Studi della Campania "Luigi Vanvitelli", Viale  
dei Pini, 6 Volla (NA), 80140 Naples, Italy

Feliciano Ciccarelli  
Division of Plastic Surgery, Ospedale  
Accreditato Villa dei Fiori, Acerra, Naples, Italy  
E-mail address: [Antonio.guastafierro.15@gmail.com](mailto:Antonio.guastafierro.15@gmail.com) (A.  
Guastafierro)

© 2021 British Association of Plastic, Reconstructive and Aesthetic Surgeons. Published by Elsevier Ltd. All rights reserved.

<https://doi.org/10.1016/j.bjps.2021.03.065>

## Don't forget the block



Dear Sir,

The use of WALANT (wide awake local anaesthesia no tourniquet) has gained recent popularity, especially during the COVID-19 pandemic, for upper and lower limb surgery.<sup>1</sup> It avoids the need for an anaesthetist, reducing costs and issues with tourniquet pain.<sup>2</sup> However, WALANT is not entirely free of problems. Injecting local anaesthetic directly into and around the site of surgery causes local swelling and distorts tissue planes. Although adrenaline produces a relatively bloodless field, excessive post-op bleeding can be a problem once the adrenaline wears off and any fibrin deposition related to this may result in increased stiffness in both the short and long term.<sup>3</sup>

The predecessor to WALANT was the regional block and knowing how to administer one was always considered part of a hand surgeons' armamentarium. However, in the

UK today, 'blocks' are usually administered by an anaesthetist, under ultrasound guidance.<sup>4</sup> This was not always the case, and the senior author remembers a time when surgeons would routinely administer regional blocks themselves, safely, quickly and often more effectively than those now administered by anaesthetists.

We have speculated on the reasons for the greater speed and efficacy of surgeon-administered blocks in our unit compared with those administered by our anaesthetic colleagues. We wonder whether this is related to a better appreciation of the anatomy of the brachial plexus and/or sciatic nerves derived from direct experience of seeing these structures during surgery. Alternatively, it might be the result of our reliance on nerve stimulators (rather than ultrasound), and the positive feedback that is obtained from using this device during the block procedure.

Using a nerve stimulator, the patient confirms whether the intended nerve territory has been blocked (Table 1) which enhances the efficacy of the procedure. Moreover, injection of local anaesthetic immediately adjacent to the specific nerves ensures that anaesthesia is induced very quickly (typically within a few seconds), avoiding the need to wait for the block to 'cook'. Equally, there is no need to wait 30 minutes for the vasoconstrictive effect of the adrenaline with WALANT because a tourniquet can be used.<sup>5</sup> Using our block technique (Figure 1), tourniquet pain is not an issue because we are able to block both the axillary (deltoid area) and intercostobrachial nerves (inner arm). Therefore, the area to be treated can be prepped and surgery can begin almost immediately after administration of the regional block, resulting in further time-saving.

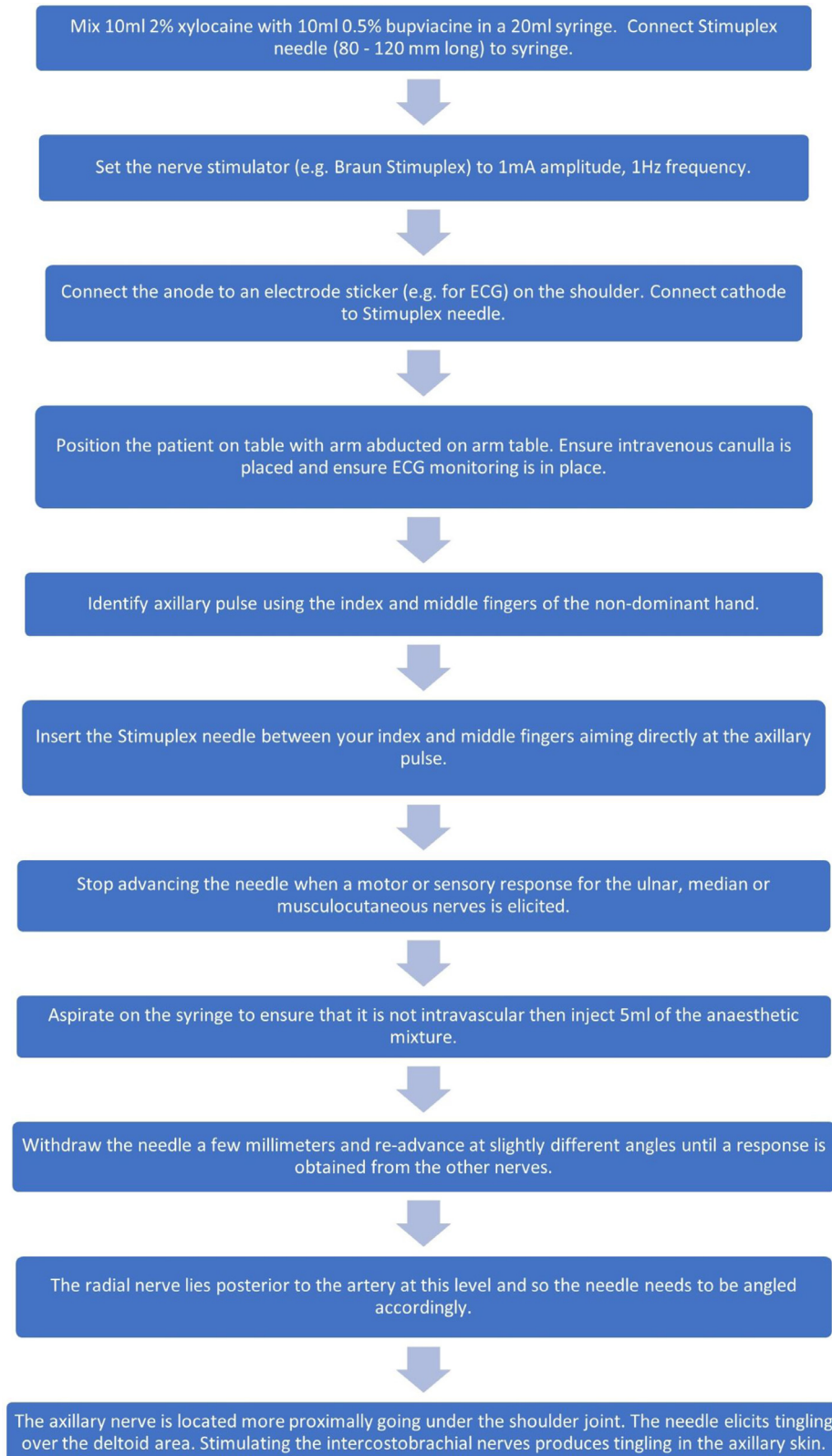WALANT and regional blocks both have definite roles in extremity surgery. Gauging the correct tension of a tendon transfer is definitely easier to do under WALANT. However, for most of the other procedures we do, the blocks we administer are quick, effective and often less painful than the alternatives. We would do well to remember how to do them.

### Ethical approval

N/A.

**Table 1** Anatomical landmarks, motor (muscle contraction) and sensory (paraesthesia) responses when administering regional blocks using a nerve stimulator.

	Landmark	Motor response	Sensory response
Ulnar nerve	Anterior (inferior) to axillary artery	Finger flexion	Little and ring fingers, medial forearm/ arm
Median nerve	Anterior (middle) to axillary artery	Wrist flexion	Thumb, index and middle fingers
Musculocutaneous nerve	Anterior (superior) to axillary artery	Elbow flexion	Lateral forearm
Radial nerve	Posterior (distal) to axillary artery	Wrist and elbow extension	Dorsum of hand, forearm and arm
Axillary nerve	Posterior (proximal) to axillary artery	Deltoid contraction	Lateral arm
Sciatic nerve	Midline posterior thigh	Plantar flexion	Posterior lower leg



**Figure 1** Guide to safe administration of an infraclavicular axillary block using a nerve stimulator.

## Declaration of Competing Interest

None.

## Funding

None.

## References

1. Hobday D, Welman T, O'Neill N, Pahal GS. A protocol for wide awake local anaesthetic no tourniquet (WALANT) hand surgery in the context of the coronavirus disease 2019 (COVID-19) pandemic. *Surgeon* 2020;18(6):e67-71.
2. Lalonde D.H. Latest advances in wide awake hand surgery. *Global advances in wide awake hand surgery, an issue of hand clinics, E-Book*, 2018.
3. Kulkarni M, Harris SB, Elliot D. The significance of extensor tendon tethering and dorsal joint capsule tightening after injury to the hand. *J Hand Surg Eur* 2006;31(1):52-60.
4. Marhofer P, Harrop-Griffiths W, Kettner SC, Kirchmair L. Fifteen years of ultrasound guidance in regional anaesthesia: part 1. *Br J Anaesth* 2010;104(5):538-46.
5. Lalonde D, Bell M, Benoit P, Sparkes G, Denkler K, Chang P. A multicenter prospective study of 3,110 consecutive cases of elective epinephrine use in the fingers and hand: the Dalhousie Project clinical phase. *J Hand Surg Am* 2005;30(5):1061-7.

Dimitris Reissis  
Norbert Kang

Department of Plastic and Reconstructive Surgery, Royal Free Hospital, Hampstead, London NW3 2QG, UK  
E-mail address: [dreissis@nhs.net](mailto:dreissis@nhs.net) (D. Reissis)

© 2021 British Association of Plastic, Reconstructive and Aesthetic Surgeons. Published by Elsevier Ltd. All rights reserved.

<https://doi.org/10.1016/j.bjps.2021.03.111>

## WALANT Protocol: Stop before you block



Dear Sir,

The use of Wide Awake Local Anaesthetic No Tourniquet (WALANT) has become increasingly popular both through interest and necessity. Since Don Lalonde's seminal description of WALANT<sup>1</sup>, the uptake of the technique has been accelerated by the impact of the COVID-19 pandemic. Restrictions and risks associated with anaesthesia during the pandemic enabled WALANT to grow in popularity and serve as an effective alternative in a time of crisis.<sup>2</sup>

In addition, proponents of WALANT have highlighted benefits of a bloodless field, improved recovery relative to general anaesthesia and significant time and cost reductions.<sup>3</sup> However, the uptake of WALANT is not ubiquitous,

with some questioning its effectiveness relative to regional anaesthesia with tourniquet. Further clinical trials are imminent to address the question of clinical equipoise, however, whilst demonstrating an excellent safety profile, a survey of plastic and orthopaedic surgeons in our department found a significant variety of beliefs towards the contraindications of WALANT. Thakkar et al. advise theoretical caution towards the use of adrenaline in patients with sickle cell disease.<sup>4</sup> and this would logically extend to other blood dyscrasias. The British Society for Surgery of the Hand (BSSH) provides a list of 7 contraindications to WALANT in the 2020 edition of their Handbook of Wide Awake Surgery. However, the contents of this list appear broad and include 'Cardiac disease' and 'Compromised Peripheral Circulation - Patients with previous vascular injury, vasculitis, Buerger's disease, scleroderma'. It is interesting to note that Raynaud's Disease is not explicitly named in the list of contraindications whilst this is often cited as being excluded from WALANT assessment.<sup>5</sup>

Further to the variety of contraindications and exclusion criteria, our survey also identified a wide variation in knowledge of reversal agent for complications of WALANT, with only 20% of those surveyed aware of Phentolamine being used as a reversal agent. None of those surveyed were aware of both the dosage and the location of Phentolamine in our hospital. The BSSH handbook also states that should the 'finger remain white after 4 h' Phentolamine can be administered. It is our experience that patients are not routinely observed for 4 h post-procedure, and are often discharged prior to this.

The successes of the WHO checklist and the Royal College of Anaesthetists campaign, titled 'Stop Before You Block', are both examples of the multiple significant improvements that can be achieved in clinical safety by introducing systems and formalised checkpoints into a process. We believe that the creation and implementation of a WALANT checklist prior to the administration of local anaesthetic with adrenaline into an extremity can lead to a significant improvement in patient care and prevent the inadvertent or accidental administration of local anaesthetic with adrenaline where it is contraindicated. We believe that the checklist should include contraindications to WALANT and also make the operator aware of the availability, dose and location of Phentolamine as a reversal agent. Further work is required to identify what specific contraindications to WALANT exist, however, by identifying the need for a protocol we hope to continue safeguarding and upholding patient safety whilst facilitating further, safe use of WALANT.

## Funding

N/A.

## Ethical Approval

N/A.



## Declaration of Competing Interest

N/A.

## References

1. Lalonde D, Martin A. Epinephrine in local anesthesia in finger and hand surgery: the case for wide-awake anesthesia. *J Am Acad Orthop Surg* 2013;21(8):443-7 Aug.
2. Khor WS, Lazenby DJ, Campbell T, Bedford JD, Winterton RIS, Wong JK, et al. Reorganisation to a local anaesthetic trauma service improves time to treatment during the COVID-19 pandemic - experience from a UK tertiary plastic surgery centre. *J Plast Reconstr Aesthet Surg* 2021;74(4):890-930 Apr.
3. Maliha SG, Cohen O, Jacoby A, Sharma S. A cost and efficiency analysis of the WALANT technique for the management of trigger finger in a procedure room of a major city hospital. *Plast Reconstr Surg Glob Open* 2019;7(11):e2509 Nov 20.
4. Thakkar M, Bednarz B. WALANT and sickle cell disease: a cautionary tale. *J Plast Reconstr Aesthet Surg* 2021 Mar.
5. Moog P, Dozan M, Betzl J, Sukhova I, Kükrek H, Megerle K. WALANT-Epinephrine injection may lead to short term, reversible episodes of critical oxygen saturation in the fingertips. *Arch Orthop Trauma Surg* 2021;141(3):527-33 Mar.

David Zargaran

Royal Free Hospital, Pond St, London NW3 2QG

Alexander Zargaran

St Thomas' Hospital, Westminster Bridge Rd, London SE1 7EH

Dariush Nikkha, Afshin Mosahebi

Royal Free Hospital, Pond St, London NW3 2QG

E-mail address: [alexanderzargaran@gmail.com](mailto:alexanderzargaran@gmail.com) (A. Zargaran)

© 2021 British Association of Plastic, Reconstructive and Aesthetic Surgeons. Published by Elsevier Ltd. All rights reserved.

<https://doi.org/10.1016/j.bjps.2021.05.025>

## Potentially serious incidental findings on medical imaging in plastic surgery patients: A single-institution retrospective cohort study



Dear Sir,

Incidental findings (IFs) in medical imaging, commonly known as incidentalomas, are unexpected findings that are not related to the original diagnostic inquiry, and they have recently become a medical problem.<sup>1</sup> The clinical severity of IFs—which includes some malignancies and vas-

cular lesions—ranges from non-serious to potentially life-threatening. If IFs are overlooked, the opportunity for proper treatment may be missed, and this can cause patients to suffer morbidity.<sup>2</sup> The current study, therefore, aimed to investigate the incidence of potentially serious incidental findings (PSIFs) in patients who were being prepared for plastic surgery and to suggest the ideal management of IFs for plastic surgeons.

We reviewed 1001 consecutive plastic surgery patients who underwent CT and/or MRI, which was interpreted by radiologists at our institution, from April 2017 to March 2020. CT scans were performed using 80-detector CT scanners (Aquilion Prime®; Canon Medical Systems Co., Tochigi, Japan). MRI was performed using a 1.5 Tesla MRI system (Magnetom Avanto®; Siemens Healthineers AG, Erlangen, Germany). We retrospectively reviewed radiology reports of CT scans and MRIs and extracted data on the total number of patients who had IFs as well as all available data on follow-up examinations, treatment, and final diagnoses. To determine which IFs were potentially serious, based on a previous study,<sup>2</sup> we referred to a list of potentially serious and non-serious IFs developed by the UK Biobank's<sup>3</sup> and the German National Cohort's methods.<sup>4</sup> All statistical analyses were performed using JMP Pro 15 software (SAS Institute, Inc., Cary, NC, USA).

IFs were detected in 23.3% (233/1001) patients. The prevalence of IFs was 24.0% (165/687) on CT scan and 21.7% (68/314) on MRI. PSIFs were detected in 3.3% (33/1001) of all patients. The prevalence rates of PSIFs were 3.9% (27/687) and 1.9% (6/314) on CT and MRI, respectively. All IFs are summarized as potentially serious and non-serious in Supplemental Table 1. The proportion of patients with IFs progressively increased with age ( $p < 0.001$ , OR 1.04, 95% CI 1.03-1.04) (Figure 1). A similar pattern was seen for the head region ( $p < 0.001$ ), neck ( $p < 0.001$ ), abdomen ( $p < 0.001$ ), chest ( $p = 0.006$ ), pelvis ( $p = 0.012$ ), and lower extremities ( $p = 0.021$ ), but not for the face ( $p = 0.285$ ) and upper extremities ( $p = 0.189$ ). The mean prevalence of PSIFs was 1.9%, and it gradually increased with age ( $p = 0.003$ , OR 1.02, 95% CI 1.00-1.04) although PSIFs were not detected in subjects under 20 years of age.

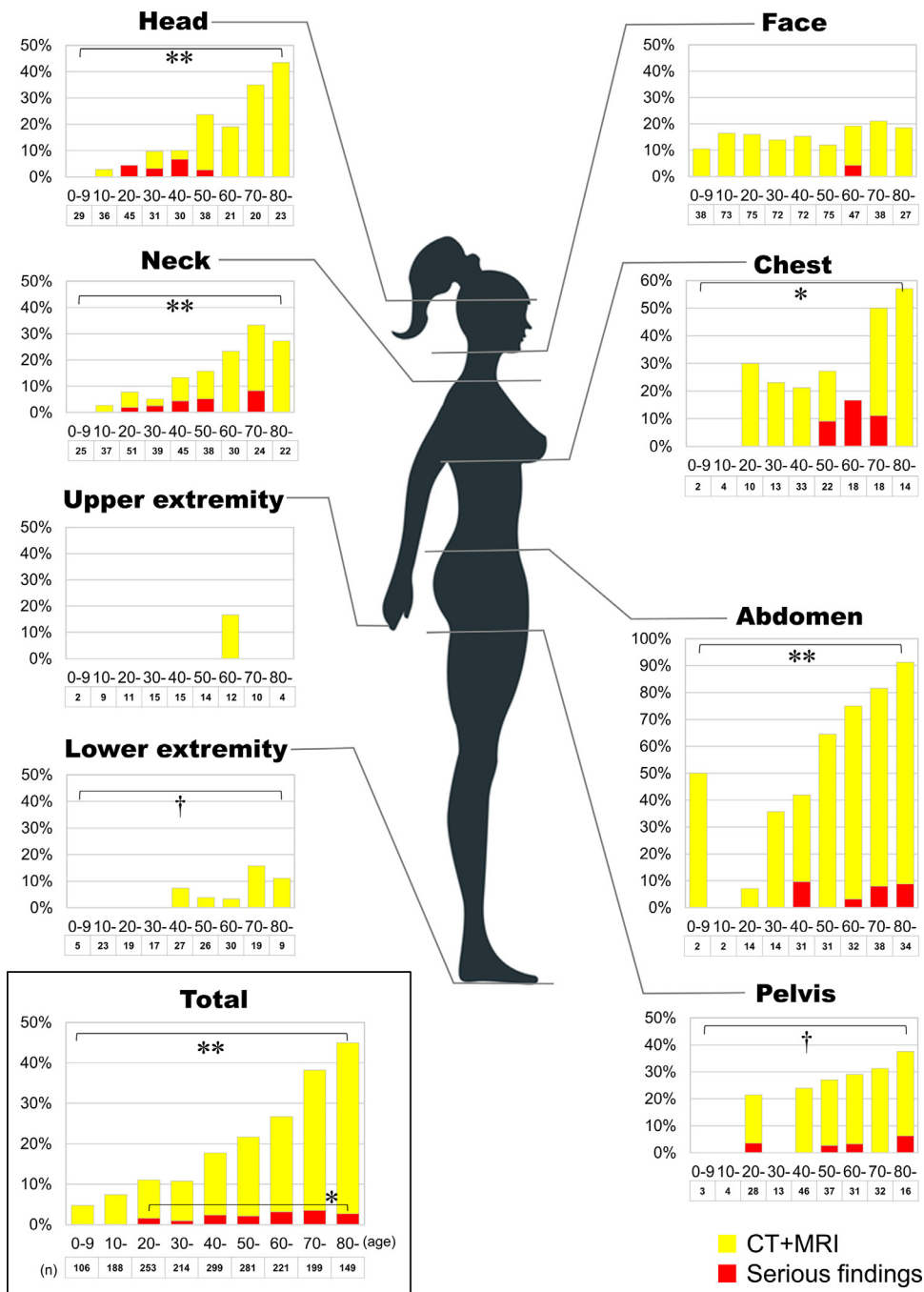
The final diagnoses and management of all PSIFs are summarized in Table 1. Most patients who had PSIFs were informed carefully, and this led to further examinations, including other imaging or pathological tests, except for six cases that adopted a wait-and-see policy based on the specialists' judgment. The majority of patients with PSIF were consequently managed under wait-and-see policies; however, eight patients (0.8%) had clinically serious final diagnoses and underwent further treatment; four required surgical treatment, and four were managed with medication.

Our results demonstrated that the proportion of patients with PSIFs progressively increased with age, and some previous studies have reported similar findings.<sup>3,5</sup> We also found that PSIFs were detected even in young patients, especially in the head and neck regions. In contrast, PSIFs tended to be detected in the chest and abdomen in aged patients. The mean age of patients in the current study was younger than in any previous study, indicating that patients who require plastic surgery are relatively young compared to pa-

**Table 1** Final diagnosis and management for serious incidental findings.

No.	Age	Sex	Exam	Cont.	Region	Serious incidental finding	Main diagnosis	Additional examination	Final incidental diagnosis	Management
1	22	F	CT	E	Head	Intracranial mass lesion	Neurofibroma	eMRI	Optic glioma	wait-and-see
2	22	M	MRI	N	Pelvis	Ascites	Pilonidal sinus	Blood test	Inflammatory ascites	wait-and-see
3	24	M	CT	N	Head	Acute intracranial hemorrhage	Zygomatic fracture	f/u nCT	Subdural hematoma	wait-and-see
4	27	F	MRI	N	Neck	Thyroid lesion with Susp.	Venous malformation	f/u nMRI	Nodular goiter	wait-and-see
5	34	F	CT	E	Neck	Thyroid lesion with Susp.	Arteriovenous malformation	US	Diffuse goiter	wait-and-see
6	37	M	CT	E	Head	Intracranial mass lesion	Squamous cell carcinoma	PET-CT	Ventricular xanthogranuloma	wait-and-see
7	44	F	CT	N	Head	Intracranial mass lesion	Neurofibroma	eCT	Hemimegalencephaly	wait-and-see
8	45	F	CT	E	Abdomen	Gallbladder wall thickening	Breast cancer	f/u eCT	Gallbladder adenomyosis	wait-and-see
9	45	F	CT	E	Abdomen	Gallbladder wall thickening	Neurofibroma	f/u eCT	Gallbladder adenomyosis	wait-and-see
10	48	F	CT	E	Abdomen	Solid renal tumor > 2 cm	Diabetic gangrene	dynamic CT	Renal cell carcinoma	Surgery
11	49	F	CT	N	Neck	Thyroid lesion with Susp.	Funnel chest	FNA	Thyroid cancer	Surgery
12	49	F	MRI	E	Head	Arachnoid cyst-large	Pilonidal sinus	none	Arachnoid cyst	wait-and-see
13	50	M	CT	E	Pelvis	Lymph node > 1 cm	Primary lymphedema	f/u eCT	Lymphadenitis	wait-and-see
14	50	M	MRI	N	Head	Intracranial mass lesion	Venous malformation	nCT	Meningioma	wait-and-see
15	52	F	CT	N	Neck	Thyroid lesion with Susp.	Venous malformation	US	Nodular goiter	wait-and-see
16	54	F	CT	N	Chest	Vascular malformation	Breast foreign body	eCT	Pulmonary arteriovenous fistula	Surgery
17	54	F	MRI	E	Chest	Solid/cystic pancreatic tumor	Lipoma	none	Branch duct type IPMN	wait-and-see
18	57	F	CT	N	Neck	Thyroid lesion with Susp.	Zygomatic fracture	FNA	Thyroid cancer	Surgery
19	61	M	CT	N	Chest	Severe ventricular dysfunction	Lipedema	MIBG	Chronic heart failure	Medication
20	61	M	CT	N	Chest	Pleural effusion	Lipedema	f/u nCT	Pulmonary hypertension	Medication
21	65	F	CT	E	Chest	Severe ventricular dysfunction	Arteriovenous malformation	US	Chronic heart failure	wait-and-see
22	65	M	CT	N	Abdomen	Gallbladder wall thickening	Umbilical hernia	US	Alcoholic cirrhosis	Medication
23	68	M	MRI	N	Face	Carotid-cavernous fistula	Follicular cyst	none	Carotid-cavernous fistula	wait-and-see
24	69	M	CT	N	Face	Parotid gland mass > 2 cm	Zygomatic fracture	eMRI	Pleomorphic adenoma	wait-and-see
25	69	M	CT	E	Pelvis	Major artery stenosis > 80%	Decubitus ulcer	none	Arteriosclerosis obliterans	wait-and-see
26	70	F	CT	E	Neck	Thyroid lesion with Susp.	Squamous cell carcinoma	FNA	Nodular goiter	wait-and-see
27	70	F	CT	N	Neck	Thyroid lesion with Susp.	Lipoma	PET-CT	Diffuse goiter	wait-and-see
28	71	F	CT	N	Abdomen	Solid renal tumor > 2 cm	Lipoma	dynamic CT	Renal cyst	wait-and-see
29	74	F	CT	N	Chest	Pleural effusion	Lymphangioma	f/u nCT	Inflammatory pleural effusions	wait-and-see
30	75	F	CT	N	Abdomen	Gallbladder wall thickening	Arteriosclerosis obliterans	US	Gallbladder adenomyosis	wait-and-see
31	77	F	CT	N	Chest	Pleural effusion	Secondary lymphedema	f/u nCT	Inflammatory pleural effusions	wait-and-see
32	81	M	CT	E	Abdomen	Solid/cystic pancreatic tumor	Abdominal incisional hernia	f/u eCT	Pancreatic cyst	wait-and-see
33	85	F	CT	N	Pelvis	Ovarian teratoma	Decubitus ulcer	none	Mature teratoma	wait-and-see
34	85	F	CT	N	Abdomen	Cholestasis	Decubitus ulcer	none	Postcholecystectomy	wait-and-see
35	87	F	CT	E	Abdomen	Gallbladder wall thickening	Arteriosclerosis obliterans	Blood test	Chronic cholecystitis	medication

M: male, F: female, Cont.: contrast, E: enhanced, N: non-enhanced, Susp.: suspected malignant, f/u: follow-up, eCT: enhanced CT, nCT: non-enhanced CT, eMRI: enhanced MRI, nMRI: non-enhanced MRI, PET: positron emission tomography, FNA: fine-needle aspiration biopsy, US: Ultrasonography, MIBG: metaiodobenzylguanidine scintigraphy, IPMN: intraductal papillary mucinous neoplasia. Number 19/20 and 33/34 were the same patients.



**Figure 1** The proportion of incidental findings by age. The prevalence rates of incidental findings according to nine age groups (0-9, 10-19, 20-29, 30-39, 40-49, 50-59, 60-69, 70-79, and 80-99 years) are shown in total as well as according to eight body regions: head, face, neck, chest, abdomen, pelvis, upper extremities, and lower extremities. Potentially serious incidental findings are indicated in red. The number of patients is expressed below each bar. † $p < 0.05$ , \* $p < 0.01$ , \*\* $p < 0.001$ .

tients who undergo any other specialty surgery. Thus, plastic surgeons should keep in mind that their patients may have PSIFs even if they are young and healthy.

Many PSIFs in this study turned out to be clinically non-serious, but eight of 35 PSIFs required further treatment with surgery or medication. A previous study also showed that only 20% of PSIFs represented serious disease.<sup>3</sup> Thus, the optimal strategy for evaluation of a patient with PSIFs is unclear and remains controversial because the majority

of patients with PSIFs may feel anxious and be urged to undergo uncomfortable or even harmful further investigations. However, patients should understand the risk involved as well as the indications for the operation. Failure to appropriately inform patients with PSIFs is a potential cause of litigation against not only radiologists but also referring clinicians. It is known that plastic surgeons receive more than twice as many malpractice claims as other physicians annually.

There are no guidelines to address the management of PSIFs by clinicians; thus, plastic surgeons may be unsure of which IFs are potentially serious and require urgent further investigation. Our results inform plastic surgeons about the risks of PSIFs on medical imaging before or after surgery and will help them to appropriately manage PSIFs.

## Declaration of Competing Interest

None of the authors have conflicts of interest, including employment, consultancies, stock ownership, honoraria, paid expert testimony, patent applications/registrations, and grants or other funding.

## Acknowledgements

There are no funding that should be declared as an acknowledgement for the role of study sponsors in the study design, in the collection, analysis and interpretation of data, in the writing of the manuscript, and in the decision to submit the manuscript for publication.

## Ethical approval

All study participants provided informed consent, and the study design was approved by the appropriate ethics review board.

## Supplementary materials

Supplementary material associated with this article can be found, in the online version, at doi:[10.1016/j.bjps.2021.03.118](https://doi.org/10.1016/j.bjps.2021.03.118).

## References

1. Weiner C. Anticipate and communicate: ethical management of incidental and secondary findings in the clinical, research, and direct-to-consumer contexts (December 2013 report of the presidential commission for the study of bioethical issues). *Am J Epidemiol* 2014;**180**:562-4.
2. Gibson LM, Paul L, Chappell FM, et al. Potentially serious incidental findings on brain and body magnetic resonance imaging of apparently asymptomatic adults: systematic review and meta-analysis. *BMJ* 2018;**363**:k4577.
3. Gibson LM, Nolan J, Littlejohns TJ, et al. Factors associated with potentially serious incidental findings and with serious final diagnoses on multi-modal imaging in the UK biobank imaging study: a prospective cohort study. *PLoS One* 2019;**14**:e0218267.
4. Bertheau RC, von Stackelberg O, Weckbach S, Kauczor HU, Schlett CL. Management of incidental findings in the German national cohort. In: Weckbach S, editor. *Radiological incidental findings*. Springer; 2017. p. 57-70.
5. Furtado CD, Aguirre DA, Sirlin CB, et al. Whole-body CT screening: spectrum of findings and recommendations in 1192 patients. *Radiology* 2005;**237**:385-94.

Koji Kanayama  
Jun Oba  
Kengo Yoshii  
Yoko Tomioka  
Masakazu Kurita  
Shimpei Miyamoto  
Mutsumi Okazaki

Department of Plastic, Reconstructive and Aesthetic Surgery, the University of Tokyo Hospital, 7-3-1, Hongo, Bunkyo-Ku, Tokyo 113-8655, Japan  
E-mail address: [kanayama-tyk@umin.ac.jp](mailto:kanayama-tyk@umin.ac.jp) (K. Kanayama)

© 2021 British Association of Plastic, Reconstructive and Aesthetic Surgeons. Published by Elsevier Ltd. All rights reserved.

<https://doi.org/10.1016/j.bjps.2021.03.118>

## Perfusion changes in the foot after a free fibula flap



Dear Sir,

Short communication - Letter

The Free Fibula Flap (FFF) is considered the gold standard for osseous reconstruction of the mandible after ablative surgery for head and neck cancer or osteoradionecrosis and has a flap survival-rate of more than 95%. The patient's postoperative hospitalisation is often lengthy and complications are common, which makes interventions for optimisation such as early ambulation key factors for improvement.<sup>1</sup>

Donor-site complications in FFF surgery are relatively common, but the literature scarce regarding effect of the procedure on blood perfusion.<sup>2</sup> The blood supply of the leg may be altered due to comorbidities such as diabetes, atherosclerosis and smoking.

The incidence of foot ischemia has decreased as colour-doppler and CT-Angiograms (CTA) have become routine, but represents a severe complication that may ultimately lead to amputation. CTAs may detect vascular congestion due to atherosclerosis, anomalies and variants of the blood supply of the foot such as hypoplasia or aplasia of the tibial arteries with a resulting reliance on the peroneal artery for blood supply. This is important as a dominant peroneal artery often necessitates and alternative surgical strategy. Colour-doppler and CTA are useful to determine occlusion of arteries but are not sufficient to determine the flow, i.e. the pressure delivered to the peripheral arteries.<sup>3</sup>

Toe pressure may be determined with an easily handled and reliable bedside device. It is considered the method of choice by many for examining the peripheral arterial supply.<sup>3</sup>

We examined the effect of raising a fibula flap on perfusion of the operated leg distal to the flap donor-site, measured by toe pressure and Photoplethysmography (PPG).

**Table 1** Demographic- and procedural data of patients undergoing surgery with a free fibula flap

Characteristics	Total (10)
Sex (%)	
Male	7 (70)
Female	3 (30)
Age, years (range)	55.8 (43-74)
BMI (range)	26.2 (19.9-34.4)
Tobacco use (%)	
Active smokers*	3 (30)
Former smokers	3 (30)
Non-smokers	4 (40)
Comorbidities (%)	
Hypothyroidism	1 (10)
Hypertension	2 (20)
Lichen planus	1 (10)
Ischemic heart disease	1 (10)
Time to ambulation, avg (days)	7.3 (5-13)

\*Defined as patients smoking until <14 days before surgery

We prospectively included 10 consecutive patients who underwent osteocutaneous free fibula flap reconstruction from January 2019 until March 2020. All patients had CT-angiography performed prior to surgery to secure normal vascular anatomy. Furthermore, perforators for the skin-island were identified using doppler ultrasound.

Upon receipt of informed consent we measured toe pressure bilaterally in each patient the day before and 5-7 days after the procedure, before the patients were allowed full mobilisation. Patient demographics and reasons for surgery were recorded (Table 1).

PPG measurements were performed using the SysToe system (ATYS medical, Soucieu en Jarrest, France). A cuff is placed around the proximal phalanx of the first toe and a PPG sensor is placed on the distal pad of the toe. During deflation the PPG sensor detects the resumption of blood flow. Toe pressure was measured in mmHg.

All patients were examined lying down after resting for at least 10 min prior to measurements. The patients' feet were heated using a heating overlay during the resting pe-

riod to secure adequate perfusion and prevent vascular constriction. All measurements were performed twice, and the average pressure calculated.

No patients had peripheral vascular disease or arterial insufficiency. More than 50% of the patients were active- or former smokers.

The average toe pressure on the operated side was 109.8 mmHg before and 104.7 mmHg after surgery ( $p = 0.47$ ) and average pressure on the non-operated side was 106.0 mmHg before and 97.1 mmHg after ( $p = 0.22$ ). An average decrease in toe pressure of 5.1 mmHg (95% confidence interval (CI) [-20.6, 10.4]) on the operated side and 8.9 (95% CI [-15.4, 7.8]) on the non-operated side was observed ( $p = 0.48$ ). The average difference in change between the two sides were 3.8 mmHg (95% CI [-15, 8]). Individual measurements are shown in Table 2.

There was no pattern in the changes of toe pressure on the operated side, as a decrease (1-45 %) was measured in six patients, while an increase was present in four. Only one patient had a difference in toe-pressure change of more than 10% between his operated (3% decrease) and non-operated leg (34% decrease). This suggests that raising a fibula flap and ligating the peroneal vessels does not impact the perfusion of the foot. The observed variations in toe pressure occurred almost identical bilaterally and was most likely related to other factors than surgery.

The literature on the effect of raising a fibula flap on foot perfusion is limited, but Shan et al.<sup>4</sup> evaluated the perfusion of the foot in 47 patients using near-infrared spectroscopy. They found a significant decrease in blood oxygenation of up to 5% in the donor-foot for the first hours after surgery, although the difference disappeared after 8 h post-operatively. Based on these findings, the authors conclude that the blood-supply of the donor-foot was minimally affected by ligation of the peroneal artery.

Complication-rates are generally low after fibula flaps, and severe complications related to rises in intracompartmental pressure are usually sought to be avoided by using a split-thickness skin graft (STSG). Complications may be more frequent than previously anticipated in patient receiving STSG compared to patient undergoing primary donor-site closure.<sup>5</sup> Therefore, the use of an STSG has traditionally hindered of ambulation for up to seven days after surgery in order to promote healing and prevent graft loss.

**Table 2** Toe pressure before and after surgery with a free fibula flap.

Patient	Indication	Procedure laterality	Pre-op pressure		Post-op pressure		Change (%)	
			Operated	Control	Operated	Control	Operated	Control
1	Cancer	Right	130	98	120	92	↓8%	↓6%
2	Trauma	Left	73	78	84	85	↑15%	↑9%
3	Cancer	Right	134	138	131	125	↓2%	↓9%
4	ORN	Left	93	138	90	91	↓3%	↓34%
5	Cancer	Right	83	86	85	88	↑2%	↑2%
6	Cancer	Right	104	98	117	100	↑13%	↑2%
7	Cancer	Right	128	99	65	52	↓45%	↓48%
8	Cancer	Left	97	96	105	109	↑8%	↑14%
9	ORN	Left	168	148	166	153	↓1%	↓3%
10	ORN	Left	88	81	84	76	↓5%	↓6%

Contralateral leg was used as control

Self-adhering pressure bandages prevents the formation of edema under the graft and can allow early ambulation for patients without compromising graft survival.

In our study of 10 patients with a normal 3-vessel runoff from the popliteal artery, a free fibula flap does not decrease the toe-pressure of the donor-leg compared to the non-operated side. This contributes evidence and knowledge to the field support the safety of strategies such as early ambulation, while respecting the fibula donor-site, in order to prevent postoperative complications.

## Funding

None.

## Ethical approval

Not required.

## Financial Disclosures

None.

## Declaration of Competing Interest

None declared.

## References

1. Højvig JH, Kehlet H, Bonde CT. Enhanced recovery after head and neck cancer reconstruction with a free flap-what is next? *J Oral Maxillofac Surg* 2020;**78**(1):10-11.
2. McMahon J, Handley TPB, Bobinskas A, et al. Postoperative complications after head and neck operations that require free tissue transfer - prevalent, morbid, and costly. *Br J Oral Maxillofac Surg* 2017;**55**(8):809-14.
3. Rogers RK, Montero-Baker M, Biswas M, Morrison J, Braun J. Assessment of foot perfusion: overview of modalities, review of evidence, and identification of evidence gaps. *Vasc Med* 2020 1358863X20909433.
4. Shan XF, Ouyang SY, Cai ZG, Zhang J. Evaluation of foot perfusion after fibula flap surgery. *J Craniofac Surg* 2014;**25**(4):1346-7.
5. Ling XF, Peng X. What is the price to pay for a free fibula flap? a systematic review of donor-site morbidity following free fibula flap surgery. *Plast Reconstr Surg* 2012;**129**(3):657-74.

Jens H. Højvig, Lisa Toft Jensen, Mette Stueland Wolters  
*Department of Plastic Surgery and Burns Treatment,  
 Copenhagen University Hospital, Rigshospitalet,  
 Copenhagen Denmark*

Henrik Kehlet  
*Department of Surgical Pathophysiology, Copenhagen  
 University Hospital, Rigshospitalet, Copenhagen, Denmark*

Christian T. Bonde  
*Department of Plastic Surgery and Burns Treatment,  
 Copenhagen University Hospital, Rigshospitalet,  
 Copenhagen Denmark*  
 E-mail address: [jenshoejvig@gmail.com](mailto:jenshoejvig@gmail.com) (J.H. Højvig)

© 2021 British Association of Plastic, Reconstructive and Aesthetic Surgeons. Published by Elsevier Ltd. All rights reserved.

<https://doi.org/10.1016/j.bjps.2021.05.028>

## Determining the real site of peroneal nerve injury with knee dislocation: Early is easier



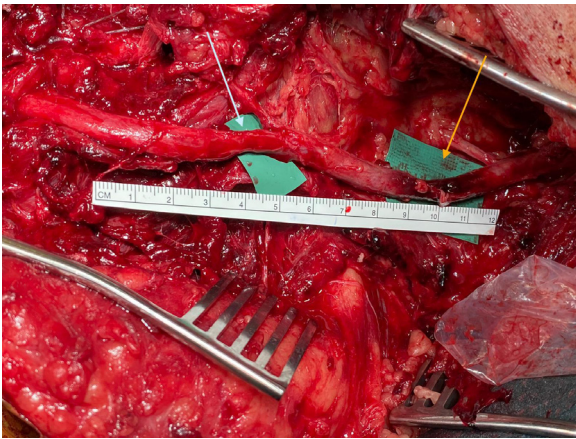
Dear Sir,

Common peroneal nerve (CPN) disruption has a reported incidence between 25% and 40% following traumatic knee dislocation.<sup>1</sup> It appears that there is a direct association between the severity of the ligamentous injury and degree of the CPN palsy.<sup>2</sup> Delayed identification and reconstruction can lead to increased morbidity.<sup>2</sup> Our recent experience highlights the importance of exploring the proximal nerve to ensure the true injury is not missed.

The CPN is a terminal branch of the sciatic nerve, it runs along the upper lateral side of the popliteal fossa, deep to biceps femoris and its tendon. It then courses anteriorly around the neck of the fibula where it divides into superficial and deep peroneal nerves. It is the fixed attachment to the neck of the fibula that makes the CPN particularly vulnerable to injury, with the portion of the nerve proximal to the area susceptible to varus and hyperextension of the knee.<sup>1-3</sup>

The CPN is responsible for providing motor function to the short head of biceps femoris and muscles in the lateral and anterior compartment of the leg. The sensory component innervates the skin of the posterolateral leg, anterolateral leg and dorsum of the foot. Although cutaneous sensation loss does result in morbidity it is the foot drop associated with motor disruption that requires life-long splinting or tendon transfers.<sup>4</sup>

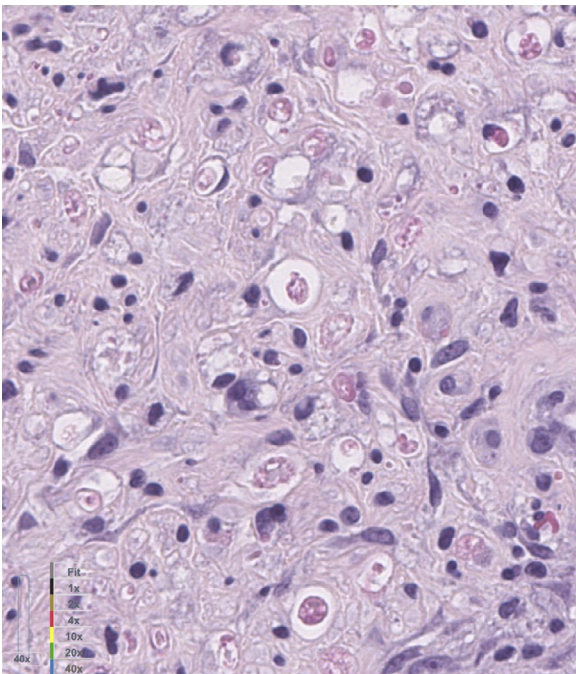
We present a 30 year old off road male cyclist who sustained a hyperextension injury to his left knee. He had foot drop and altered sensation in the distribution of the superficial and deep peroneal nerves. X-ray and CT angiography did not show any bone or vascular injury. An MRI showed complete rupture of the anterior cruciate ligament, all lateral ligaments and posterolateral corner structures, besides distal iliotibial band and biceps femoris avulsion. The femoral attachment of the posterior cruciate ligament was partially torn. The medial collateral ligament, menisci, extensor mechanism and articular surfaces were all intact.



**Figure 1** Intraoperative image showing the area of common peroneal nerve constricted and bruised around the fibular head (White Arrow) and area of common peroneal tortuosity overlying the fibular head with associated significant proximal nerve injury (Yellow Arrow).

The common peroneal nerve was found to thickened and oedematous.

Twelve days following his injury a combined orthopedic and plastic surgery team simultaneously explored the peroneal nerve and ligamentous injury. The nerve was bruised and constricted around the fibula neck (Figure 1). More proximal exploration to the bifurcation of the sciatic nerve revealed severe epineural disruption with fascicular rupture (Figure 1). Wallerian generation was confirmed on the histological assessment (Figure 2). Both the nerve and the knee ligamentous injuries were reconstructed immediately allowing a single multidisciplinary rehabilitation episode.



**Figure 2** H&E stain at 40X magnification showing degenerate axons with myelin ovoids and surrounding reactive vascular proliferation (confirming Wallerian degeneration).

Common teaching in the literature states that CPN injury is found at the point it passes around the fibular head.<sup>2</sup> However, as in this case, there can be a more proximal nerve injury. The extent of common peroneal nerve injury is dependent on the direction and degree of the deforming force.

Exploration should include the branching of the sciatic nerve, a known point of fragility, even if other defects have been identified.<sup>5</sup> Despite being a common complication, literature detailing the neurological prognosis following traumatic knee dislocation is limited.<sup>1,2</sup> Previous attitudes to lower limb nerve repair have been pessimistic due to the complex distribution of nerve fascicles and distance from the spinal cord resulting in end organ atrophy.<sup>3,4</sup> Refinements in surgical technique, however, has led to improved outcomes.

### Declaration of Competing Interest

None.

### Funding

No funding has been obtained for this work.

### Ethical approval

Not required.

### References

1. Niall DM, Nutton RW, Keating JF. Palsy of the common peroneal nerve after traumatic dislocation of the knee. *J Bone Jt Surg - Ser B* 2005;**87**:664-7. doi:10.1302/0301-620X.87B5.15607.
2. Bonneville P, Dubrana F, Galaud B. Common peroneal nerve palsy complicating knee dislocation and bicruciate ligaments tears. *Orthop Traumatol Surg Res* 2010;**96**:64-9. doi:10.1016/j.otsr.2009.12.001.
3. Ferraresi S, Garozzo D, Buffatti P. Common peroneal nerve injuries: results with one-stage nerve repair and tendon transfer. *Neurosurg Rev* 2003;**26**:175-9. doi:10.1007/s10143-002-0247-4.
4. Thorne CH, Chung KC, Gosain AK. *Grabb and Smith's plastic surgery*. Wolters Kluwer Health Adis; 2013. 7th ed.ESP.
5. Tomaino M, Day C, Papageorgiou C. Peroneal nerve palsy following knee dislocation: pathoanatomy and implications for treatment. *Knee Surgery, Sport Traumatol Arthrosc* 2000;**8**:163-5. doi:10.1007/s001670050208.

Benedict A. Hughes  
Joseph Stallard  
Aruna Chakrabarty  
Sanjeev Anand  
Grainne Bourke

*Plastic Surgery, Leeds Teaching Hospitals NHS Trust, Great George Street, Leeds, West Yorkshire LS1 3EX, United Kingdom*

*E-mail address: Benedict.hughes@nhs.net (B.A. Hughes)*

© 2021 British Association of Plastic, Reconstructive and Aesthetic Surgeons. Published by Elsevier Ltd. All rights reserved.

<https://doi.org/10.1016/j.bjps.2021.05.063>

## The mini incision approach to the facial artery as a recipient vessel in head and neck reconstruction



Dear Sir,

The facial artery can be reached without the need for an extra incision in trauma and oncological surgeries in the microsurgical intervention of lower face and neck. Keeping the incision size minimal precludes the new scar under the mandible from preventing the success of the performed main surgical intervention in post-operative follow-ups. This letter presents technical details of a mini incision approach to the facial artery as a recipient vessel in head and neck reconstruction.

The facial artery was detected 1 cm below the middle mandibular corpus with the aid of a hand doppler and the exact localization of the mini incision was specified (Figure 1). Superficial neck fascia and platysma were dissected and the facial artery was exposed via the mini skin incision. Both skin edges were suspended with suspension sutures to provide optimal vision. The exposed facial artery was marked with vascular tape. Connections to tissues surrounding the facial artery were dissected distally (Figure 1). The facial artery was ligated with micro clips as distally as possible after a sufficient range of motion to the vessel was provided. The facial artery was released towards the distal end and taken out from the existing incision. The same procedure was performed to prepare the facial vein.

To enable the free flap pedicle to reach the anastomosis site, a subcutaneous tunnel was created from the defect area to the recipient area with blunt dissection. Using the silicone drain as a guide, the free flap pedicle was passed to the anastomosis site without traumatization (Figure 1). While the recipient vessels were more superficial, arterial and venous anastomosis were performed approximately at or above the skin level after preparation of the anastomosis area (Figure 1, 2). After all anastomoses were carried out, the entire pedicle was pulled towards the distal end to return the anastomosed vessels to their anatomic planes without kinking (Figure 1).

This technic was performed 13 male and 5 female patients. The mean age of patients was 32 (8-82). The mean follow-up time was 18 months. The mean preparation time of the recipient area was calculated as 30 min. The patients' mean scar length measured 17 mm (13-22 mm),

and the mean Modified Vancouver Scar Scale score was 1.33 (0-4).<sup>1</sup>

It is believed that using microscope magnification during the recipient area dissection is safe and advantageous since it does not traumatize the facial artery and provides sufficient mobilization to perform the anastomosis at the skin level. There are many advantages to performing anastomosis at the skin level. The most important advantage is bringing vessels that are in a hole out to the surface. In doing so, we avoid working in a blood hole.

Perhaps the biggest problem here is the need to create a new scar on the face or the submandibular region. It is essential for the chosen flap for mid-face reconstruction to have adequate pedicle length. Furthermore, with the technique described in this study, the required pedicle length would be shortened owing to ligation of the facial artery as distally as possible.

In the technic we described, operating in a bloodless clean area at the skin level can shorten the operation time and facilitate performing anastomosis. The additional incision to be made should be limited. It should be placed in an area that can be hidden so as not to cause a new morbidity in the face area of patients who are operated on under elective conditions and who have esthetic concerns. Wider incisions can overshadow the success of the primary operation on patients with high esthetic expectations. When the size of the mini incision length is compared with the literature on exposing facial vessels, it is thought that microsurgical anastomosis can be performed by creating a smaller surgical area.<sup>2,3</sup> To avoid facial scarring and to shorten the required pedicle length, intraoral anastomosis can also be performed. However, it can extend the operation time, and performing the intraoral anastomosis technique is harder than performing the mini incision technique.<sup>4</sup>

With the technique described in this study, the pedicle length required was shortened, the scar was smaller in an area that could be hidden below the mandible, and a well-qualified, barely visible scar can be obtained in late post-operative periods.

### Ethical approval

This study doesn't involve human or animal subject. Ethical approval was not required.

### Disclosure

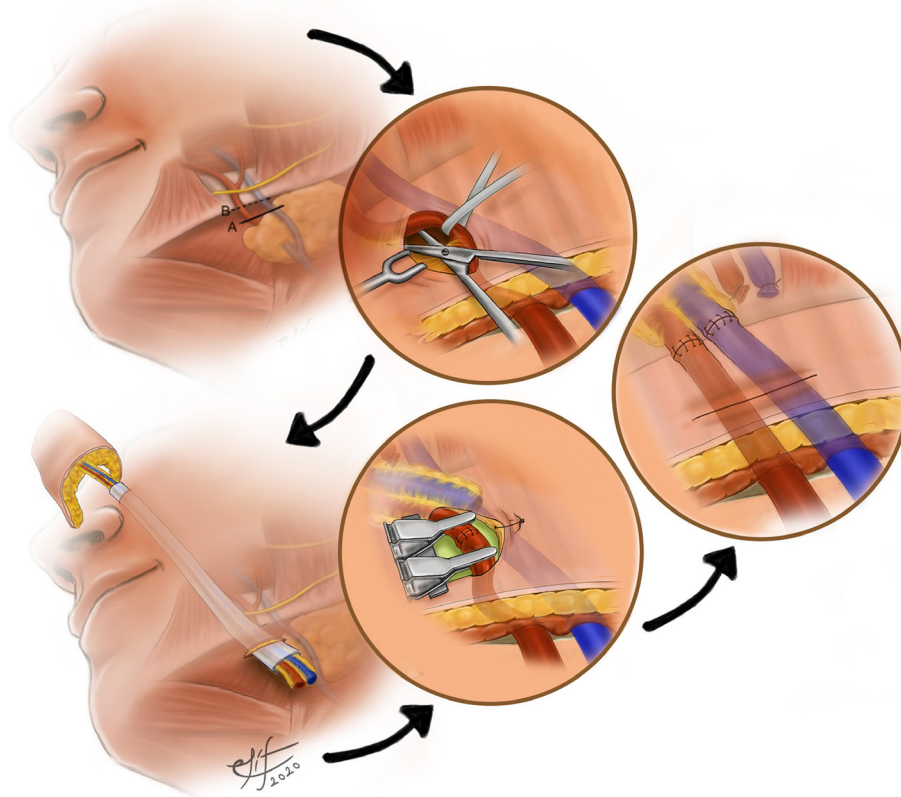
The authors state that they have no conflicts of interest to disclose and no funding was received to assist in the creation of this manuscript.

### Supplementary materials

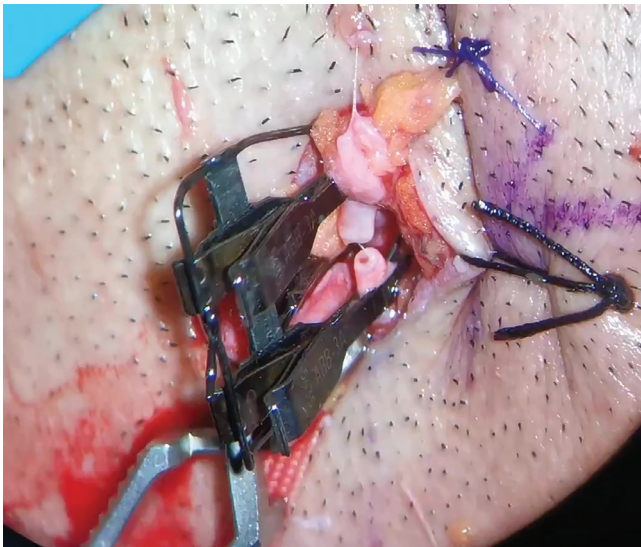
Supplementary material associated with this article can be found, in the online version, at doi:[10.1016/j.bjps.2021.03.072](https://doi.org/10.1016/j.bjps.2021.03.072).

**Presentation:** This study will be presented in 9th National Congress of the Turkish Society for Reconstructive Microsurgery and 2nd National Congress of the Emergency Hand Care and Microsurgery Society which was suspended due to the risks associated with the Novel Coronavirus (COVID-19)





**Figure 1** An illustration of the surgical technique. Mini skin incision were carried out on straight line and vessels were ligated on dotted line. The facial vessel were gently dissected towards distal by using blunt tissue scissors. For the free flap pedicle to reach the anastomosis site, a subcutaneous tunnel was created from the defect area to the recipient area with blunt dissection and using the silicone drain as a guide, the free flap pedicle was passed to the anastomosis site. While the recipient vessels were more superficial than its level, anastomoses were performed approximately at the skin level or above the skin level. After all anastomoses were carried out, the entire pedicle was pulled towards to the distal to return anastomosed vessels to their anatomic planes without kinking.



**Figure 2** Facial vessels were extracted out in their anatomic plane and preparation of the facial vessels for anastomosis was completed at the skin level.

## References

1. Sullivan T, Smith J, Kermode J, McIver E, Courtemanche DJ. Rating the burn scar. *J Burn Care Rehabil* 1990;11:256-60.
2. Chia H-L, Wong C-H, Tan B-K, Tan K-C, Ong Y-S. An algorithm for recipient vessel selection in microsurgical head and neck reconstruction. *J Reconstr Microsurg* 2011;27:47-56.
3. Revenaugh PC, Fritz MA, Haffey TM, Seth R, Markey J, Knott PD. Minimizing morbidity in microvascular surgery: small-caliber anastomotic vessels and minimal access approaches. *JAMA Facial Plast Surg* 2015;17:44-8.
4. Zheng L, Lv X, Shi Y, Zhang J, Zhang J. Intraoral anastomosis of a vascularized iliac-crest flap in maxillofacial reconstruction. *J Plastic, Reconstruct Aesthetic Surg* 2019;72:744-50.

Erden Erkut ERKOL  
Osman AKDAG  
Mustafa SUTCU

Department of Plastic, Reconstructive, and Aesthetic  
Surgery, Selcuk University Faculty of Medicine, Konya,  
Turkey

E-mail address: oakdag@gmail.com (O. AKDAG)

© 2021 British Association of Plastic, Reconstructive and Aesthetic Surgeons. Published by Elsevier Ltd. All rights reserved.

<https://doi.org/10.1016/j.bjps.2021.03.072>

## Towards an orthoplastic dynamic soft tissue classification for closed ankle pilon fractures



Dear Sir,

When sufficient energy is imparted on bone to cause fracture, that energy also causes soft tissue injury. The “orthoplastic” management of open fractures is well established, however, its role in closed fractures is nascent. An orthoplastic approach to closed ankle pilon fracture (APF) is of particular value. APFs are high-energy intra-articular distal tibial plafond fractures, usually associated with comminution and soft tissue disruption. To achieve anatomical reduction, an open reduction and internal fixation (ORIF) is usually required. However, dissecting the soft tissue for ORIF, in already traumatized tissues, creates additional surgical trauma which can lead to poor outcomes with high rates of wound complications. Watson et al. demonstrated that the degree of initial soft tissue injury in APF is a predictor of poorer patient outcomes regardless of the degree of skeletal injury.[1] To mitigate this issue, strategies such as delayed or staged ORIF, or definitive treatment with circular or spanning external fixation alone have been popularized to allow soft tissue resuscitation with improved outcomes. As such, key dynamic orthoplastic decisions as to “how” and “when” to treat APF are mediated not only by the state of the bone, but also by the soft tissue envelope.

Despite the major role of the soft tissue envelope in determining APF management, there is no objective soft tissue classification for APF and currently decisions are made subjectively by expert clinicians. Sirkin et al., popularized a protocol of staged management for APF and advocated waiting for “soft tissue swelling to disappear” and stabilization prior to definitive fixation.[2] Furthermore, a randomized control trial investigating clinical and cost-effectiveness management options for APF, the ACTIVE trial, does not address the role of the soft tissue component of the injury.[3] The two classifications of APF, Ruedi and Allgower and the AO classification, only take into account the radiological bony configuration. (Table 1) [4] Generic classifications of the soft tissue envelope in closed fractures exist, such as the Tschernke and Oesterle and AO classification.[5] (Table 1) However, none of these classifications have significant value in predicting overall patient outcomes.<sup>6</sup> Given the impact of the soft tissue envelope on APF management and outcomes, a dynamic classification of bone and soft tissue injury is needed to guide orthoplastic decisions as to “when” and “how” to perform fracture fixation.

From our major trauma centers’ experience with high volumes of pilon fractures and the current available literature, features in the classification likely to be most valuable in guiding optimal management include patient factors, in-

jury factors, bony fragment pattern and specific soft tissue signs (Figure 1). We recommend that these features be routinely evaluated within an orthoplastics multidisciplinary meeting, initially at 48 h and when staged, weekly, until the inflammatory peak is reached.

We hypothesize that this orthoplastics approach to a “closed” fracture, would potentially decrease the APF inpatient course and improve outcomes. In our major trauma center, APFs with minimal soft tissue disruption, if indicated, safely undergo ORIF with minimal delay. The orthoplastic assessment, aids identification of such cases. (Figure 1) Fractures with significant soft tissue trauma, identified with signs in Table 2, can initially be managed with spanning external fixation and/or delayed ORIF. In APFs that manifest signs of healing, a combined orthoplastic approach can identify safe corridors for ORIF. This assessment of soft tissue injury signs and understanding of expected healing, permits informed decisions of “if” and “how” bone fixation can be performed to be taken earlier compared with empirical delayed approach.

In APFs that do not manifest signs of healing, tissue loss is likely, particularly if further surgical trauma is applied. The orthoplastic classification can provide objective evidence to avoid further surgical trauma and for the fracture to be managed with external fixation alone, an increasingly recognized treatment option.[3] The more accurate selection of these patients may avoid catastrophic post-operative complications such as deep infection and exposed metalwork. Some cases may have significant soft tissue injury, in which safe access cannot be established but the fracture configuration is such that adequate access would allow for good reduction and fixation. The ideal approach for these injuries remains a source of debate. The emergence of an orthoplastic approach with the benefits of the “fix and flap” algorithm may reduce the inpatient course, reduce the risk of deep infection and improve overall outcomes, as has been extensively documented in open fractures, but is yet to become common practice in closed fractures.

The introduction of a dynamic orthoplastic classification for closed complex fractures can improve clinical outcomes. We propose implementation of a soft tissue assessment along with the radiographic features of APF in a prospective trial with standardized serial photographic documentation of the soft tissue envelope. In our major trauma center soft tissue serial photographs are presented alongside the routine radiographs during the daily multidisciplinary trauma meeting allowing for a more holistic orthoplastic evaluation. We encourage the utilization of this simple adjustment and look forward to reporting on number of surgeries, timing and type of definitive fixation, length of hospital stays, infection rates, revision surgeries and patient reported outcomes.

### Funding

N/A

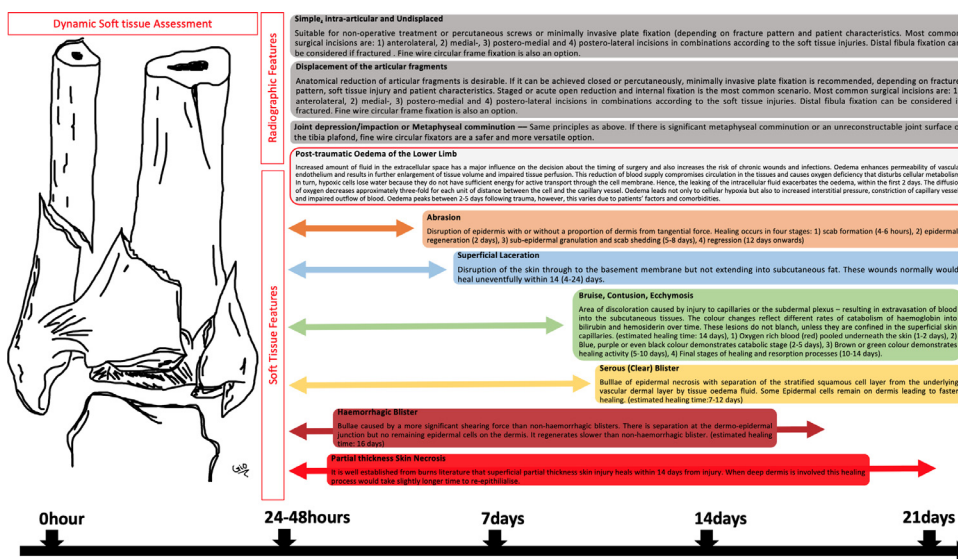
### Declaration of Competing Interest

N/A

**Table 1** Classifications applied to the management of Closed Ankle Pilon Fractures (APF).

Ruedi and Allgower	AO/ OTA* (43)	Tscherne	AO (IC*)
Radiographic only	Radiographic only- Distal tibia classification including non pilon fractures	Combined - Radiographic and clinical soft tissue (non-specific to APF)	Clinical soft tissue only (non-specific to APF)
		<b>Radiographic</b>	<b>Soft tissue</b>
<b>Type 1</b> Non displaced intra-articular fracture	<b>Type A (Extra articular distal tibia fracture - non pilon)</b> 1 Simple 2 Wedge 3 Multifragmentary	<b>Grade 0</b>	Simple fracture No or minor soft tissue damage <b>IC-1</b> No evidence of skin lesion
<b>Type 2</b> Displaced without comminution	<b>Type B (Partial articular)</b> 1 Split 2 Split and depressed 3 Depressed	<b>Grade 1</b>	Medium severity fracture pattern Superficial abrasion or skin contusion <b>IC-2</b> No skin laceration but contusion
<b>Type 3</b> Displaced with comminution	<b>Type C (Complete articular)</b> 1 Simple 2 Simple articular, multifragmentary metaphyseal 3 Multifragmentary	<b>Grade 2</b>	Severe fracture pattern Deep (contaminated abrasion with skin or muscle contusion) <b>IC-3</b> Circumscribed degloving
		<b>Grade 3</b>	Complex fracture pattern Extensive skin contusion, crush injury with damage to underlying muscle Compartment syndrome, Morel- Lavallee lesion +/- vascular injury <b>IC-4</b> Extensive closed degloving  <b>IC-5</b> Necrosis from Contusion

\* AO= Arbeitsgemeinschaft für Osteosynthesefragen; OTA= Orthopaedic Trauma Association IC= Integument Closed.



**Fig. 1** Factors to dynamically evaluate during bone and soft tissue assessment of ankle pilon fractures.

## Supplementary materials

Supplementary material associated with this article can be found, in the online version, at [doi:10.1016/j.bjps.2021.05.047](https://doi.org/10.1016/j.bjps.2021.05.047).

## References

1. Watson JT, Moed B, Karges D, Cramer K. Pilon fractures. *Clin Orthop Relat Res* 2000(375):78-90.
2. Sirkin M, Sanders R, DiPasquale T, Herscovici D. A staged protocol for the soft tissue management in the treatment of complex pilon fractures. *J Orthop Trauma* 1999;13(2):S32-8.
3. Sharma H.K. Protocol for the ACTIVE (articular pilon fracture) trial [Internet]. 2018. Available from: <http://library1.nida.ac.th/termpaper6/sd/2554/19755.pdf>
4. Rüedi T. Fractures of the lower end of the tibia into the ankle joint: results 9 years after open reduction and internal fixation. *Injury* 1973;5(2):130-4.
5. Oestern H-J, Tschernke H. Pathophysiology and classification of soft tissue injuries associated with fractures. *Fract with Soft Tissue Inj* 1984(3):1-9.

Isabelle Citron, Parviz Sadigh

Department of Plastic and Reconstructive Surgery,  
Emergency Care and Trauma Division, The Royal London  
Hospital, Barts Health NHS Trust & The Blizard Institute,  
Barts and The London School of Medicine and Dentistry,  
Queen Mary University of London, 4 Newark Street,  
London E12AT, United Kingdom

Alexios-Dimitrios Iliadis

Limb Reconstruction and Bone Infection Service,  
Department of Trauma and Orthopaedics, Emergency Care  
and Trauma Division, The Royal London Hospital, Barts  
Health NHS Trust, London, United Kingdom

Nicola Bystrzonowski

Department of Plastic and Reconstructive Surgery,  
Emergency Care and Trauma Division, The Royal London  
Hospital, Barts Health NHS Trust & The Blizard Institute,  
Barts and The London School of Medicine and Dentistry,  
Queen Mary University of London, 4 Newark Street,  
London E12AT, United Kingdom

William Wynell-Mayow, Nima Heidari, Alexandros Vris

Limb Reconstruction and Bone Infection Service,  
Department of Trauma and Orthopaedics, Emergency Care  
and Trauma Division, The Royal London Hospital, Barts  
Health NHS Trust, London, United Kingdom

Georgios Pafitanis\*

Department of Plastic and Reconstructive Surgery,  
Emergency Care and Trauma Division, The Royal London  
Hospital, Barts Health NHS Trust & The Blizard Institute,  
Barts and The London School of Medicine and Dentistry,  
Queen Mary University of London, 4 Newark Street,  
London E12AT, United Kingdom

\*Corresponding author.

E-mail addresses: [g.pafitanis@qmul.ac.uk](mailto:g.pafitanis@qmul.ac.uk),  
[georgios.pafitanis@nhs.net](mailto:georgios.pafitanis@nhs.net) (G. Pafitanis)

© 2021 British Association of Plastic, Reconstructive and Aesthetic Surgeons. Published by Elsevier Ltd. All rights reserved.

<https://doi.org/10.1016/j.bjps.2021.05.047>

## Changes in the size of the Distal Phalanx included in wrap-around flap and in the flap circumference for finger and thumb reconstruction

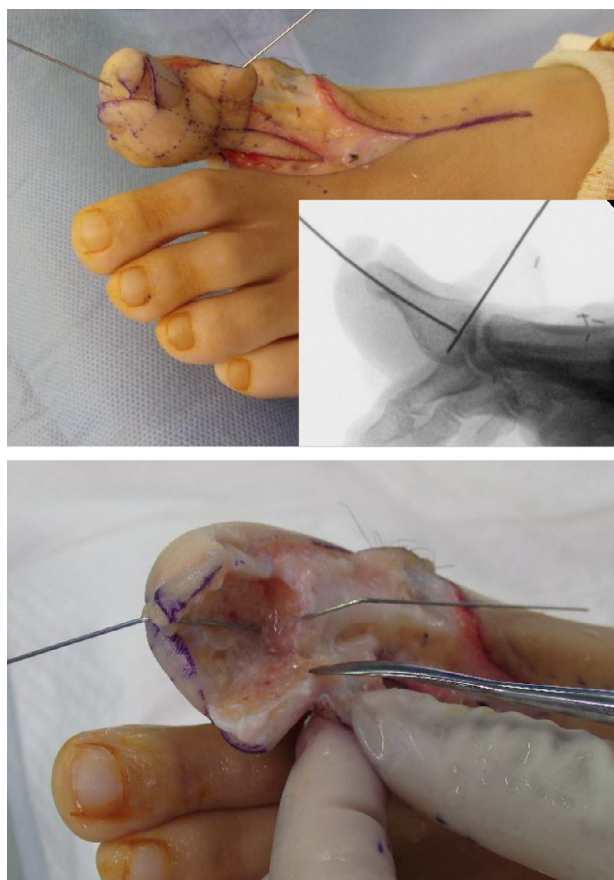


Dear Sir,

Wrap-Around Flap (WAF) method, in which tissue is partially harvested from the great toe, is successfully used for thumb reconstruction.<sup>1</sup> Recent reports included not only the periosteum of the distal phalanx but also a split-thickness subungual bone tissue to prevent deformity of the reconstructed thumb nail.<sup>2</sup> The size change of the graft, including the bone, is an important factor to determine final reconstructed digit morphology. Doi et al.<sup>2</sup> reported a preferable design based on resorption of the iliac bone graft and final appearance of the reconstructed thumb; however, they did not address reconstructions of other fingers, and the entire nail including the partial dorsal distal phalanx was harvested. Reconstructing fingers other than the thumb using WAF requires more partial harvesting of the nail and distal phalanx from the great toe. Flap devoid of hard tissue shrinks with time,<sup>3</sup> but we expect that WAF containing vascularized bone tissue would maintain more of its original volume. Some reports measured bone resorption in non-vascularized iliac bone grafts in WAF,<sup>4</sup> but none have focused on the size changes of the distal phalanx included in the WAF. The distal phalanx size change directly affects the morphology of the reconstructed nail.<sup>5</sup> To determine the preferable WAF design for finger and thumb reconstructions, we investigated size changes in distal phalanx used in WAF and flap circumference.

We retrospectively reviewed WAF surgeries performed by the same surgeon at our institution (February 2014-October 2018). Inclusion criterion was follow-up radiography for  $\geq 1$  year. Exclusion criteria encompassed fractures or surgeries of the first metacarpal bone (for thumb reconstruction) and/or proximal phalanx (for finger reconstruction), and unknown skin and flap circumference at the time of design and 6 months postoperatively.

We preserved the interphalangeal joint while harvesting the distal phalanx included in the WAF, as suggested previously.<sup>2</sup> The width of nail and distal phalanx was de-



**Figure 1** Harvesting of partial nail with the dorsal distal phalangeal bone with preservation of the interphalangeal joint in a 36-year-old man who underwent a right middle finger reconstruction. A guide wire was inserted, and a bone saw was used along the wire.

terminated with reference to the healthy contralateral nail. If distal phalanx could not achieve sufficient length, we added an iliac bone graft. After harvesting by bone saw and chisel (Figure 1), the distal phalanx was fixed with two or three 1.0- or 0.7 mm K-wires.

To determine size changes of the distal phalanx included in the WAF, radiographic measurements were performed immediately postoperatively, at 6 and 12 months, and at the last follow-up using the PACS measurement tool (Synapse, Fujifilm Medical Co., Tokyo, Japan). Measurements by three different examiners were averaged for analysis. The measurements of length, thickness, and width of the distal phalanx included in the WAF were standardized to internal control values (first metacarpal and proximal phalanx, in thumb and finger reconstruction, respectively), yielding relative length (RL), thickness (RT), and width (RW). Resorption Amount (RA) for each of these parameters was calculated as the relative change at the follow-up period divided by the postoperative value ( $\times 100\%$ ). Flap circumferences were measured at the eponychium and distal interphalangeal crease at the time the flap was designed and at 6 months postoperatively (Online Supplementary Figures 1-6).

All included flaps survived and there were no re-explorations. Measurements on radiography were available for 20 patients ( $41.0 \pm 12.9$  years; 1 woman/19 men;

5 thumb/15 finger reconstructions). Flap circumferences were measured in 11 patients (age  $42.3 \pm 6.72$  years; 1 woman/10 men; 2 thumb/9 finger reconstructions). We observed resorption of vascularized bone of the nail portion in the WAF, more in width than in length and thickness.

Namely, at the last follow-up (12-44 months [mean 21.1]), there were significant reductions in length, thickness, and width on distal phalanx radiography (6.7%, 1.3 mm,  $t$ -test  $p < 0.001$ ; 9.1%, 0.4 mm,  $p = 0.021$ ; and 14.9%, 1.2 mm,  $p < 0.001$ , respectively; Figure 2).

The flap circumference did not shrink much after 6 months at the eponychium level ( $\geq 1$  mm in ten cases, maximum 4 mm). At the distal interphalangeal crease level, shrinkage was  $\leq 2$  mm in eight patients (finger reconstructions, two with iliac bone grafts) and  $\geq 10$  mm in two patients (thumb reconstructions using the iliac bone graft).

Based on our results, to achieve similarity with the healthy contralateral digit, we recommended to design the nail approximately 1.2 mm wider than the healthy digit, and to design the pulp portion of the digit with the same size as the healthy contralateral digit. Designing a larger skin flap at the interphalangeal crease level in anticipation of flap shrinkage is not necessary when an iliac bone graft is not required. However, not only the WAF design but also the subcutaneous tissue volume and bone morphology are important factors for reconstructing a digit similar to the healthy contralateral digit. The method of harvesting depends on each facility and surgeon. Therefore, these results may not be directly generalized to all WAFs. Further follow-up and larger studies are required to validate our findings and examine individual effects of various factors on the outcomes.

## Declaration of Competing Interest

None.

## Acknowledgments

The authors would like to thank Enago ([www.enago.jp](http://www.enago.jp)) for the English language review.

## Funding

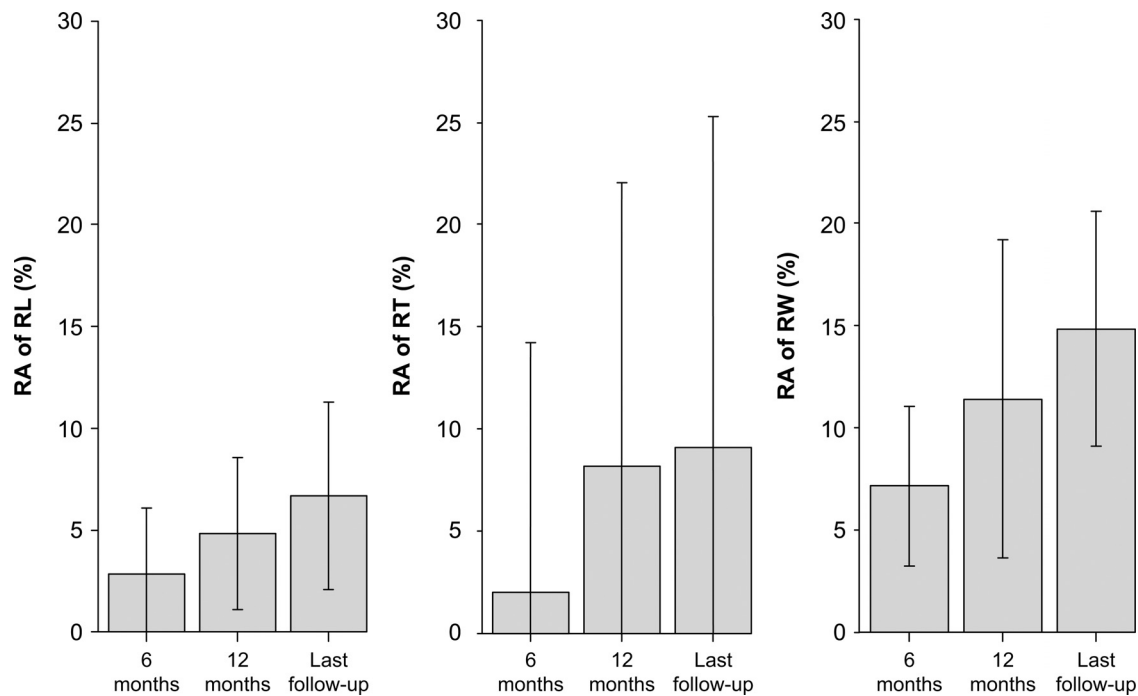
No financial support received.

## Ethical approval

This study was approved by the institutional review board, and each patient provided informed consent for using the data in this study.

## Supplementary materials

Supplementary material associated with this article can be found, in the online version, at doi:[10.1016/j.bjps.2021.05.054](https://doi.org/10.1016/j.bjps.2021.05.054).



**Figure 2** Bone Resorption Amount (RA) of the distal phalanx included in the wrap-around flap presented as the resorption values of the Relative Length (RL), Thickness (RT), and width (RW; mean  $\pm$  standard deviation).

## References

- Morrison WA, O'Brien BM, MacLeod AM. Thumb reconstruction with a free neurovascular wrap-around flap from the big toe. *J Hand Surg Am* 1980;5:575-83.
- Doi K, Hattori Y, Dhawan V. The wrap-around flap in thumb reconstruction. *Tech Hand Up Extrem Surg* 2002;6:124-32.
- Sakamoto Y, Yanamoto S, Ota Y, et al. Magnitude of myocutaneous flaps and factors associated with loss of volume in oral cancer reconstructive surgery. *J Oral Maxillofac Surg* 2016;74:644-9.
- Yang K, Zhao Z, Pan Y, et al. Resorption of iliac bone grafts following wrap-around flap for thumb reconstruction: a follow-up study. *J Hand Surg Am* 2020;45:64.e1-64.e8.
- Parrinello JF, Japour CJ, Dykyj D. Incurvated nail. does the phalanx determine nail plate shape? *J Am Podiatr Med Assoc* 1995;85:696-8.

Takeo Matsusue, Ikuma Yoshimi, Koji Kimura  
 Department of Plastic Reconstructive Surgery, Kansai  
 Electric Power Hospital, 2-1-7 Fukushima, Fukushima-ku,  
 Osaka, 553-0003, Japan

E-mail address: [matsusue.takeo@c5.kepcoco.jp](mailto:matsusue.takeo@c5.kepcoco.jp) (T. Matsusue)

© 2021 British Association of Plastic, Reconstructive and Aesthetic Surgeons. Published by Elsevier Ltd. All rights reserved.

<https://doi.org/10.1016/j.bjps.2021.05.054>

## Lymphography change after liposuction: Possible neo-lymphangiogenesis by surgical trauma



Dear Sir,

I read with the great interest the article entitled "Liposuction-assisted brachioplasty in breast cancer-related lymphedema: Impact on volume reduction and quality of life" by Chollet, et al. (*J Plast Reconstr Aesthet Surg*. 2020 Dec 14. Epub ahead of print).<sup>1</sup> We completely agree with the authors' opinion that liposuction efficiently reduce lymphedematous limb volume. It is quite natural and easy to understand that volume is decreased after direct removal of fat tissue. There is another possibility of liposuction for lymphedema management; the concept comes from a case showing neolymphangiogenesis after liposuction.

A 53 year old female with secondary lower extremity lymphedema was followed with indocyanine green (ICG) lymphography every year. ICG lymphography was performed as previously reported; 0.2 ml of 0.25% ICG was injected at the second web space of the foot, and lymphographic images were obtained using a near-infrared camera 2 h after ICG injection.<sup>2-5</sup> The patient underwent abdominal and

thigh liposuction for the esthetic purpose without any post-operative complication in another clinic. Before the liposuction, there was no dermal backflow seen in the abdomen on ICG lymphography. Nine months after the liposuction, ICG lymphography showed dermal backflow in some part of the lower abdomen where liposuction was performed.

It is well known that liposuction surgically remove the fat tissue, and the lymph vessels can be injured during liposuction as they exist in the fat tissue. The case revealed 2 important points. One is that liposuction has injured the lymph vessels. The other is that liposuction has created new lymphatic pathways; liposuction seemed to develop new pathways by traumatic injury via neolymphangiogenesis. The case has shed light on possibility of new lymphatic pathway creation via neolymphangiogenesis by a simple surgical intervention such as liposuction. Currently, lymph node transfer, various growth factors, and gene therapy are attempted to promote neolymphangiogenesis to improve lymph circulation. However, they have significant disadvantages; lymph node transfer is invasive with donor site lymphedema risk, and growth factor and gene therapy requires high cost. If confirmed to be effective for lymph circulation improvement via neolymphangiogenesis, liposuction allows simultaneous volume reduction and lymph flow improvement; to improve lymph circulation, liposuction should be performed beyond the border of dermal backflow to create new lymphatic pathways. Further studies are warranted to confirm efficiency of new lymphatic pathways creation by liposuction.

### Funding

None.

### Prior presentations

None.

### Ethical approval

N/A.

### Declaration of Competing Interest

None

### References

1. Chollet C, Malloizel-Delaunay J, Cabarro B, et al. Liposuction-assisted brachioplasty in breast cancer-related lymphedema: impact on volume reduction and quality of life. *J Plast Reconstr Aesthet Surg* 2020 Dec 14. Epub ahead of print.
2. Yamamoto T, Yamamoto N, Yoshimatsu H, et al. Factors associated with lower extremity dysmorphia caused by lower extremity lymphedema. *Eur J Vasc Endovasc Surg* 2017;54(1):126 Jul.
3. Yamamoto T. Onco-reconstructive supermicrosurgery. *Eur J Surg Oncol* 2019;45(7):1146-51 Jul.
4. Yamamoto T, Yamamoto N, Fuse Y, et al. Optimal sites for supermicrosurgical lymphaticovenular anastomosis: an analysis of lymphatic vessel detection rates on 840 surgical fields in lower extremity lymphedema. *Plast Reconstr Surg* Dec 2018;142(6) 924e-930e.
5. Yamamoto T, Narushima M, Koshima I. Lymphatic vessel diameter in female pelvic cancer-related lower extremity lymphedematous limbs. *J Surg Oncol* 2018;117(6):1157-63 May.

Nana Yamamoto

Department of Plastic and Reconstructive Surgery,  
National Center for Global Health and Medicine, 1-21-1  
Toyama, Shinjuku-ku, Tokyo 162-8655, Japan

Department of Plastic Surgery, Tokyo Metropolitan  
Bokutoh Hospital, Tokyo, Japan

E-mail address: [tayamamoto@hosp.ncgm.go.jp](mailto:tayamamoto@hosp.ncgm.go.jp) (N. Yamamoto)

© 2021 British Association of Plastic, Reconstructive and Aesthetic Surgeons. Published by Elsevier Ltd. All rights reserved.

<https://doi.org/10.1016/j.bjps.2021.05.006>

## RE: Perineal reconstruction following abdominoperineal resection: Comprehensive review of the literature ALT versus VRAM for perineal reconstruction after abdominoperineal resection - still a debate or a no-brainer?



Dear Sir,

We read with interest the article published in the November issue of JPRAS, "Perineal reconstruction following abdominoperineal resection: Comprehensive review of the literature".<sup>1</sup> We would like to congratulate Dr. Copeland-Halperin and her co-authors for the overview of current literature describing perineal reconstruction after abdominoperineal amputation. We particularly appreciated the efforts the authors deployed to present a review of a complicated topic with no international consensus on defect measurement, operative management, complication definition and lacking a clear treatment algorithm.

The central question assessed by this paper, i.e. which reconstructive option is best for perineal reconstruction after APR, is neatly developed by analyzing available techniques (e.g. VRAM vertical rectus abdominis muscle flaps, gracilis, etc...) and comparing thigh and abdominal flaps. This avoids comparing flaps to primary closure, where evidence shows that the latter leads to significantly worse

outcomes.<sup>2</sup> By reviewing the current state of literature, the authors acknowledge that the vast majority of papers describes experience of abdominal flaps (mainly pedicled VRAMs) for APR reconstructions. However, as described in the paper, no statistically significant difference was present in reported complications of the different reconstructive procedures, namely abdominal, perineal or thigh flaps, while abdominal morbidity after VRAM raise is well known.

We would however like to present additional data that would significantly increase the author's caseload, especially given the limited sample of anterolateral thigh (ALT) flaps considered in the published review (10 cases out of a single paper, compared to 157 VRAM flaps, as stated in Tables 1 and 5). In 2015 we published a series of perineal reconstructions using the combined pedicled anterolateral thigh and vastus lateralis flap.<sup>3</sup> In that case series, 25 combined ALT-vastus lateralis flaps (ALT-VL) were used to reconstruct perineal defects in 23 patients. Although this cohort included both post-abdominoperineal resection cases (n=13) and perineal reconstructions following infectious diseases (n=10), data showed satisfactory outcomes with no reconstructive failures, albeit the large defects treated (mean over 180cm<sup>2</sup>).

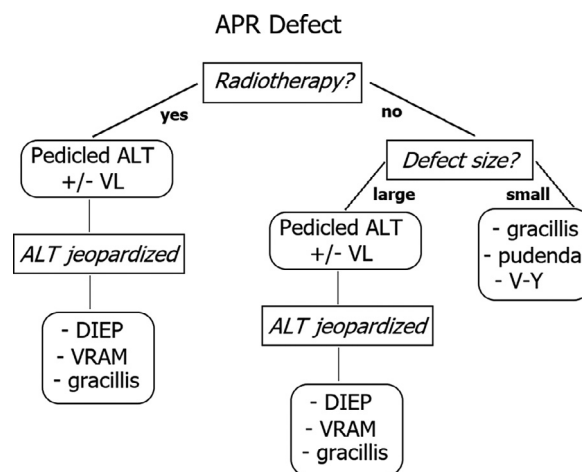
Although we acknowledge the inherent risk of overseeing one paper in large literature reviews, we think that it is to the reader's interest to consider large case studies of perineal reconstructions with ALT.

As mentioned by the author, extrapolation of review data may result in publication bias. This could skew the reader towards accepting the VRAM as the go-to option in perineal reconstruction, despite the risk of abdominal wall instability, cited as high as 66% in recent literature.<sup>4</sup>

Data available from the author's work show no significant difference in age in the groups under study, which seems logical given the defined population of patients treated for low rectal and anal cancers, with age ranging between 50 and 60 y.o. However, authors somehow suggest that VRAM would be particularly appropriate to old or frail patients, as suggested by the proposed algorithm. On the contrary, one could argue that these patients would benefit from an intervention with less morbidity, despite similar cumulative complications, such as ALT reconstructions. Indeed, in our experience is the defect size (not the patient's age) to be associated to increased complication rates, with a potential (but not significant) role played by radiotherapy. Thus, we find the author's statement suggesting choosing the reconstructive procedure based on the patient's age quite misleading for the reader.

Furthermore, the choice to group all thigh-based reconstructions, (i.e. local pudendal, VY, gracilis myocutaneous flaps, and ALT) and consider them less reliable (1, Table 7) does not reflect the current consensus - the ALT being an extremely safe flap with a reliable skin paddle, a long pedicle and wide arc of rotation.

The combination of ALT with vastus lateralis greatly increases the harvestable bulk to fill voluminous defects (often avoiding a double-flap raise, which in our experience is around 7%, despite massive defects).<sup>3,5</sup> In our experience, the ALT-VL can reach the sacro-coccygeal region after full pedicle dissection and flap tunneling under the sartorius and rectus femoris. **Figure 1**



**Figure 1** Abdominoperineal (APR) defect management: stratification is based on local radiotherapy, and defect size. In case the anterolateral thigh flap (ALT) cannot be harvested, i.e. in the presence of thigh scarring, or impairment of the circumflex femoral artery system, the abdominal donor site is preferred (deep inferior epigastric perforator flap, V-DIEP or VRAM if muscle need). In smaller defects local flaps are a viable option.

In conclusion, we believe that recent data suggests the ALT offers at least the reliability, bulk and ductility of the VRAM, with significantly inferior donor site morbidity.

In this sense, we would like to propose an amended algorithm, which we believe could better help reconstructive surgeons to tailor flap choice in perineal reconstructions following APR, this further confirmed by work of our group focusing on perineal reconstruction after APR, currently in press.<sup>5</sup>

## Declaration of Competing Interest

Authors do not have any conflict of interest to disclose.

## Funding

Authors do not have any funding sources to disclose.

## Ethical approval

N/A

## References

1. Copeland-Halperin LR, et al. Perineal reconstruction following abdominoperineal resection: Comprehensive review of the literature. *J Plast Reconstr Aesthet Surg* Nov 2020;73(11):1924-32.
2. Yang XY, et al. Primary vs myocutaneous flap closure of perineal defects following abdominoperineal resection for colorectal disease: a systematic review and meta-analysis. *Colorectal Dis* Feb 2019;21(2):138-55.



3. di Summa PG, et al. The combined pedicled anterolateral thigh and vastus lateralis flap as filler for complex perineal defects. *Ann Plast Surg* Jul 2015;75(1):66-73.
4. Devulapalli C, et al. Primary versus flap closure of perineal defects following oncologic resection: a systematic review and meta-analysis. *Plast Reconstr Surg* May 2016;137(5):1602-13.
5. Rossi SA, et al. Outcomes of the composite anterolateral thigh flap for perineal reconstruction after postoncological abdominoperineal resection. *Dis. Colon Rectum* 2021 Forthcoming. doi:10.1097/DCR0000000000002132.

S.A. Rossi

Department of Plastic, Reconstructive and Hand surgery,  
University Hospital, CHUV, Route du Bugnon 46, 1011  
Lausanne, Switzerland

D. Guillier

Department of Plastic Reconstructive and Hand Surgery,  
Department of Oral and Maxillofacial Surgery, University  
Hospital, Boulevard de Lattre de Tassigny, 21000 Dijon,  
France

M. Maruccia

Division of Plastic and Reconstructive surgery,  
Department of Emergency and Organ transplantation,  
University of Bari, Piazza Giulio Cesare, Bari 70124, Italy

P.G. di Summa

Department of Plastic, Reconstructive and Hand surgery,  
University Hospital, CHUV, Route du Bugnon 46, 1011  
Lausanne, Switzerland

© 2021 Published by Elsevier Ltd on behalf of British Association of Plastic, Reconstructive and Aesthetic Surgeons.

<https://doi.org/10.1016/j.bjps.2021.05.062>

## Pressure therapy with a novel compressive device for auricular keloids treatment after surgical excision<sup>☆</sup>



Dear Sir,

Auricular keloids are common in clinics and always lead to cosmetic problems and annoying symptoms such as pruritus and pain. The monotherapy of surgical excision proved to be ineffective with a recurrence rate between 45% and 100%, and intralesional corticosteroid injection shows recurrence rates of 9% - 50% as well as side effects such as skin atrophy, pigmentation/depigmentation, and telangiectasias.<sup>1</sup> Here, we introduce our compressive device for auricular

keloids prevention postoperatively, which has several advantages over other nonsurgical treatments and other compressive devices. It consists of three subunits: a fixing part with a nut and a pad, a sliding pad, and a screw bolt. (Figure 1 From left to right) The pads that contact the skin are frosted to enhance the friction. Its average weight is 0.8 g. Adjustment of the pressure is acquired by screwing the bolt.

Twelve female patients with 20 auricular keloids were included, which ranged from 18 to 76 years old. Among them, 16 cases received the combination of surgery and pressure therapy with our compressive devices. The other four cases treated with pressure therapy came with only early recurrence after surgeries or steroid injections in other hospitals.

In the surgery, the keloids were removed by intra-marginal undermining and the keloid fillet flaps were then trimmed to reshape the auricle. The wound was tension-free closed. The stitches were removed after the incision healed (mostly 7 - 10 days).

Pressure therapy was started on the third day after the stitches were removed. Patients were required to wear the device(s) for at least 10 h a day and for 6 months continuously. The pressure was adjusted to make the skin of interest turn slightly pale, and the patients complained of slight pain, which gradually disappeared. The follow-up ended if no recurrence was observed for at least 18 months after pressure therapy.

A good result was defined as a flat, nonpruritic, and no redness scar at the endpoint of the follow-up. Seventeen cases strictly followed the pressure therapy. One case underwent only 6 weeks of pressure therapy with no recurrence in the end. Two cases had early recurrence with slightly raised nodules weeks after surgery due to their insufficient time of daily pressure application, and therefore, received instructed pressure therapy once again for 6 months. No recurrence was observed for all cases when the follow-up ended. No contact dermatitis, pigmentation/depigmentation, or skin ulcer occurred. No patients complained of discomfort, device failure, or inconvenience.

For example, the 76-year-old patient suffered from ear-lobe keloids with repeated surgeries and steroid injections in other hospitals during the past 9 years. The first batch of the compressive devices, which were black and nontransparent were used after surgical excision. Pressure was applied until skin around the device slightly turned pale and caused moderate pain, and the pressure therapy lasted continuously for 7 months. At the end of follow-up for 2.5 years, no recurrence was observed. (Figure 2) For more direct and comprehensive observation, transparent devices made from aromatic polycarbonate were produced following the first batch. (Figure 1)

Previous studies agreed on the following standards for a compressive device: provide uniform and adjustable pressure; easy to apply, remove, and clean; being made of nonflammable materials; be cosmetically acceptable; and not compromise hearing.<sup>2</sup> Comparing different devices, we made a list of four categories: free adjustment, durability, easy usage, and skin observation. (Supplementary Table 1)

Our devices combine the advantages of light weight, precise pressure control, easy wearing, and last but not least, the universality in application because of the appropriate size, bolt design, and material. Transparency allows direct

<sup>☆</sup> Changhai Hospital, Naval Medical University. August, 2020.




Figure 1 The composition of the device.

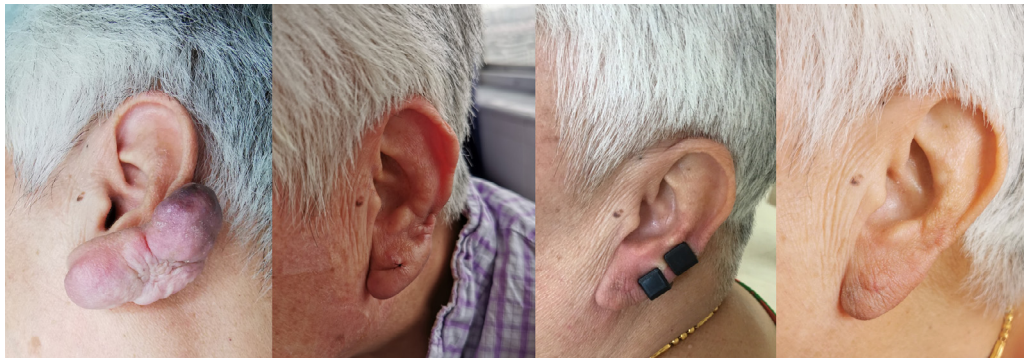

Figure 2 The 76-year-old patient as an example.

observation of whether the applied pressure is appropriate, particularly for patients. Patients could wear more than one according to their needs, with each one adjusted specifically and dynamically to fit the different thickness and change the locations freely. The compressive force could be directly and accurately adjusted by screwing the bolts. The material of aromatic polycarbonate, which features durability and lightness brings better patient compliance. In the future, the device is to be casted in different sizes to apply to all wounds after auricular keloids surgery.

Although 4 to 6 months of pressure therapy were recommended in previous articles because of the active scar formation in the early healing period<sup>3</sup> or the therapy ended once the scar showed no redness, nodule, and pruritus;<sup>4</sup> the exact time to terminate pressure therapy is yet to be elucidated. Besides, more evidence is required to determine the duration of each day and the appropriate follow-up time.

### Declaration of Competing Interest

The patent number of the novel compressive device: ZL201730233967.9.

### Acknowledgments

None.

### Funding

None.

### Ethical Approval

Institutional review board approval of Changhai Hospital was obtained for this study, and signed consent forms were collected from all patients who agreed to participate in the study.

### Supplementary materials

Supplementary material associated with this article can be found, in the online version, at [doi:10.1016/j.bjps.2021.05.031](https://doi.org/10.1016/j.bjps.2021.05.031).

### References

1. Mustoe TA, et al. International clinical recommendations on scar management. *Plast Reconstr Surg* 2002;110(2):560-71.
2. Chang CH, et al. The efficacy of magnetic disks for the treatment of earlobe hypertrophic scar. *Ann Plast Surg* 2005;54(5):566-9.
3. Monstrey S, et al. Updated scar management practical guidelines: non-invasive and invasive measures. *J Plast Reconstr Aesthet Surg* 2014;67(8):1017-25.
4. Bran GM, et al. Auricular keloids: combined therapy with a new pressure device. *Arch Facial Plast Surg* 2012;14(1):20-6.

Mengyan Sun<sup>1</sup>, Yuchong Wang<sup>1</sup>, Chunyu Xue, Ji Zhu  
*Department of Plastic Surgery, Changhai Hospital, Naval  
 Medical University, Shanghai, China*

Corresponding author: Ji Zhu, PhD, No. 168 Changhai Road,  
 Shanghai 200433, China.

<sup>1</sup>The first two authors 1 and 2 contributed equally to the  
 work and should be regarded as co-first authors.  
 E-mail address: [drzhuji@163.com](mailto:drzhuji@163.com) (J. Zhu)

© 2021 British Association of Plastic, Reconstructive and Aesthetic  
 Surgeons. Published by Elsevier Ltd. All rights reserved.

<https://doi.org/10.1016/j.bjps.2021.05.031>

## Letter to the Editor regarding “Impact of opioid-free anesthesia on complications after deep inferior epigastric perforator flap surgery: A retrospective cohort study”



Dear Sir,

Deep Inferior Epigastric Perforator Flap Surgery has  
 shown to be safe with less complications whilst the En-  
 hanced Recovery after Surgery (ERAS) Pathways' implemen-  
 tation provides patient the opportunity to recover earlier.

<sup>1</sup> Mulier et al. <sup>2</sup> has conducted an interesting research, en-  
 titled “*Impact of opioid-free anesthesia on complications  
 after deep inferior epigastric perforator flap surgery:  
 A retrospective cohort study*” focusing on the advantages  
 of opioid- free anesthesia and its complications.

Accordingly to their study, patients have less pain levels  
 and complications but we have to take into consideration  
 some major limitations of their research. First, reading  
 the article, it is not clear what was the exact protocol the  
 team was followed. We believe that it was a descriptive  
 retrospective study, which was the reason for the significant  
 difference in patients' age between the two groups. It is  
 better, when we conduct a comparative study to secure  
 that the 2 groups will be fully arrayed of patients' de-  
 mographic and anthropometric data, ensuring the same  
 baseline groups' characteristics for the study.

Visual Analogue Scale (VAS) has been proven to eval-  
 uate pain levels adequately. In this article, authors have  
 recorded the maximum VAS values in both groups but  
 they did not mention the time points of pain evaluation.  
 We believe, it is important for the readers, who want to  
 implement this type of anesthesia, to know how many  
 times authors evaluated pain levels and in which time point  
 of patients postoperative hospitalization. Furthermore,  
 authors referred to total intravenous anesthesia (TIVA),

without including the significance of this method (7 cases  
 among 149 cases).

Concluding, in our opinion, Mulier et al. conducted an  
 inspirous descriptive study that laid the foundations for  
 interesting prospective researches in Deep Inferior Epigas-  
 tric Perforator Flap Surgery. Future directions in this field  
 should include more specific prospective perioperative pro-  
 tocols because retrospectively we might miss information  
 through the recording process, especially if we combine  
 these protocols with ERAS programs.

### Conflict of interest

No.

### Funding

No.

### Ethical approval

The study does not involve human or animal subjects.

### References

1. Boer VB, van Wingerden JJ, Wever CF, Beets MR, Verhaegen PD,  
 Hamdi M. Perforator mapping practice for deep inferior epi-  
 gastric artery perforator flap reconstructions: a survey of the  
 benelux region. *J Reconstr Microsurg* 2021;37(2):111-18. doi:[10.1055/s-0040-1714427](https://doi.org/10.1055/s-0040-1714427).
2. Mulier H, De Frene B, Benmeridja L, et al. Impact of opioid-  
 free anesthesia on complications after deep inferior epigastric  
 perforator flap surgery: a retrospective cohort study. *J Plast  
 Reconstr Aesthet Surg* 2021;74(3):504-11. doi:[10.1016/j.bjps.2020.09.004](https://doi.org/10.1016/j.bjps.2020.09.004).

Maria Kapritsou  
*Chair of the Hellenic Perianaesthesia Nursing  
 Organization, Chief Nurse of Anesthesiology Department,  
 Hellenic Anticancer Institute, “Saint Savvas” Hospital,  
 Athens, Greece*

Nikolaos Fyrfiris  
*Consultant Anesthesiologist, “Saint Savvas” Hospital,  
 Athens, Greece, Av. Alexandras 171, Athens, 11522 Greece*

Maria Kotrotsiou  
*Director of Plastic and Reconstructive Clinic,  
 Evaggelismos Hospital, Athens, Greece*

Spyros Stavrianos  
*Head Director of Plastic and Reconstructive Clinic, “Saint  
 Savvas” Hospital, Athens, Greece  
 E-mail address: [sstavria@otenet.gr](mailto:sstavria@otenet.gr) (S. Stavrianos)*

© 2021 British Association of Plastic, Reconstructive and Aesthetic  
 Surgeons. Published by Elsevier Ltd. All rights reserved.

<https://doi.org/10.1016/j.bjps.2021.05.061>

## Letter comments on: Total breast reconstruction using large-volume condensed and viable fat grafting after mastectomy



Dear Sir,

We read with great interest the article entitled “Total breast reconstruction using large-volume condensed and viable fat grafting after mastectomy”<sup>1</sup> by Zhang X et al. in *Journal of Plastic, Reconstructive & Aesthetic Surgery*. In this article, the authors conducted a retrospective study on the effect of fat grafting for breast reconstruction. They provided data on fat grafting for postmastectomy patients, which is a basis for the popularization of this technology in clinical practice.

We see the lively appearance of the reconstructed nipples in Figures 1-3, and would like to know more technical details of nipple reconstruction in the authors’ practice.

The authors achieved good results based on pre- and postoperative photographs, a three-point grading scale, and the patient satisfaction, which are invalidated and subjective. We recommend the authors to use validated and objective scales for the outcome evaluation. As was mentioned in the article, magnetic resonance imaging (MRI) was conducted pre- and postoperatively, which can be utilized to calculate the volume retention rate. In addition, the breast-Q is a widely recognized scale to evaluate results of breast reconstruction.<sup>2</sup>

The authors said that an average of 3.3 (0.7) sessions and 230.5 (57.8) ml of fat at each session was performed for each patient. We believe that the authors should tell the amount of fat graft and the volume retention rate for each section, as each fat injection changes the microenvironment in the recipient site, possibly resulting in altered graft outcome.

The authors said that the fat grafts are ‘viable’ based on the relatively low incidence of fat necrosis postoperatively with MRI. We are afraid that this is not rigorous due to the lack of pathological and adipocyte metabolic examination.

### Declaration of Competing Interest

None declared.

### Funding

None.

### Ethical approval

Not required.

## References

1. Zhang X, Cai L, Yin B, et al. Total breast reconstruction using large-volume condensed and viable fat grafting after mastectomy. *J Plast Reconstr Aesthet Surg* 2021;74(5):966-73.
2. Pusic AL, Klassen AF, Scott AM, et al. Development of a new patient-reported outcome measure for breast surgery: the BREAST-Q. *Plast Reconstr Surg* 2009;124(2):345-53.

Zuguang Hua  
Peng Wei

Ningbo No1 Hospital, No. 59, Liuting Street, Haishu District, Ningbo 315000, Zhejiang, People’s Republic of China

E-mail address: [hzg-m2004@126.com](mailto:hzg-m2004@126.com) (Z. Hua)

© 2021 Published by Elsevier Ltd on behalf of British Association of Plastic, Reconstructive and Aesthetic Surgeons.

<https://doi.org/10.1016/j.bjps.2021.05.064>

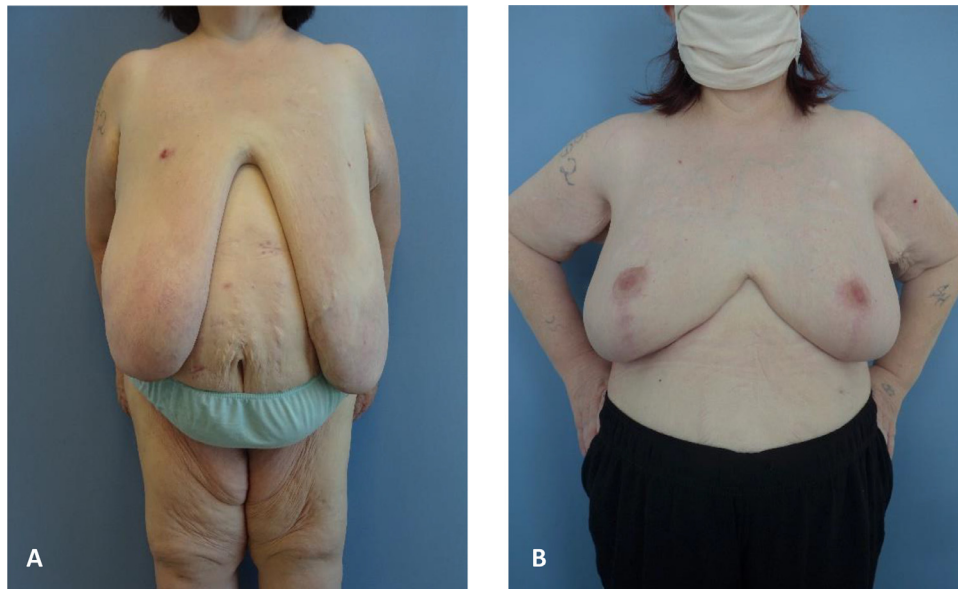
## Overcoming the limits of traditional breast reduction -inferior pedicle approach for macromastia with sternal notch-to-nipple distance of up to 57 cm



Dear Sir,

When building clinical expertise, many questions can be answered by using textbooks or other digital learning resources to determine what is generally known about a topic and its standard clinical practice. Medical residency, however, also involves the evolution of critical questioning of standard protocols and guidelines, which means the revising of their concordance with evidence-based medicine. Medical progress and development may sometimes be rapid as demonstrated by latest innovations in the recent COVID-19 pandemic. Thus, constant reevaluation is crucial for every practicing health professional.

We have read with great interest the recently published article by *Bustos et al.* who highlight the outdated recommendations of some clinical textbooks and literature concerning the indication of free nipple grafting in reduction mammoplasty by providing a valuable overview about the indication and safety of the inferior pedicle approach.<sup>1</sup> We specifically thank the authors for their evaluation of - success of this procedure considering nipple-areola-complex (NAC)-viability in patients suffering from extreme macromastia. Only two out of 576 breasts (0.4%) with a mean preoperative sternal notch-to-nipple (SN-N) distance of 31.5 cm (range 16-48 cm) and mean nipple-to-inframammary fold (N-IMF) distance of 14.8 cm (range 7.5-27) developed partial NAC necrosis. These results support the inferior pedicle



**Figure 1** Pre (A) and 6-months postoperative (B) photographs of a 50-year old patient with gigantomastia and sternal-notch distance of 53 cm and 48 cm (left/right), who underwent reduction mammoplasty with resection weights 1.230 g and 1050 g (left/right).

reduction mammoplasty being a safe and reliable technique - even in patients with gigantomastia and resection weights up to 2385 g. For this reason, common indications for free nipple grafting such as “long N-IMF distance, long SN-N distance and resection weight > 2000 g” may be regarded obsolete.<sup>1</sup>

We highly agree with the authors that reduction mammoplasty should always attempt a pedicle approach and pre-operative planning of nipple grafting is to be avoided. The later may only be considered intraoperatively when NAC perfusion is clearly limited. In addition to this, we do not consider age an indication for free nipple grafting because of reduction of operative time. An experienced team that regularly performs breast reduction is to be regarded well familiar with pedicle dissection and thus may be able to perform in an appropriate operative time without increasing perioperative mortality.

Given the length of arterial supply in extreme macromastia using an inferior pedicle, concerns about the relationship between pedicle length and NAC survival are comprehensible. According to *Bustos et al.*, resection weight instead of pedicle length was found to be a significant predictor for skin or NAC necrosis in multivariate analysis.<sup>1</sup> Considering overall complication, however, resection weight failed to reach statistical significance after adjustment for BMI, age and SN-N distance. Since a positive correlation between BMI and resection weight must be considered, the aforementioned influence on skin or NAC necrosis may be biased by patients' BMI. This observation is further supported by subgroup analysis assessing the rate of complication in relation to resection weight (<1000 g or >1000 g). In this analysis, patients' BMI was statistically significant higher when resection weights exceeded 1000 g; and so was the risk of wound dehiscence, skin necrosis, unplanned readmission and sur-

gical site infection. Unfortunately, the influence of pedicle width on skin or NAC necrosis was not addressed in statistical analysis, even though it was mentioned in the introduction of the study.

As for gigantomastia, we think the low rate of NAC necrosis might also be related to protective effects, which are well known from reconstructive surgery or flap surgery: conditioning techniques that aim to increase tissue tolerance to ischemia by short and repeated mechanical interruption of blood flow. It seems intelligible that elongation of the breasts vessels due to their heavy weight and shear forces during mobilization may mimic a stimulus of “chronic ischemic pre-conditioning” promoting NAC viability when reduction mammoplasty is performed. **Figure 1** shows an example of a gigantomastia patient with severe ptosis and pre-operative SN-N of 53 cm and 48 cm (left/right) given a body height of 150 cm. Intraoperative pedicle length equalled 36 cm while pedicle width reached 12 cm. Postoperative evaluation revealed perfectly viable NACs on both sides. Likewise, *Wirthmann et al.* presented results of a gigantomastia patient with preoperative SN-N distance of even up to 57 cm.<sup>2</sup> Considering these examples, we actually have to wonder, do we really need to pose the question “how long is safe”? Indeed, do we have to define a maximum to successfully perform inferior pedicle breast reduction? We definitely rely on the safety of the inferior pedicle for large resections and long pedicles as mentioned by the authors. However, when seeking for even more safety and reliability of the vascular supply, preservation of the Würinger's septum can be considered turning the inferior pedicle into an infero-central one.<sup>3,4</sup> This should ultimately ban anecdotal indications for free nipple grafting and enable pedicle breast reduction among all gigantomastia patients.

## Declaration of Competing Interest

All authors declare no potential conflicts of interest with respect to the research, authorship, and/or publication of this article.

## Ethical approval

For this type of study, ethical approval is not necessary.

## Funding

None.

## Informed consent

All subjects gave informed consent for publishing pre-, intra- and postoperative photographs.

## References

1. Bustos SS, Molinar V, Kuruoglu D, et al. Inferior pedicle breast reduction and long nipple-to-inframammary fold distance: how long is safe? *J Plast Reconstr Aesthet Surg* 2021;74:495-503.
2. Wirthmann AE, Welsch L, Wellenbrock SV, et al. Reduction mammoplasty in adolescents and elderly: a ten year case series analyzing age related outcome with focus on safety and complications. *J Plast Reconstr Aesthet Surg* 2018;71:377-83.
3. Georgiade GS, Riefkohl RE, Georgiade NG. The inferior dermal-pyramidal type breast reduction: long-term evaluation. *Ann Plast Surg* 1989;23:203-11.
4. Portincasa A, Ciancio F, Cagiano L, Innocenti A, Parisi D. Septum-enhanced mammoplasty in inferocentral pedicled breast reduction for macromastia and gigantomastia patients. *Aesthetic Plast Surg* 2017;41:1037-44.

I.A. Ederer  
S. Spennato  
L. Kueenzlen  
S. Kuehn  
J. Rothenberger  
U.M. Rieger

Department of Plastic and Aesthetic, Reconstructive and Hand Surgery, Agaplesion Markus Hospital, Frankfurt, Germany

E-mail address: [ines.ederer@hotmail.com](mailto:ines.ederer@hotmail.com) (I.A. Ederer)

© 2021 British Association of Plastic, Reconstructive and Aesthetic Surgeons. Published by Elsevier Ltd. All rights reserved.

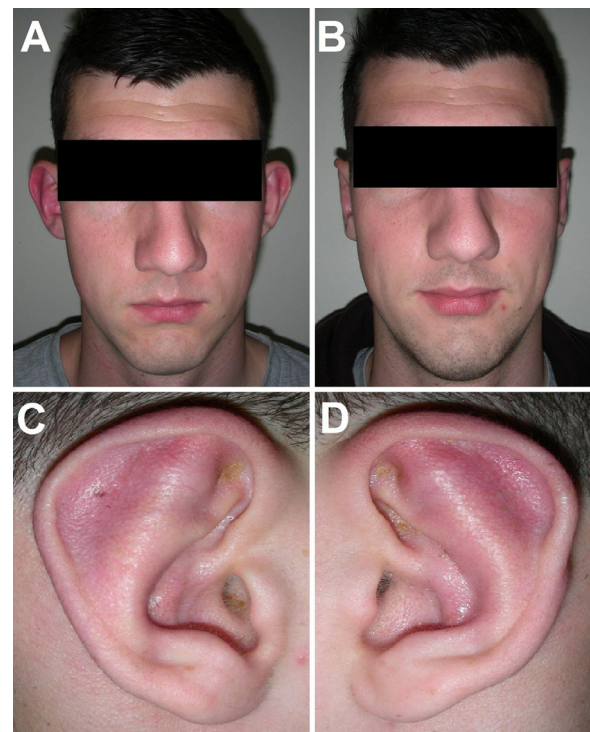
<https://doi.org/10.1016/j.bjps.2021.05.060>

## Earfold™: A combined approach with conchal bowl reduction



Dear Sir,

Prominent ears are caused by a combination of factors but especially a poorly developed antihelical fold and hypertrophy of the conchal fossa.<sup>1</sup> Correction of the antihelical fold is most frequently achieved using sutures or cartilage scoring techniques<sup>2</sup>, while correction of a hypertrophic conchal bowl can be accomplished through cartilage excision, cartilage plication or concho-mastoid sutures.<sup>3</sup> Recently, a minimally invasive technique for correction of the antihelical fold has been described using an implant placed subcutaneously, at the front of the ear.<sup>4</sup> When the Earfold™ implant is released, it grips the cartilage and reshapes the antihelical fold, thereby correcting this aspect of ear prominence (Figure 1). We now present the results of a prospective, uncontrolled, qualitative study of outcomes follow-



**Figure 1** A: 21-year-old male patient before undergoing combined procedure with Earfold™ implants and conchal bowl reduction for prominent ears. 1B: the same patient at 12-months follow-up. 1C: Result at 12-month follow-up showing right ear with Earfold™ implants in situ. 1D: Result at 12-month follow-up showing left ear with Earfold™ implants in situ.

**Table 1** Results of the Ear-Q for all age groups. All questions were answered on a 4- point Likert scale. Significance level was set below 0.05.

Question	Question Details	Which response would be best?	Difference (Mean)	STD	P-Value
PEM section 1: Ear Appearance - All age groups (n = 8)					
1	How much do you like how your ears look from far away?	Higher	2.38	1.19	0.001
2	How much do you like how your ears look if you put on a hat that shows your ears (e.g. a baseball cap)?	Higher	2.63	0.74	<0.001
3	How much do you like the size of your ears?	Higher	1.25	1.28	0.028
4	How much do you like how well your ears match each other (look the same)?	Higher	1.25	1.28	0.028
5	How much do you like how your ears look if your hair is short or pulled back?	Higher	2.63	0.52	<0.001
6	How much do you like how your ears look when your hair is wet?	Higher	2.75	0.46	<0.001
7	How much do you like how close your ears are to your head?	Higher	2.75	0.46	<0.001
8	How much do you like how your ears look in photos?	Higher	2.50	1.07	<0.001
9	How much do you like how your ears look if you wear glasses or sunglasses?	Higher	2.25	1.04	<0.001
10	How much do you like how far your ears come out from your head?	Higher	1.13	2.64	0.268
11	How much do you like how your ears look compared with other people's ears?	Higher	2.50	0.76	<0.001
12	How much do you like how your ears look in the mirror?	Higher	2.63	0.74	<0.001
13	How much do you like how your ears look from the side (your profile)?	Higher	2.00	0.76	<0.001
14	How much do you like the overall shape of your ears?	Higher	2.00	0.93	<0.001
15	How much do you like how your earlobes look?	Higher	1.13	0.99	0.015
16	How much do you like how the top part of your ears look?	Higher	1.75	1.17	0.004
17	How much do you like how your ears look from behind (e.g., a photo that shows the back of your head)?	Higher	2.88	0.35	<0.001
18	How much do you like how your ears look up close?	Higher	2.00	1.07	0.001
19	How much do you like how your ears look overall?	Higher	2.63	0.74	<0.001

ing treatment of prominent ears using a combination of Earfold™ and conchal bowl reduction over a five-year period.

Our primary aim was to evaluate patient perceptions regarding the appearance of their ears before and after surgery, using a validated EAR-Q questionnaire. Additionally, information regarding their self-perceived health was collected using the SF-10™ (children and adolescents) and SF-12™ (adults) Health Surveys. The secondary aim was to establish the nature and incidence of complications and to compare the results with other otoplasty techniques.

A total of 18 patients underwent combined surgery. There were 10 females and 8 males ranging in age from 7 to 65 years (mean = 28 years). All patients underwent bilateral treatment (i.e., 36 ears) using an average of 1 Earfold™ implant per ear (total of 37 implants used). Conchal bowl reduction was performed on 35 ears (i.e., one unilateral con-

chal bowl reduction). A total of 8 completed questionnaires were received giving a 44.44% response rate (mean follow up = 2.3 years, range = 4.3 years). The study respondents consisted of 5 adults (aged at least 18 years), 2 adolescents (aged 12-17) and 1 child (under the age of 12).

All responding patients were satisfied following treatment with a mean change of 2.63 ( $p < 0.001$ ) in self-perceived appearance of both ears (Table 1). There was no significant change in self-perceived general health and social function in any age group, apart from a statistically significant increase in the scores relating to how patients felt about their external appearance. Whilst it can be argued that the aim of the procedure is purely aesthetic, it is well established that prominent ear correction leads to an improvement in both social function and well-being, especially for children. Therefore, it is more likely that the absence of an improvement in general health was due to the

small sample size. We also compared our results with those in a previous study using the Earfold™ implant alone.<sup>4</sup> Our results suggest that the combination procedure resulted in a greater difference (65.7% vs 39%) in perceived improvement in appearance when compared with use of the implant alone.

Post-operative pain subsided in 7 patients within the first 48 h and this was managed solely with over-the-counter analgesia. One patient reported overt pain in the vicinity of the operative site for the first three months following surgery, but this eventually resolved. Hypersensitivity of the skin overlying the implant was initially reported by all study participants. However, this was self-limiting and disappeared after three months in all but one patient in whom the discomfort failed to resolve even at 17 months after surgery. There were no cases of haematomas or infections necessitating antimicrobial therapy, no cases of erosion/extrusion of the implant and no reports of recurrence of prominent ear deformity in the study group. Furthermore, none of the patients included in our study required revision surgery. Therefore, we concluded that the side effect profile was different compared with other otoplasty procedures. The most common complications in this study were (temporary) pain and hypersensitivity in the area surrounding the implants, while other studies more commonly list recurrence of prominence, problems with asymmetry, bleeding, and extrusion of sutures.<sup>5</sup> The complication rate seen in this study was 25%, which is higher than that seen using Earfold™ implants alone, but most of the complications were minor (e.g. pain, discomfort) not requiring treatment or revision surgery.

The main limitation of our study is the small sample size. The cohort of patients who have undergone this type of prominent ear correction is small and many patients did not complete their questionnaires. Although the sample size was within the expected range, sampling bias cannot be ruled out as patients who failed to obtain a satisfactory result might be less keen to participate in research related to their surgery.

Overall, our study suggests that the Earfold™ implant can be used safely in combination with conchal bowl reduction to achieve a better outcome compared with treatment using Earfold™ implants alone.

### Financial disclosure statement

Dr Kang is the inventor of the Earfold™ implant. Ms Michno and Mr Konczalik have nothing to disclose. No funding was received for this article.

### Funding

None.

### Declaration of Competing Interest

Dr Kang is the inventor of the Earfold™ implant. Ms Michno and Mr Konczalik have nothing to disclose.

### Ethical approval

Ethical approval was obtained from the Institutional Review Board at Royal Free NHS Foundation Trust, as well as from the Health Research Authority (HRA) and Health and Care Research Wales (HCRW) in the United Kingdom.

### References

1. Nazarian R, Eshraghi AA. Otoplasty for the protruded ear. *Semin Plast Surg* 2011;**25**(4):288-94.
2. Kang NV, Sabbagh W, O'Toole G, Silberberg M. Earfold: a new technique for correction of the shape of the antihelix. *Laryngoscope* 2018;**128**(10):2282-90.
3. Naumann A. Otoplasty - techniques, characteristics and risks. *GMS Curr Top Otorhinolaryngol Head Neck Surg* 2007;**6**:Doc04.
4. Kang NV, Kerstein RL. Treatment of prominent ears with an implantable clip system: a pilot study. *Aesthet Surg J* 2016;**36**(3):Np100-16.
5. Handler EB, Song T, Shih C. Complications of otoplasty. *Facial Plast Surg Clin N Am* 2013;**21**(4):653-62.

Norbert V. Kang

Wojciech J. Konczalik

Dominika A. Michno

Department of Plastic Surgery, Royal Free Hospital, Pond St., NW3 2QG London, United Kingdom

E-mail address: [Dominika.michno@nhs.net](mailto:Dominika.michno@nhs.net) (D.A. Michno)

© 2021 British Association of Plastic, Reconstructive and Aesthetic Surgeons. Published by Elsevier Ltd. All rights reserved.

<https://doi.org/10.1016/j.bjps.2021.03.113>

## Improving smartphone follow-up after patient discharge from annual short-term head and neck missions in Ethiopia



Dear Sir,

### Introduction

Project Harar is a non-governmental organisation (NGO) that works closely with Yekatit 12 Medical College, Addis Ababa, Ethiopia, treating children and adults with complex facial disfigurement on annual short-term reconstructive missions. Contrary to our recent 2020 mission comprising 35 volunteers, early Project Harar missions were significantly less well resourced. As a result, patient follow-up was often limited to less than one month.<sup>1</sup> Today, there is still a global

This research project has not been submitted for national or international presentation at the time of submission.





**Figure 1** Medical picture guideline: an educational tool to assist patients in providing optimal quality post-operative photographs, aiding complication identification. In practice, the medical picture guideline will be translated appropriately depending on each patient's language/dialect.

lack of longer-term follow-up reported after short-term reconstructive missions.<sup>2</sup>

In 2017, a Project Harar review team travelled across Ethiopia gathering long-term outcome data for patients operated on by the charity since 2008. Although successful, the time commitment, extensive distances travelled, and associated costs were limiting factors for the sustainability of this follow-up method.<sup>3</sup>

In 2018, the charity piloted remote follow-up using regional field workers with smartphones to follow-up 79% of patients in their rural villages at ten months post-operatively. Project Harar has continued to develop and refine this novel method using smartphones, minimising costs for the charity and the burden on patients after discharge.<sup>4</sup>

The aim of this study is to evaluate the transition from successful pilot follow-up programme into routine charity practice, and to evaluate the quality of remote follow-up data being received. Based on this we propose a new educational tool and a follow-up algorithm that will benefit other NGOs working in resource-limited settings.

## Patients and methods

Three months after discharge from the 2020 mission, patients were contacted via telephone (voice or video call) using the IMO app (a communications app) and asked six triage questions, as previously detailed by the authors.<sup>4</sup>

Patients were asked to send photographs to Project Harar using their own smartphones (anteroposterior, lateral, oblique, and (if indicated) intra-oral views). All con-

sent to their photographs and clinical data being used. De-identified patient data was sent to the charity leads via a secure file-sharing platform. Four consultant head and neck surgeons graded all photos using a visual analogue scale, from 1 (poor quality and diagnostic utility) to 5 (excellent quality and diagnostic utility).

## Results

Twenty-six patients were operated on during the 2020 mission (mean age 23.3 years, range 4 to 40). Twenty-three [88%] of 26 patients provided answers to the triage questions, and photographs were received from 19 [73%] of 26 patients. Three patients were not contactable. Four patients had no internet access to send photographs. Twenty-two [96%] of 23 patients were happy with their surgical outcome at three months.

### Photo quality assessment

Five photos [4%] were graded 1 (poor), 18 [14%] graded 2, 46 [36%] graded 3, 54 [42%] graded 4, and 5 [4%] graded 5 (excellent). Reasons for low grading included: poor focus, poor resolution, and incorrect patient angle or position.

## Discussion

Follow-up and triage using patients' own smartphones is now established charity practice, enabling successful

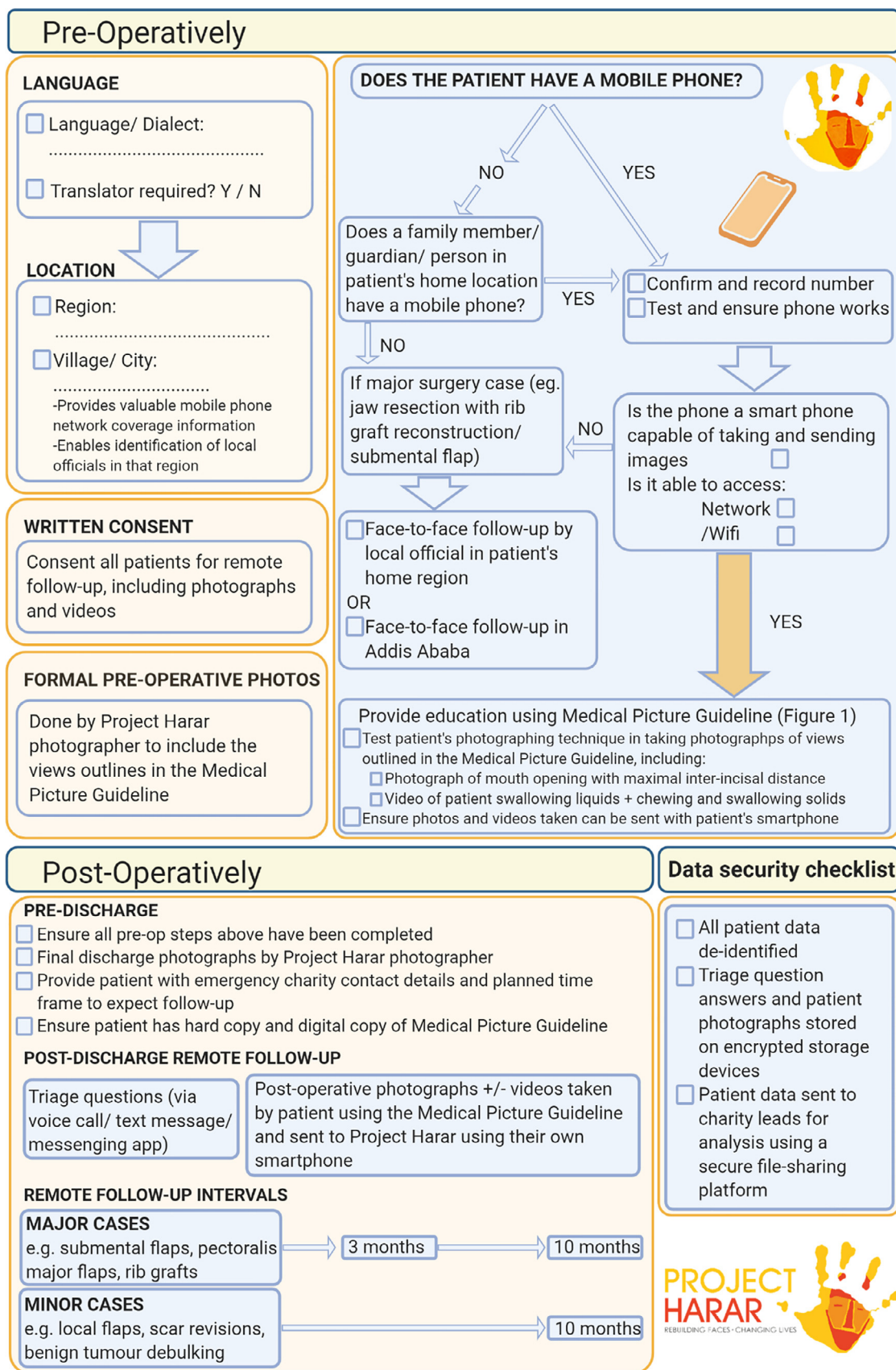


Figure 2 Remote follow-up algorithm: an algorithm to support successful remote follow-up using patients' own smartphones.

follow-up of the majority of patients following a short-term head and neck reconstructive mission in Ethiopia. In 2020 our follow-up rate improved from 79% (2018-2019) to 88%, without field workers having to travel to patients' home regions in the majority, allowing the re-allocation of charity workforce whilst ensuring continued patient safety. Regional travel restrictions due to the COVID-19 pandemic, and recent civil unrest in Ethiopia, have so far been overcome using our remote follow-up method. However, major disruptions affecting smartphone networks and internet coverage could be detrimental to the remote follow-up model, leading to time delays. Face-to-face follow-up using field workers will remain an essential element for any uncontactable patients, those unable to send follow-up photographs, and those retuning for staged surgery.

The photograph grading data indicated that patient photograph quality was highly variable- although, in most cases sufficient to assess post-operative complications and early outcomes. Suboptimal photographs were often simply due to patient positioning. We created a medical picture guideline (Figure 1) as an educational tool to assist patients to take better quality, standardised, post-operative photographs.

### Future developments

Ongoing refinements in patient follow-up practice have led to the development and implementation of a new remote follow-up algorithm (Figure 2). During the next mission, patients' will be assessed taking photographs prior to discharge, and education provided in conjunction with the medical picture guideline (Figure 1). We aim to expand our programme to include pre- and post-operative mouth-opening and eating videos for patients with relevant pathology (e.g. temporomandibular joint (TMJ) ankylosis). In addition, physiotherapy using smartphones for TMJ cases may also be possible, but further work is required.

### Conclusions

Patients' smartphones alone facilitated successful follow-up in the majority of patients following a short-term reconstructive head and neck mission in Ethiopia, reducing burden and travel time for patients, and saving significant cost and workload for the charity. In an effort to improve accountability on short-term surgical missions, we hope this work will be of use to other organisations operating in resource-limited settings facing access restrictions limiting longer-term patient follow-up.

### Funding

None.

### Disclosures

None.

### Ethical approval

This study is part of an ongoing audit of clinical practice and did not require research and ethics approval.

### Patient consent

Written patient consent was obtained from all patients included in this study.

### Declaration of Competing Interest

None.

### Acknowledgements

We would like to thank all Project Harar staff and volunteers for their hard work and support, especially during the unprecedented difficulties of the COVID-19 pandemic and civil unrest in Ethiopia.

### References

- Huijing MA, Marck KW, Combes J, et al. Facial reconstruction in the developing world: a complicated matter. *Br J Oral Maxillofac Surg* 2011;49:292-6. doi:10.1016/j.bjoms.2009.08.044.
- Hendriks TCC, Botman M, Rahmee CNS, et al. Impact of short-term reconstructive surgical missions: a systematic review. *BMJ Glob Heal* 2019;4(2):e001176. doi:10.1136/bmjgh-2018-001176.
- Honeyman C, Patel V, Yonis E, et al. Long-term outcomes associated with short-term surgical missions treating complex head and neck disfigurement in Ethiopia: a retrospective cohort study. *J Plast Reconstr Aesthetic Surg* 2020 Published online. doi:10.1016/j.bjps.2019.12.009.
- Bradley D, Honeyman C, Patel V, et al. Smartphones can be used for patient follow-up after a surgical mission treating complex head and neck disfigurement in Ethiopia: results from a prospective pilot study. *J Plast Reconstr Aesthetic Surg* 2020:1-3 Published online. doi:10.1016/j.bjps.2020.10.025.

Daniel R Bradley

Department of Maxillofacial and Head and Neck Surgery,  
University Hospitals Coventry and Warwickshire, Clifford  
Bridge Rd, Coventry CV2 2DX, England, United Kingdom

Calum Honeyman

Department of Plastic, Reconstructive and Burns Surgery,  
Ninewells Hospital, Dundee, Scotland, United Kingdom

Vinod Patel

Oral Surgery Department, Guys Dental Institute, Guys &  
St Thomas NHS Foundation Trust, London, England, United  
Kingdom

Fernando Almas

Department of Cranio-Maxillofacial and Reconstructive  
Surgery, Saint Judes General Hospital, Federal Hospital of  
Rio de Janeiro, Rio de Janeiro, Brazil

Gary Walton  
*Department of Maxillofacial and Head and Neck Surgery,  
 University Hospitals Coventry and Warwickshire, Coventry,  
 England, United Kingdom*

Mekonen Eshete  
*Department of Surgery, School of Medicine, College of  
 Health Sciences Addis Ababa University, Addis, Ababa,  
 Ethiopia*

Dominique Martin  
*Private Practice, 35 avenue des pins 13013, Marseille,  
 France*

Mark McGurk  
*Department of Head and Neck Surgery, University College  
 London Hospital, London, England, United Kingdom*  
 E-mail address: [drdanielrobinbradley@hotmail.com](mailto:drdanielrobinbradley@hotmail.com) (D.R.  
 Bradley)

© 2021 British Association of Plastic, Reconstructive and Aesthetic Surgeons. Published by Elsevier Ltd. All rights reserved.

<https://doi.org/10.1016/j.bjps.2021.03.037>

## Scientometric analysis of genital cosmetic and aesthetic procedures between 1981 and 2019



Dear Sir,

Today, genital cosmetic treatments and aesthetics have become one of the important issues that affect life socially and psychologically for both women and men. Cutaneous changes with advancing age, vaginal relaxation, vulvar atrophy, vulvar asymmetry, vaginal birth scars or sexual demands of partners are some of the common causes of genital aesthetics in women.<sup>1</sup> With the scientometric analysis method, we want to present the research topics and trends related to genital cosmetic and aesthetic procedures to the reader in a global context.<sup>2</sup>

The source of our analysis is the Web of Science (WoS) database and includes the Korean journal database, core collection index, Russian Science Citation Index and ScELO citation index. While searching the database, the words "genital cosmetics" or 'genital or aesthetics' were used as keywords. We found a total of 522 documents between 1981-2019. The documents obtained were written in 8 different languages, 92.7% of them were produced in English, followed by German with 3.0% and French with 2.1%. The majority of the documents found were original articles, followed by reviewers and editorial material, respectively. About genital cosmetics and aesthetics were investigated in

the field of urology-nephrology, surgery and obstetrics gynecology respectively.

The number of articles about genital cosmetics and aesthetics began to increase in 2004, the upward trend has continued until today, the year in which the highest number of documents were printed was 2016, the most cited year was 2019. We analyzed the document productivity of countries in the WoS database and found that the most productive country was the United States (USA), producing 161 articles. Following USA, Britain was the second productive country with 68 articles, and Germany was the third productive country with 40 publications. We found that the productivity of African countries, Central Asian Countries and South American countries is very low in genital cosmetics and aesthetics (Fig. 1).

When the authors' productivity, institutions, and H-Indices were examined, Creighton S.M from the University of London, England, was found to be the most productive researcher. The 10 most productive authors and countries are presented in Table 1. We compared the productivity of universities and organizations in the WoS database. The most productive university was the University of Melbourne and hosted 12 publications in the field of genital cosmetics and aesthetics.

We have determined that 1741 authors research about genital cosmetics and aesthetics in the WoS database. When the citation analysis between the operators was examined with Vosviewer, we found that there was a cluster around Braun V., Goodman M.P and Alter H.J. A total of 58 active universities were identified. In terms of the citation relationship, University of Melbourne, University Collage of London, University of California, San Francisco, Harvard University, and New York University were at the center.

The H index of 522 articles in the WoS database was 41, and the average number of citations for each item was 15.23. When the most cited publications are examined, the relationship created by the citations is gathered around the authors Creighton, Goodman, Bouman and Ebert. These authors have a strong relationship among themselves in terms of citations.

International document collaboration is developing around the USA. Britain, Germany, Italy, Australia and the Netherlands are the countries that have the most relations in terms of documents. When international cooperation is valued by the collaboration of the authors, USA is also in the center. However, after 2018, the joint working trends of Tunisia, Colombia, Malaysia and Egypt became evident.

We found that a total of 1108 repetitive words were used in publications about genital cosmetics and aesthetics; 102 words are used very frequently after filtering in order to detect words that repeat at least three times in a publication and may be a keyword for this subject. After our analysis, we found that the keywords intersecting in all publications were "labiaplasty, cosmetic surgery, female genital cosmetic surgery, vaginoplasty, genital surgery, hypospadias and bladder extrophy" in order of frequency (Fig. 1). We found the keywords of labiaplasty, female genital cosmetic surgery and vaginoplasty in women at the center. In particular, the US, Britain, Spain and Turkey started its certifica-

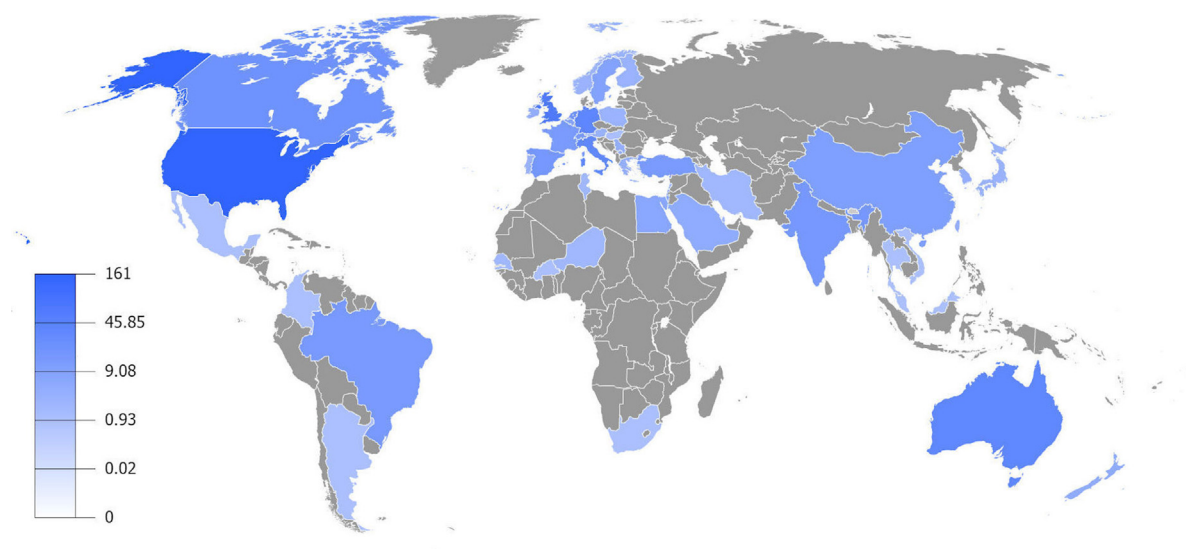


Fig. 1 Global genital aesthetic and cosmetic publication density according to the countries.

Table 1. The first ten authors by record count in genital cosmetics and aesthetics literature between 1981 and 2019.

Authors	Institution	Record Count	% of 522	H-index
Creighton S.M.	University College London, England.	11	2.1	33
Liao L.M.	University College London, England.	10	1.9	22
Veale D.	Maudsley Hosp & Inst Psychiat, London England.	7	1.1	30
Cardozo L.	King's College Hospital, England.	6	1.2	59
Garaffa G	Bellaria Hosp, Bologna, Italy	6	1.1	20
Goodman M.P.	Northwestern Univ. Chicago, IL, USA	6	1.1	21
Sharp G.	Flinders Univ., S Adelaide, Australia.	6	1.1	20
Braun V.	Univ Auckland, Auckland, New Zealand.	5	0.9	21
Fisch M.	Univ Klinikum, Hamburg Germany	5	0.9	35
Hoebeke P.	Ghent Univ Hosp, Ghent, Belgium	5	0.9	42

Univ: University; USA: United States of America.

tion program is known about female genital cosmetic procedures.<sup>3</sup>

Our analysis has shown that cosmetic and aesthetic interventions of male genital system concern both pediatrics and urology disciplines. Correction of penile and scrotal deformities or surgical treatments of cosmetic demands are among the trending topics. Especially before applying male genital cosmetic and aesthetic procedures, the psychiatric conditions of the patients should be taken into consideration and their body perceptions and psychosexual states should be carefully evaluated.

The communication of patients trying to reach genital cosmetic and aesthetic procedures with clinicians before or after surgery was interrupted due to the Covid 19 pandemic. It has begun to be seen that the previously used telemedicine or telephonic consultation methods play a more important role in the patient-physician relationship or between physicians.<sup>4</sup> It seems that genital aesthetic and cosmetic procedures have not yet been adequately

accommodated in the practice of obstetrics, urology and dermatology, but have been increasing rapidly for several years.

### Funding

No funding

### Ethical approval

N/A

### Declaration of Competing Interest

There is no conflict of interest

## Supplementary materials

Supplementary material associated with this article can be found, in the online version, at doi:[10.1016/j.bjps.2021.05.057](https://doi.org/10.1016/j.bjps.2021.05.057).

## References

1. Placik OJ, Devgan LL. Female genital and vaginal plastic surgery: an overview. *Plast Reconstr Surg* 2019 Aug;144(2): 284e-297e.
2. Yildirim E, Kahraman E. Thrombosis in pregnancy: scientometric analysis of thrombotic diseases in pregnancy between 1975 and 2019. *Ann Med Res* 2020;27(7):1893-9.
3. Güneş A, Alinsod RM. A mini-review of aesthetic gynecology and leading gynecology associations' approaches to this link. *Turk J Obstet Gynecol* 2018;15(2):105-11.
4. Gillman-Wells Christopher C, Sankar Thangasamy K, Vadoria Shailesh. COVID-19 reducing the risks: telemedicine is the new norm for surgical consultations and communications. *Aesthetic Plast Surg* 2020:1-6.

Engin Yildirim

Malatya Turgut Ozal University Faculty of Medicine,  
Department of Obstetrics and Gynecology, Alacakapi  
Campus, Kırkgöz Street, 44210 Battalgazi / MALATYA  
E-mail address: [engin.yildirim@ozal.edu.tr](mailto:engin.yildirim@ozal.edu.tr) (E. Yildirim)

© 2021 British Association of Plastic, Reconstructive and Aesthetic Surgeons. Published by Elsevier Ltd. All rights reserved.

<https://doi.org/10.1016/j.bjps.2021.05.057>

## Didactic principles in plastic surgery training



Dear Sir,

As in all other fields, mentoring in plastic surgery is reflected by the capability of the teacher to teach and the capacity of the student to learn. The process of mentoring has been under research and tight scrutiny for many years, but little information about the application of didactic principles in plastic surgery training has been published. Providing surgical training is something that may have become considered as a routine over time, however, training effectiveness can be optimised if some didactic principles are respected.

The principle of conscious and active participation of students in an educational process was introduced by Jan Amos Komenský (Comenius) in his work "Didactica Magna" in the 17th century.<sup>1</sup> According to this principle, the teacher must provide the informational content in a comprehensive dimension for the student, so that, on the other hand, the student can actively participate in the educational process. Comenius' principle was later adopted by Jean-Jacques Rousseau and Johann Heinrich

Pestalozzi among others. In current times, the principle is still valid for surgical training. In order for the trainee to actively participate, the objectives and competences must be presented and explained clearly; the trainee must accomplish educational tasks to process information, adopt clinical attitudes and practice surgical thinking; and the trainee must be encouraged to actively practice surgery to develop the capacity of independence.

It is important to respect a thorough acquisition of knowledge, skills and abilities. Not all informational content should be offered at once, but gradually in different levels of increasing complexity. In plastic surgery, this levelled principle starts with fundamental knowledge such as anatomy and physiology, before continuing with actual surgical strategies. Crucial is that the new information must relate to the anterior experience of the trainee. The consolidation of the taught material must be durable in time and prove their usefulness. In this way, the teacher can ensure key principles are understood, enhancing patient safety during procedures. Respecting this principle can also avoid discouragement from the trainee's perspective. By giving the trainee a foundation of basic principles, you bring them confidence and ability to deal with surgical scenarios that they have not faced before, rather than teaching them how to complete series of consecutive actions.

In plastic surgery training, it is imperative that a large part of the training is conducted in a hands-on setting. Based upon to the principle of pedagogical materialisation there is an importance of being able to apply informational content in a functional and materialistic environment. Pedagogic effectiveness can be increased when the trainee is allowed to process conceptual principles into functional actions. The principle of connecting theory with practice supposes adequate understanding of theories and concepts, but also a wide applicability in the practical field. It is necessary that the trainee is stimulated to develop their own tissue feeling, surgical precision and spatial effectiveness in addition to procedural knowledge. Therefore, we recommend a durable acquisition of knowledge and skills through numerous of practical applications but also through their diversifications.

The relationship between teacher and trainee plays an important role during surgical training. At the moment of assuming some actions with a didactic purpose, both the learning environment and the teacher must allow a re-assessment of a conception. The feeling of being supported in a learning process is more influential than the epistemic structures. A trainee learns through the experiences that the teacher provides, and the acquisition of knowledge is strengthened through constructive feedback in what is perceived as a safe learning environment. The didactic activity should be seen as a continuous process that benefits from feedback through which one can emphasize the understanding and assimilation of the informational content. Adequate communication skills and mutual respect and understanding are essential for this to be successful. For both the teacher and the trainee, regardless of age or gender, recognition is important. Being a teacher bears huge responsibilities with it and should be appreciated accordingly. The teacher helps the trainee to become a competent surgeon, ensuring preservation of what is already known and ongoing patient safety, but also generates career opportunities, space for

groundbreaking research and collective discoveries of what is still unknown.

## Funding

None.

## Declaration of Competing Interest

None declared.

## Ethical approval

Not required.

## Reference

1. Comenius IA. *Didactica magna*. Amsterdam: Impensis D. Laurentii de Geer; 1657.

G. Vissers, T. Tondu, F. Thiessen  
 Department of Plastic, Reconstructive and Aesthetic  
 Surgery, University Hospital Antwerp, Drie Eikenstraat  
 655, B-2650 Edegem, Belgium  
 Faculty of Medicine and Health Sciences, Antwerp  
 University, Universiteitsplein 1, B-2610, Wilrijk, Belgium  
 E-mail address: [ginovissers@doctor.com](mailto:ginovissers@doctor.com) (G. Vissers)

© 2021 British Association of Plastic, Reconstructive and Aesthetic Surgeons. Published by Elsevier Ltd. All rights reserved.

<https://doi.org/10.1016/j.bjps.2021.03.099>

## Women plastic surgeons are overlooked in the new era of webinars



Dear Sir,

The COVID-19 pandemic has greatly affected our clinical work and research since it first emerged in the beginning of 2020. Thankfully, several Plastic Surgery societies have worked tirelessly to continue educational activities to

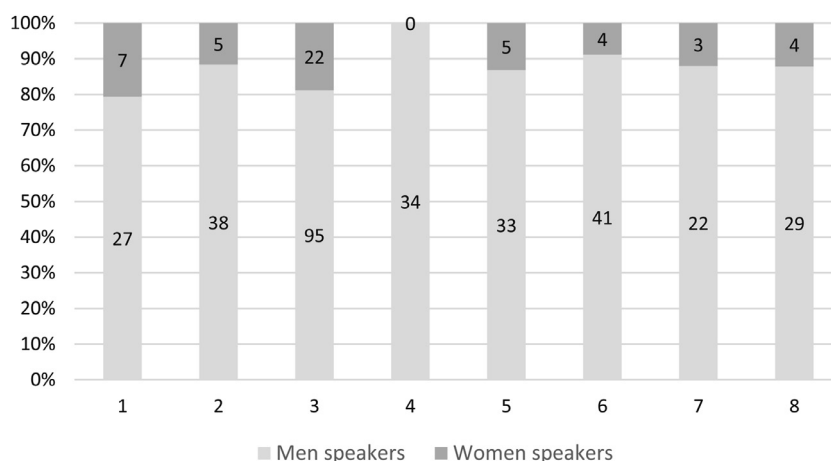
supplement stunted operative and clinical practice with online seminars. These have proven greatly valuable to both residents and consultants, and have enabled a perhaps never-before-seen opportunity to gain knowledge and experience from the world's leading experts. However, if analyzed deeper, one sees an unbalanced breadth of speakers in webinars, where a predominantly male surgeon population is represented. "Where are all our women plastic surgeon experts?", one might ask.

A detailed analysis of eight official plastic surgery webinar and seminar organizers from the UK and abroad reveals a concerning statistic, worth sharing with the wider plastic surgery community. In a total of 234 webinars/seminars from March 2020 to February 2021, women represented 13.5% of speakers (see [Table 1](#)), with an average of 6 women invited per organizer, and with one organizer not having invited any women to the faculty at all (see [Figure 1](#)). This might of course be representative of the actual lower number of female plastic surgery consultants worldwide, although we doubt that the discrepancy is as large as 13.5vs 86.5%. Even so, should this very fact not be the reason for inviting women even more? Arguably, it is more convenient to invite the more regular speakers, and indeed expert knowledge should be delivered by expert surgeons. However, webinars are in fact the perfect platform to diversify both topics and speakers, and find and promote expert women surgeons who perhaps modestly flourish in the shadow of their male counterparts.

This year of 2021 marks 100 years since Sweden first legalized women voting in the national general election (with the UK following shortly thereafter) but only 6 years since the Royal College of Surgeons of England appointed their first female president, and the first year of our first female vice president of the United States. In business, since 2017, the presidencies and most powerful positions on Wall Street (NASDAQ and the New York Stock Exchange) and the European Central Bank have been held by women. Women are clearly achieving in high powered positions across disciplines, but how is it that so many talents go unnoticed, or worse, are lost? In surgery, NHS statistics from 2018 showed a decline in women at senior surgeon level, with 41% women in core surgical training and only 12% women as consultants. On the contrary, male surgeons showed to increase at senior levels, with 59% men in core surgical training and 88% men as consultants.<sup>1</sup> Women at senior surgeon level are only marginally increasing in numbers, with the Royal College of Surgeons stating 13.1% women surgeons in 2020 (a 1.1% increase in 2 years); of which 21% are plastic surgeons.<sup>2</sup> Somewhere along the career pathway men and women diverge in their achievements, but is this the result of a lack in ambition or a lack in opportunity? Silva et al. describe two phenomena that provide great

**Table 1** Detailed information of men and women speakers in relation to number of webinars.

Organizer	1	2	3	4	5	6	7	8	Total	Average
Number of webinars	23	42	36	34	2	43	22	32	234	29
Men speakers	27	38	95	34	33	41	22	29	319	40
Women speakers	7	5	22	0	5	4	3	4	50	6
Invited speakers	34	43	117	34	38	45	25	33	369	46
% Women speakers	20.6%	11.6%	18.8%	0%	13%	9%	12%	12.1%	13.5%	



**Figure 1** Number of Men and Women surgeon speakers at eight official plastic surgery webinar organizers in 2020.

insight.<sup>3</sup> Women do not lack ambition, as evidence supports equal academic achievements in residency. However, a so called “Ambition Gap” seems to strike, where some women fail to progress due to less networking opportunities, fewer official appearances, less institutional support, and fewer female mentors and role models. The second obstacle described is the “Confidence Gap”, and speaks of the unfortunately adverse effect of some women’s overt self-criticism, resulting in suboptimal self-advocacy and arguably less self-exposure to the wider surgical community. Indeed, evidence has shown feedback to women to be less academic and constructive in nature and more personal.<sup>4</sup> Furthermore, male surgeons have not only been found superior at seeking promotions, but also better at rating themselves higher than perhaps their actual merit.<sup>3</sup>

The old surgical “boys club” mentality is on its way out as modern surgical practice teaches anything but arrogance, nepotism and exclusiveness. In that regard, women can and should provide a breath of fresh air in the otherwise hard-to-rock community. There should be no doubt that women surgeons can contribute in the profession, and have in fact been shown to be preferred by patients and have a lower surgical morbidity and mortality rate.<sup>5</sup> Indeed, meritocracy should govern promotion, however as reality shows it is unfortunately not as simple. We still risk inequality unless we change the actual opportunity for merit. This starts by realizing that opportunity needs to be given equally, and efforts need to be made to ensure to enlist those to whom (because of work culture, previous experiences, and/or inherent characteristics) self-promotion does not come easily. As such, Plastic Surgery societies must actively stimulate and endorse a culture where surgeons from all backgrounds and genders are not only inspired to, but importantly also shown it is possible to, achieve greatness.

### Declaration of Competing Interest

None.

### Ethical approval

N/A.

### Funding

None

### References

1. Moberly T. A fifth of surgeons in England are female. *BMJ* 2018;**363**:k4530.
2. Surgeons, R.C. of. Statistics - Women in Surgery. undefined <https://www.rcseng.ac.uk/careers-in-surgery/women-in-surgery/statistics/>.
3. Silva AK, Preminger A, Slezak S, Phillips LG, Johnson DJ. Melting the plastic ceiling. *Plast Reconstr Surg* 2016;**138**:721-9.
4. Furnas HJ, et al. Gender differences in the professional and personal lives of plastic surgeons. *Plast Reconstr Surg* 2018;**142**:252-64.
5. Wallis CJ, et al. Comparison of postoperative outcomes among patients treated by male and female surgeons: a population based matched cohort study. *BMJ* 2017;**359**:j4366.

Eleonora O.F. Dimovska  
Department of Plastic and Maxillofacial Surgery, Uppsala  
University Hospital, Uppsala, Sweden

Nicole A. Zelenski  
Department of Orthopaedic Surgery, Emory University,  
Atlanta, GA, USA

Ebba K. Lindqvist  
Department of Reconstructive Plastic Surgery, Karolinska  
University Hospital, Stockholm, Sweden  
E-mail address: [eleonora.dimovska@akademiska.se](mailto:eleonora.dimovska@akademiska.se) (E.O.F.  
Dimovska)

© 2021 British Association of Plastic, Reconstructive and Aesthetic Surgeons. Published by Elsevier Ltd. All rights reserved.

<https://doi.org/10.1016/j.bjps.2021.03.108>



## Targeted muscle reinnervation for Morton Neuroma: An anatomical study



Dear Sir,

Morton neuroma is a neuropathy of the common digital nerve in the foot.<sup>1</sup> This neuropathy presents itself as a painful sensation most frequently in either the third or the second web space. Surgical treatments consist of nerve decompression, neurolysis, and neurectomy with or without transposition of the nerve in muscle or bone.<sup>2</sup> Neurectomy changes the Morton neuroma from a pseudoneuroma to a true neuroma, potentially resulting in pain as well. In Targeted Muscle Reinnervation (known as TMR) the sensory nerve proximal to a neuroma is sutured to the distal continuation of a transected motor nerve branch. The main goal in performing TMR is to give the nerve a “place to go and something to do”.<sup>3</sup> Studies suggest this reduces neuroma pain after nerve injury, for example after amputation.<sup>4</sup> The aim of our anatomical study is to identify a possible and consistent motor nerve target for targeted muscle reinnervation in the foot.

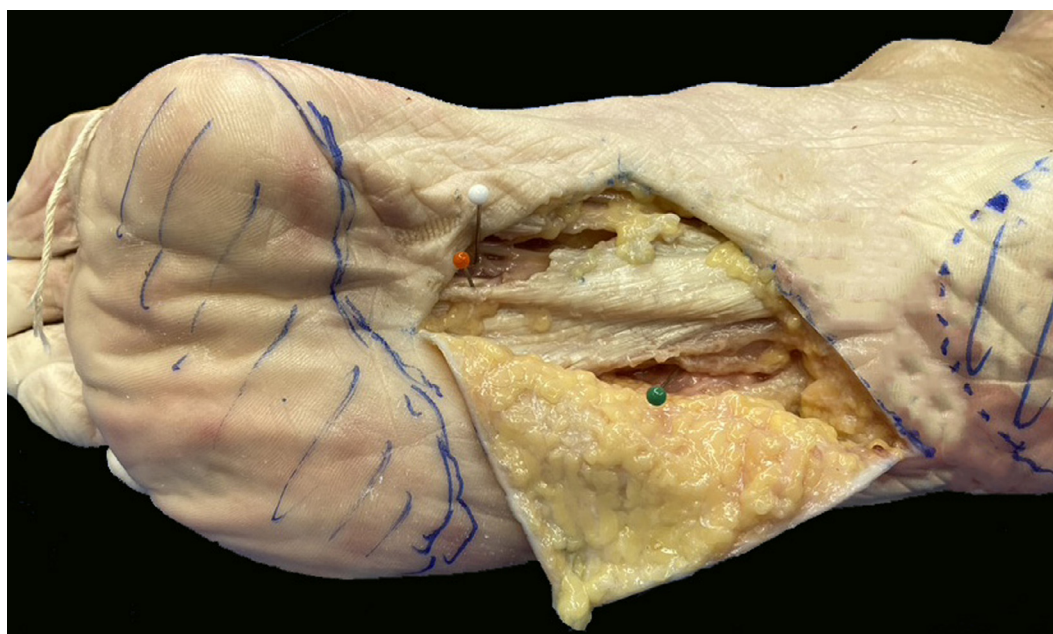
The limbs of five fresh-frozen adult cadavers were used. Dissections were performed by two authors (DDK and TT). Initially, we removed all skin to be able to identify any potential motor nerves. In our final dissection, after identifying consistent nerve anatomy, we refined our dissection

by performing a V-shaped incision in the nonweightbearing part of the foot only, creating a laterally based skin flap including the subcutaneous tissue (Figure 1). We were able to reach all sites of interest through a V-shaped incision placed at the nonweightbearing area of the foot. A good exposure through a plantar incision is important and a previous study in 115 patients treated with a plantar incision showed a 96% satisfaction rate.<sup>5</sup> The plantar fascia is distally partially transected in an oblique direction to be able to visualize the second and third common digital nerves. These nerves lie directly under the plantar fascia and therefore it is key to carefully incise the plantar fascia overlying these nerves. These common digital nerves can be dissected until the metatarsal phalangeal joint is reached and can subsequently be transected. We noticed a slight variation in the location of the bifurcation between the second and third common digital nerves. The location of the bifurcation determines the total length of the transected nerve.

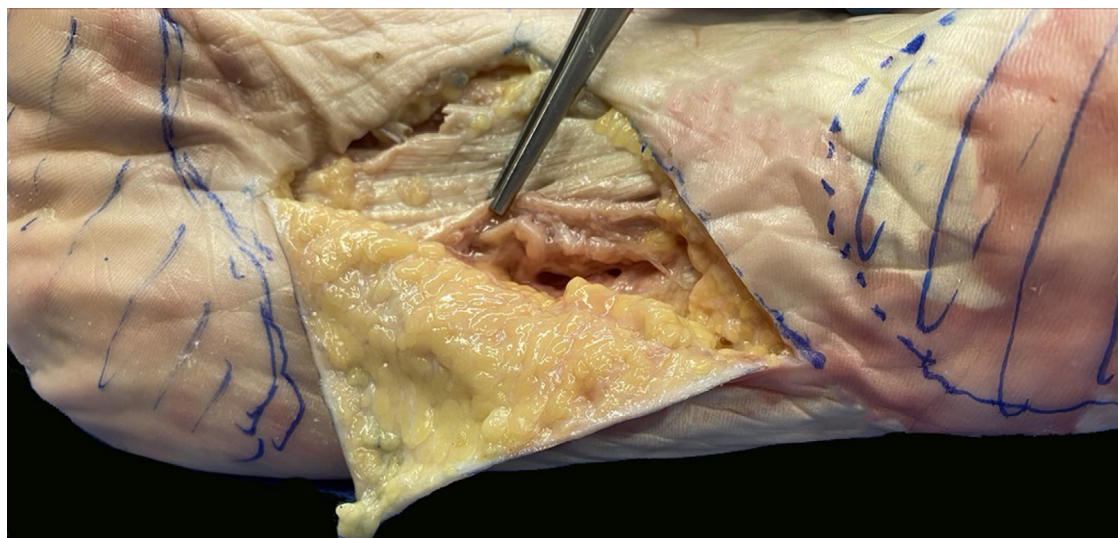
Deep and lateral to the plantar fascia, just lateral to the flexor digitorum brevis muscle, the deep branch of the lateral plantar nerve can be found. The deep plantar branch of the lateral plantar nerve can be transected as proximally as possible to increase the length available and ensure tension-free coaptation (Figure 2). In 3 cadavers a branch of the deep plantar branch was used as a target.

We found two pathways for nerve transposition: (1) under the plantar fascia and (2) under the flexor digitorum brevis musculature. The second, deeper pathway requires greater nerve length and might not always be feasible. It does provide greater tissue padding possibly reducing residual neuroma pain.

Three motor nerve biopsies were sent to pathology to identify the proportion of myelinated nerve fascicles. Taking the strictly sensory sural nerve as a point of reference, our



**Figure 1** Inferior view of a left foot. Brunner incision placed on nonweight bearing are of the foot with a laterally based skin flap exposing the plantar fascia. Partial transection of the plantar fascia distally. White marker: second common digital nerve. Red marker: third common digital nerve. Green marker: Deep branch of the lateral plantar nerve.



**Figure 2** Third common digital nerve transected proximal of the metatarsal phalangeal joint. Transposition of the third common digital nerve through a tunnel under the plantar fascia towards the proximally transected deep branch of the lateral plantar nerve. Coaptation can be performed without any tension (placed superficial for the photograph) and the nerve anastomosis can subsequently be transposed into a deeper plane.

biopsy specimens showed a proportionally high number of myelinated fibers, suggesting that the nerve mainly has a motor function.

Due to the fact that this is an anatomical cadaver study, there are several limitations. First, anatomical structures such as muscles and fascia can be softer and easier manipulated in a fresh frozen cadaver. Secondly, in case a patient has been treated before with a neurectomy, then the total length of the common digital nerve can be expected to be shorter, and TMR may not be feasible. The length of the to be transposed nerve could be increased by separating the common digital nerves by microdissection or by using an autologous or acellular processed nerve interposition graft. Lastly, it is important to note that this is a cadaver study and therefore we do not know if the surgical technique presented in this study reduces the pain in actual patients, nor do we know the effect of transection of the deep plantar branch of the lateral plantar nerve. The deep branch of the lateral plantar nerves innervates the lumbrical and interosseous muscles of the foot and TMR will affect the function of these muscles. The resultant morbidity and long-term consequences are unknown and need to be weighed against pain severity.

We present a potential surgical technique for TMR in patients suffering from treatment resistant pain after Morton neuroma surgery with the deep branch of the lateral plantar nerve as the target nerve. In each cadaver the location of the common digital nerves and the deep branch of the lateral plantar nerve was identical and TMR was feasible without any tension. This study is an anatomical cadaver study and therefore the success rate for pain reduction and the possible morbidity of this technique are unknown.

## Ethics

These specimens were derived from bodies that had entered the Department of Anatomy of the University Medical Cen-

ter Utrecht through a donation program. Written informed consent was obtained from these persons when they were alive.

## Funding

None.

## Declaration of Competing Interest

None declared.

## References

1. Morton TG. A peculiar and painful affection of the fourth metatarsophalangeal articulation. *Am J Med Sci* 1876;**71**:37-45.
2. Jain S, Mannan K. The diagnosis and management of Morton's neuroma: a literature review. *Foot Ankle Spec* 2013;**6**(4):307-17.
3. Fracol ME, Janes LE, Ko JH, Dumanian GA. Targeted muscle reinnervation in the lower leg: an anatomical study. *Plast Reconstr Surg* 2018;**142**(4):541-50.
4. Kuiken TA, Dumanian GA, Lipschutz RD, et al. The use of targeted muscle reinnervation for improved myoelectric prosthesis control in a bilateral shoulder disarticulation amputee. *Prosthet Orthot Int* 2004;**28**:245-53.
5. Faraj AA, Hosur A. The outcome after using two different approaches for excision of Morton's neuroma. *Chin Med J (Engl)* 2010;**123**(16):2195-8.

David D. Krijgh, Teun Teunis, Emile B. List  
Department of Plastic and Reconstructive Surgery,  
University Medical Center Utrecht, Netherlands

Wim Van Hecke  
Department of Pathology, University Medical Center  
Utrecht, Netherlands

Ronald L.A.W. Bleys  
 Department of Anatomy, University Medical Center  
 Utrecht, Netherlands

J. Henk Coert  
 Department of Plastic and Reconstructive Surgery,  
 University Medical Center Utrecht, Netherlands  
 E-mail address: [d.d.krijgh@umcutrecht.nl](mailto:d.d.krijgh@umcutrecht.nl) (D.D. Krijgh)

© 2021 British Association of Plastic, Reconstructive and Aesthetic Surgeons. Published by Elsevier Ltd. All rights reserved.

<https://doi.org/10.1016/j.bjps.2021.05.053>

## Feasibility of a 3D printed nasal model for resident teaching in rhinoplasty



Dear Sir,

Rhinoplasty is one of the more challenging operations performed by facial plastic surgeons. Resident exposure is limited, as there is no standard for hands-on teaching outside of the operating room. The increase in availability and affordability of 3D printed models has led to its use in patient education and intra-operative use.<sup>1-5</sup> We sought to create a 3D printed nasal model for teaching various rhinoplasty techniques.

A representative CT scan of the nasal cavity was chosen to create a model suitable for sinonasal anatomy education.

This work was presented as a poster at the American Academy of Facial Plastic and Reconstructive Surgery (AAFPRS) Virtual Annual Meeting in September 2020.


The scan was performed using a Somatom Force multi-row detector array CT machine (Siemens, Erlangen, Germany) in helical mode with 1 mm contiguous slice reconstruction and z axis range of 1 cm below the mandible to 1 cm above the vertex. Advanced Model Iterative Reconstruction (ADMIRE, SIEMENS, Siemens Health Care) was used for noise reduction. Other technical factors included pitch of 0.531, peak energy of 120 kVp), and index current of 60 mA.

Aquarius Intuition (TeraRecon AI, Redlands, CA) was used to post process the DICOM files. Smoothing algorithms, sub-voxel resampling, and interpolation techniques were utilized to achieve an effective isometric voxel resolution of 50  $\mu\text{m}$  thus improving the quality of the subsequent segmentation of pertinent anatomy using semi-automated and manual region of interest selection. The septum, inferior turbinates, nasal bones, upper lateral cartilages, and lower lateral cartilages and their interfaces were segmented. A deidentified surface rendering was then exported into a standard tessellation language (.stl) file.

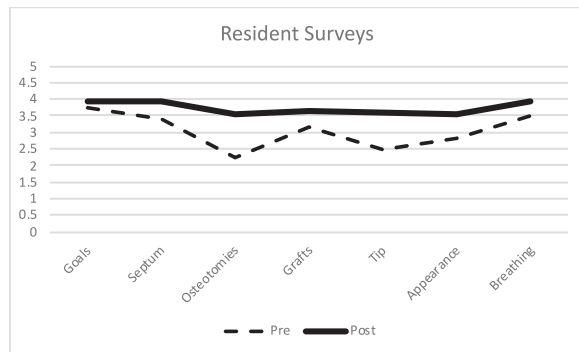
Meshmixer (Autodesk, San Rafael, CA) and Rhinoceros 3D (Robert McNeel & Associates, Seattle, WA) were used for mesh repair and smoothing to improve suitability for printing (Fig. 1). Stereolithography printing of the model was performed using a Form 3D Printer (FormLabs, Somerville, MA) with a photosensitive, translucent methacrylate polymer. The finest resolution of 50  $\mu\text{m}$  per layer was utilized for printing purposes.

The study was approved by both the Intuitional Review Board (IRB) as well as the office of Graduate Medical Education (GME). The model was integrated into the resident curriculum of the Otolaryngology department at the University of Kentucky. The model was used as a hands-on model during a lecture on rhinoplasty given by a fellowship-trained facial plastic surgeon where residents answered anatomical questions, with the model serving as a visual reinforcement. This lecture was given 5 months after the routine bi-annual facial plastic and reconstructive surgery education series and at the end of the academic year.

Both prior to and immediately after the session, the residents were given a questionnaire. They were asked if they were a junior resident (PG1-3) or senior resident (PGY4-5).



**Fig. 1** Anterior oblique view of computer-aided design of 3D model of sinonasal anatomy. NB - Nasal Bone; ULC - Upper Lateral Cartilage, LLC - Lower Lateral Cartilage.



**Fig. 2** Rhinoplasty knowledge in residents both prior to and after an educational session with a 3D printed model of sinonasal anatomy.

Additionally, they were asked to approximate how many cases they had served as a 1) resident assistant surgeon, 2) resident surgeon, and 3) resident supervisor. They then answered a 7-questionnaire survey on a 5-point Likert scale addressing their familiarity with the goals of rhinoplasty, approach to the septum, osteotomies, grafts, and changes to the tip, appearance, and nasal airway. Surveys were administered anonymously, and no identifiable information was included.

A total of 12 participants were included in the study with 50% (6/12) being junior residents (PGY1-3) and 50% (6/12) being senior residents (PGY4-5). The data showed that junior residents had minimal experience as resident surgeon (range 0-5 total cases) while having some exposure to rhinoplasty in the form of a resident assistant (range 3-15 total cases). In contrast, senior residents had more exposure to rhinoplasty both as the resident surgeon performing the rhinoplasty (range 0-20) as well as experience as a resident assistant (range 3-20). No residents listed experience as resident supervisor for this procedure. Furthermore, both junior and senior residents demonstrated improvement in knowledge across all categories assessed, with the greatest improvement in knowledge in both groups being in the categories they scored the lowest prior to the intervention (Fig. 2). Additionally, both the junior and senior residents seemed to have the least knowledge with respect to osteotomies, changes to the nasal tip as the result of surgery, and how surgery would affect the outward appearance of the nose after surgery.

The results from our study demonstrate that a 3D model of patient anatomy can feasibly be used in the field of facial plastic surgery to educate residents about the relevant anatomy for a rhinoplasty. This model demonstrates anatomic features of the septum, inferior turbinates, nasal bones, upper lateral cartilages, and lower lateral cartilages and their interactions. It can demonstrate septal reconstruction, osteotomies, grafting (spreader, alar, tip), and tip work. This study demonstrates the feasibility of using a 3D printed nasal model for teaching rhinoplasty to resident learners.

## Declaration of Competing Interest

None declared.

## Authorship

All authors have met the guidelines listed for authorship.

## Acknowledgments

None.

## Funding

None.

## Ethical approval

University of Kentucky Institutional Review Board 56063.

## References

1. Suszynski MT, Serra MJ, Weissler MJ, et al. Three-dimensional printing in rhinoplasty. *Plast Reconstr Surg* 2018;141:1383-5.
2. Codazzi D, Bruschi S, Mazzola RF, Bocchiotti MA, Bogetti P, Ortelli L, Robotti E. Bergamo 3D rhinoplasty software: select, store, and share surgical maneuvers in a three-dimensional nasal model. *Plast Reconstr Surg* Feb 2016;137(2):313e-317e.
3. Chae MP, Rozen WM, McMenamin PG, et al. Emerging applications of bedside 3D printing in plastic surgery. *Front Surg* 2015;2:25 - 25.
4. Kamali LP, Dean AD, Skoracki SR, et al. The current role of three-dimensional printing in plastic surgery. *Plast. Reconstr. Surg.* 2016;137:1045-55.
5. Fried G, Feldman L. Objective assessment of technical performance. *World J Surg* 2008;32:156-60.

Nikita Gupta, Casey M. Fitzgerald  
University of Kentucky Department of  
Otolaryngology-Head and Neck Surgery, Division of Facial  
Plastic and Reconstructive Surgery USA

Mohamed Tarek Ahmed  
University of Kentucky, Department of Radiology USA

Siavash Tohidi  
University of Kentucky, School of Art and Visual Studies  
USA

Michael Winkler  
University of Kentucky, School of Art and Visual Studies  
USA

Augusta University, Department of Radiology USA  
E-mail address: [nikita.gupta@uky.edu](mailto:nikita.gupta@uky.edu) (N. Gupta)

© 2021 British Association of Plastic, Reconstructive and Aesthetic Surgeons. Published by Elsevier Ltd. All rights reserved.

<https://doi.org/10.1016/j.bjps.2021.05.071>

# Response to: Preoperative perforator mapping: Accuracy, bias, concordance and the devil



Dear Sir,

We thank the authors for their interest in our paper, and regret failing to include their well-formulated and written

article in our review.<sup>1-3</sup> Surprisingly their article was not captured in our original searches, rather than being excluded later in abstract or article screening.

It is not entirely clear why our search failed to capture this manuscript and having re-run the searches with further advice from information specialists, we can confirm that this article still does not appear. Glandular Surgery is indexed in the databases we searched and the terms we used should have captured both the keywords used, as well as compatible text within the title and abstract. Although there are discrepancies in the spelling of the word mammoplasty (Glandular Surgery assigned the keyword “mammoplasty” whilst our strategy used “mammoplasty”, which we could have anticipated and ameliorated

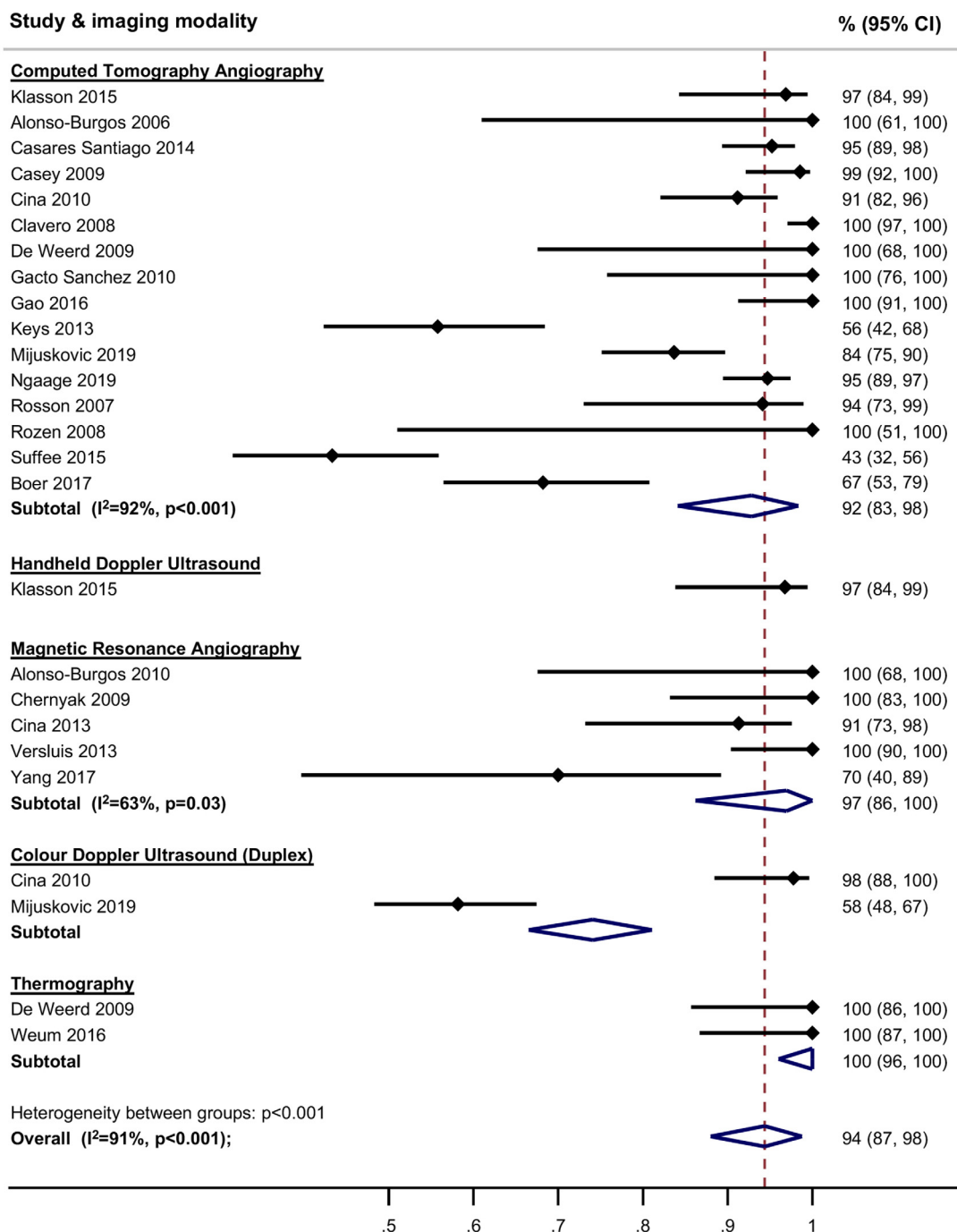


Figure 1 .

with the term “mamm#plasty”); however, altering this term still does not capture the article. In addition, their keywords do not include ‘Breast Reconstruction’ or ‘DIEP/Deep Inferior Epigastric Perforator’, which might have aided capture in reviews of microsurgical breast reconstruction. This illustrates the importance of keywords when publishing within the rapidly expanding scientific literature, and standardisation of spellings/terms given their impact on search engine retrieval.<sup>4</sup> Furthermore, this article does not appear in the reference lists of the included articles so backward citation chasing did not identify it either.

However, since the publication of our review an automated tool called CitationChaser has been released. This tool might have captured the article based on forward citation chasing and we commend it to readers who perform evidence synthesis.<sup>5</sup>

While systematic review aims to capture the relevant literature, in practice even the most rigorous methods may still fail to capture relevant works. None-the-less, we are delighted that Boer and colleagues brought this omission to our attention and equally, we are pleased to re-do our meta-analysis with the benefit of their article (Figure 1). Based on the updated synthesis, we can confirm that the addition of their valuable work does not change our conclusion.

## Ethical approval

N/A

## Declaration of Competing Interest

None.

## Funding

Ryckie Wade is supported by the National Institute for

Health Research (NIHR) in Leeds (DRF-2018-11-ST1-159). The views expressed are those of the author(s) and not necessarily those of the NIHR or the Department of Health and Social Care.

## References

1. Boer V, Jv Wingerden. Preoperative perforator mapping: accuracy, bias, concordance and the devil. *J Plastic, Reconstruct Aesthetic Surgery* 2021;0(0). doi:10.1016/j.bjps.2021.03.040.
2. Kiely J, Kumar M, Wade R. The accuracy of different modalities of perforator mapping for unilateral DIEP flap breast reconstruction: a systematic review and meta-analysis. *J Plastic, Reconstruct Aesthetic Surgery* 2020 12/10/2020. doi:10.1016/j.bjps.2020.12.005.
3. Boer V, Jv Wingerden, Wever C, et al. Concordance between preoperative computed tomography angiographic mapping and intraoperative perforator selection for deep inferior epigastric artery perforator flap breast reconstructions. *Gland Surg* Dec 2017;6(6). doi:10.21037/gs.2017.09.13.
4. Ruffell D. Writing a great abstract: tips from an Editor. *FEBS Letters* Jan 2019;593(2). doi:10.1002/1873-3468.13304.
5. Haddaway NR, Grainger MJ, Gray CT. citationchaser: an R package and Shiny app for forward and backward citations chasing in academic searching. 2021; doi:10.5281/zenodo.4543513.

John R. Kiely  
Sheffield Teaching Hospitals NHS Foundation Trust,  
Wakefield, United Kingdom

Ryckie G. Wade  
Leeds Institute for Medical Research, The University of  
Leeds, Leeds, UK | Leeds Teaching Hospitals NHS Trust,  
United Kingdom  
E-mail address: johnkiely@nhs.net (J.R. Kiely)

© 2021 British Association of Plastic, Reconstructive and Aesthetic Surgeons. Published by Elsevier Ltd. All rights reserved.

<https://doi.org/10.1016/j.bjps.2021.05.058>