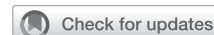

## Rationale and surgical strategy for concomitant tricuspid repair



Joanna Chikwe, MD, FRCS, and Dominick Megna, MD

**Feature Editor's Note**—The tricuspid has oft been the forgotten valve. When it comes to intervention for secondary tricuspid regurgitation (TR), the approach has historically been conservative, with the expectation that TR would reverse with correction of mitral regurgitation. Growing evidence has shown that late symptomatic heart failure can develop secondary to residual TR after isolated mitral valve surgery for degenerative disease and that late TR is prevalent in these patients upon long-term follow-up. Recently, a more aggressive stance toward concomitant repair of the tricuspid valve at the time of mitral valve surgery for degenerative disease has been proposed, with guidelines from the American Heart Association/American College of Cardiology and European Society of Cardiology that support tricuspid repair based on the severity of TR and/or tricuspid annular size. Evolution of repair techniques from suture annuloplasty to remodeling annuloplasty with semi-rigid or rigid devices has also led to greater durability of the repair. In this issue of the *Journal*, Drs Chikwe and Megna review the evidence supporting concomitant tricuspid repair at the time of mitral valve surgery for degenerative disease and describe the key anatomic and physiologic changes that mediate secondary TR. The authors offer a robust discussion regarding the types of surgical repair strategies and their relative strengths and weaknesses. While catheter-based valvular interventions are gaining momentum for left-sided valvular lesions, devices for tricuspid repair remain in their infancy and their relative role for correction of secondary TR remains small. For the practicing cardiac surgeon, these authors provide a framework with the when, why, and how to manage the tricuspid valve at the time of mitral valve surgery for degenerative disease.

**Leora B. Balsam, MD**


From the Department of Cardiac Surgery, Smidt Heart Institute, Cedars-Sinai Medical Center, Los Angeles, Calif.

Received for publication May 7, 2020; revisions received May 7, 2020; accepted for publication May 27, 2020; available ahead of print July 22, 2020.

Address for reprints: Joanna Chikwe, MD, FRCS, Department of Cardiac Surgery, Smidt Heart Institute, Cedars-Sinai Medical Center, Beverly Hills, Los Angeles, CA 90048 (E-mail: [Joanna.chikwe@cshs.org](mailto:Joanna.chikwe@cshs.org)).

JTCVS Open 2020;3:52-61  
2666-2736

Copyright © 2020 The Authors. Published by Elsevier Inc. on behalf of The American Association for Thoracic Surgery. This is an open access article under the CC BY-NC-ND license (<http://creativecommons.org/licenses/by-nc-nd/4.0/>).  
<https://doi.org/10.1016/j.xjon.2020.05.009>



Joanna Chikwe MD, FRCS, and Dominick Megna MD

### CENTRAL MESSAGE

Concomitant tricuspid ring annuloplasty prevents moderate-to-severe tricuspid regurgitation, which otherwise occurs in a 25% to 30% of patients after isolated mitral repair.

See Commentaries on pages 62 and 64.

Secondary or functional tricuspid regurgitation is commonly seen in the settings of right ventricular dilation or dysfunction, pulmonary hypertension, and left-heart dysfunction and is characterized by structurally normal tricuspid valve leaflets and subvalvular apparatus.<sup>1,2</sup> In the 1960s, observations that functional tricuspid regurgitation sometimes improved after mitral surgery led Braunwald and colleagues<sup>3</sup> to recommend conservative management of functional tricuspid regurgitation, which remained the accepted approach for decades. Although Carpentier and colleagues<sup>4</sup> stated in 1974 that a conservative approach to concomitant tricuspid repair could be “dangerous,” it took another decade for the impact of severe heart failure due to tricuspid regurgitation years after isolated mitral surgery and the high mortality associated with reoperative tricuspid surgery to be widely recognized.<sup>1,2,5</sup> Current consensus guideline recommendations recommend concomitant tricuspid valve repair at time of degenerative mitral repair for moderate tricuspid regurgitation or tricuspid annular dilatation (Table 1), based on superior long-term clinical and echocardiographic outcomes with this strategy and evidence suggesting that a conservative approach is associated with residual and recurrent moderate-to-severe tricuspid regurgitation rates as high as 30% at 5 years.<sup>1,2</sup>

**TABLE 1. Current consensus guideline recommendations for concomitant tricuspid repair from the American Heart Association/American College of Cardiology (AHA/ACC) and the European Society of Cardiology (ESC)**

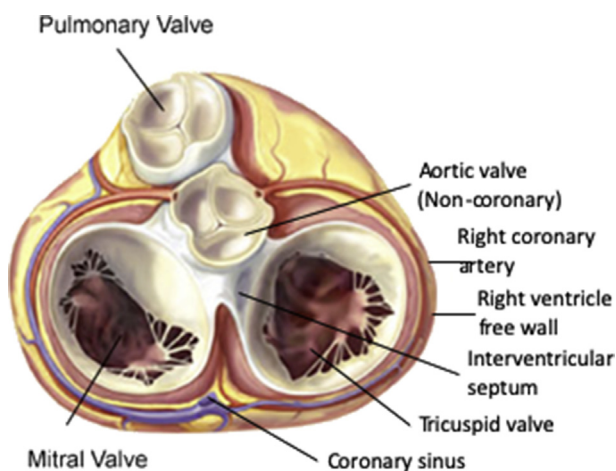
AHA/ACC guidelines	ESC guidelines
Tricuspid valve surgery is recommended for patients with <b>severe TR</b> undergoing left-sided valve surgery. Class I (Level of Evidence C)	Surgery is indicated in patients with <b>severe secondary TR</b> under-going left-sided valve surgery. Class I (Level of Evidence C)
Tricuspid valve repair can be beneficial for patients with <b>mild, moderate, or greater functional TR</b> at the time of left-sided valve surgery with either (1) <b>tricuspid annular dilatation</b> or (2) previous evidence of <b>right heart failure</b> . Class IIa (Level of Evidence B)	Surgery should be considered in patients with <b>mild or moderate secondary TR with a dilated annulus (&gt;40 mm or &gt;21 mm/m<sup>2</sup> by 2-dimensional echocardiography)</b> undergoing left-sided valve surgery. Class IIa (Level of Evidence C)
Tricuspid valve repair may be considered for patients with <b>moderate functional TR</b> (stage B) and <b>pulmonary artery hypertension</b> at the time of left-sided valve surgery Class IIb (Level of Evidence C)	Surgery may be considered in patients undergoing left-sided valve surgery with <b>mild or moderate secondary tricuspid regurgitation</b> even in the absence of annular dilatation when previous recent <b>right-heart failure</b> has been documented. Class IIb (Level of Evidence C)

TR, Tricuspid regurgitation.

There remains controversy and wide practice variation in the approach to concomitant tricuspid repair.<sup>6-10</sup> The aim of this review is to provide a concise account of the rationale and optimal surgical technique for concomitant tricuspid repair based on current evidence.

### SURGICAL TRICUSPID VALVE ANATOMY

The tricuspid valve annulus is saddle-shaped and characterized by the lack of a fibrous skeleton: consequently, it is very flexible, distensible, and fragile. The anterior annulus is in close proximity to 3 structures at risk during annuloplasty: the right and noncoronary sinuses of the aortic root at about 10'o clock, the right coronary artery as it runs in the atrioventricular groove between 11 and 2'o clock, and the atrioventricular conduction tissue, which lies in close proximity to the anteroseptal commissure at 7'o clock (Figures 1 and 2). The septal annulus is supported by the musculature of the interventricular septum and is least subject to dilation, which disproportionately affects the posterior and anterior annulus<sup>11</sup> (Figure 3).



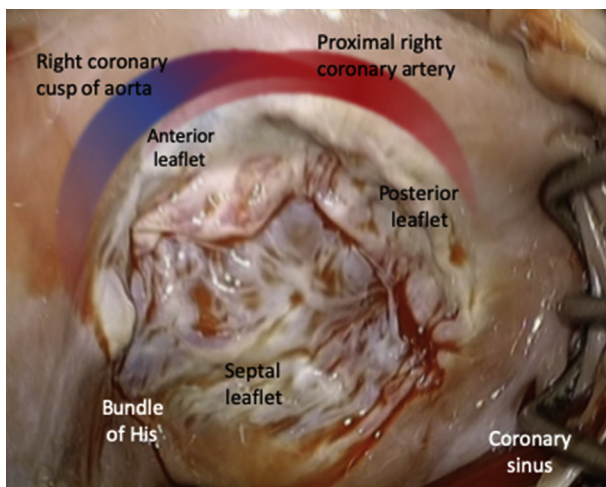
**FIGURE 1.** Cross-section of heart showing anatomic relationships of the tricuspid valve. (With permission from Carpentier A, Filsooufi F, Adams D. *Carpentier's Reconstructive Valve Surgery*. Philadelphia: Saunders; 2010).

Annuloplasty rings are therefore deliberately designed as incomplete rings, to facilitate remodeling annuloplasty of the anterior and posterior annulus while avoiding suture placement in the region of conduction tissue and bundle of His.

### PATHOPHYSIOLOGY OF SECONDARY TRICUSPID REGURGITATION

Three factors contribute to functional tricuspid regurgitation: tricuspid annular dilatation, right ventricular dysfunction and dilatation, and pulmonary hypertension. Echocardiographic analysis has suggested that functional tricuspid regurgitation is most strongly associated with tricuspid annular dilatation, whereas pulmonary hypertension and right ventricular dilatation are weaker predictors of functional tricuspid regurgitation.<sup>12</sup> However, recent data in a long-term surgical cohort suggest that preoperative tricuspid regurgitation grade is a more important predictor of postoperative tricuspid regurgitation after degenerative mitral repair than annular dilatation.<sup>13</sup> Three-dimensional echocardiography in patients with functional tricuspid regurgitation reveals that the annulus tends to be dilated and flatter, with abnormal annular contraction, compared with the normal saddle-shaped annulus.<sup>14</sup> A key part of surgical strategy is therefore correcting tricuspid annular dilatation with a remodeling annuloplasty that restores the 3-dimensional annular geometry and corrects annular dilatation.

Elevated left atrial pressures in patients with advanced left-sided heart disease are transmitted to the lungs, causing pulmonary hypertension and right ventricular pressure overload, eventually with permanent pulmonary vascular remodeling. This can result in tricuspid regurgitation either directly, or indirectly as a result of right ventricular dilatation and leaflet tethering, which are predictive of functional tricuspid regurgitation severity.<sup>15</sup> Consequently, in order for isolated mitral repair to reduce or eliminate tricuspid regurgitation, reverse remodeling of both the dilated right ventricle and pulmonary vascular is needed, which takes months to years and may not occur in the presence of



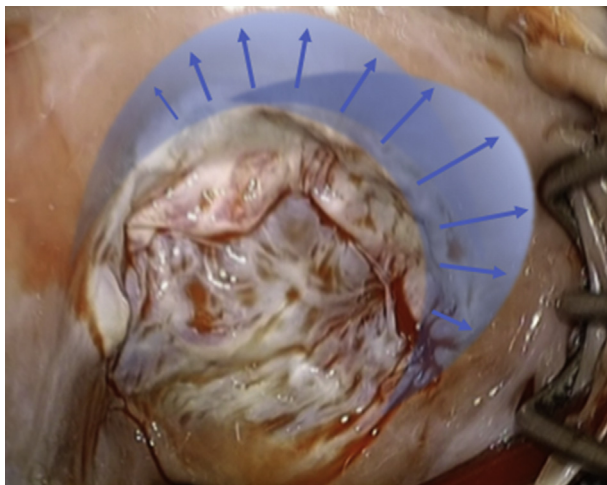
**FIGURE 2.** Surgical anatomy of the tricuspid valve, viewed through a right atriotomy (the superior and inferior vena cava orifices lie to the *lower left* and *right* of the image, respectively).

residual tricuspid regurgitation, or residual left-sided ventricular dysfunction or valve lesions.

Finally, septal leaflet tethering may contribute to tricuspid regurgitation even in the absence of right ventricular dysfunction or pulmonary hypertension.<sup>16</sup> The mechanism may be due to left ventricular dysfunction, since the ventricles are interdependent at the septum, and left ventricular septal dysfunction also causes dysfunction of the septal wall of the right ventricular septum where the papillary muscles and chordae to the tricuspid valve septal leaflet arise.

### RATIONALE FOR CONCOMITANT TRICUSPID REPAIR

Concomitant tricuspid repair confers both prognostic and symptomatic benefit in patients with severe tricuspid



**FIGURE 3.** Annular dilatation predominantly affects the anterior and posterior annulus.

regurgitation documented on preoperative or intraoperative echocardiography.<sup>1,2</sup> Given the dynamic nature of tricuspid regurgitation, the absence of severe tricuspid regurgitation on pre-bypass transesophageal echocardiography should not necessarily change the intent to perform concomitant tricuspid repair if severe tricuspid regurgitation was documented on preoperative echocardiography. This is because severe tricuspid regurgitation is usually associated with right ventricular dysfunction and dilatation and is unlikely to see significant and sustained improvement with isolated mitral repair. The role of concomitant tricuspid repair in the setting of moderate or lesser degrees of tricuspid regurgitation is less clear cut: the primary goal is to prevent progression in those patients at increased risk of severe tricuspid regurgitation.

### Course of Untreated Tricuspid Regurgitation

Moderate-to-severe tricuspid regurgitation is very common after isolated mitral valve surgery, even in patients with mild or no tricuspid regurgitation at baseline.<sup>17-19</sup> It is associated with worse right-sided remodeling, functional outcomes, and survival.<sup>17-19</sup> One of the first large, retrospective studies to demonstrate the impact of a conservative approach to concomitant tricuspid surgery showed that the prevalence of moderate or severe tricuspid regurgitation in 5-year follow-up after isolated degenerative mitral repair was close to 30%, compared with 16.5% at baseline.<sup>17</sup> More recently, David and colleagues<sup>19</sup> reported moderate or severe tricuspid regurgitation rates of 21% in 20-year follow-up, compared with 4% at baseline. Moderate tricuspid regurgitation is associated with significantly worse survival: in a series of 5223 patients followed over 10 years, greater mortality was observed in patients with moderate tricuspid regurgitation compared with mild or, no regurgitation, even after adjusting for pulmonary hypertension and left and right ventricular dysfunction.<sup>20</sup> About one half of the patients who develop severe tricuspid regurgitation report symptoms of heart failure.<sup>1</sup> The mortality of reoperative tricuspid valve surgery is relatively high and associated with a high rate of persistent or recurrent heart failure and continued elevated risk of death.<sup>21</sup> Surgery and increasingly transcatheter repair may be offered to these patients, but the impact on survival and even symptoms at this late stage is unpredictable. Concomitant tricuspid repair has been associated with significantly better functional outcomes in patients compared with those undergoing isolated mitral repair.<sup>22</sup> Improved right ventricular remodeling and freedom from right ventricular dysfunction and pulmonary hypertension have also been associated with concomitant tricuspid repair compared with isolated mitral repair.<sup>22</sup>

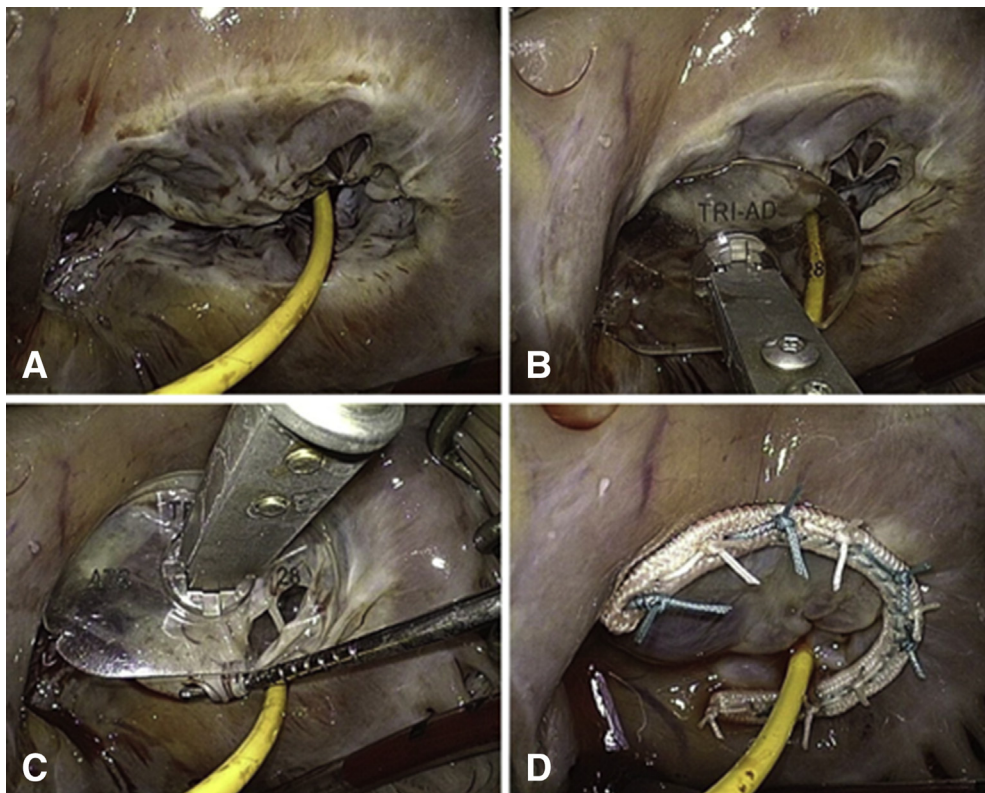
### Annular Dilatation as an Indication for Tricuspid Repair

Functional tricuspid regurgitation is highly dynamic and may vary widely in the same patient depending on volume loading and hemodynamic conditions.<sup>1</sup> Specifically, tricuspid regurgitation may be downgraded in fasted patients under general anesthesia, so the pre-bypass transesophageal echocardiogram can be less reliable measure of tricuspid regurgitation than preoperative transthoracic echocardiography. This is one reason why assessment of annular dilatation is an important factor in the decision to perform concomitant tricuspid repair. Carpentier first described direct intraoperative assessment of annular dilatation by comparing the tricuspid leaflet surface area with the diameter of the annulus (Figure 4).<sup>4,26</sup> This approach was popularized by Dreyfus and colleagues,<sup>18</sup> who assessed tricuspid annular dilatation by direct intraoperative measurement, with a threshold for repairing of >70 mm in a flaccid heart. They subsequently acknowledged that this threshold may be too high, since one third of patients below this threshold developed moderate or severe tricuspid regurgitation during follow-up. The current consensus guideline echocardiographic threshold for significant tricuspid annular dilatation of an end-diastolic diameter of 40 mm

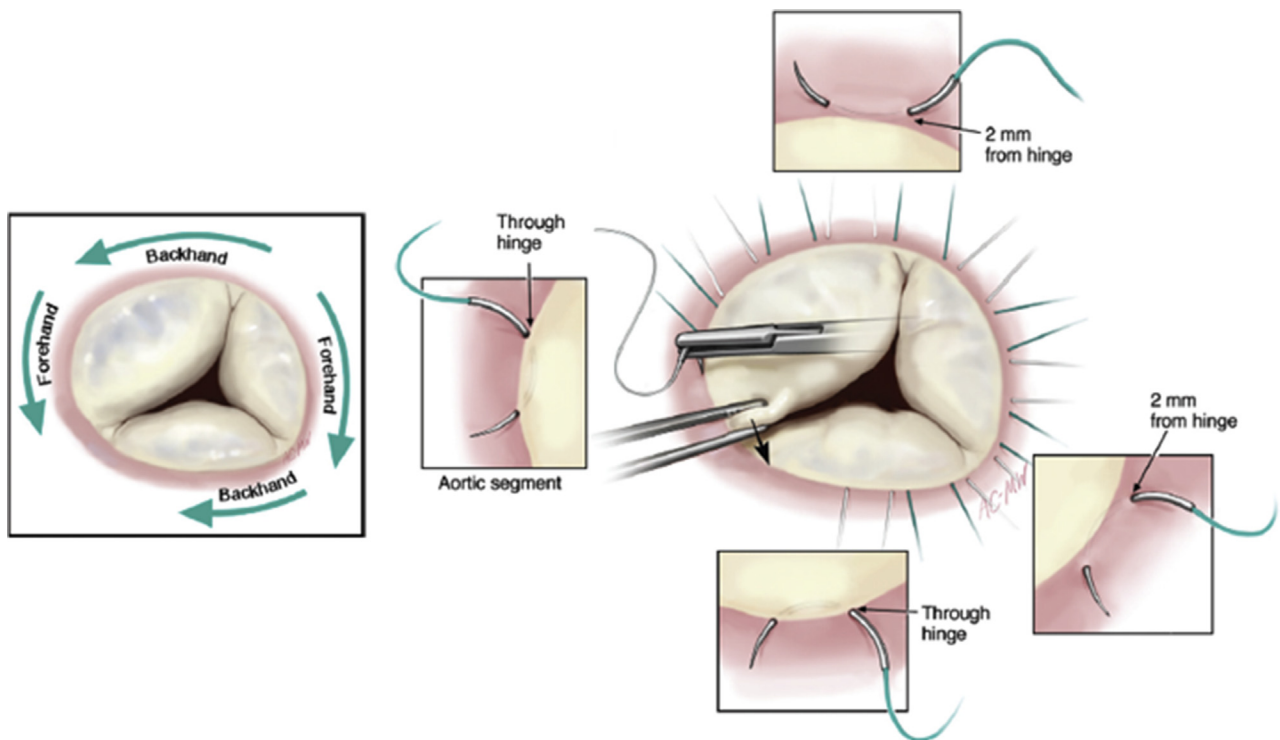
(or >21 mm/m<sup>2</sup>) in the 4 chamber transthoracic view is somewhat arbitrary but supported by several retrospective series.<sup>1,2</sup> Three-dimensional echocardiography is probably a more accurate method of assessing dilatation of the tricuspid annulus.<sup>23</sup>

### SURGICAL TECHNIQUES FOR TRICUSPID VALVE REPAIR

Concomitant repair is most easily performed via an oblique right atriotomy on the arrested heart before mitral or aortic valve reconstruction, with direct bicaval cannulation and caval snares or vacuum-assisted venous drainage. The right atrium can be very fragile, and the risk of tearing into the atrioventricular groove is minimized by starting the atriotomy incision well away from the groove and avoiding aggressive retraction. As long as there is no patent foramen ovale or atrial septal defect, tricuspid repair can also safely be performed on the beating heart without the crossclamp to minimize ischemia time, although greater care with suture placement is required to avoid annular tears (Figure 5). Vacuum-assisted venous drainage removes the need to snare the vena cavae. The pulmonary artery catheter may be retracted to one side or temporarily placed in the right atrium to facilitate suture placement.



**FIGURE 4.** Intraoperative assessment of annular dilatation and selection of annuloplasty ring size: comparing the leaflet surface area with a tricuspid valve sizer. A, Surgeons view of tricuspid valve. B, Tricuspid valve sizer compared with annular dimension showing dilatation. C, Tricuspid valve sizer compared with surface area of anterior leaflet. D, Competent saline test after tricuspid ring annuloplasty (With permission from Milla and colleagues.<sup>26</sup>)



**FIGURE 5.** Suture technique for tricuspid annuloplasty. Directing the needle through the annulus toward the ventricle ensures bites have maximum strength and minimizes risk of sutures impinging on aortic root and right coronary artery. (With permission from Carpentier A, Filsoufi F, Adams D. *Carpentier's Reconstructive Valve Surgery*. Philadelphia: Saunders; 2010)


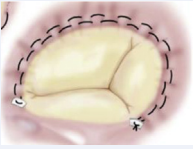



There are 2 main approaches to repair of tricuspid regurgitation: ring annuloplasty and suture annuloplasty (most commonly DeVega repair) (Table 2).<sup>22-24,36</sup> Both techniques aim to correct and prevent anterior and posterior annular dilatation, and avoid suture placement in the region of conduction tissue to minimize the risk of heart block. Ring annuloplasty, where the annulus is remodeled or permanently fixed in a systolic position by suturing in a rigid or semi-rigid ring, has been associated with significantly greater durability of tricuspid repair compared with suture annuloplasty, where the annulus size is reduced by using a continuous suture to “purse string” the annulus (Figure 6, A).<sup>24</sup> The purse-string is prone to cutting out of the fragile annulus and associated with high rates of residual and recurrent tricuspid regurgitation. Simple horizontal mattress sutures are placed close together, approximately 1 cm wide, 2 to 3 mm deep, and 1 to 2 mm outside the hinge-point between the leaflet and the atrial wall. The DeVega suture annuloplasty is usually performed with a running suture taken from the septal annulus just above the coronary sinus, to the anteroseptal commissure and back again with a distance of about 5 mm between the 2 arms, and buttressed at the far ends with pledgets.

Choice of approach is ideally tailored to the severity of tricuspid regurgitation (Table 2). Mild tricuspid regurgitation can effectively be treated with reduction annuloplasty

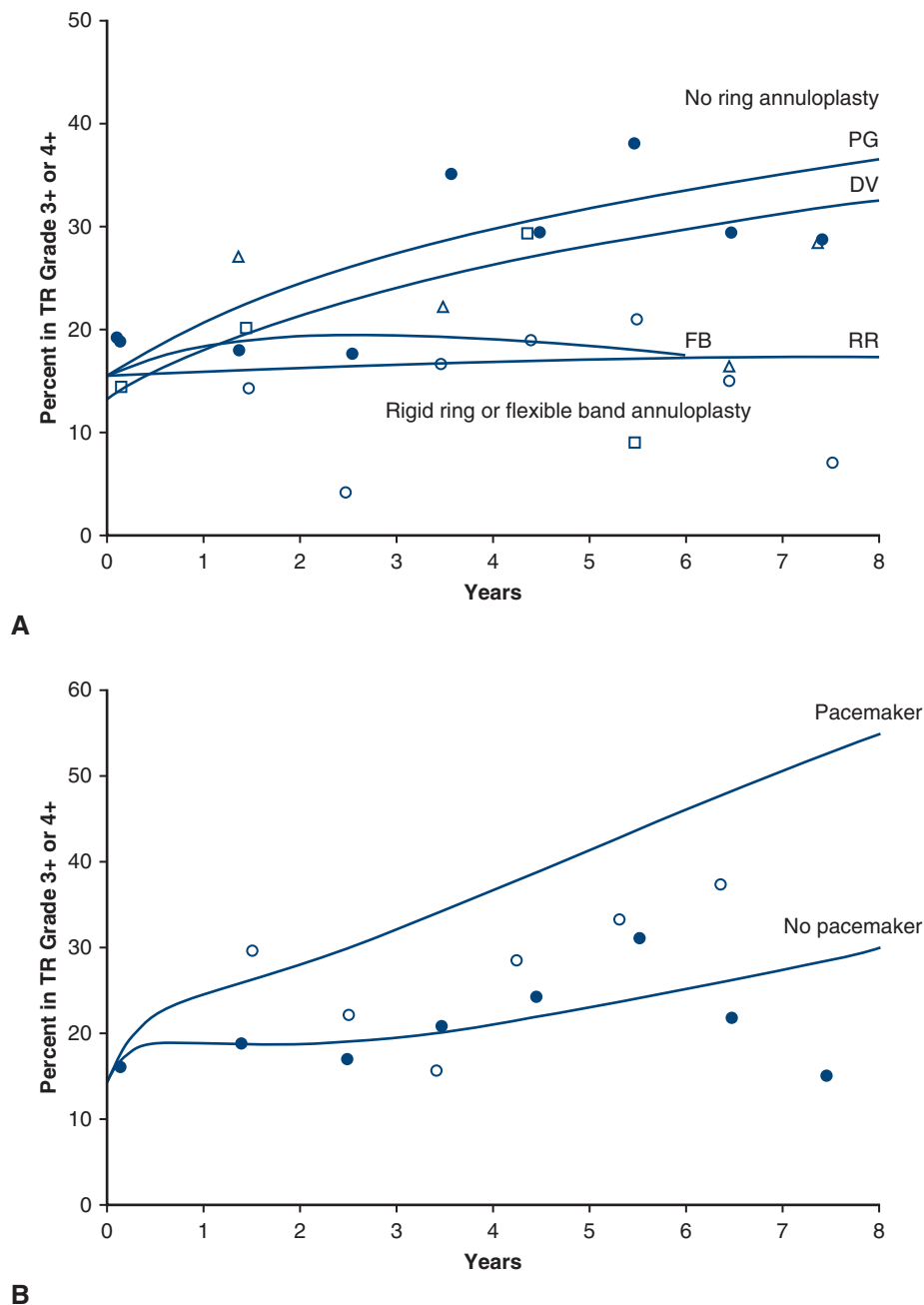
using a flexible band such as the Cosgrove-Edwards Annuloplasty Band (Edwards Lifesciences, Irvine, Calif), or semi-rigid rings such as the Tri-Ad (Medtronic, Carlsbad, Calif) or Carpentier-Edwards Physio Tricuspid ring (Edwards Lifesciences). Severe tricuspid regurgitation is most effectively treated with remodeling annuloplasty using a rigid ring such as the Carpentier Classic (Edwards Lifesciences) or Edwards MC3 (Edwards Lifesciences) ring. Data from the surgical literature suggest that up to 95% of patients having a ring annuloplasty will be free from moderate or severe tricuspid regurgitation years after surgery.<sup>2</sup> Rigid ring annuloplasty has been associated with dehiscence, and semi-rigid rings have been used in an attempt to reduce the risk of this complication.<sup>24,25</sup>

Ring annuloplasty can be easily sized by comparing the septal annulus, and then the anterior and posterior leaflet surface area to a sizer (Figure 4)<sup>26</sup>; however, a size 28 annuloplasty consistently achieves a good result in most patients. Adjunctive leaflet repair techniques such as Gore-Tex neochordae (W.L. Gore & Assoc, Inc, Flagstaff, Ariz) to correct prolapse, and closure of large fenestrations and gaps between leaflets are occasionally necessary to achieve a competent repair. Leaflet patch augmentation may be required to achieve a competent and durable repair when there is substantial leaflet tethering. Permanent epicardial pacing wires or right ventricular leadless pacemakers

TABLE 2. Comparison of annuloplasty techniques for functional TR

Annuloplasty technique	Reduction annuloplasty			Remodeling annuloplasty	
	Bicuspidization	DeVega	Flexible band	Semi-rigid ring	Rigid ring
	Suture	Suture	Band	Ring	Ring
Prostheses					
Indication	Limited	Mild TR	Mild TR	Mild-moderate TR	Moderate-severe TR
Annular stabilization	Posterior	Anteroposterior	Anteroposterior	Anteroposterior and septal	Anteroposterior and septal
Durability	Poor 25% moderate or severe TR at 3 y <sup>36</sup>	Poor to moderate 28% 3+ or 4+ TR at 5 y <sup>24</sup>	Moderate 32% 3+ or 4+ TR at 5 y <sup>24</sup>	Good	Good <5% ≥2+ TR at 5 y depending on indications for repair <sup>22-24</sup>
Risk heart block	Minimal	Minimal	Minimal	Low	Low
Risk dehiscence	Moderate	Moderate	Minimal	Minimal	Low to moderate
Additional time	5 min	5-10 min	10-15 min	15+ min	15+ min

TR, Tricuspid regurgitation.



**FIGURE 6.** Freedom from moderate or greater TR after tricuspid repair. A, Stratified by tricuspid annuloplasty technique. B, According to the presence of permanent pacemaker leads. *TR*, Tricuspid regurgitation; *PG*, Peri-Guard band annuloplasty; *DV*, DeVega suture annuloplasty; *FB*, flexible band annuloplasty; *RR*, rigid ring annuloplasty. (With permission from McCarthy and colleagues.<sup>24</sup>)

should be considered in patients at risk of requiring long-term ventricular pacing postoperatively.

**INCREMENTAL RISKS ASSOCIATED WITH TRICUSPID VALVE REPAIR**

Correctly performed, concomitant tricuspid repair is associated with minimal incremental mortality or morbidity.<sup>22,27-29</sup> Historic reports of greater mortality with

concomitant tricuspid repair reflect a case selection that may be biased by a much greater proportion of patients with severe tricuspid regurgitation, pulmonary hypertension, and right-sided dysfunction included in the concomitant tricuspid surgery cohort compared with the isolated mitral surgery group. In addition, outcomes of patients undergoing tricuspid surgery have improved with time, with lower risk-adjusted operative mortality seen in

TABLE 3. Summary of outcomes of tricuspid repair strategies

AHA/ACC level of recommendation	Indication for concomitant tricuspid repair strategy	Late TR in patients without tricuspid repair	Series
Class I: “Should be performed”	Severe TR		
Class IIa: “Is reasonable to perform”	Mild/moderate TR and annular dilatation	11% of patients with moderate or severe TR at 3 y 30% of patients with moderate or severe TR at 5 y 20% of patients with moderate or severe TR at 20 y	Brescia et al <sup>37</sup> Yilmaz et al <sup>17</sup> David et al <sup>19</sup>
Class IIb: “May be considered”	Moderate TR and PAH	Mean grade of TR at 5 y was 2+	Dreyfus et al <sup>18</sup>
	Mild/moderate TR or annular dilatation	<2% patients with >2+ TR at 5 y	Chikwe et al <sup>22</sup>

AHA, American Heart Association; ACC, American College of Cardiology; TR, tricuspid regurgitation; PAH, pulmonary artery hypertension.

a national analysis of patients operated on between 2000 and 2010.<sup>21</sup> In a surgical series comparing outcomes of 600 patients, the incidence of mortality, major bleeding events, and permanent pacemaker was not significantly different between patients who underwent concomitant tricuspid repair versus mitral repair only.<sup>22</sup> The rate of permanent pacemaker associated with tricuspid surgery in a national registry analysis was 4%.<sup>21</sup> Avoiding conduction block and the need for permanent pacemaker is particularly important, since transvalvular pacemaker leads are associated with much greater recurrence rates of tricuspid regurgitation (Figure 6, B). Compromise of the right coronary artery from tricuspid annular suture placement or kinking is a rare complication.

### RESIDUAL AND RECURRENT TRICUSPID REGURGITATION

Rates of residual moderate or greater tricuspid regurgitation after concomitant tricuspid repair for class IIa and IIb indications have been reported to range from zero in one single-surgeon series to 10% (Table 3).<sup>22-24</sup> Long-term rates of recurrent tricuspid regurgitation after tricuspid repair also vary widely, from around 3% to more than 20%, reflecting wide variation in the indications for concomitant repair, surgical approach, and outcomes reporting.<sup>22-24</sup> Risk factors associated with residual and recurrent tricuspid include echocardiographic factors such as tricuspid annular dilatation, tricuspid leaflet tethering, and right ventricular dysfunction; clinical factors such as atrial fibrillation, pulmonary hypertension, rheumatic valve disease, and transvalvular pacing wires; and technical factors—primarily suture annuloplasty techniques are associated with greater risk of residual and recurrent tricuspid regurgitation compared with ring annuloplasty.<sup>6,8,13-15,22,24</sup>

### FUTURE DIRECTION AND RESEARCH

The National Institutes of Health–supported multicenter trial, which randomized 401 patients with mild-to-

moderate tricuspid regurgitation undergoing degenerative mitral repair to concomitant tricuspid repair versus isolated mitral surgery, was designed and powered for a primary echocardiographic (tricuspid regurgitation grade) rather than clinical end point.<sup>30</sup> The outcomes of this trial may inform practice but will probably be less influential than the results of current trials comparing transcatheter and surgical repair for degenerative mitral regurgitation, and the results of transcatheter repair versus medical therapy for severe tricuspid regurgitation. These studies are designed and powered for noninferiority composite end points at 1 to 2 years that include repeat hospitalization<sup>31</sup> and as such will likely provide a platform for the expanded use of transcatheter devices in this population—both as first-line treatment for degenerative mitral regurgitation and subsequently instead of reoperative surgery for progression of tricuspid regurgitation. The initial feasibility studies of transcatheter tricuspid repair show some limited efficacy: in the TRILUMINATE study using MitraClip to repair the tricuspid valve, tricuspid regurgitation was reduced, on average from 5+ to 4+.<sup>32</sup> The surgical experience suggests that while short-term palliation of severe functional tricuspid regurgitation may be achieved with transcatheter edge-to-edge repair, this will be insufficient for in patients in whom the goal of care is curative, because long-term treatment efficacy in functional tricuspid regurgitation depends primarily on durable tricuspid annuloplasty. Transcatheter annular techniques under initial feasibility studies include Trialalign (Mitralign Inc, Boston, Mass), TriCinch (4Tech Cardio Ltd, Galway, Ireland), and Cardioband (Edwards Lifesciences).<sup>33-35</sup>

### CONCLUSIONS

Moderate or severe functional tricuspid regurgitation occurs in up to one third of patients after isolated degenerative mitral surgery, even in patients with insignificant tricuspid regurgitation at baseline. Tricuspid regurgitation is not a benign lesion, and even moderate degrees have been associated with reduced survival. Tricuspid regurgitation is highly



dynamic, and annular dilatation is a helpful predictor of the presence and progression of tricuspid regurgitation. Tricuspid ring annuloplasty can be performed safely, without incremental risk, and offers excellent and durable freedom from tricuspid regurgitation—correlated with improved right ventricular modeling. An aggressive approach to concomitant tricuspid repair is supported by current consensus guidelines and more recent data from surgical series with more conservative approaches characterized by high rates of recurrent moderate and severe tricuspid regurgitation in late follow-up. Future research will focus on the role of transcatheter repair in the management of severe tricuspid regurgitation after cardiac surgery.

### Conflict of Interest Statement

The authors reported no conflicts of interest. Cedars-Sinai Medical Center receives honoraria from Edwards-Lifesciences and Medtronic for speaker and consulting activity. Joanna Chikwe has previously received honoraria from Edwards LifeSciences and Medtronic.

The *Journal* policy requires editors and reviewers to disclose conflicts of interest and to decline handling or reviewing manuscripts for which they may have a conflict of interest. The editors and reviewers of this article have no conflicts of interest.

### References

- Nishimura RA, Otto CM, Bonow RO, Carabello BA, Erwin JP III, Guyton RA, et al. 2014 AHA/ACC guideline for the management of patients with valvular heart disease: a report of the American College of Cardiology/American Heart Association Task Force on Practice Guidelines. *J Am Coll Cardiol*. 2014;63:e57-185.
- Falk V, Baumgartner H, Bax JJ, De Bonis M, Hamm C, Holm PJ, et al. Corrigendum to '2017 ESC/ACTS Guidelines for the management of valvular heart disease' [*Eur J Cardiothorac Surg*. 2017;52:616-664]. *Eur J Cardiothorac Surg*. 2017;52:832.
- Braunwald NS, Ross J Jr, Morrow AG. Conservative management of tricuspid regurgitation in patients undergoing mitral valve replacement. *Circulation*. 1967;35:163-9.
- Carpentier A, Deloche A, Hanania G, Forman J, Sellier P, Pivnic A, et al. Surgical management of acquired tricuspid valve disease. *J Thorac Cardiovasc Surg*. 1974;67:53-65.
- King RM, Schaff HV, Danielson GK, Gersh BJ, Orszulak TA, Piehler JM, et al. Surgery for tricuspid regurgitation late after mitral valve replacement. *Circulation*. 1984;70:1193-7.
- David TE, David C, Manlhiot C, Fan CS. Tricuspid regurgitation is uncommon after mitral valve repair for degenerative disease. *J Thorac Cardiovasc Surg*. 2017;154:110-22.
- Dion R. Is the air in Toronto, Rochester and Cleveland different from that in London, Monaco, Leiden, Genk, Milan and New York? *J Thorac Cardiovasc Surg*. 2015;150:1040-3.
- Chikwe J, Adams DH. The donkey's shadow. *J Thorac Cardiovasc Surg*. 2017;154:125-6.
- McCarthy PM. Evolving approaches to tricuspid valve surgery: moving to Europe? *J Am Coll Cardiol*. 2015;65:1939-40.
- David TE. Invited commentary: outcomes of guideline directed concomitant annuloplasty for functional tricuspid regurgitation. *Ann Thorac Surg*. 2020;109:P1232-3.
- Deloche A, Guerinon J, Fabiani JM. Anatomical study of rheumatic valvulopathies. Applications to the critical study of various methods of annuloplasty. *Arch Mal Coeur Vaiss*. 1974;67:497-505.
- Sagie A, Schwammenthal E, Padial LR, Vazquez de Prada JA, Weyman AE, Levine RA. Determinants of functional tricuspid regurgitation in incomplete tricuspid valve closure: Doppler color flow study of 109 patients. *J Am Coll Cardiol*. 1994;24:446-53.
- David TE, David CM, Manlhiot C. Tricuspid annulus diameter does not predict the development of tricuspid regurgitation after mitral valve repair for mitral regurgitation due to degenerative diseases. *J Thorac Cardiovasc Surg*. 2018;155:2429-36.
- Ton-Nu TT, Levine RA, Handschumacher MD, Dorer DJ, Yosefy C, Fan D, et al. Geometric determinants of functional tricuspid regurgitation: insights from 3-dimensional echocardiography. *Circulation*. 2006;114:143-9.
- Kwon DA, Park JS, Chang HJ, Kim YJ, Sohn DW, Kim KB, et al. Prediction of outcome in patients undergoing surgery for severe tricuspid regurgitation following mitral valve surgery and role of tricuspid annular systolic velocity. *Am J Cardiol*. 2006;98:659-61.
- Matsuyama K, Matsumoto M, Sugita T, Nishizawa J, Tokuda Y, Matsuo T. Predictors of residual tricuspid regurgitation after mitral valve surgery. *Ann Thorac Surg*. 2003;75:1826-8.
- Yilmaz O, Suri RM, Dearani JA, Yilmaz O, Suri RM, Dearani JA, et al. Functional tricuspid regurgitation at the time of mitral repair for degenerative leaflet prolapse: the case for a selective approach. *J Thorac Cardiovasc Surg*. 2011;142:608-13.
- Dreyfus GD, Corbi PJ, Chan KM, Bahrami T. Secondary tricuspid regurgitation or dilatation: which should be the criteria for surgical repair? *Ann Thorac Surg*. 1990;49:706-11.
- David TE, David CM, Tsang W, Lafreniere-Roula M, Manlhiot C. Long-term results of mitral valve repair for regurgitation due to leaflet prolapse. *J Am Coll Cardiol*. 2019;74:1044-53.
- Nath J, Foster E, Heidenreich PA. Impact of tricuspid regurgitation on long-term survival. *J Am Coll Cardiol*. 2004;43:405-9.
- Kilic A, Saha-Chaudhuri P, Rankin JS, Conte JV. Trends and outcomes of tricuspid valve surgery in North America: an analysis of more than 50,000 patients from the Society of Thoracic Surgeons database. *Ann Thorac Surg*. 2013;96:1546-52.
- Chikwe J, Itagaki S, Anyanwu A, Adams DH. Impact of concomitant tricuspid annuloplasty on tricuspid regurgitation, right ventricular function and pulmonary artery hypertension after repair of mitral valve prolapse. *J Am Coll Cardiol*. 2015;65:1931-8.
- Sukmawan R, Watanabe N, Ogasawara Y, Yamaura Y, Yamamoto K, Wada N, et al. Geometric changes of tricuspid valve tenting in tricuspid regurgitation secondary to pulmonary hypertension quantified by novel system with transthoracic real-time 3-dimensional echocardiography. *J Am Soc Echocardiogr*. 2007;20:470-6.
- McCarthy PM, Bhudia SK, Rajeswaran J, Hoercher KJ, Lytle BW, Cosgrove DM, et al. Tricuspid valve repair: durability and risk factors for failure. *J Thorac Cardiovasc Surg*. 2004;127:674-85.
- Pfannmuller B, Doenst T, Eberhart K, Seeburger J, Borger MA, Mohr FW. Increased risk of dehiscence after tricuspid repair with rigid annuloplasty rings. *J Thorac Cardiovasc Surg*. 2012;142:1050-5.
- Millá F, Castillo JG, Varghese R, Chikwe J, Anyanwu AC, Adams DH. Rationale and initial experience with the Tri-Ad Adams tricuspid annuloplasty ring. *J Thorac Cardiovasc Surg*. 2012;143:S71-3.
- Chikwe J, Anyanwu AC. Surgical strategies for functional tricuspid regurgitation. *Semin Thorac Cardiovasc Surg*. 2010;22:90-6.
- Filsoufi F, Chikwe J, Carpentier A. Rationale for remodeling annuloplasty to address functional tricuspid regurgitation during left-sided valve surgery. *Eur J Cardiothorac Surg*. 2015;47:1-3.
- Badwhar V, Rankin JS, He M, Jacobs JP, Furnary AP, Fazzalari FL, et al. Performing concomitant tricuspid valve repair at the time of mitral operations is not associated with increased operative mortality. *Ann Thorac Surg*. 2017;103:587-93.
- ClinicalTrials.gov. Evaluating the Benefit of Concurrent Tricuspid Valve Repair During Mitral Surgery. Available at: <https://www.clinicaltrials.gov/ct2/show/NCT02675244>. Accessed November 9, 2019.
- Pirou N, Al Habash O, Donal E, Senage T, Le Tourneau T, Pattier S, et al. The MITRA-HR study: design and rationale of a randomized study of MitraClip transcatheter mitral valve repair in patients with severe primary mitral regurgitation eligible for high-risk surgery. *Eurointervention*. 2019;15:e329-35.
- Nickenig G, Weber M, Lurz P, von Bardeleben RS, Sitges M, Sorajja P, et al. Transcatheter edge-to-edge repair for reduction of tricuspid regurgitation: 6 months outcomes of the TRILUMINATE single-arm study. *Lancet*. 2019;394:2002-11.

33. Sorajja P, Cavalcante J, Goessi M, Bae R. Transcatheter repair of tricuspid regurgitation with MitraClip. *Prog Cardiovasc Dis*. 2019;62:488-92.
34. Nickenig G, Weber M, Schueler R, Hausleiter J, Näbauer M, von Bardeleben RS, et al. 6-Month outcomes of tricuspid valve reconstruction for patients with severe tricuspid regurgitation. *J Am Coll Cardiol*. 2019;73:1905-15.
35. Hahn RT, Meduri CU, Davidson CJ, Lim S, Nazif TM, Ricciardi MJ, et al. Early feasibility study of a transcatheter tricuspid valve annuloplasty: SCOUT Trial 30-Day results. *J Am Coll Cardiol*. 2017;69:1795-806.
36. Ghata RK, Chen R, Narayanaswamy N, McGurk S, Lipsitz S, Chen FY, et al. Suture bicuspidization of the tricuspid valve versus ring annuloplasty for repair of tricuspid regurgitation: midterm results of 237 consecutive patients. *J Thorac Cardiovasc Surg*. 2007;133:117-26.
37. Brescia AA, Ward ST, Watt TM, Rosenbloom LM, Baker M, Khan S, et al. Outcomes of guideline directed concomitant annuloplasty for functional tricuspid regurgitation. *Ann Thorac Surg*. 2019;109:1227-32.