


Respiratory failure patient with lung cancer diagnosed by transesophageal bronchoscopic ultrasound-guided aspirates

Takayasu Ito¹ , Masahide Oki², Hideo Saka², Yasuhiro Kondoh¹, Tomoki Kimura¹ & Kensuke Kataoka¹

¹Department of Respiratory Medicine and Allergy, Tosei General Hospital, Seto, Japan.

²Department of Respiratory Medicine, Nagoya Medical Center, Nagoya, Japan.

Keywords

Chronic respiratory failure, endobronchial ultrasound-guided transbronchial needle aspiration, endoscopic ultrasound with bronchoscope-guided fine-needle aspiration, lung cancer.

Correspondence

Yasuhiro Kondoh, Department of Respiratory Medicine and Allergy, Tosei General Hospital, 160 Nishioiwake-cho, Seto, Aichi 489-8642, Japan. E-mail: konyasu2003@yahoo.co.jp

Received: 24 November 2017; Revised: 2 January 2018; Accepted: 24 January 2018; Associate Editor: Tow Keang Lim.

Respirology Case Reports, 6 (4), 2018, e00309

doi: 10.1002/rcr2.309

Introduction

Endobronchial ultrasound-guided transbronchial needle aspiration (EBUS-TBNA) has been reported to be an accurate and safe procedure for diagnosis of mediastinal lesions adjacent to the trachea [1]. Although the procedure is low-invasive and well-tolerated in most patients, it is often unsuitable for patients with respiratory failure. Such patients need a different procedure that does not use a transbronchial approach. If the lesion is accessible, endoscopic ultrasound with bronchoscope-guided fine-needle aspiration (EUS-B-FNA), which can be performed with an ultrasound bronchoscope through the oesophagus, seems to be a reasonable approach as fewer episodes of oxygen desaturation occurs during EUS-B-FNA than EBUS-TBNA [2]. Here, we report a patient with respiratory failure whose mediastinal lymph node could not be diagnosed by EBUS-TBNA under non-invasive positive pressure ventilation (NPPV) but was successfully diagnosed by EUS-B-FNA.

Abstract

A 71-year-old man, who had received long-term oxygen therapy for respiratory failure caused by chronic obstructive pulmonary disease, had an enlarged mediastinal lymph node for one year. As his lung function was poor, we tried performing endobronchial ultrasound-guided transbronchial needle aspiration under non-invasive positive pressure ventilation for diagnosis but could not obtain sufficient specimens. Later, we performed an endoscopic ultrasound with bronchoscope-guided fine-needle aspiration (EUS-B-FNA) using a transesophageal approach. Rapid on-site cytology revealed that adequate specimens were obtained, and we could terminate the procedure in 12 min without any complications. The histological findings revealed lung adenocarcinoma. EUS-B-FNA, which can be performed by a pulmonologist, is a useful alternative for diagnosing mediastinal lesions in patients with respiratory failure.

Case Report

A 71-year-old man had received long-term oxygen therapy for respiratory failure related to chronic obstructive pulmonary disease. In a periodic medical examination, an enlarged mediastinal lymph node was seen in the subcarinal region (Fig. 1A). Fluorodeoxyglucose-positron emission tomography (FDG-PET) revealed a hypermetabolic lesion in the enlarged mediastinal lymph node (Fig. 1B); thus, we suspected malignant disease. For diagnosis of mediastinal lesions, we first selected EBUS-TBNA because we were more accustomed to performing EBUS-TBNA than EUS-B-FNA. To avoid desaturation during EBUS-TBNA, we used three methods: tracheal intubation, high-flow nasal cannula (HFNC), and NPPV. For the prevention of lower tidal volume, tracheal intubation or NPPV was better than HFNC. Intubation management was not used out of concern for the difficulty of extubation. We therefore selected to perform the procedure under NPPV. Before the procedure, the upper airway was anaesthetised

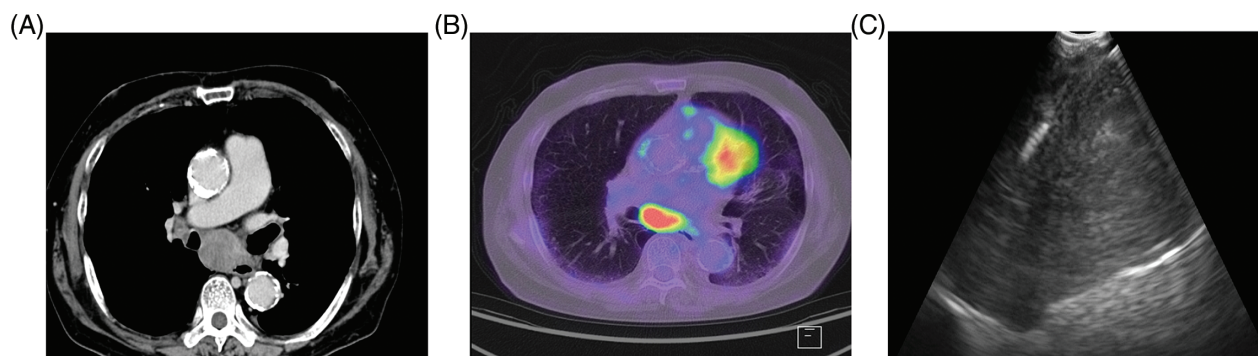


Figure 1. (A) Chest computed tomography revealed mediastinal lymphadenopathy measuring 30 mm in the shortest diameter. (B) Fluorodeoxyglucose positron emission tomography showed a hypermetabolic lesion in the enlarged mediastinal lymph node. (C) An ultrasound image of the puncture procedure showed the needle within the mediastinal lesion.

with a 2% lidocaine spray, and an intravenous bolus of fentanyl and midazolam was administered. We then advanced the ultrasound bronchoscope (BF-UC260FW; Olympus Corporation, Japan) through the mouth to the trachea, with the patient in the supine position under NPPV in continuous positive airway pressure mode (pressure, 5 cmH₂O; oxygen saturation, 100%; respiratory rate, 15/min). After one puncture with a 22-gauge needle (NA-201SX-4022; Olympus Corporation), the patient experienced a deteriorating cough and transient oxygen desaturation (with a minimum of 88%) under NPPV. We therefore ended EBUS-TBNA with insufficient specimens for diagnosis. The operation time was 15 min. Later, we tried to diagnose the lesion again using EUS-B-FNA. Before the procedure, the upper airway was anaesthetised with 4% lidocaine through a nebulizer, and an intravenous bolus of fentanyl was administered. Then, we advanced the ultrasound bronchoscope (the same as used in EBUS-TBNA) through the mouth to the oesophagus with the patient in the supine position. After the target lesion was identified on an ultrasound image, we punctured it with a

22-gauge needle (also the same as in EBUS-TBNA, Fig. 1C). The resulting rapid on-site cytological evaluation was positive at the first puncture. For detection of the genetic mutation, three biopsies were performed. The operation time was 12 min without cough reflex. During the procedure, the patient's oxygen saturation was constantly maintained at >90% with an oxygen flow rate of 2 L/min. Histological and immunohistochemical findings were compatible with primary lung adenocarcinoma (Fig. 2). Immunohistochemistry for the expression of programmed cell death ligand-1 (PD-L1) was positive, and molecular testing for epidermal growth factor receptor and anaplastic lymphoma kinase rearrangement were negative. FDG-PET and enhanced computed tomography revealed no primary lesions. The staging was thus T0N2M0. Chemotherapy with carboplatin and pemetrexed was administered as the first-line treatment.

Discussion

We report a patient with respiratory failure in whom EUS-B-FNA was feasible and effective for the diagnosis of a

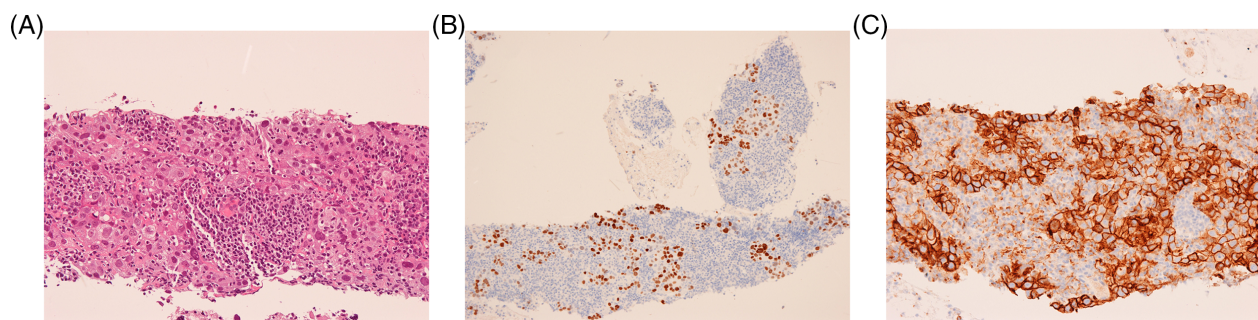


Figure 2. Histopathological and immunohistochemical findings of the specimen obtained by endoscopic ultrasound with bronchoscope-guided fine-needle aspiration (EUS-B-FNA). (A) High-power view of the stained and enlargement atypical cells cluster with large nuclear cell (haematoxylin and eosin stain). (B) Atypical cells showed positive staining for the expression of thyroid transcription factor-1 (TTF-1). (C) Atypical cells showed strong positive staining for the expression of programmed cell death ligand-1 (PD-L1).

mediastinal lesion adjacent to the oesophagus. EUS-B-FNA provided diagnostic specimens that were sufficient for immunohistochemical and molecular analyses.

Bronchoscopy including EBUS-TBNA cannot be tolerated in some patients with respiratory failure, as it sometimes causes significant hypoxia during the procedure. For such patients, procedures that do not use a transbronchial approach are needed. EUS-B-FNA has been reported to provide a high diagnostic yield, equivalent to that of EBUS-TBNA [1–3], and it has the advantages, over EBUS-TBNA, of fewer episodes of oxygen desaturation, comparable tolerance with fewer doses of anaesthetics and sedatives, and shorter procedure time [2]. In our case, we might have been able to diagnose the lesions if we had performed the puncture many times under different circumstances. However, with the transbronchial approach, the longer examination may have caused worsening of the respiratory failure. Therefore, EUS-B-FNA seemed to be a good alternative to EBUS-TBNA.

Recently, Watanabe et al. reported that chemotherapy could improve the survival of non-small lung cancer patients who received oxygen therapy [4]. In such patients, surgical procedures are not an option for diagnosis and treatment, so accurate diagnosis, including both subtyping and genotyping, by minimally invasive procedures is necessary for choosing the optimal treatment. In our case, specimens obtained by EUS-B-FNA were sufficient for immunohistochemical examination as well as molecular testing, which provided useful information for decisions on management.

In conclusion, EUS-B-FNA was feasible and useful in this case of chronic respiratory failure. In patients with poor lung function, it can be used as the first procedure for diagnosing mediastinal lesions adjacent to the oesophagus.

Disclosure Statement

Appropriate written informed consent was obtained for publication of this case report and accompanying images.

References

1. Vilmann P, Clementsen PF, Colella S, et al. 2015. Combined endobronchial and esophageal endosonography for the diagnosis and staging of lung cancer: European Society of Gastrointestinal Endoscopy (ESGE) guideline, in cooperation with the European Respiratory Society (ERS) and the European Society of Thoracic Surgeons (ESTS). *Endoscopy* 47:545–559.
2. Oki M, Saka H, Ando M, et al. 2015. Transbronchial vs transesophageal needle aspiration using an ultrasound bronchoscope for the diagnosis of mediastinal lesions: a randomized study. *Chest* 147:1259–1266.
3. Dhooria S, Aggarwal AN, Gupta D, et al. 2015. Utility and safety of endoscopic ultrasound with bronchoscope-guided fine-needle aspiration in mediastinal lymph node sampling: systematic review and meta-analysis. *Respir. Care* 60:1040–1050.
4. Watanabe K, Shinkai M, Tei Y, et al. 2016. Chemotherapy in non-small cell lung cancer patients receiving oxygen therapy. *Oncol. Res. Treat.* 39:587–590.