

LETTER

COVID-19 infection in patients with Sézary syndrome: Report of two cases

Dear Editor,

A pandemic coronavirus, severe acute respiratory syndrome coronavirus 2 (SARS-CoV-2), causes a disease called coronavirus disease 2019 (COVID-19), which is potentially life-threatening. Patients with hematologic malignancies may be at an increased risk of severe COVID-19 due to immunosuppression related to the underlying disease and/or its treatment.¹ Sézary syndrome (SS) is a rare leukemic type of primary cutaneous lymphoma, defined by the triad of erythroderma, lymphadenopathy, and clonal T cells in the skin, lymph nodes, and peripheral blood.² Skin infections frequently occur at sites of breakdown caused by the disease, and may result in death.³ In addition, chemotherapy and corticosteroids further increase the susceptibility to infection.^{4,5} The outcome of COVID-19 in these patients is unknown. Herein, we present two cases of patients with SS who developed COVID-19.

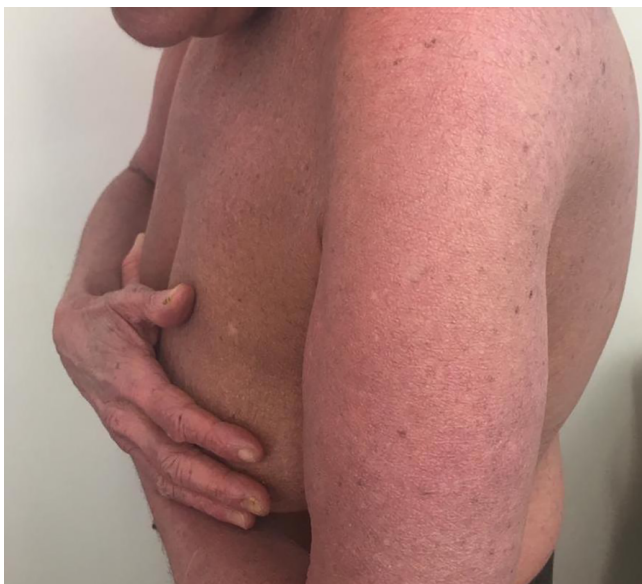

FIGURE 1 Patient with erythroderma at diagnosis of Sézary syndrome

Case 1: A 56-year-old woman without comorbidities was diagnosed with SS in June 2018. She presented with pruritic erythroderma (Figure 1) without palpable lymph nodes, and was treated with extracorporeal photopheresis and interferon alpha, with complete response. In March 2020, she presented with relapse of the skin lesions, and large bilateral inguinal lymph nodes. Biopsy of a lymph node was consistent with a diagnosis of large cell transformation of SS. Chemotherapy with gemcitabine was started. In May 2020, she was admitted to the hospital with fever, chills, and progressive cutaneous and nodal disease. She received broad-spectrum antibiotics and a nasopharyngeal swab was positive to SARS-CoV-2. Laboratory parameters are described in Table 1. A chest X-ray was normal and computed tomography (CT) was not performed due to logistic reasons. The clinical course progressed, and palliative care measures were adopted. She died due to progressive SS 5 days after admission.

Case 2: A 78-year-old woman with well-controlled arterial hypertension and asthma was diagnosed with SS in February 2020. She presented with pruritic erythroderma and bilateral cervical and axillary lymphadenopathy. Treatment with dexamethasone and interferon alpha was started, with partial response. Six weeks later, the skin lesions worsened and gemcitabine was started. After two cycles of chemotherapy, the patient presented with fever and hypotension. She was admitted to the hospital and received broad-spectrum antibiotics. Hypotension was responsive to fluid resuscitation and the patient became afebrile. Cutaneous disease was stable. After 10 days, the patient developed dry cough and respiratory distress. Chest CT showed bilateral ground-glass opacities affecting more than 50% of both lungs (Figure 2). A nasopharyngeal swab was positive for SARS-CoV-2. Laboratory parameters are described in Table 1. Oxygen supplementation was started, but respiratory failure progressed and she died 8 days after the onset of respiratory symptoms, under palliative care.

Patients with cancer who develop COVID-19 may have a poor outcome, especially if comorbidities are present.⁶ SS is a rare disease that affects predominantly elderly patients. Treatment is usually

TABLE 1 Laboratory parameters (day of positive RT-PCR for SARS-CoV-2)

Patient	WBC (/μL)	ANC (/μL)	ALC (/μL)	CRP (mg/dL)	Ferritin (mg/dL)	D-dimer (ng/mL)
1	7400	5950	1391	9.67	897.4	894
2	8450	6625	1394	18.51	736.8	NA

Abbreviations: ALC, absolute lymphocyte count; ANC, absolute neutrophil count; CRP, C-reactive protein; NA, not available; RT-PCR, reverse transcription polymerase chain reaction; SARS-CoV-2, severe acute respiratory syndrome coronavirus 2; WBC, white blood cell count.

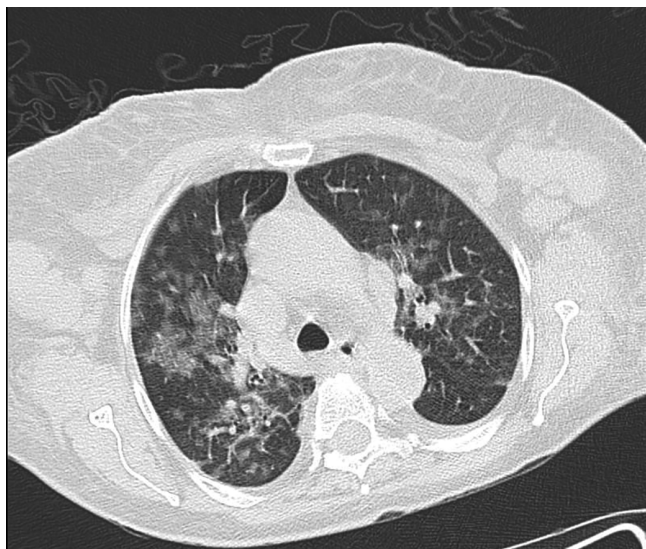


FIGURE 2 Chest computed tomography scan showing bilateral ground-glass opacities

started immediately in order to repair a severely damaged skin, and therefore reduce the risk of cutaneous and systemic infections. Corticosteroids and chemotherapy are frequently used and further increase immunosuppression. The course of COVID-19 in these patients is unknown and, to our knowledge, these are the first reported cases with the association of SS and COVID-19. While the optimal management of COVID-19 in such patients is unknown, experts recommend postponing chemotherapy in patients with stable disease.¹ The occurrence of COVID-19 in patients with progressive lymphoma is a great challenge. Our cases point to the dilemma: how to deal with patients who are at risk for severe COVID-19 and need immediate treatment for progressive neoplastic disease?

CONFLICT OF INTEREST

The authors declare no conflicts of interest.

Yung Gonzaga¹ 

Mayne Batista Fontes Santos¹ 

Marcia Matos Silva² 

Márcio Nucci³

¹Hematology Department, Instituto Nacional de Cancer, Rio de Janeiro, Brazil

²Phototherapy Department, Instituto Nacional de Cancer, Rio de Janeiro, Brazil

³Internal Medicine Department, Universidade Federal do Rio de Janeiro, Rio de Janeiro, Brazil

Correspondence

Yung Gonzaga, Hematology Department, Instituto Nacional de Cancer, Rio de Janeiro, Brazil.
Email: yungbmg@hotmail.com

ORCID

Yung Gonzaga  <https://orcid.org/0000-0003-1416-2118>

Mayne Batista Fontes Santos  <https://orcid.org/0000-0001-8601-0290>

Marcia Matos Silva  <https://orcid.org/0000-0003-2038-5158>

REFERENCES

1. Weinkove R, McQuilten ZK, Adler J. Managing haematology and oncology patients during the COVID-19 pandemic: interim consensus guidance. *Med J Aust.* 2020;212(10):481-489.
2. Willemze R, Cerroni L, Kampf W, et al. The 2018 update of the WHO-EORTC classification for primary cutaneous lymphomas. *Blood.* 2019; 133(16):1703-1714.
3. Redfort PT, Devessa SS, Andersow WF, et al. Cutaneous lymphoma incidence patterns in the United States: a population-based study of 3884 cases. *Blood.* 2009;113(21):5064-5073.
4. Hermann B, Lehnert N, Brodhun M, et al. Influenza virus infection in patients with malignancies – characteristics and outcomes of the season 2014/2015. A survey conducted by the Infectious Disease Working Party (AGIHO) of the German Society of Haematology and Medical Oncology (DGHO). *Eur J Clin Microbiol Infect Dis.* 2017;36(3):565-573.
5. Blaizot R, Ouattara E, Fauconneau A. Infectious events and associated risk factors in mycosis fungoides/Sezary syndrome: a retrospective cohort study. *Br J Dermatol.* 2018;179:1322-1329.
6. Liang W, Guan W, Chen R, et al. Cancer patients in SARS-CoV-2 infection: a nationwide analysis in China. *Lancet Oncol.* 2020;21(3): 335-337.