



# Erector Spinae Plane Block for Children Undergoing Cardiac Surgeries via Sternotomy: A Randomized Controlled Trial

Ahmed Ali Gado<sup>1</sup>, Wafaa Mohamed Alsadek<sup>1</sup>, Hassan Ali <sup>1</sup> and Ahmed Abdelaziz Ismail <sup>1,\*</sup>

<sup>1</sup>Anesthesia Department, Faculty of Medicine, Cairo University, Giza, Egypt

\*Corresponding author: Anesthesia Department, Faculty of Medicine, Cairo University, Giza, Egypt. Email: ahmed.abdelaziz81@yahoo.com

Received 2022 February 28; Revised 2022 March 25; Accepted 2022 March 25.

## Abstract

**Background:** Ineffective management of postoperative pain following pediatric cardiac surgeries adversely affects a patient's postoperative course. The erector spinae plane (ESP) block has been described in the literature regarding perioperative pain management. We hypothesized that bilateral ESP blocks in pediatric patients would decrease intraoperative fentanyl consumption, reduce the need for postoperative morphine consumption, and improve pain scores.

**Objectives:** The aim of this double-blinded randomized controlled trial was to assess the efficacy and safety of bilateral ESP blocks in pediatric patients undergoing cardiac surgeries through a median sternotomy.

**Methods:** The study involved 98 children aged 6 months to 7 years who were American Society of Anesthesiologists (ASA) II and III and scheduled for cardiac surgery through a median sternotomy. Patients were divided randomly into 2 groups: the ES group (n = 50) who received bilateral ultrasound-guided ESP blocks, and the N group (n = 48) who received no block. The primary outcome was the total dose of administered fentanyl intraoperatively. Secondary outcomes included morphine consumption in the first 24 hours postoperatively; the length of time before the first need for postoperative analgesia; and FLACC (face, legs, activity, consolability, and cry) scores at the first and second hours postoperatively and every 4 hours, with readings taken for a period of 24 hours.

**Results:** There were statistically significantly higher levels of administered fentanyl intraoperatively ( $6.7 \pm 3$  vs  $4.3 \pm 1.9 \mu\text{g}\cdot\text{kg}^{-1}$ ) and postoperative morphine consumption ( $0.5 \pm 0.2$  vs  $0.4 \pm 0.2 \text{ mg}\cdot\text{kg}^{-1}$ ) in the N group compared with the ES group ( $P < 0.001$ ). Moreover, the timing of the first rescue analgesia was significantly delayed in the ES group compared with the N group ( $231.6 \pm 104.5$  vs  $108.8 \pm 47.8$  minutes).

**Conclusions:** Bilateral ultrasound-guided ESP blocks can be used to reduce perioperative opioid consumption in pediatric patients undergoing cardiac surgery through a sternotomy. It also can be used to decrease postoperative pain scores.

**Keywords:** Sternotomy, Pediatric Cardiac Surgeries, Erector Spinae Plane Block

## 1. Background

Ineffective management of postoperative pain following pediatric cardiac surgery conducted through a sternotomy adversely affects a patient's postoperative course. It could result in delayed recovery, prolonged mechanical ventilation, prolonged intensive care unit (ICU) stay, prolonged hospital stay, and/or adverse psychological sequelae (1). One of the essential requirements of an enhanced recovery program following cardiac surgery is the proper control of post-sternotomy pain without significant sedation or side effects (2). Accordingly, various analgesic tools have been used to alleviate intraoperative and postoperative sternotomy pain. These tools include a number of multimodal analgesics, including paracetamol, nonsteroidal anti-inflammatory drugs (NSAIDs), and opioids. Non-pharmacological techniques used to con-

trol sternotomy pain include such thoracic regional analgesic techniques as thoracic epidural anesthesia (TEA), paravertebral block (PVB), intercostal nerve block, transversus thoracic plane block, parasternal plane block, and erector spinae plane (ESP) block (3-6).

The ESP block has been described in the literature regarding perioperative pain management. It has been used unilaterally in thoracic surgeries and bilaterally in cardiac surgeries. It has the advantages of being technically simpler and safer than other local anesthetic techniques, such as thoracic paravertebral and thoracic epidural block (7).

Since 2016, few studies have been conducted to assess the efficacy of the ESP block in thoracic and cardiac surgeries. We hypothesized that bilateral ESP blocks in pediatric patients would decrease intraoperative fentanyl consumption, reduce the need for postoperative morphine

consumption, and improve pain scores.

## 2. Objectives

The aim of this study was to assess the efficacy and safety of bilateral ESP blocks in pediatric patients undergoing cardiac surgeries through a median sternotomy.

## 3. Methods

This study was a randomized controlled, double-blinded clinical trial. The randomization task was performed by an independent party who used an online random number generator. Patients were divided into 2 groups: the ES group (n = 50) who received bilateral ultrasound-guided ESP blocks, and the N group (n = 48) who received no regional anesthesia. Patient study code numbers and allocations were placed in closed numbered envelopes. Following the induction of general anesthesia, envelopes were opened to reveal group assignments. ESP blocks were carried out by a single regional anesthesia consultant.

To achieve blinding of the study, the same surgical dressing was applied to the back of all the participants. During the intervention, another anesthesia team was out of the operating room and took over when the ESP block and full surgical draping were performed (just before the skin incision). Moreover, the nurses who recorded postoperative data in the ICU were blinded to the nature of the research and intraoperative interventions.

This clinical trial was carried out at Cairo University Pediatric Hospital between July 2020 and August 2021 after receiving approval from the institutional ethical committee. It was registered on clinicaltrials.gov with reference number NCT04452656. Each parent/legal guardian was given a thorough explanation of the procedure before signing an informed consent form for the child to participate in the study.

The study involved 98 children aged 6 months to 7 years who were American Society of Anesthesiologists (ASA) II and III and scheduled for cardiac surgery through a sternotomy. Exclusion criteria included redo surgeries, emergency surgeries, vertebral column anomalies, refusal of the parent/legal guardian, coagulopathy, preoperative injection site infection, history of allergy to any of the utilized medications, cyanotic heart disease, patients with single ventricles, and severe cardiac, renal, or hepatic insufficiency.

### 3.1. Anesthesia Management

A peripheral intravenous line was secured for each patient in the inpatient ward 1 day prior to the operation. Premedication in the form of midazolam  $0.05 \text{ mg.kg}^{-1}$ , ketamine  $1 \text{ mg.kg}^{-1}$ , and atropine  $0.05 \text{ mg.kg}^{-1}$  was intravenously administered before transferring the patient to the operating room. As per "standard" intraoperative monitoring, an electrocardiogram, pulse oximeter, and non-invasive arterial pressure monitor were connected to the patient. Induction of anesthesia was achieved with the intravenous administration of  $2 \text{ mg.kg}^{-1}$  of ketamine,  $0.5 - 1 \mu\text{g.kg}^{-1}$  of fentanyl, and  $0.5 - 2 \text{ mg.kg}^{-1}$  of atracurium. Additional monitors, including a capnogram, inhalational gas analyzer, invasive arterial pressure monitor, central venous pressure monitor, transesophageal echo (TEE) probe, and near infra-red spectrophotometer (NIRS), were then connected to the patient. After induction,  $30 \text{ mg.kg}^{-1}$  of cefazolin was administered as antibiotic prophylaxis. Maintenance of anesthesia was achieved through an inhalational 1.2% - 2% sevoflurane mixture in oxygen and the infusion of  $0.5 \text{ mg.kg}^{-1}.\text{h}^{-1}$  of atracurium.

Intraoperative analgesia was achieved by administering  $0.5 - 1 \mu\text{g.kg}^{-1}$  of fentanyl plus  $15 \text{ mg.kg}^{-1}$  of paracetamol, given to all patients concomitantly with induction of anesthesia. Additional analgesic medication in the form of boluses of  $0.5 - 2 \mu\text{g.kg}^{-1}$  of fentanyl was administered in the event of a persistent rise in systolic arterial pressure or heart rate of more than 20% of baseline readings (confirmed by 2 consecutive readings). To control postoperative nausea and vomiting,  $0.1 \text{ mg.kg}^{-1}$  of dexamethasone and  $10 \mu\text{g.kg}^{-1}$  of granisetron were administered to all patients.

The administration of both the inhalational anesthetic agent and atracurium infusion was stopped after the surgeon finished suturing the skin incision. A trial of endotracheal extubation was conducted in the operating room if extubation criteria stipulated by the institutional policy were met. These are the return of motor power, normal arterial blood gas analysis, body temperature  $\geq 36^\circ\text{C}$ , and stable hemodynamics. After 30 minutes, patients were transferred to the ICU, whether they were still intubated or extubated. At the ICU, all patients received  $10 \text{ mg.kg}^{-1}$  of paracetamol every 6 hours. A trained nurse evaluated and recorded postoperative pain using the FLACC (face, legs, activity, consolability, and cry) pain chart. It consists of 5 categories: (F) face; (L) legs; (A) activity; (C) consolability; and (C) cry. Every category is scored from 0 to 2, resulting in a total score between 0 and 10. If a patient's FLACC score was  $\geq 4$ ,  $0.05 \text{ mg.kg}^{-1}$  of morphine was administered intravenously.

### 3.2. ESP Block Technique

The ESP block was conducted under complete aseptic conditions with ultrasound machine guidance (SonoSite Inc, Bothell, WA, USA). After induction of anesthesia was accomplished, the patient was turned to the prone position. Then, the fifth thoracic spinous process (T5) was identified by palpating and counting down from the seventh cervical spinous process (C7). A high-frequency 7 to 13-MHz linear ultrasound transducer was placed in a parasagittal (parallel) position lateral to the T5 spinous process. Then, the probe was moved from lateral to medial until it was positioned over the tip of the transverse process. Transverse processes could be differentiated from the proximal ribs by their squared-off appearance. The trapezius muscle, rhomboids major muscle, and erector spinae muscle could be recognized overlying the hyperechoic transverse process (Figure 1). Using an in-plane approach, a Simplex® Ultra 360® 22 gauge (35 mm) echogenic needle was inserted in the caudal-cephalad direction until the tip was deep into the erector spinae muscle and hit the transverse process. The correct needle tip location was confirmed by injecting 1 mL of normal saline and visualizing the linear spread in the fascial plane between the erector spinae muscle and the transverse process (Figure 2). Then, 0.4 ml.kg<sup>-1</sup> of bupivacaine 0.25% was injected. After that, the procedure was performed on the other side in the same manner as described above (8, 9).

The primary outcome was the total dose of administered fentanyl intraoperatively. Secondary outcomes included the morphine consumption in the first 24 hours postoperatively, the length of time before the first need for postoperative analgesia (defined as the time between extubation and a FLACC score  $\geq 4$ ), the place of extubation (operating theatre or ICU), and FLACC scores in the first and second hour postoperatively and at every 4 hours for a period of 24 hours. Incidences of postoperative complications, including postoperative nausea vomiting (PONV), itching, respiratory depression, pneumothorax, and prolonged paresthesia, were also considered as secondary outcomes of this study.

### 3.3. Sample Size

A statistician calculated the sample size by comparing intraoperative fentanyl consumption between children who had undergone sternotomies and had received ESP blocks with those who had received conventional anesthesia (as reported by a previous study) (10). In that study, the mean  $\pm$  SD of intraoperative fentanyl consumption stood at approximately 10.45  $\pm$  3.2  $\mu\text{g.kg}^{-1}$  in the ESP group and approximately 11.46  $\pm$  2.1  $\mu\text{g.kg}^{-1}$  in the conventional group. Accordingly, using the Student t test for independent samples, the statistician found the minimum proper

sample size needed to detect a real difference of 1.2  $\mu\text{g.kg}^{-1}$  with 80% power at Cronbach  $\alpha = 0.05$  level to have stood at 47 participants for each group. We increased the sample size to 54 patients in each group to compensate for drop-outs. The sample size calculation was performed using the PS Power and Sample Size Calculations software version 3.0.11 for MS Windows (William D. Dupont and Walton D., Vanderbilt University, Nashville, Tennessee, USA).

### 3.4. Statistical Analysis

Data were analyzed using SPSS version 20 (SPSS Inc, Chicago, Ill, USA). The Kolmogorov-Smirnov test was used to verify the normality of the distribution of variables. Comparisons between groups for categorical variables were assessed using the chi-square test (Fisher or Monte Carlo). The Student t test was used to compare differences between the 2 study groups regarding normally distributed quantitative variables, while the Mann-Whitney test was used to compare differences between the 2 groups regarding not-normally distributed quantitative variables. The significance of the obtained results was judged at the 5% level.

## 4. Results

A total of 115 pediatric patients were assessed for eligibility to participate in this study. Five children were excluded from the study because their parents did not consent to participate. Two children were excluded because they were redo cases. A total of 108 children met the inclusion criteria. They were allocated into 2 groups: the ES group who received ESP blocks and the N group who received no block. Fifty-four patients were initially allocated to each group. Four patients from the ES group and 6 patients from the N group were excluded from the study due to complicated postoperative courses. A remaining total of 98 children participated and completed the study, and their data were successfully analyzed (Figure 3).

There were no statistically significant differences between both groups in terms of age, sex, weight, or height. The type and duration of surgical procedures and ASA classifications were also comparable between both groups (Table 1).

The study showed statistically significantly higher levels of intraoperatively administered fentanyl and postoperative morphine consumption in the N group compared with the ES group ( $P < 0.001$ ). Moreover, the timing of the first rescue analgesia was significantly delayed in the ES group compared with the N group (Table 2).

A statistically significantly higher percentage of children from the ES group (58%) were extubated in the operating room compared with those from the N group (37.5%;

**Table 1.** Comparison Between the 2 Groups According to Patient and Surgical Characteristics <sup>a</sup>

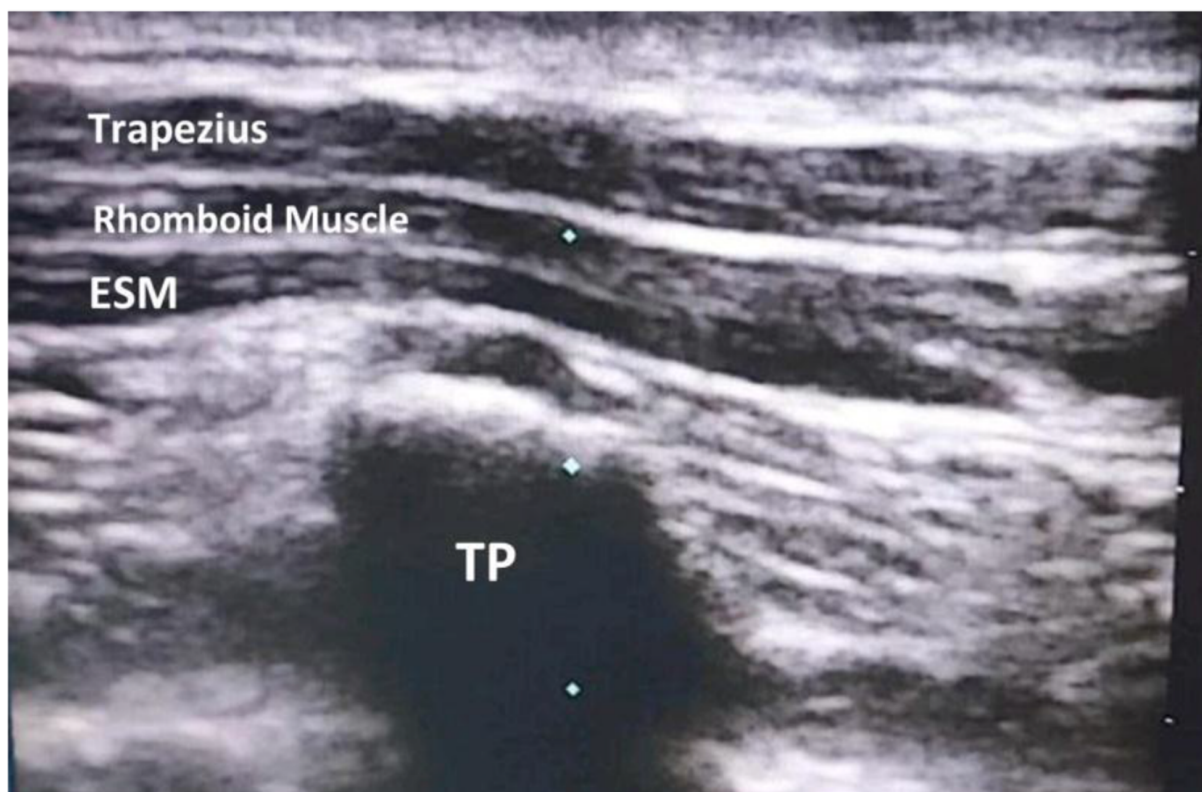
Variables	Group N (n = 48)	Group ES (n = 50)	P Value
<b>Age (mo)</b>			0.230
Mean $\pm$ SD	33.5 $\pm$ 24.9	28.2 $\pm$ 25.3	
Median (min - max)	33.5 (6 - 84)	14.5 (6 - 84)	
<b>Weight (kg)</b>			0.201
Mean $\pm$ SD	13 $\pm$ 7	11.7 $\pm$ 7.3	
Median (min - max)	14 (4.8 - 36)	9.8 (3.2 - 38)	
<b>Height (cm)</b>			0.356
Mean $\pm$ SD	88 $\pm$ 20.3	84.1 $\pm$ 20.8	
Median (min - max)	90 (60 - 129)	80.5 (56 - 135)	
<b>Sex (male/female)</b>			0.980
Male	21 (43.8)	22 (44)	
Female	27 (56.3)	28 (56)	
<b>ASA</b>			0.563
II	27 (56.3)	31 (62)	
III	21 (43.8)	19 (38)	
<b>Surgical duration (min)</b>			0.557
Mean $\pm$ SD	142.8 $\pm$ 27.8	145.9 $\pm$ 23.7	
<b>Type of surgical procedure</b>			
VSD closure	19 (39.6)	27 (54)	0.153
ASD closure	14 (29.2)	11 (22)	0.416
AVSD closure	10 (20.8)	8 (16)	0.537
SAM resection	2 (4.2)	3 (6)	1.000
Mitral valve repair	2 (4.2)	0 (0)	0.237
Supravalvular AS repair	1 (2.1)	0 (0)	0.490
Pulmonary artery banding	0 (0)	1 (2)	1.000

<sup>a</sup> Values are expressed as No. (%) unless otherwise indicated.

**Table 2.** Comparison Between the 2 Groups According to Primary and Secondary Outcomes <sup>a</sup>

Variables	Group N (n = 48)	Group ES (n = 50)	P Value
<b>Primary outcome</b>			
Intraoperative fentanyl ( $\mu\text{g.kg}^{-1}$ )	6.7 $\pm$ 3	4.3 $\pm$ 1.9	< 0.001
<b>Secondary outcomes</b>			
Postoperative morphine consumption ( $\text{mg.kg}^{-1}$ )	0.5 $\pm$ 0.2	0.4 $\pm$ 0.2	< 0.001
Time to first rescue analgesia (min)	108.8 $\pm$ 47.8	231.6 $\pm$ 104.5	< 0.001
<b>Place of extubation</b>			0.042
OR	18 (37.5)	29 (58)	
ICU	30 (62.5)	21 (42)	

<sup>a</sup> Values are expressed as mean  $\pm$  SD or No. (%).



**Figure 1.** Muscles overlying erector spinae muscles (abbreviations: TP, transverse process; ESM, erector spinae muscle).

$P = 0.04$ ). Consequently, a statistically significantly lower percentage of children from the ES group (42%) were extubated in the ICU compared with those from the N group (62.5%;  $P = 0.04$ ; [Table 2](#)).

FLACC pain score values were significantly higher in the N group than in the ES group in the first 24 hours postoperatively ([Figure 4](#)). The incidence of complications was comparable between both groups with no measurable, significant differences ([Table 3](#)).

## 5. Discussion

The main findings of the current study are that the bilateral ESP block decreased the perioperative opioid consumption, prolonged the duration of postoperative analgesia, and improved the 24-hour postoperative pain score in children that had undergone cardiac surgery.

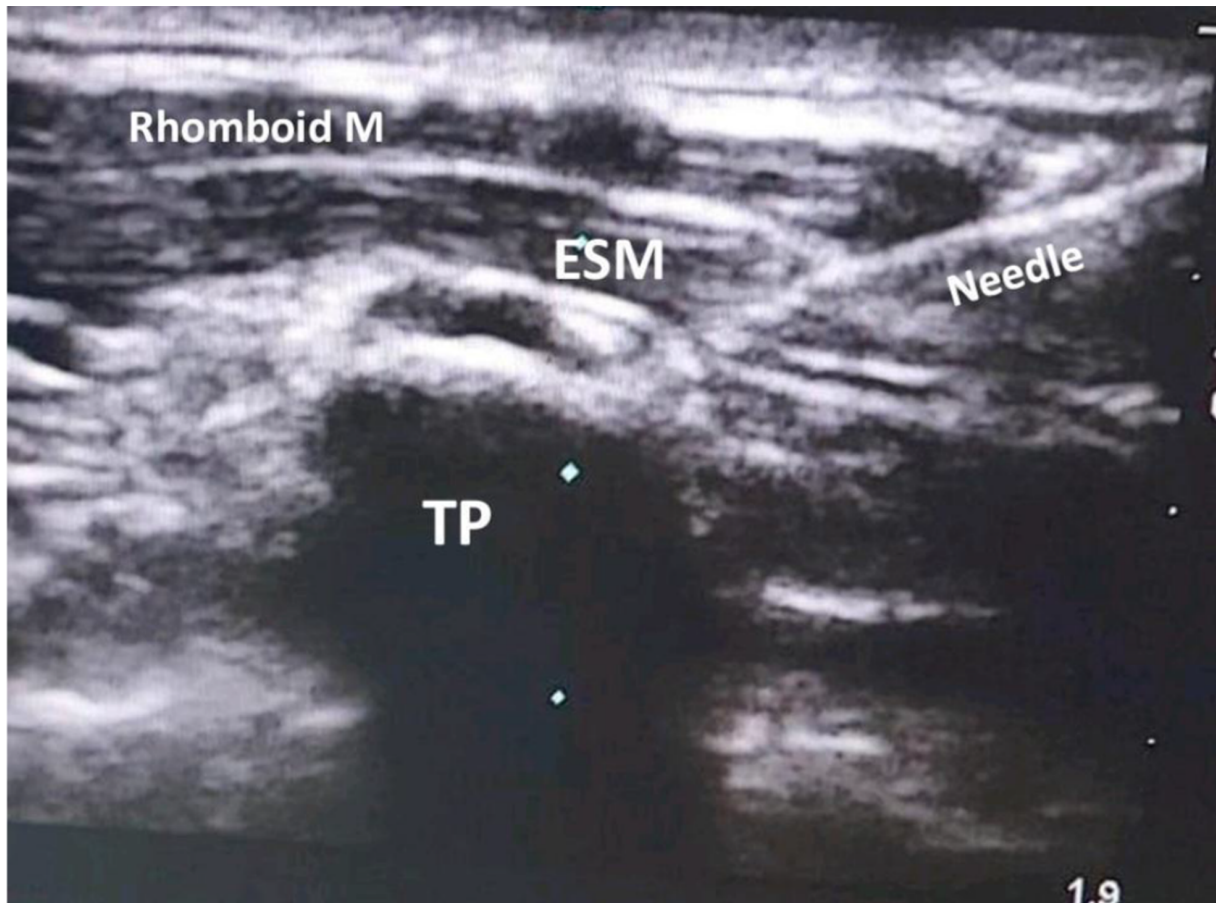
The mechanism of action of the ESP block is still not clearly understood ([11](#)). Presumably, the injection of a local anesthetic agent in the fascial plane between the erector spinae muscle and the tips of the transverse processes anesthetizes neural structures passing within this space. The local anesthetic agent then presumably spreads out of

**Table 3.** Comparison Between the 2 Groups According to Postoperative Complications<sup>a</sup>

Postoperative complications	Group N (n = 48)	Group ES (n = 50)	P Value
Vomiting	4 (8.3)	2 (4)	0.431
Itching	3 (6.3)	2 (4)	0.674
Fever	2 (4.2)	3 (6)	1.000
Respiratory depression	2 (4.2)	2 (4)	1.000
Hypotension	1 (2.1)	2 (4)	1.000
Bradycardia	2 (4.2)	0 (0)	0.237

<sup>a</sup> Values are expressed as No. (%).

that space anteriorly and laterally to achieve general anesthesia of the dorsal rami and ventral rami of the spinal nerves and the lateral cutaneous nerve branches. A single-injection ESP block can spread to at least 3 and maximum 8 spinal nerve territories. Thus, a single injection at the fourth or fifth spine process level is presumably sufficient to produce adequate anesthesia for the anterior, lateral, and posterior parts of the chest wall. In this study, we per-



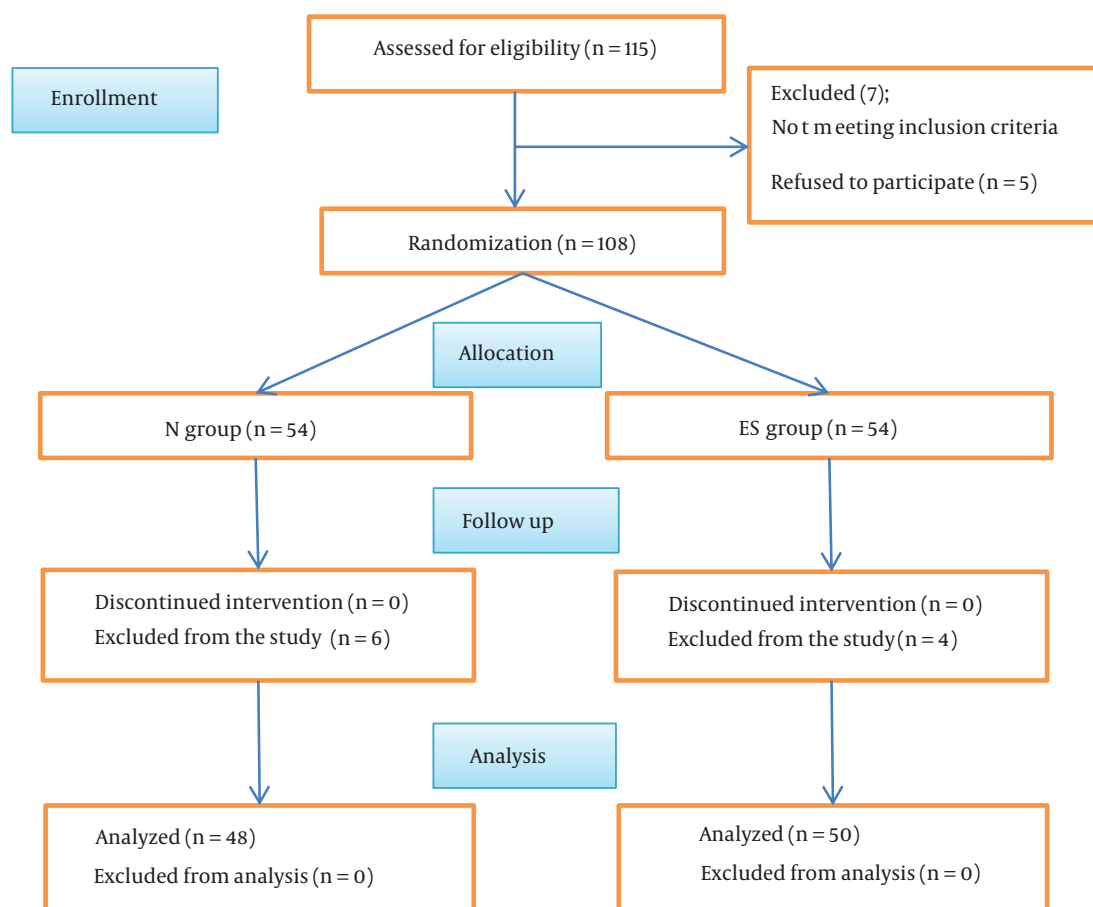
**Figure 2.** A needle penetrates the muscles until hitting the transverse process (abbreviations: TP, transverse process; ESM, erector spinae muscle).

formed a bilateral ESP block to secure complete chest wall anesthesia, with the extension of the anesthetic effect to the sternum (12, 13).

ESP blocks were initially recommended for the management of chronic thoracic pain. Subsequently, a number of clinical trials detailed the role of bilateral ESP blocks in the management of perioperative pain in thoracic and cardiac surgeries (14). Muñoz-Leyva et al published a case series of 5 adult patients for whom they used a catheter technique to deliver continuous bilateral ESP blocks. They reported low intraoperative opioid consumption, early extubation in the operating room, and proper postoperative pain management without supplemental opioids in 4 of 5 cases (15). Tsui et al. also reported decreased intraoperative opioid consumption, early extubation, and decreased postoperative pain in a case report of an adult patient who had received bilateral ESP blocks before a cardiac surgery conducted via sternotomy (16). In a case report of 1 pediatric patient, Wong et al detailed using bilateral ESP blocks

to manage perioperative median sternotomy pain. The patient was extubated during the first 3 hours postoperatively, and a pain score of zero was achieved during the 48 hours postoperatively without the use of opioids (17).

Kaushal et al. reported a reduction in intraoperative fentanyl consumption, lower postoperative pain scores, and prolonged postoperative duration of analgesia in pediatric patients who had received bilateral ESP blocks before sternotomy. As with their clinical trial, we aimed to investigate the efficacy of bilateral ESP blocks in pediatric cardiac surgeries. For the most part, our study produced comparable findings to their clinical trial. Some differences existed between the 2 studies. One important difference was the local anesthetic used. We used bupivacaine, 0.25%, as a local anesthetic, while Kaushal et al. used ropivacaine, 0.2%. In addition, our primary endpoint was intraoperative fentanyl consumption, and we used the FLACC score for postoperative pain assessment and morphine for postoperative analgesia. In their study, the primary out-



**Figure 3.** The CONSORT flow chart (abbreviations: ES group, erector spinae plan block group; N group, no block group).

come involved the modified objective pain score (MOPS) at 24 hours postoperatively, and they used fentanyl for intraoperative and postoperative analgesia. Furthermore, our study sample (98 patients) was larger than their sample of 80 patients (10).

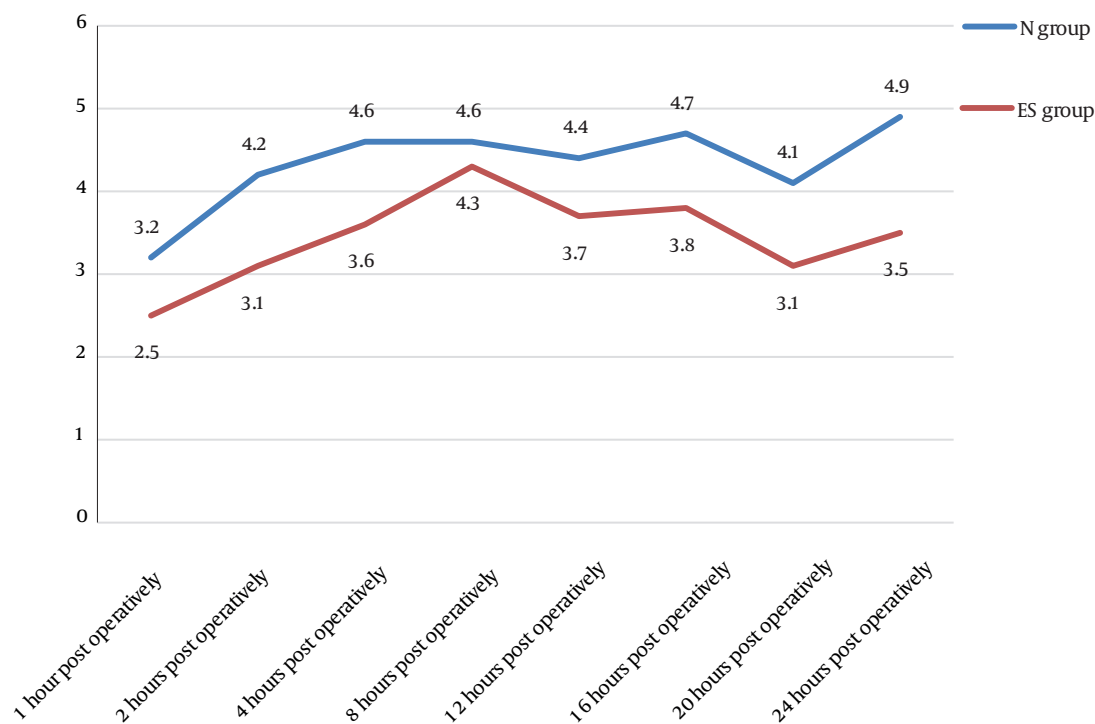
Macaire et al. reported a significant reduction of morphine consumption during the 48 hours following pediatric cardiac surgery in patients who had received bilateral ESP blocks with blouses of 0.2% ropivacaine ( $120 \pm 320 \mu\text{g.kg}^{-1}$ ) compared with patients who had received bilateral ESP blocks with saline ( $512 \pm 560 \mu\text{g.kg}^{-1}$ ;  $P = 0.03$ ). In our study, we noted lower morphine consumption in patients who had received bilateral single-shot ESP blocks with bupivacaine ( $0.4 \pm 0.2 \text{ mg.kg}^{-1}$ ) compared with those who received no block ( $0.5 \pm 0.2 \text{ mg.kg}^{-1}$ ;  $P < 0.001$ ) (18).

Another clinical trial was carried out to assess the efficacy of bilateral ESP block vs. thoracic epidural analgesia in adult patients scheduled for open cardiac surgery. It demonstrated comparable results regarding intraoper-

ative fentanyl consumption and postoperative Visual Analog Scale (VAS), especially in the first 12 hours postoperatively. These results further support the recommendation to use bilateral ESP blocks because of their high efficacy with a low incidence of complications (19).

Krishna et al. found that bilateral ESP blocks with 0.375% ropivacaine produced better analgesia than conventional analgesia with paracetamol and tramadol in an adult population undergoing sternotomy. They reported significant differences between both groups regarding the timing of the first rescue analgesia, standing at  $8.9 \pm 0.14$  hours with the ESP block and  $4.6 \pm 0.12$  hours in the control group ( $P = 0.0001$ ). In our study, there was a significant delay in the need for first rescue analgesia in the ES group ( $231.6 \pm 104.5$  minutes) compared with the N group ( $108.8 \pm 47.8$  minutes;  $P < 0.001$ ) (20).

The safety of ESP blocks was demonstrated by a retrospective study conducted on 164 general and pediatric thoracic surgeries. The authors reported no complications



**Figure 4.** Comparison between the 2 groups according to postoperative mean FLACC pain score over time.

following ESP blocks in pediatric patients. In the current study, we did not record any serious complications in the study population. A small number of complications, such as vomiting, itching, bradycardia, hypotension, and fever, occurred and were managed accordingly with no significant differences between the 2 groups (21).

The limitation of this study was that we did not include complicated cardiac surgeries or cardiac surgical procedures of long duration because it was not included in the scope of our study. Accordingly, we included only ASA II and III patients in our study as per the 2020 ASA classification.

The results of bilateral ESP blocks for the management of perioperative sternotomy pain appear to be promising. Accordingly, we recommend further research to be conducted to compare the efficacy of bilateral ESP block vs other regional techniques in pediatric open cardiac surgeries.

### 5.1. Conclusions

Bilateral ultrasound-guided ESP blocks can be used to reduce perioperative opioid consumption in pediatric patients undergoing cardiac surgery through a sternotomy.

It can also play an important role in decreasing postoperative pain scores and facilitating early extubation.

### Footnotes

**Authors' Contribution:** A. G., contributed to the concept, design, definition of intellectual content, literature search, clinical studies, experimental studies, data acquisition, data analysis, statistical analysis, manuscript preparation, manuscript editing, and manuscript review; W. A., contributed to the concept, design, definition of intellectual content, literature search, clinical studies, experimental studies, data analysis, statistical analysis, manuscript preparation, manuscript editing, and manuscript review; H. A., contributed to the concept, design, definition of intellectual content, literature search, clinical studies, experimental studies, data acquisition, data analysis, statistical analysis, manuscript preparation, manuscript editing, and manuscript review; A. I., contributed to the concept, design, definition of intellectual content, literature search, clinical studies, experimental studies, data analysis, statistical analysis, manuscript preparation, manuscript editing, and manuscript review.



**Clinical Trial Registration Code:** NCT04452656 (<https://ClinicalTrials.gov/NCT04452656>).

**Conflict of Interests:** The authors declare that there is no conflict of interests.

**Data Reproducibility:** The dataset presented in the study is available on request from the corresponding author during submission or after its publication. The data are not publicly available due to institutional rules.

**Ethical Approval:** This study was approved under the ethical approval code, N473-2020.

**Funding/Support:** This project is self-funded. We did not receive any financial funding or support.

**Informed Consent:** Informed consent was obtained from all the participants prior to their participation in this study.

## References

- Chaudhary V, Chauhan S, Choudhury M, Kiran U, Vasdev S, Talwar S. Parasternal intercostal block with ropivacaine for postoperative analgesia in pediatric patients undergoing cardiac surgery: a double-blind, randomized, controlled study. *J Cardiothorac Vasc Anesth*. 2012;**26**(3):439–42. doi: [10.1053/j.jvca.2011.10.012](https://doi.org/10.1053/j.jvca.2011.10.012). [PubMed: [22176767](https://pubmed.ncbi.nlm.nih.gov/22176767/)].
- Grant MC, Isada T, Ruzankin P, Gottschalk A, Whitman G, Lawton JS, et al. Opioid-Sparing Cardiac Anesthesia: Secondary Analysis of an Enhanced Recovery Program for Cardiac Surgery. *Anesth Analg*. 2020;**131**(6):1852–61. doi: [10.1213/ANE.0000000000005152](https://doi.org/10.1213/ANE.0000000000005152). [PubMed: [32889848](https://pubmed.ncbi.nlm.nih.gov/32889848/)].
- Caruso TJ, Lawrence K, Tsui BCH. Regional anesthesia for cardiac surgery. *Curr Opin Anaesthesiol*. 2019;**32**(5):674–82. doi: [10.1097/ACO.0000000000000769](https://doi.org/10.1097/ACO.0000000000000769). [PubMed: [31356362](https://pubmed.ncbi.nlm.nih.gov/31356362/)].
- Barr LF, Boss MJ, Mazzeffi MA, Taylor BS, Salenger R. Postoperative Multimodal Analgesia in Cardiac Surgery. *Crit Care Clin*. 2020;**36**(4):631–51. doi: [10.1016/j.ccc.2020.06.003](https://doi.org/10.1016/j.ccc.2020.06.003). [PubMed: [32892818](https://pubmed.ncbi.nlm.nih.gov/32892818/)].
- Edinoff AN, Girma B, Trettin KA, Horton CC, Kaye AJ, Cornett EM, et al. Novel Regional Nerve Blocks in Clinical Practice: Evolving Techniques for Pain Management. *Anesth Pain Med*. 2021;**11**(4). e118278. doi: [10.5812/aapm.118278](https://doi.org/10.5812/aapm.118278). [PubMed: [34692446](https://pubmed.ncbi.nlm.nih.gov/34692446/)]. [PubMed Central: [PMC8520672](https://pubmed.ncbi.nlm.nih.gov/PMC8520672/)].
- Rahimzadeh P, Imani F, Faiz SHR, Boroujeni BV. Impact of the Ultrasound-Guided Serratus Anterior Plane Block on Post-Mastectomy Pain: A Randomised Clinical Study. *Turk J Anaesthesiol Reanim*. 2018;**46**(5):388–92. doi: [10.5152/TJAR.2018.86719](https://doi.org/10.5152/TJAR.2018.86719). [PubMed: [30263863](https://pubmed.ncbi.nlm.nih.gov/30263863/)]. [PubMed Central: [PMC6157977](https://pubmed.ncbi.nlm.nih.gov/PMC6157977/)].
- Forero M, Adhikary SD, Lopez H, Tsui C, Chin KJ. The Erector Spinae Plane Block: A Novel Analgesic Technique in Thoracic Neuropathic Pain. *Reg Anesth Pain Med*. 2016;**41**(5):621–7. doi: [10.1097/AAP.0000000000000451](https://doi.org/10.1097/AAP.0000000000000451). [PubMed: [27501016](https://pubmed.ncbi.nlm.nih.gov/27501016/)].
- Chen N, Qiao Q, Chen R, Xu Q, Zhang Y, Tian Y. The effect of ultrasound-guided intercostal nerve block, single-injection erector spinae plane block and multiple-injection paravertebral block on postoperative analgesia in thoracoscopic surgery: A randomized, double-blinded, clinical trial. *J Clin Anesth*. 2020;**59**:106–11. doi: [10.1016/j.jclinane.2019.07.002](https://doi.org/10.1016/j.jclinane.2019.07.002). [PubMed: [31330457](https://pubmed.ncbi.nlm.nih.gov/31330457/)].
- Greaney D, Everett T. Paediatric regional anaesthesia: updates in central neuraxial techniques and thoracic and abdominal blocks. *BJA Educ*. 2019;**19**(4):126–34. doi: [10.1016/j.bjae.2018.12.003](https://doi.org/10.1016/j.bjae.2018.12.003). [PubMed: [33456881](https://pubmed.ncbi.nlm.nih.gov/33456881/)]. [PubMed Central: [PMC7807850](https://pubmed.ncbi.nlm.nih.gov/PMC7807850/)].
- Kaushal B, Chauhan S, Magoon R, Krishna NS, Saini K, Bhoi D, et al. Efficacy of Bilateral Erector Spinae Plane Block in Management of Acute Postoperative Surgical Pain After Pediatric Cardiac Surgeries Through a Midline Sternotomy. *J Cardiothorac Vasc Anesth*. 2020;**34**(4):981–6. doi: [10.1053/j.jvca.2019.08.009](https://doi.org/10.1053/j.jvca.2019.08.009). [PubMed: [31551910](https://pubmed.ncbi.nlm.nih.gov/31551910/)].
- Ivanusic J, Konishi Y, Barrington MJ. A Cadaveric Study Investigating the Mechanism of Action of Erector Spinae Blockade. *Reg Anesth Pain Med*. 2018;**43**(6):567–71. doi: [10.1097/AAP.0000000000000789](https://doi.org/10.1097/AAP.0000000000000789). [PubMed: [29746445](https://pubmed.ncbi.nlm.nih.gov/29746445/)].
- Chin KJ, Pawa A, Forero M, Adhikary S. Ultrasound-Guided Fascial Plane Blocks of the Thorax: Pectoral I and II, Serratus Anterior Plane, and Erector Spinae Plane Blocks. *Adv Anesth*. 2019;**37**:187–205. doi: [10.1016/j.aan.2019.08.007](https://doi.org/10.1016/j.aan.2019.08.007). [PubMed: [31677656](https://pubmed.ncbi.nlm.nih.gov/31677656/)].
- Chin KJ, Adhikary SD, Forero M. Erector Spinae Plane (ESP) Block: a New Paradigm in Regional Anesthesia and Analgesia. *Curr Anesthesiol Rep*. 2019;**9**(3):271–80. doi: [10.1007/s40140-019-00333-0](https://doi.org/10.1007/s40140-019-00333-0).
- Tsui BCH, Fonseca A, Munshey F, McFadyen G, Caruso TJ. The erector spinae plane (ESP) block: A pooled review of 242 cases. *J Clin Anesth*. 2019;**53**:29–34. doi: [10.1016/j.jclinane.2018.09.036](https://doi.org/10.1016/j.jclinane.2018.09.036). [PubMed: [30292068](https://pubmed.ncbi.nlm.nih.gov/30292068/)].
- Munoz-Leyva F, Chin KJ, Mendiola WE, Cubillos J, Moreno DA, Zhong-Lin C, et al. Bilateral Continuous Erector Spinae Plane (ESP) Blockade for Perioperative Opioid-Sparing in Median Sternotomy. *J Cardiothorac Vasc Anesth*. 2019;**33**(6):1698–703. doi: [10.1053/j.jvca.2018.05.047](https://doi.org/10.1053/j.jvca.2018.05.047). [PubMed: [30871950](https://pubmed.ncbi.nlm.nih.gov/30871950/)].
- Tsui BCH, Navaratnam M, Boltz G, Maeda K, Caruso TJ. Bilateral automated intermittent bolus erector spinae plane analgesic blocks for sternotomy in a cardiac patient who underwent cardiopulmonary bypass: A new era of Cardiac Regional Anesthesia. *J Clin Anesth*. 2018;**48**:9–10. doi: [10.1016/j.jclinane.2018.04.005](https://doi.org/10.1016/j.jclinane.2018.04.005). [PubMed: [29684728](https://pubmed.ncbi.nlm.nih.gov/29684728/)].
- Wong J, Navaratnam M, Boltz G, Maeda K, Ramamurthi RJ, Tsui BCH. Bilateral continuous erector spinae plane blocks for sternotomy in a pediatric cardiac patient. *J Clin Anesth*. 2018;**47**:82–3. doi: [10.1016/j.jclinane.2018.03.020](https://doi.org/10.1016/j.jclinane.2018.03.020). [PubMed: [29631111](https://pubmed.ncbi.nlm.nih.gov/29631111/)].
- Macaire P, Ho N, Nguyen V, Phan Van H, Dinh Nguyen Thien K, Bringuier S, et al. Bilateral ultrasound-guided thoracic erector spinae plane blocks using a programmed intermittent bolus improve opioid-sparing postoperative analgesia in pediatric patients after open cardiac surgery: a randomized, double-blind, placebo-controlled trial. *Reg Anesth Pain Med*. 2020;**45**(10):805–12. doi: [10.1136/rapm-2020-101496](https://doi.org/10.1136/rapm-2020-101496). [PubMed: [32817407](https://pubmed.ncbi.nlm.nih.gov/32817407/)].
- Nagaraja PS, Ragavendran S, Singh NG, Asai O, Bhavya G, Manjunath N, et al. Comparison of continuous thoracic epidural analgesia with bilateral erector spinae plane block for perioperative pain management in cardiac surgery. *Ann Card Anaesth*. 2018;**21**(3):323–7. doi: [10.4103/aca.ACA\\_16\\_18](https://doi.org/10.4103/aca.ACA_16_18). [PubMed: [30052229](https://pubmed.ncbi.nlm.nih.gov/30052229/)]. [PubMed Central: [PMC6078032](https://pubmed.ncbi.nlm.nih.gov/PMC6078032/)].
- Krishna SN, Chauhan S, Bhoi D, Kaushal B, Hasija S, Sangdup T, et al. Bilateral Erector Spinae Plane Block for Acute Post-Surgical Pain in Adult Cardiac Surgical Patients: A Randomized Controlled Trial. *J Cardiothorac Vasc Anesth*. 2019;**33**(2):368–75. doi: [10.1053/j.jvca.2018.05.050](https://doi.org/10.1053/j.jvca.2018.05.050). [PubMed: [30055991](https://pubmed.ncbi.nlm.nih.gov/30055991/)].
- Holland EL, Bosenberg AT. Early experience with erector spinae plane blocks in children. *Paediatr Anaesth*. 2020;**30**(2):96–107. doi: [10.1111/pan.13804](https://doi.org/10.1111/pan.13804). [PubMed: [31883421](https://pubmed.ncbi.nlm.nih.gov/31883421/)].